


भारत सरकार
GOVERNMENT OF INDIA



प्रीतम सोलंकी
Pritam Solanki

जन्म वर्ष / Year of Birth : 1991
पुरुष / Male



9856 3507 9719

आधार – आम आदमी का अधिकार

Pritam



Dr. NITIN AGARWAL
MBBS, MD
Regn. No. DMC-R-1436

ONEPLUS ULTRASOUND LAB
27, Harsh Vihar, Pitam Pura,
Delhi-110034
Ph. 011-42480101, 9599913051
E-mail: oneplusul@gmail.com

प्रीतम सोलंकी, बी-७९-८०
सुरेंद्र सोलंकी, सी-७९-८०
आवण्टिका सेक्टर-१, रोहिणी, दिल्ली
रोहिणी, रोहिणी सेक्टर-७, नॉर्थ
वेस्ट दिल्ली, दिल्ली, 110085

UNIQUE IDENTIFICATION AUTHORITY OF INDIA
भारतीय पहचान प्राधिकार

1947
1800 180 1947


www.uidai.gov.in
help@uidai.gov.in

P.O. Box No.1947
Bengaluru-560 001



[Handwritten signature]

Dr. NITIN AGARWAL
MBBS, MD
Regn. No. DMC-R-1436

Byitem

ONEPLUS ULTRASOUND LAB
47, Harsh Vihar, Pitam Pura,
Delhi-110034
Ph. 011-42480101, 9599913051
E-mail: oneplusul@gmail.com

I do not wish to conduct
stool sample test.



9811312239



Dr. NITIN AGARWAL
MBBS, MD
Regn. No. DMC-R-1436

ONEPLUS ULTRASOUND LAB
47, Harsh Vihar, Pitam Pura,
Delhi-110034
Ph. 011-42480101, 9599913051
E-mail: oneplusul@gmail.com



OnePLUS
Ultrasound Lab
— QUALITY FIRST... ALWAYS! —

Dr. Nitin Agarwal
Pathologist & Director
Ex. Sr. Res. MAMC
& Lok Nayak Hospital
Ex. Chief of Lab Dr. Lal Path Labs.

Dr. Pooja (Garg) Agarwal
Radiologist & Director
MAMC & Lok Nayak Hospital

Name	: Mr. PRITAM SOLANKI	Age/Sex	: 30 YRS/Male
Ref. By	: Dr. MEDIWHEEL	Lab No	: 012201110007
Date	: 11-Jan-2022	Patient ID	: LSHHI89825

ULTRASOUND EXAMINATION----WHOLE ABDOMEN

Liver is normal in size and normal in outline with normal echopattern. Intrahepatic biliary radicles are not dilated. No abscess or mass lesion seen. Hepatic veins, portal vein, IVC and aorta are normal. CBD is normal (5.0 mm) in caliber.

Gall bladder is well distended with anechoic lumen. Wall thickness is normal.

Both kidneys are normal in size, shape, position, outline and echopattern. Corticomedullary differentiation is maintained. No pelvicalyceal dilation or mass lesion is seen.

Spleen is normal in size and echotexture. No mass lesion seen.

Pancreas is normal in size, outline and echotexture.

Urinary bladder is normal in shape and position. No evidence of intravesical stone or mass seen.

Prostate is normal in size, shape and echopattern.

Prostate measures 2.7 x 2.3 x 2.8 cm. **Weight of prostate is 9.2 grams.**

No abnormal bowel wall thickening seen in right iliac fossa.
No free fluid seen anywhere in abdomen.

IMPRESSION:

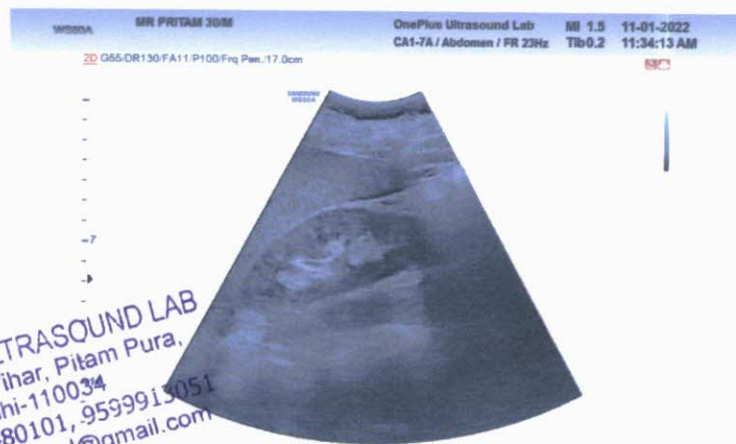
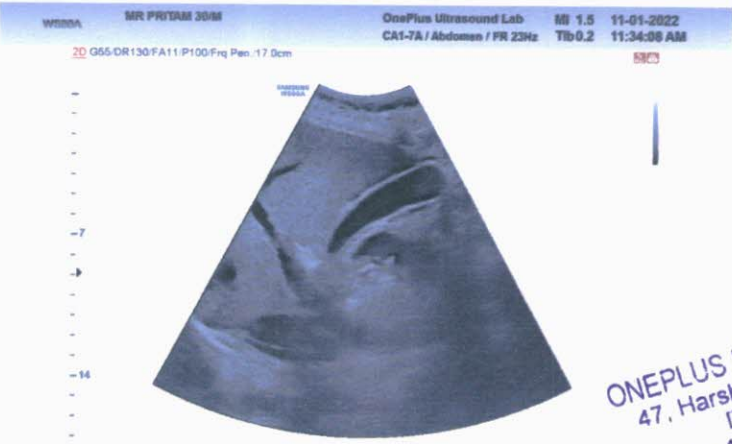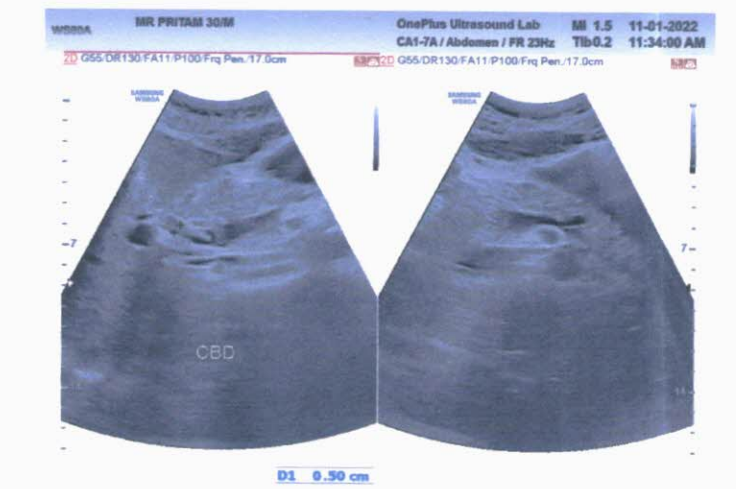
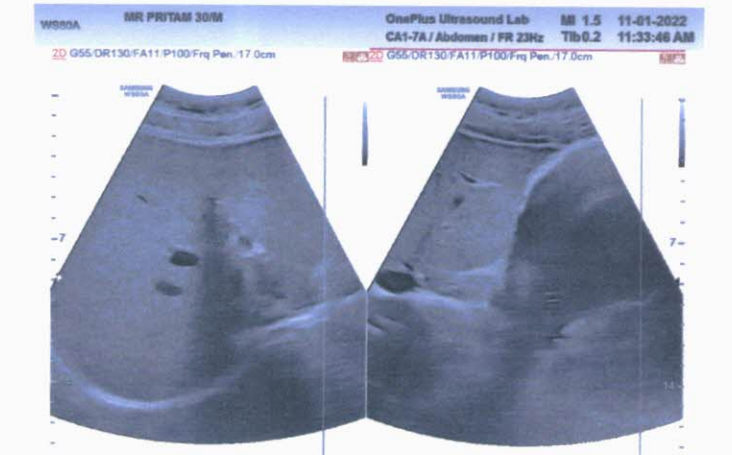
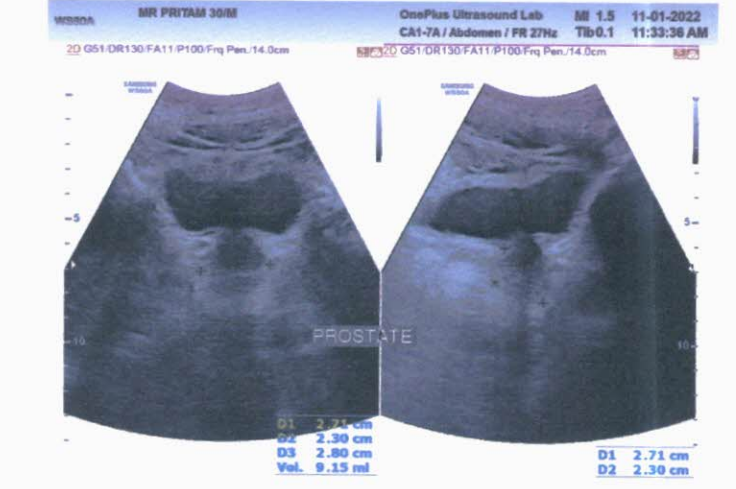
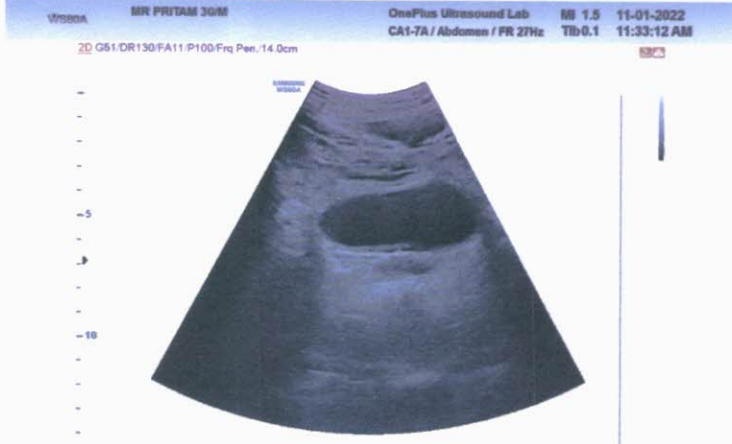- Normal study.

DR. POOJA GARG
RADIOLOGIST
REG NO- DMC/R/03398

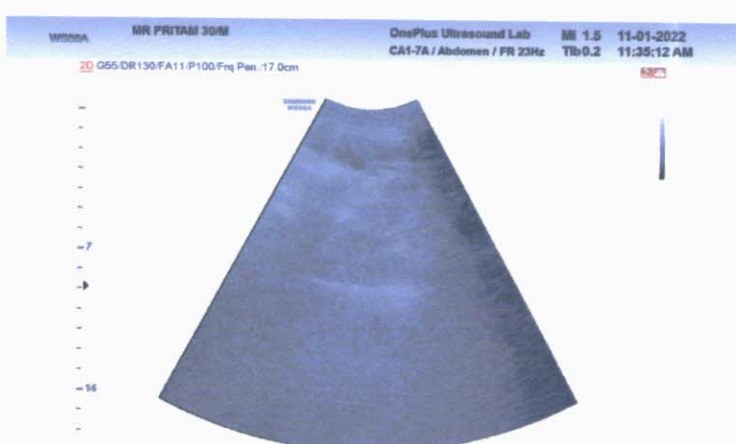
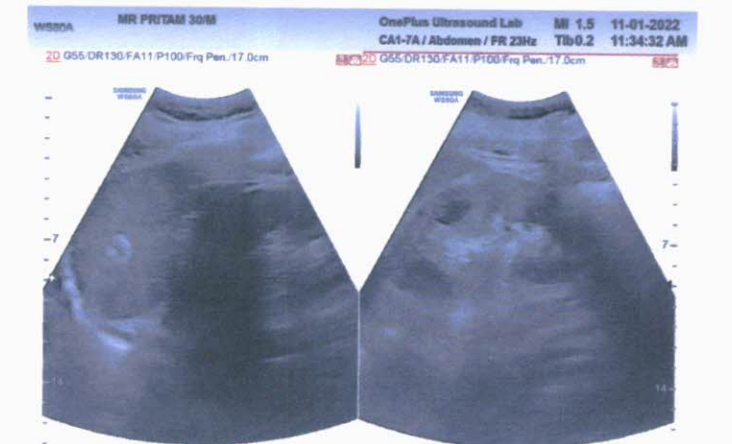
Dr. POOJA GARG
M.B.B.S., D.M.R.D
Reg No. DMC/R/03398
Radiologist

Type By : pooja

47, Harsh Vihar, Pitampura, New Delhi-110034 | Ph.: 011-42480101, 9599913051
E-mail: oneplusul@gmail.com | Web.: www.oneplusul.in



ONEPLUS ULTRASOUND LAB
47, Harsh Vihar, Pitam Pura,
Delhi-110034
Ph. 011-42480101, 9599915051
E-mail: oneplusul@gmail.com






Figure 1. Left: ... Right: ...



Figure 2. ...



Figure 3. ...

...
...
...
...
...



Figure 4. ...



Figure 5. Left: ... Right: ...



Figure 6. Left: ... Right: ...



Figure 7. ...




Figure 8. Left: ... Right: ...



OnePLUS
Ultrasound Lab
— QUALITY FIRST... ALWAYS! —

Dr. Nitin Agarwal
Pathologist & Director
Ex. Sr. Res. MAMC
& Lok Nayak Hospital
Ex. Chief of Lab Dr. Lal Path Labs.

Dr. Pooja (Garg) Agarwal
Radiologist & Director
MAMC & Lok Nayak Hospital

Name	: Mr. PRITAM SOLANKI	Age/Sex	: 30 YRS/Male
Ref. By	: Dr. MEDIWHEEL	Lab No	: 012201110007
Date	: 11-Jan-2022	Patient ID	: LSHHI89825

X-ray-Chest PA view

Bony cage and soft tissues are normal.
Cardiothoracic ratio is normal.
Mediastinum is normal.
Both hila are normal.
Both costophrenic angles are clear.
Both domes of diaphragm are normal.
Lung fields are clear. No parenchymal lesion seen.

IMPRESSION: Normal Study.

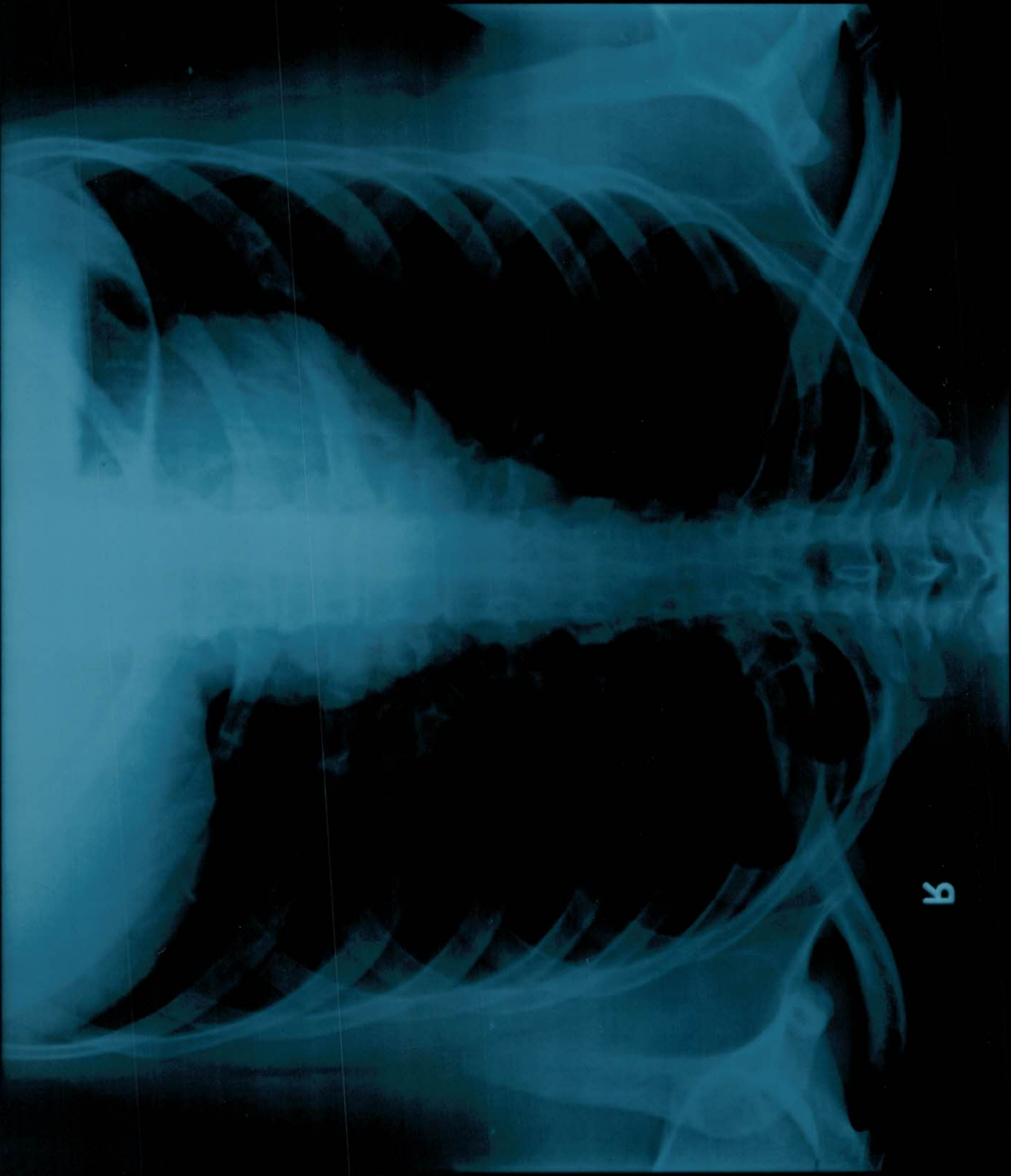
DR. POOJA GARG
RADIOLOGIST
REG NO- DMC/R/03398

Dr. POOJA GARG
M.B.B.S., D.M.R.D
Reg No. DMC/R/03398
Radiologist

Type By : pooja

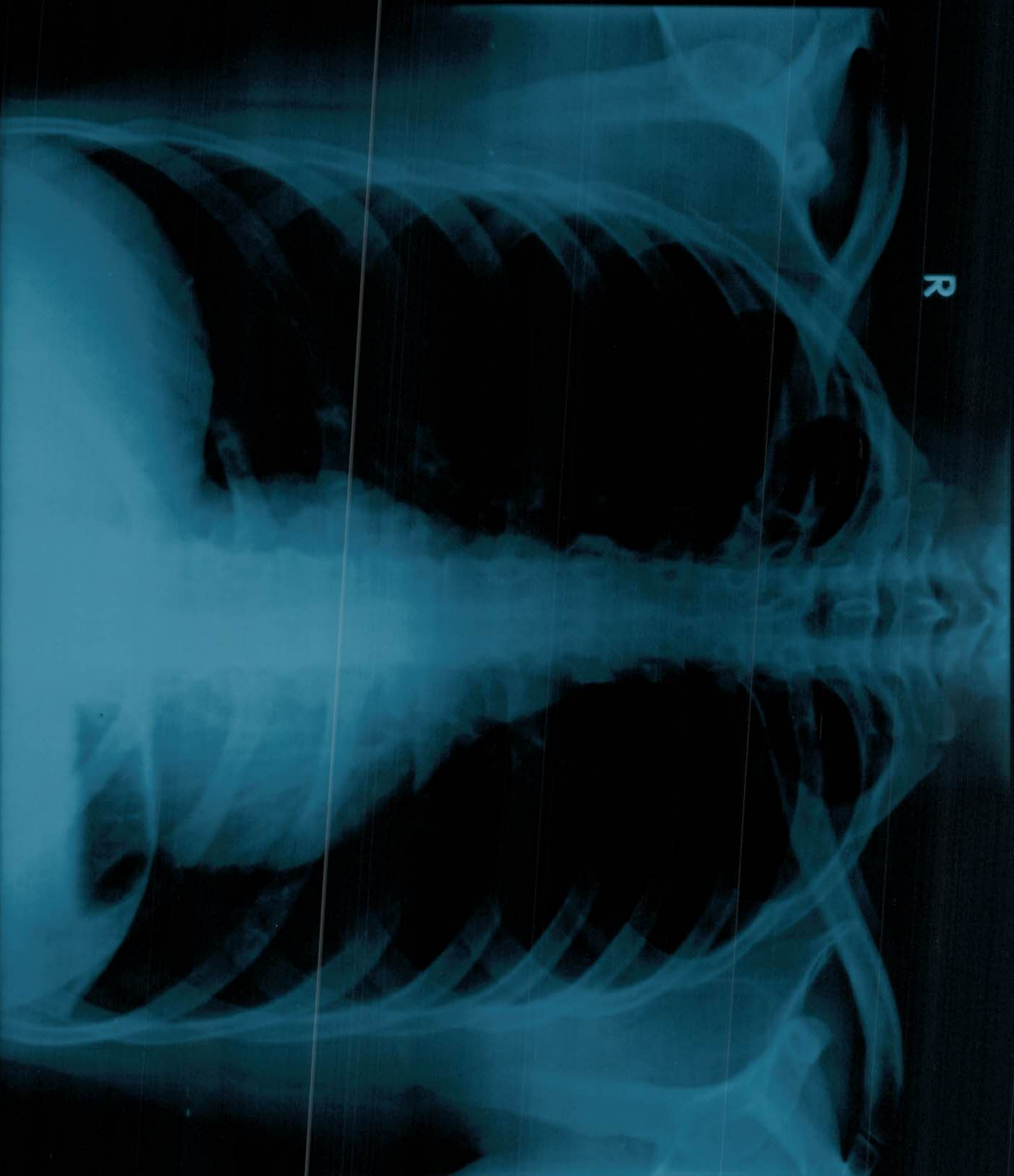
47, Harsh Vihar, Pitampura, New Delhi-110034 | Ph.: 011-42480101, 9599913051
E-mail: oneplusul@gmail.com | Web.: www.oneplusul.in

МР ҮРІТІМ СОЛЖИКИ АСЕ 30 ҮРІС ССОС-І-ІІ СҮУ АТТІ ШІУ АҚТІСІ М СЕСТ ҮА ВІЕМ ІІІ\ІІІ ССОС\ІІІ АУМАТІР, ЯННІУ НІАІІУ НАРІШ ІНІАР, ҮІТІМЬІА



Р

R



MR PRITAM SOLANKI AGE 30 YRS 11-1-2022 M CHEST PA VIEW 1/11/2022
ONEPLUS ULTRASOUND LAB,47-HARSH VIHAR,PITAMPURA

ONEPLUS ULTRASOUND LAB

47, HARSH VIHAR, PITAMPURA, DELHI- 110034

Mr. PRITAM SOLANKI
 Age : 30M
 Ref. by : MEDIWHEEL
 Indication1 :
 Indication2 :
 Indication3 :
 COMMENTS :

ID : 1850
 HMMT : 17071
 Recorded : 11-1-2022 10:14
 Medication1 :
 Medication2 :
 Medication3 :

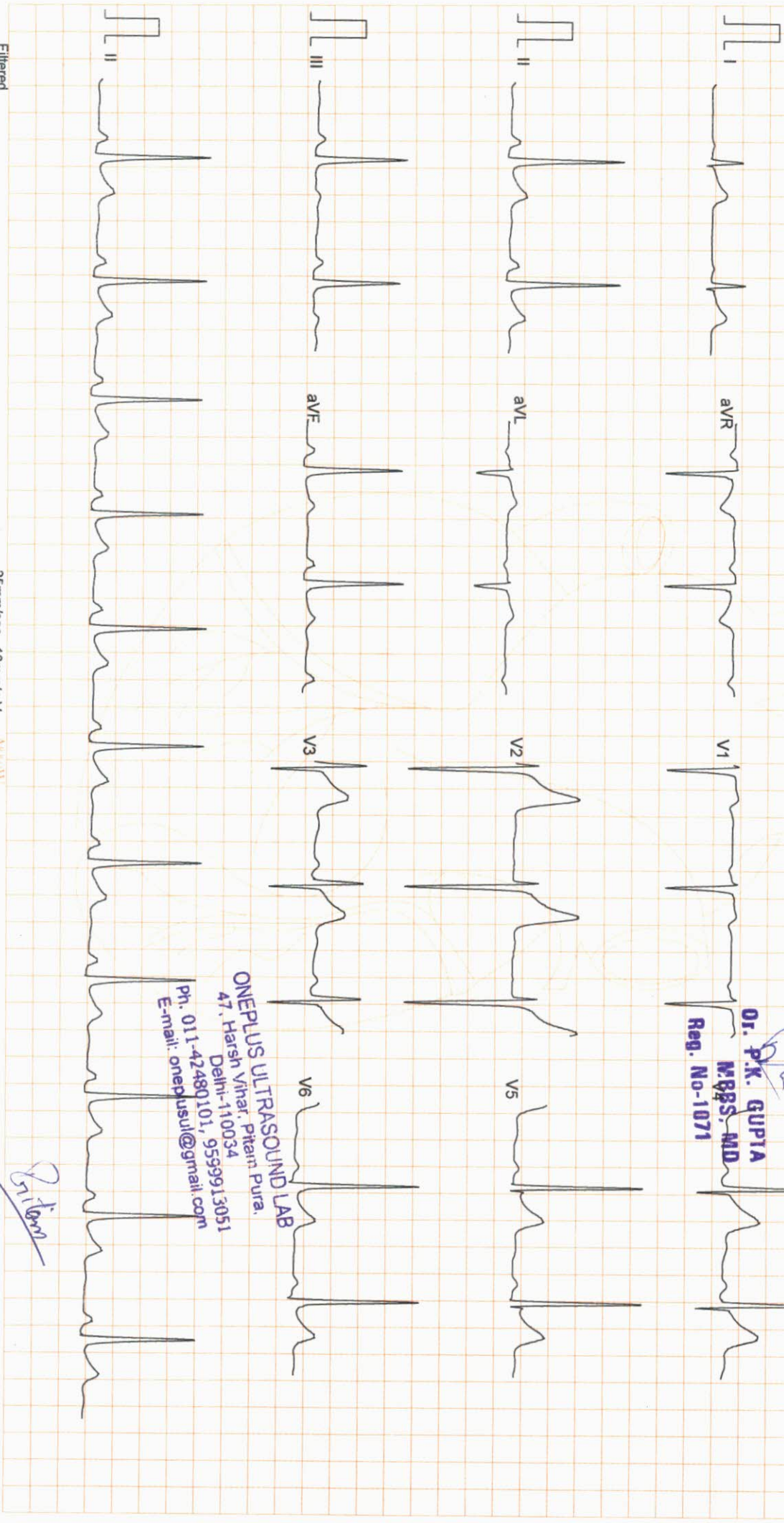
BPM : 68
 BP : 136/86
 P Axis : 82 deg
 QRS Axis : 77 deg
 T Axis : 40 deg

P duration : 86 msec
 PR duration : 153 msec
 QRS duration : 100 msec
 QT Interval : 343 msec
 QTc Interval : 357 msec

Unconfirmed Report Reviewed By:

Cardiologist

Dr. P.K. GUPTA
M.BBS, MD
 Reg. No-1071



ONEPLUS ULTRASOUND LAB
 47, Harsh Vihar, Pitam Pura,
 Delhi-110034
 Ph. 011-42480101, 9559913051
 E-mail: oneplusul@gmail.com

Filtered

25mm/sec 10mm/mV

CardiCom, INDIA

Pritam

ONEPLUS ULTRASOUND LAB

47, HARSH VIHAR PITAMPURA DELHI 110034

ID : 990

HtWt : 170/71
Recorded : 11-1-2022 10:19

TREADMILL TEST SUMMARY REPORT

Protocol: BRUCE

History:

Medication 1 :

Medication 2 :

Medication 3 :

Mr. PRITAM SOLANKI
Age/Sex : 30/M
Ref. by : MEDIVHEEL

Indication 1 :

Indication 2 :

Indication 3 :

PHASE	PHASE TIME	STAGE TIME	SPEED (Km./Hr.)	GRADE (%)	H.R. (BPM)	B.P. (mmHg)	RPP X100	II	ST LEVEL (mm) V2	V5	METS
STANDING											
SUPINE											
STAGE 1	2:59	2:59	2.70	10.00	72	136/86	97	1.2	5.2	2.3	4.80
STAGE 2	5:59	2:59	4.00	12.00	81	136/86	99	1.2	5.2	2.3	7.10
STAGE 3	8:59	2:59	5.40	14.00	100	146/88	146	1.5	5.0	2.8	10.00
STAGE 4	10:14	1:14	6.70	16.00	130	158/90	205	1.8	5.6	3.2	11.65
PEAK EXER	10:22	1:22			166	170/92	282	1.3	5.7	3.5	
RECOVERY	2:59	2:59	0.00	0.00	168	170/92	285	1.4	5.9	3.5	11.83
					76	136/86	103	0.4	2.2	0.8	

RESULTS

Exercise Duration : 10:22 Minutes

Max Heart Rate : 168 bpm 88 % of target heart rate 190 bpm

Max Blood Pressure : 170/92 mmHg

Max Work Load : 11.83 METS

Reason of Termination :

IMPRESSIONS

Normal for subject

ONEPLUS ULTRASOUND LAB
47, Harsh Vihar, Pitara, Pura,
Delhi-110034
Ph. 011-42480101, 9599913051
E-mail: oneplusul@gmail.com

Cardiologist
DR. P. K. GUPTA
MBBS, MD
Reg. No-1071

ONEPLUS ULTRASOUND LAB

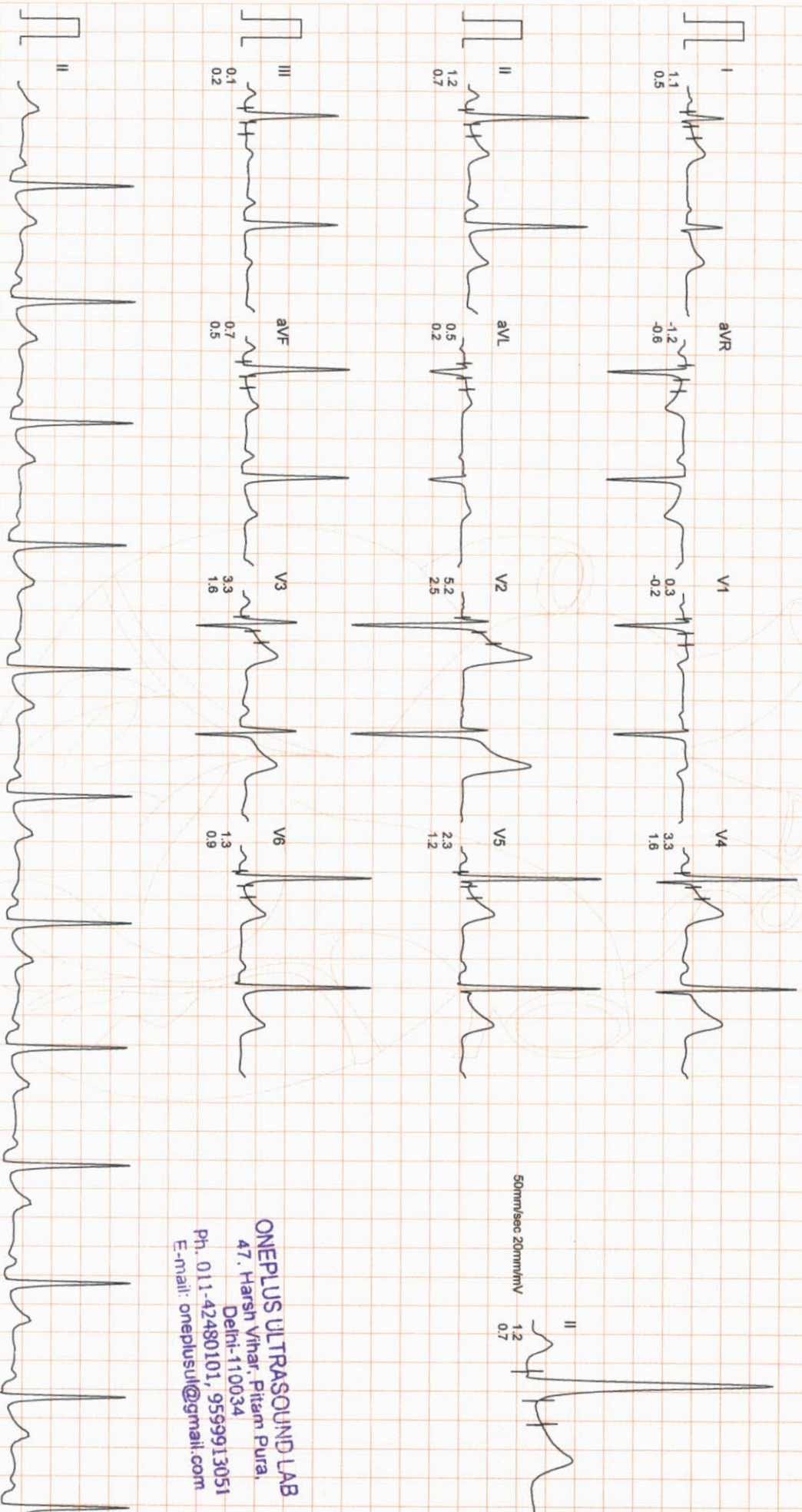
STANDING
PRETEST

ST @ 10mm/mV
80ms PostJ

Mr. PRITAM SOLANKI
I.D. : 990
AGE/SEX : 30/M
RECORDED : 11-1-2022 10:19

RATE : 72 BPM
B.P. : 136/86 mmHg

LINKED MEDIAN



ONEPLUS ULTRASOUND LAB
47, Harsh Vihar, Pitam Pura,
Delhi-110034
Ph. 011-42480101, 9559913051
E-mail: oneplusul@gmail.com

ONEPLUS ULTRASOUND LAB

Mr. PRITAM SOLANKI
I.D. : 990
AGE/SEX : 30/M

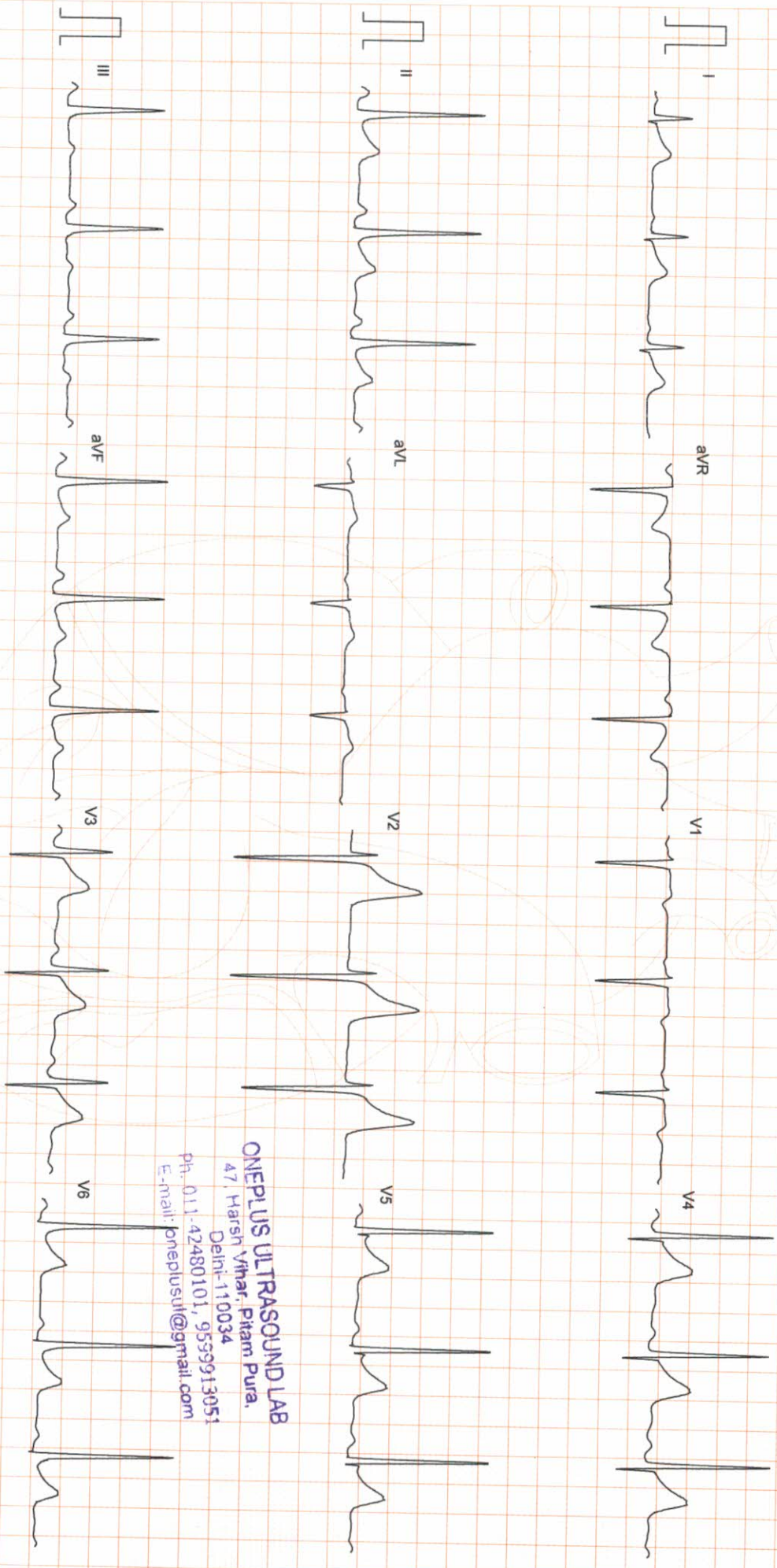
RECORDED : 11-1-2022 10:19

RATE : 73 BPM
B.P. : 136/86 mmHg

SUPINE
PRETEST

ST @ 10mm/mV
80ms PostJ

RAW E.C.G.



ONEPLUS ULTRASOUND LAB
47, Harsh Vihar, Pitam Pura,
Delhi-110034
Ph. 011-42480101, 9559913051
E-mail: oneplusul@gmail.com

Filtered

25mm/sec 10mm/mV

ARTW

CardiCom, INDIA Ph.:091-731-2620740, TeleFax:091-731-2431214

ONEPLUS ULTRASOUND LAB

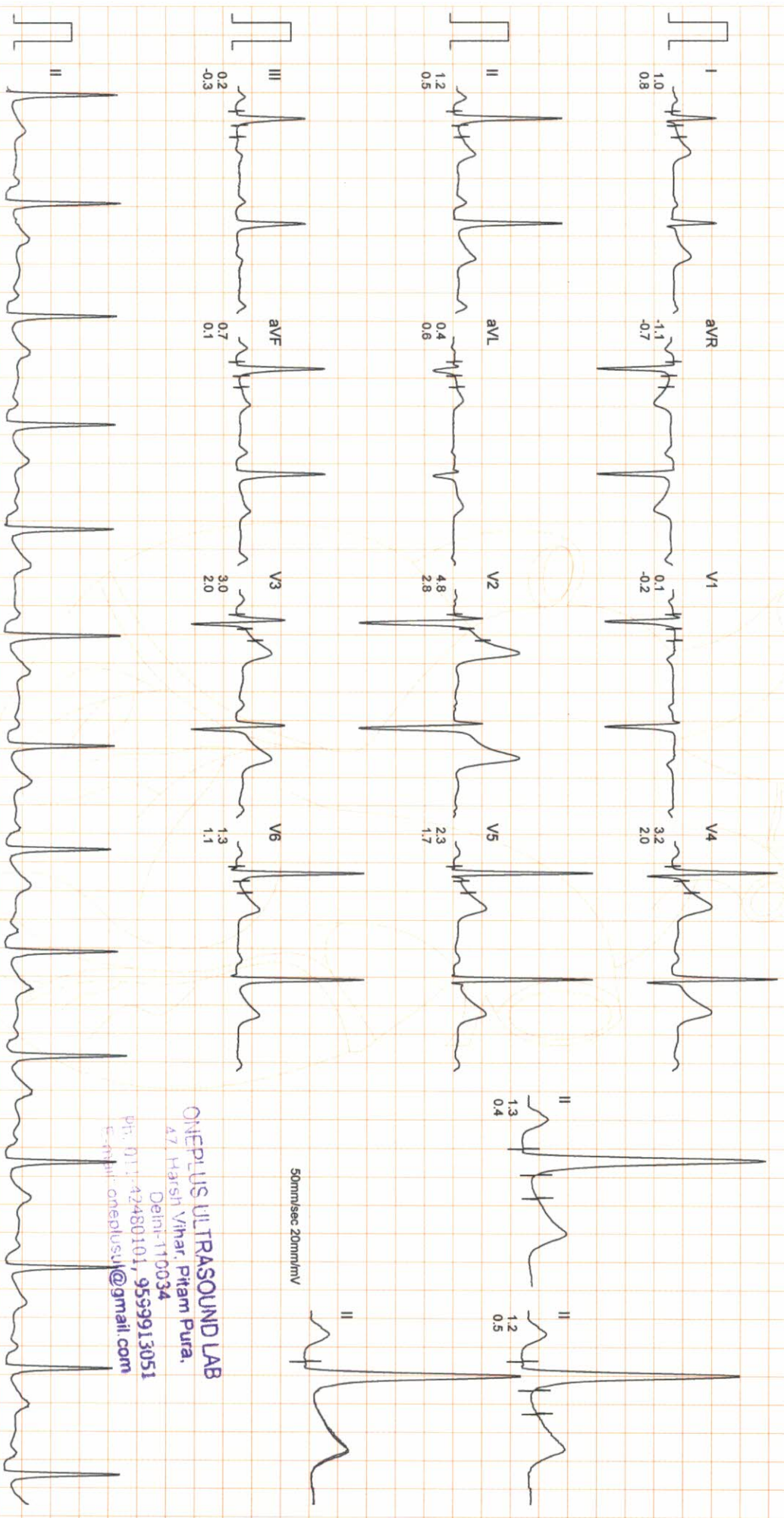
Mr. PRITAM SOLANKI
 I.D. : 990
 AGE/SEX : 30/M
 RECORDED : 11-1-2022 10:19

RATE : 81 BPM
 B.P. : 136/86 mmHg

BRUCE
 EXERCISE 1
 PHASE TIME : 2:59
 STAGE TIME : 2:59

ST @ 10mm/mV
 80ms PostJ
 SPEED : 2.7 Km./Hr.
 GRADE : 10.0 %

LINKED MEDIAN



50mm/sec 20mm/mV

ONEPLUS ULTRASOUND LAB
 A7 Harsh Vihar, Pitam Pura,
 Delhi-110034
 Ph: 011-42480101, 9599913051
 E-mail: onepusul@gmail.com

ONEPLUS ULTRASOUND LAB

Mr. PRITAM SOLANKI

I.D. : 990

AGE/SEX : 30/M

RECORDED : 11-1-2022 10:19

RATE : 100 BPM
B.P. : 146/88 mmHg

BRUCE

EXERCISE 2

PHASE TIME : 5:59

STAGE TIME : 2:59

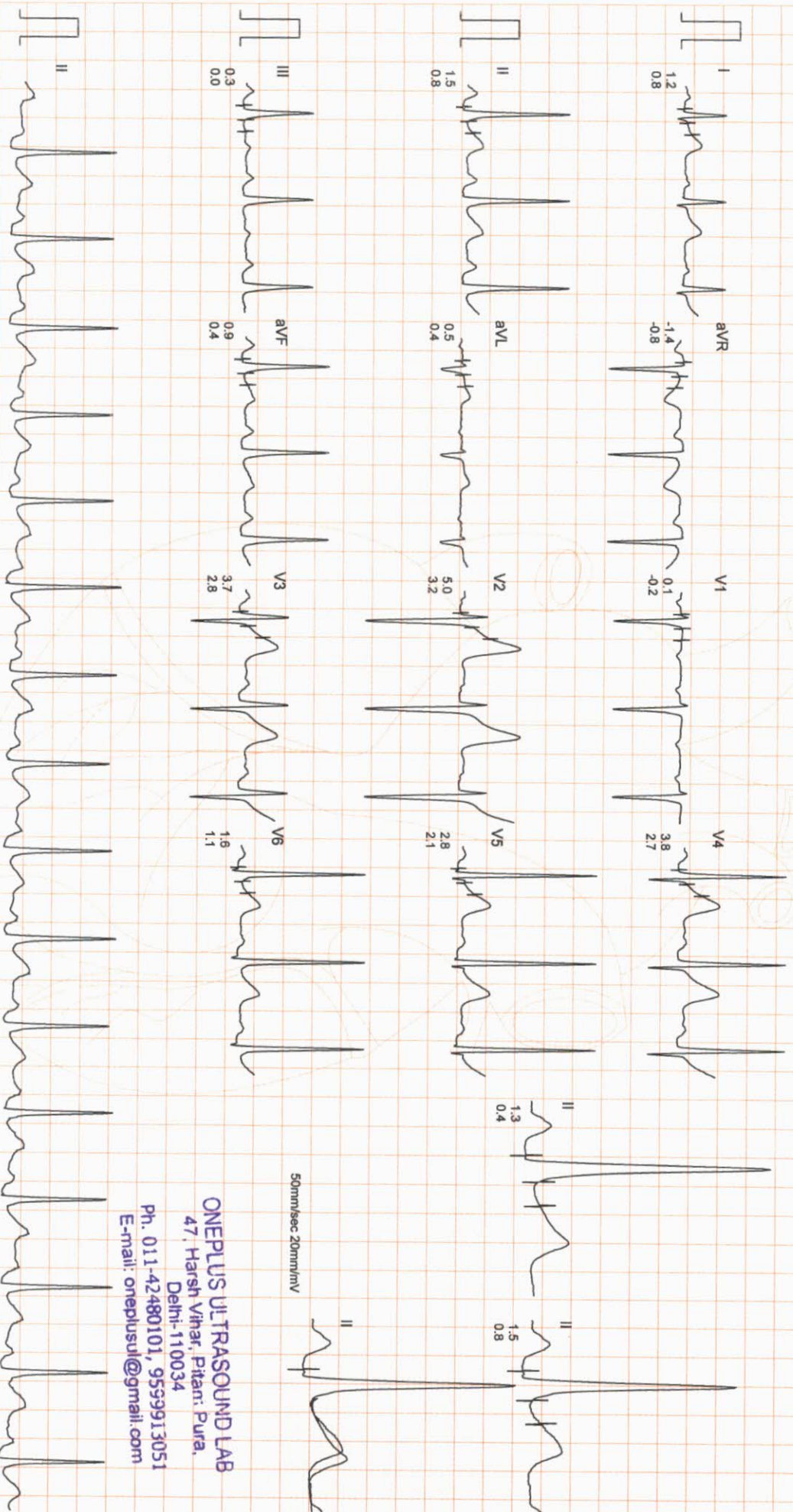
ST @ 10mm/mV

80ms PostJ

SPEED : 4.0 Km./Hr.

GRADE : 12.0 %

LINKED MEDIAN



50mm/sec 20mm/mV

ONEPLUS ULTRASOUND LAB
47, Harsh Vihar, Pitara, Pura,
Delhi-110034
Ph. 011-42480101, 9559913051
E-mail: oneplusul@gmail.com

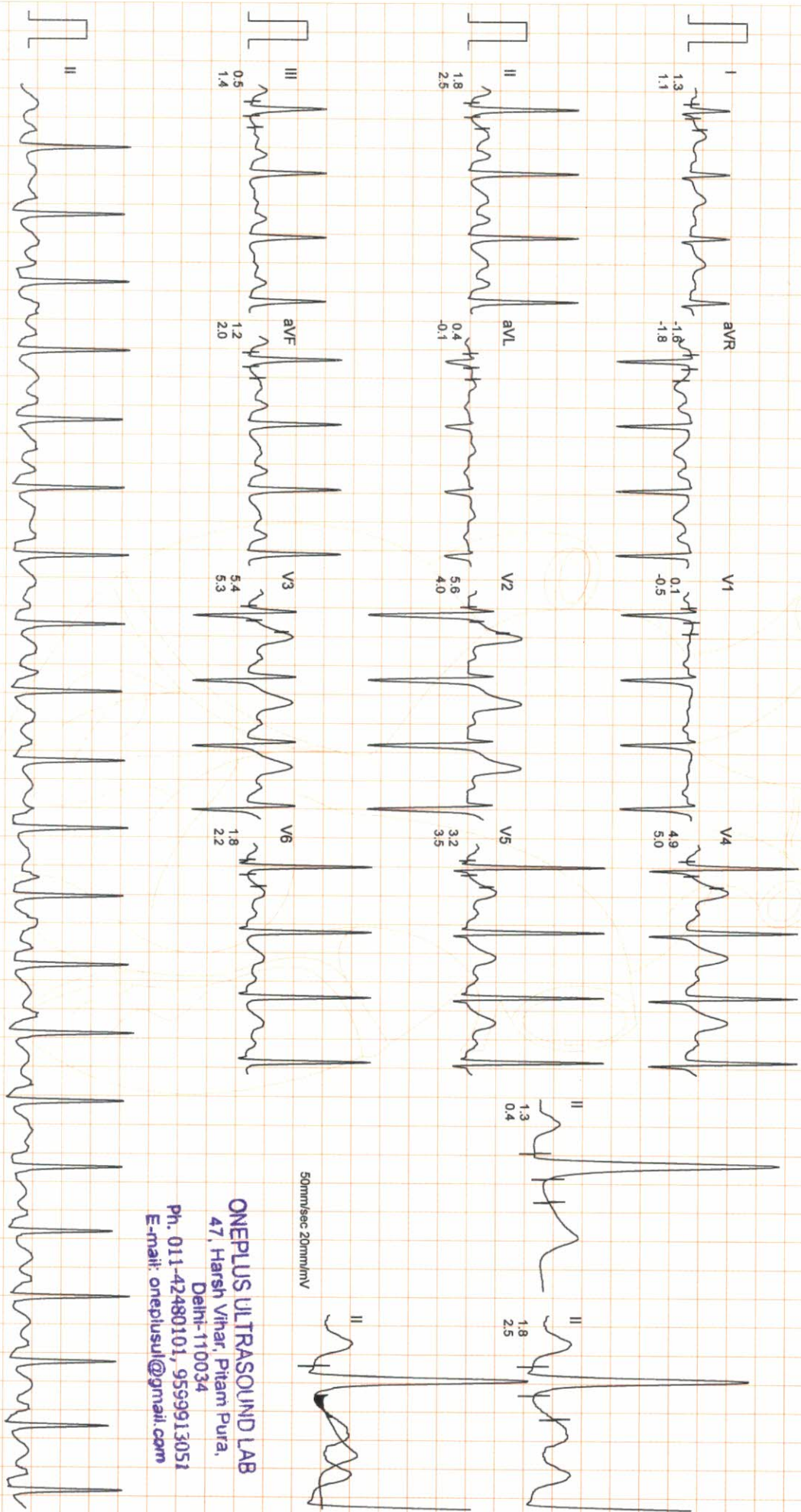
ONEPLUS ULTRASOUND LAB

Mr. PRITAM SOLANKI
I.D. : 990
AGE/SEX : 30/M
RECORDED : 11-1-2022 10:19

BRUCE
EXERCISE 3
PHASE TIME : 8:59
STAGE TIME : 2:59

ST @ 10mm/mV
80ms PostJ
SPEED : 5.4 Km./HR.
GRADE : 14.0 %

LINKED MEDIAN



ONEPLUS ULTRASOUND LAB
47, Hareh Vihar, Pitam Pura,
Delhi-110034
Ph. 011-42480101, 9559913051
E-mail: oneplusul@gmail.com

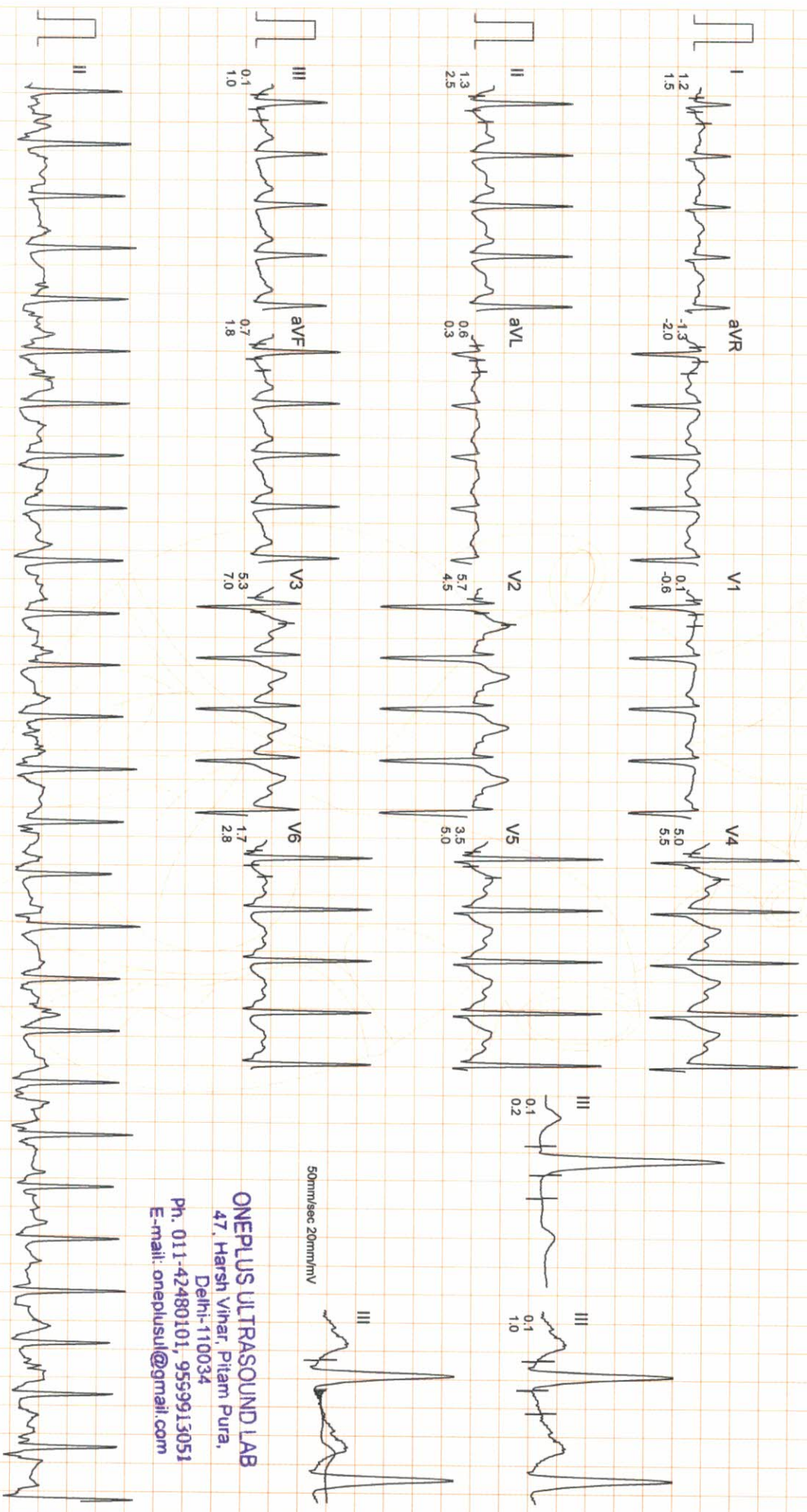
ONEPLUS ULTRASOUND LAB

Mr. PRITAM SOLANKI
I.D. : 990
AGE/SEX : 30/M
RECORDED : 11-1-2022 10:19

BRUCE
EXERCISE 4
PHASE TIME : 10:14
STAGE TIME : 1:14

ST @ 10mm/mV
80ms PostJ
SPEED : 6.7 Km./Hr.
GRADE : 16.0 %

LINKED MEDIAN



ONEPLUS ULTRASOUND LAB
47, Harsh Vihar, Pitam Pura,
Delhi-110034
Ph. 011-42480101, 9559913051
E-mail: oneplusul@gmail.com

ONEPLUS ULTRASOUND LAB

Mr. PRITAM SOLANKI

I.D. : 990

AGE/SEX : 30/M

RECORDED : 11-1-2022 10:19

RATE : 168 BPM

B.P. : 170/92 mmHg

BRUCE

PEAK EXER

PHASE TIME : 10:22

STAGE TIME : 1:22

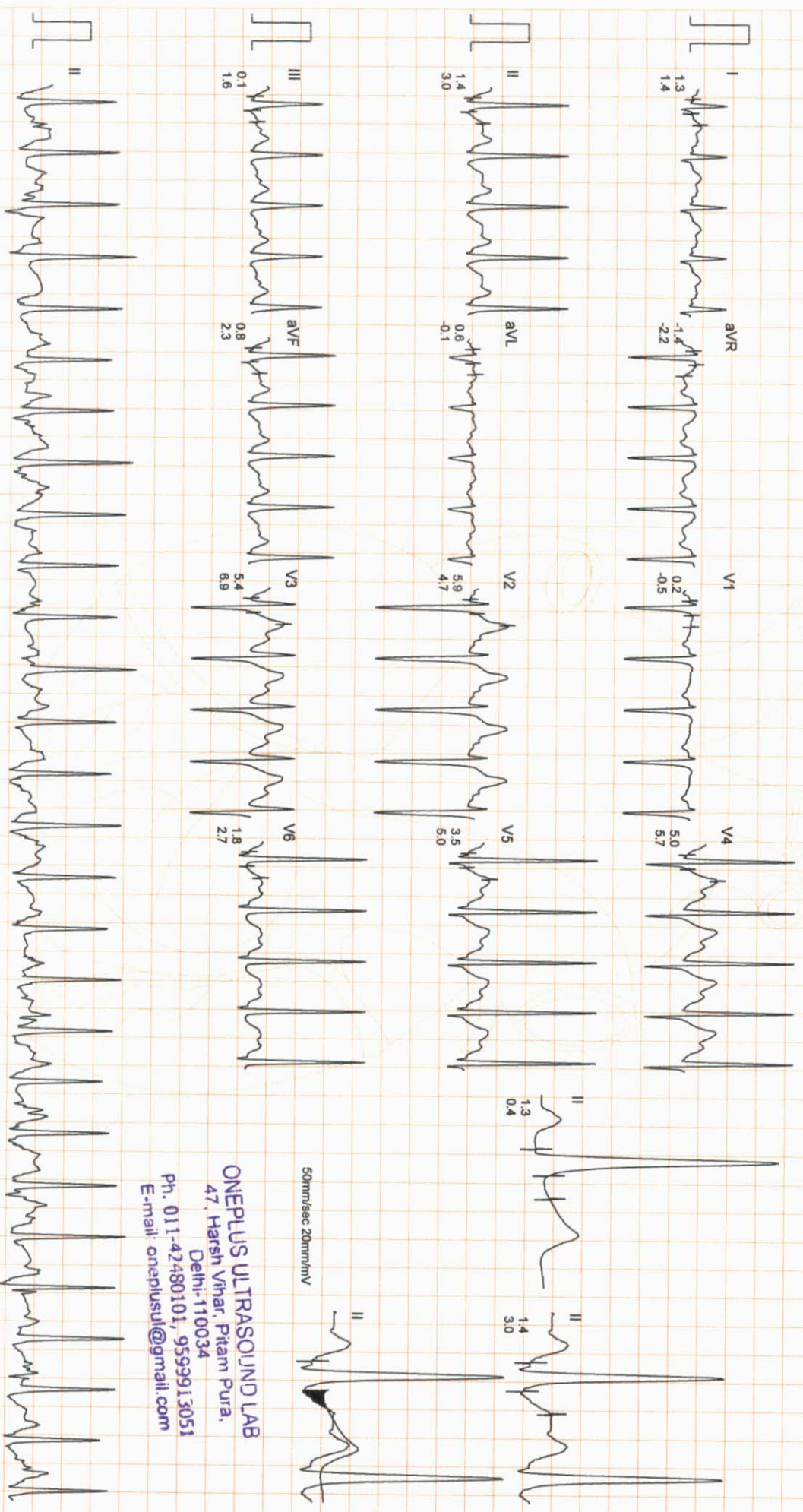
ST @ 10mm/mV

80ms PostJ

SPEED : 6.7 Km./Hr.

GRADE : 16.0 %

LINKED MEDIAN



50mm/sec 20mm/mV

ONEPLUS ULTRASOUND LAB
 47, Harsh Vihar, Pitam Pura,
 Delhi-110034
 Ph. 011-42480101, 9599913051
 E-mail: oneplusul@gmail.com

ONEPLUS ULTRASOUND LAB

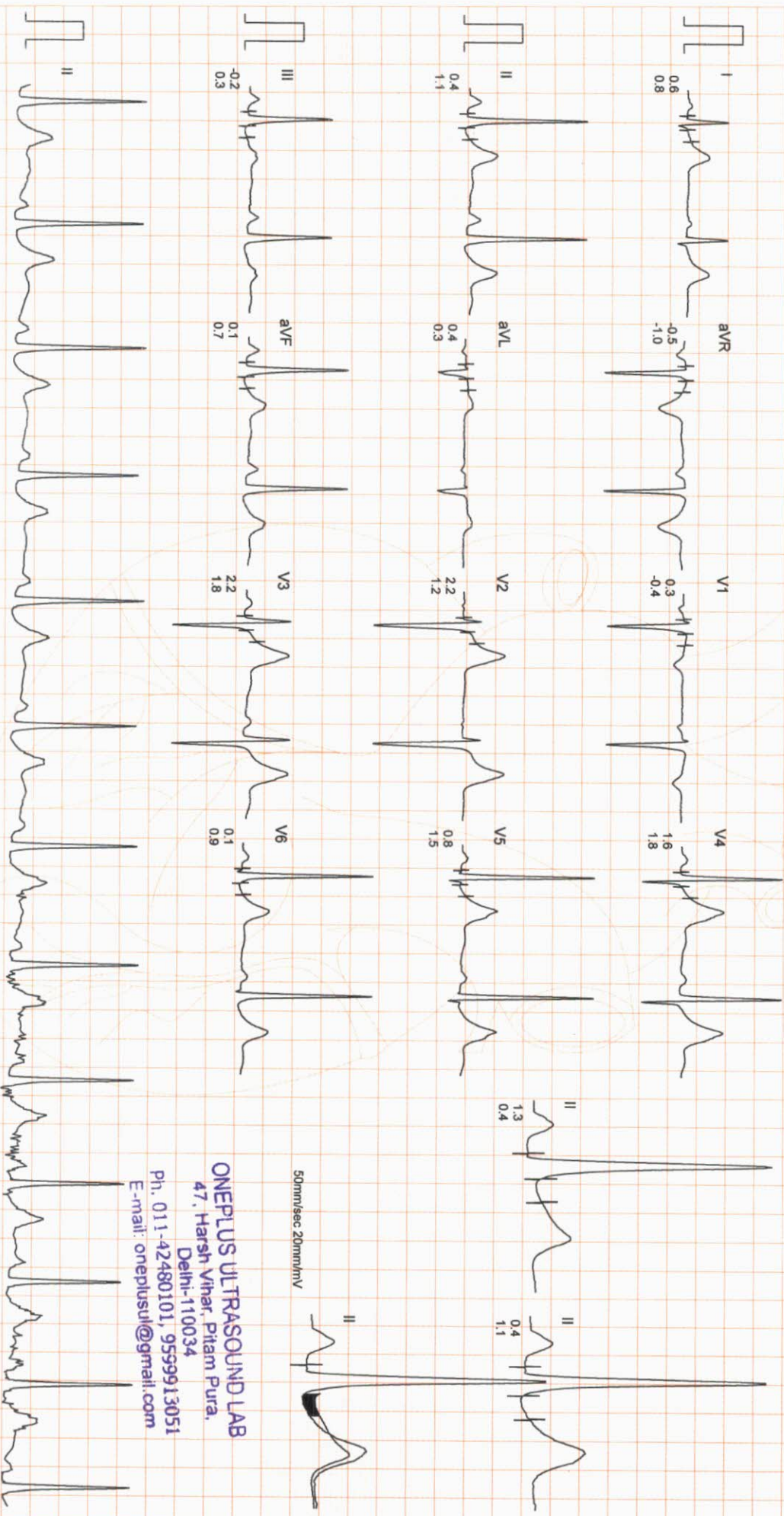
Mr. PRITAM SOLANKI
 I.D. : 990
 AGE/SEX : 30/M
 RECORDED : 11-1-2022 10:19

RATE : 76 BPM
 B.P. : 136/86 mmHg

BRUCE
 RECOVERY
 PHASE TIME : 2:59

ST @ 10mm/mV
 80ms PostJ
 SPEED : 0.0 Km./Hr.
 GRADE : 0.0 %

LINKED MEDIAN



50mm/sec 20mm/mV

ONEPLUS ULTRASOUND LAB
 47, Harsh Vihar, Pitam Pura,
 Delhi-110034
 Ph. 011-42480101, 9599913051
 E-mail: oneplusul@gmail.com

Filtered Computer Corrected Baseline

25mm/sec 10mm/mV

AIUM

CardiCom, INDIA Ph.:091-731-2620740, TeleFax:091-731-2431214

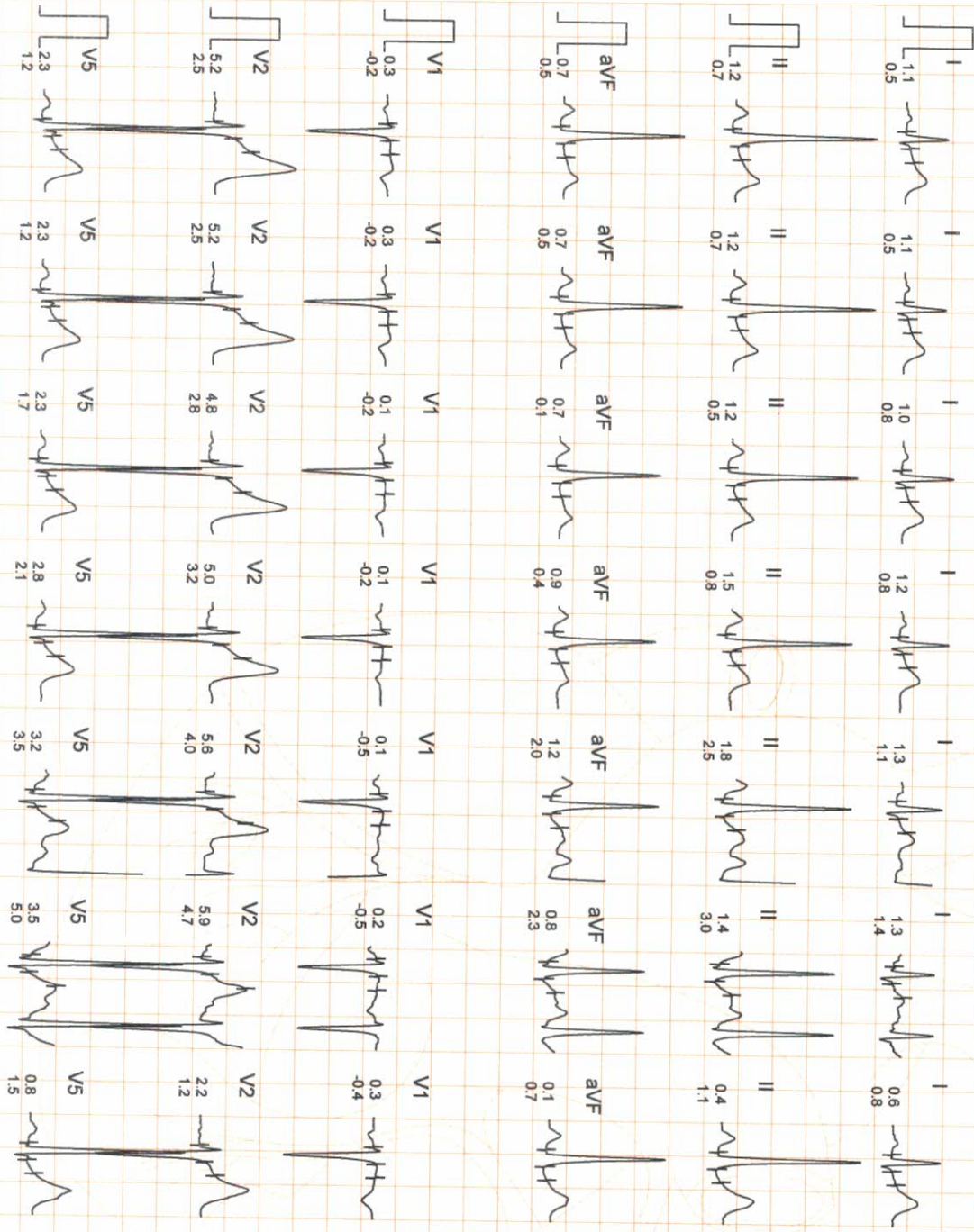
ONEPLUS ULTRASOUND LAB

AGE/SEX : 30/M

RECORDED : 11-1-2022 10:19

AVG E.C.G.

STANDING	SUPINE	STAGE 1	STAGE 2	STAGE 3	PEAK EXERCISE	RECOVERY
0.0Kmph 0.0% 72 bpm B.P. -136/86 80ms PostJ	0.0Kmph 0.0% 73 bpm B.P. -136/86 80ms PostJ	2:59 2:59 2.7Kmph 10.0% 81 bpm B.P. -136/86 80ms PostJ	5:59 2:59 4.0Kmph 12.0% 100 bpm B.P. -146/88 80ms PostJ	8:59 2:59 5.4Kmph 14.0% 130 bpm B.P. -158/90 80ms PostJ	10:22 1:22 6.7Kmph 16.0% 168 bpm B.P. -170/92 80ms PostJ	2:59 0.0Kmph 0.0% 76 bpm B.P. -136/86 80ms PostJ







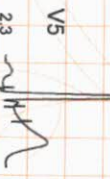




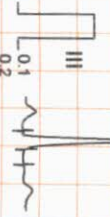
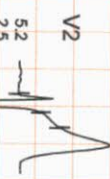

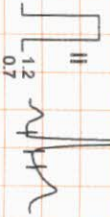

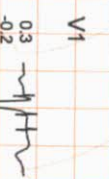


ONEPLUS ULTRASOUND LAB
 47, Harsh Vihar, Pitam Pura,
 Delhi-110034
 Ph. 011-42480101, 9599915051
 E-mail: oneplusul@gmail.com

SUPINE
0.0Kmph
0.0%
73 bpm
B.P. 138/86
80ms PostJ

PEAK EXERCISE
10:22
1.22
6.7Kmph
16.0%
168 bpm
B.P. 170/92
80ms PostJ

SUPINE
0.0Kmph
0.0%
73 bpm
B.P. 138/86
80ms PostJ

PEAK EXERCISE
10:22
1.22
6.7Kmph
16.0%
168 bpm
B.P. 170/92
80ms PostJ



ONEPLUS ULTRASOUND LAB
47, Harsh Vihar, Pitam Pura,
Delhi-110034
Ph. 011-42480101, 9599913051
E-mail: oneplusul@gmail.com



OnePLUS Ultrasound Lab

— QUALITY FIRST... ALWAYS! —

Dr. Nitin Agarwal
Pathologist & Director
Ex. Sr. Res. MAMC
& Lok Nayak Hospital
Ex. Chief of Lab Dr. Lal Path Labs.

Dr. Pooja (Garg) Agarwal
Radiologist & Director
MAMC & Lok Nayak Hospital



NAME	:Mr. PRITAM SOLANKI	Barcode No	:10111670
AGE/GENDER	:30 YRS/Male	SPECIMEN DATE	:11/Jan/2022 09:49AM
PATIENT ID	:89825	SPECIMEN RECEIVED	:11/Jan/2022 10:39AM
REFERRED BY	:Dr. MEDIWHEEL	REPORT DATE	:11/Jan/2022 01:57PM
CENTRE NAME	:ONEPLUS ULTRASOUND LAB	LAB NO.	:012201110007

Test Name	Result	Unit	Ref. Range
HAEMATOLOGY			
Health checkup 2 Male			
<u>Glycosylated Hemoglobin (HbA1c)</u>	5.1	%	Non Diabetic adults <5.7 Prediabetic (at risk) 5.7-6.4 Diabetes >6.4

Estimated average blood glucose (eag) 100
Reference range (mg/dl):

90 - 120:Excellent control, 121 - 150:Good Control, 151 - 180:Average Control, 181 - 210:Action Suggested
>211:Panic value

Checked By.

DR. NITIN AGARWAL
MBBS,MD(PATHOLOGIST)

47, Harsh Vihar, Pitampura, New Delhi-110034 | Ph: 011-42480101, 9599913051
E-mail: oneplusul@gmail.com | Web.: www.oneplusul.in
Dr. NITIN AGARWAL
MBBS, MD (Path)
DMC/R/01436



OnePLUS Ultrasound Lab

— QUALITY FIRST... ALWAYS! —

Dr. Nitin Agarwal

Pathologist & Director
Ex. Sr. Res. MAMC
& Lok Nayak Hospital
Ex. Chief of Lab Dr. Lal Path Labs.

Dr. Pooja (Garg) Agarwal

Radiologist & Director
MAMC & Lok Nayak Hospital



NAME	:Mr. PRITAM SOLANKI	Barcode No	:10111670
AGE/GENDER	:30 YRS/Male	SPECIMEN DATE	:11/Jan/2022 09:49AM
PATIENT ID	:89825	SPECIMEN RECEIVED	:11/Jan/2022 10:39AM
REFERRED BY	:Dr. MEDIWHEEL	REPORT DATE	:11/Jan/2022 01:03PM
CENTRE NAME	:ONEPLUS ULTRASOUND LAB	LAB NO.	:012201110007

Test Name	Result	Unit	Ref. Range
-----------	--------	------	------------

HAEMATOLOGY

BLOOD GROUP (ABO)	B
Rh typing	POSITIVE

NOTE :

- * Apart from major A,B,H antigens which are used for ABO grouping and Rh typing, many minor blood group antigens exist. Agglutination may also vary according to titre of antigen and antibody.
- * So before transfusion, reconfirmation of blood group as well as cross-matching is needed.
- * Presence of maternal antibodies in newborns, may interfere with blood grouping.
- * Auto agglutination (due to cold antibody, falciparum malaria, sepsis, internal malignancy etc.) may also cause erroneous result.

CBC

Haemoglobin	13.6	g/dl	13.0-17.0
Total Leucocyte Count	5190	/cumm	4000-10000
<u>Differential leucocyte count</u>			
Neutrophils	60.9	%	40-80
Lymphocyte	31.10	%	20-40
Monocytes	4.00	%	2-10
Eosinophils	3.7	%	1-6
Basophils	0.3	%	0-2
RBC Count	4.60	million/cumm	4.5 - 5.5
PCV(Hematocrit)	42.8	%	40-50
MCV	93.1	fL	83-101
MCH	29.5	Pg	27-32
MCHC	32.0	G/dL	32-35
Platelet count	176000	/cumm	150000-450000
RDW-CV	13	%	11.4-14.0
ESR(WESTEGRENS METHOD)	12	mm in 1st hr	0-20

BIOCHEMISTRY

Checked By.

Dr. NITIN AGARWAL
M B B S , MD (Path)
DMC/R/01436

DR. NITIN AGARWAL
MBBS,MD(PATHOLOGIST)

47, Harsh Vihar, Pitampura, New Delhi-110034 | Ph.: 011-42480101, 9599913051
E-mail: oneplusul@gmail.com | Web.: www.oneplusul.in

Page 2 of 9



OnePLUS Ultrasound Lab

— QUALITY FIRST... ALWAYS! —

Dr. Nitin Agarwal
Pathologist & Director
Ex. Sr. Res. MAMC
& Lok Nayak Hospital
Ex. Chief of Lab Dr. Lal Path Labs.


Dr. Pooja (Garg) Agarwal
Radiologist & Director
MAMC & Lok Nayak Hospital



NAME	:Mr. PRITAM SOLANKI	Barcode No	:10111670
AGE/GENDER	:30 YRS/Male	SPECIMEN DATE	:11/Jan/2022 09:49AM
PATIENT ID	:89825	SPECIMEN RECEIVED	:11/Jan/2022 10:39AM
REFERRED BY	:Dr. MEDIWHEEL	REPORT DATE	:11/Jan/2022 01:03PM
CENTRE NAME	:ONEPLUS ULTRASOUND LAB	LAB NO.	:012201110007

Test Name	Result	Unit	Ref. Range
<u>Blood sugar fasting</u>	90	mg/dL	70-110

Checked By.


Dr NITIN AGARWAL
MBBS, MD (Path)
DMC/R/01436
NITIN AGARWAL
MBBS, MD (PATHOLOGIST)

47, Harsh Vihar, Pitampura, New Delhi-110034 | Ph.: 011-42480101, 9599913051
E-mail: oneplusul@gmail.com | Web.: www.oneplusul.in

Page 3 of 9



OnePLUS Ultrasound Lab

— QUALITY FIRST... ALWAYS! —

Dr. Nitin Agarwal
Pathologist & Director
Ex. Sr. Res. MAMC
& Lok Nayak Hospital
Ex. Chief of Lab Dr. Lal Path Labs.

Dr. Pooja (Garg) Agarwal
Radiologist & Director
MAMC & Lok Nayak Hospital




NAME	:Mr. PRITAM SOLANKI	Barcode No	:10111670
AGE/GENDER	:30 YRS/Male	SPECIMEN DATE	:11/Jan/2022 09:49AM
PATIENT ID	:89825	SPECIMEN RECEIVED	:11/Jan/2022 05:03PM
REFERRED BY	:Dr. MEDIWHEEL	REPORT DATE	:11/Jan/2022 05:29PM
CENTRE NAME	:ONEPLUS ULTRASOUND LAB	LAB NO.	:012201110007

Test Name	Result	Unit	Ref. Range
-----------	--------	------	------------

BIOCHEMISTRY

<u>Blood sugar pp</u>	103	mg/dL	70.0-140.0
-----------------------	-----	-------	------------

Checked By.


DR. NITIN AGARWAL
MBBS, MD (PATHOLOGIST)
DMS/R/01436

47, Harsh Vihar, Pitampura, New Delhi-110034 | Ph.: 011-42480101, 9599913051
E-mail: oneplusul@gmail.com | Web.: www.oneplusul.in

Page 4 of 9

Clinical correlation is essential for final diagnosis. • If test results are unsatisfactory please contact personally or on phone. • This report is for perusal of doctors only.
• All disputes Subject to Delhi Jurisdiction only. • Not for medicolegal purposes. • All congenital anomalies in a foetus may not be diagnosed in routine obstetric ultrasound.



OnePLUS

Ultrasound Lab

— QUALITY FIRST... ALWAYS! —

Dr. Nitin Agarwal
Pathologist & Director
Ex. Sr. Res. MAMC
& Lok Nayak Hospital
Ex. Chief of Lab Dr. Lal Path Labs.

Dr. Pooja (Garg) Agarwal
Radiologist & Director
MAMC & Lok Nayak Hospital



NAME	:Mr. PRITAM SOLANKI	Barcode No	:10111670
AGE/GENDER	:30 YRS/Male	SPECIMEN DATE	:11/Jan/2022 09:49AM
PATIENT ID	:89825	SPECIMEN RECEIVED	:11/Jan/2022 10:39AM
REFERRED BY	:Dr. MEDIWHEEL	REPORT DATE	:11/Jan/2022 01:03PM
CENTRE NAME	:ONEPLUS ULTRASOUND LAB	LAB NO.	:012201110007

Test Name	Result	Unit	Ref. Range
-----------	--------	------	------------

BIOCHEMISTRY

Bun (blood urea nitrogen)	12.60	mg/dl	8.9-21.6
Uric acid, serum	4.6	mg/dl	3.4-7.0
Creatinine, serum	0.78	mg/dl	0.60-1.1

LFT(LIVER FUNCTION TEST)

Bilirubin Total	0.65	mg/dl	0.1-1.2
Bilirubin Conjugated	0.32	mg/dl	0-0.4
Bilirubin Unconjugated	0.33	mg/dl	up to 0.7
SGOT (AST)	32	U/L	0-35
SGPT (ALT)	38	U/L	<45.0
Alkaline phosphatase	96	U/L	40-129
Gamma glutamyl transpeptidase	26	U/L	<66
Total Protein	6.8	gm/dl	6.60 - 8.70
Albumin	3.8	g/dL	3.8-5.1
Globulin	3.00	gm/dl	1.8-3.4
Albumin/Globulin Ratio	1.27		1.10 - 2.50

LIPID PROFILE

Cholesterol	281	mg/dl	50-200
Triglycerides	79	mg/dL	25-150
HDL Cholesterol	45	mg/dL	30-70
LDL cholesterol	220	mg/dL	<130
VLDL cholesterol	15.8	mg/dL	5-40
Cholesterol/HDL Ratio	6.2		Low Risk 3.3-4.97 Average Risk 4.4-7.1 Moderate Risk 7.1-11.0 High Risk >11.0
LDL/HDL Ratio	4.9		0 - 3.55

According to ATP III and NCEP guidelines

Checked By.

DR. NITIN AGARWAL
MBBS, MD(PATHOLOGIST)

Dr NITIN AGARWAL
MBBS, MD (Path)
MAMC/8/01436

47, Harsh Vihar, Pitampura, New Delhi-110034 | Ph.: 011-42480101, 9599913051

E-mail: oneplusul@gmail.com | Web.: www.oneplusul.in

Page 5 of 9

Clinical correlation is essential for final diagnosis. • If test results are unsatisfactory please contact personally or on phone. • This report is for perusal of doctors only. • All disputes Subject to Delhi Jurisdiction only. • Not for medicolegal purposes. • All congenital anomalies in a foetus may not be diagnosed in routine obstetric ultrasound.



OnePLUS

Ultrasound Lab

— QUALITY FIRST... ALWAYS! —

Dr. Nitin Agarwal

Pathologist & Director
Ex. Sr. Res. MAMC
& Lok Nayak Hospital
Ex. Chief of Lab Dr. Lal Path Labs.

Dr. Pooja (Garg) Agarwal

Radiologist & Director
MAMC & Lok Nayak Hospital



NAME	:Mr. PRITAM SOLANKI	Barcode No	:10111670
AGE/GENDER	:30 YRS/Male	SPECIMEN DATE	:11/Jan/2022 09:49AM
PATIENT ID	:89825	SPECIMEN RECEIVED	:11/Jan/2022 10:39AM
REFERRED BY	:Dr. MEDIWHEEL	REPORT DATE	:11/Jan/2022 01:03PM
CENTRE NAME	:ONEPLUS ULTRASOUND LAB	LAB NO.	:012201110007

Test Name	Result			Unit	Ref. Range
Parameter	Normal	Desirable	Borderline		High
Total cholesterol	<200	200-239			240
Triglycerides	<150	150-199	200-499		500
LDL	Optimal <100 Near Optimal 100-129	130-159	160-180		190
HDL	<40 : LOW 60 : HIGH				

Checked By.

DR. NITIN AGARWAL
MBBS,MD(PATHOLOGIST)

47, Harsh Vihar, Pitampura, New Delhi-110034 | Ph.: 011-42480101, 9599913051
E-mail: oneplusul@gmail.com | Web.: www.oneplusul.in

DR. NITIN AGARWAL
MBBS, MD (Path)
MAMC/R/01453

Page 6 of 9



OnePLUS
Ultrasound Lab

QUALITY FIRST... ALWAYS!

Dr. Nitin Agarwal
Pathologist & Director
Ex. Sr. Res. MAMC
& Lok Nayak Hospital
Ex. Chief of Lab Dr. Lal Path Labs.

Dr. Pooja (Garg) Agarwal
Radiologist & Director
MAMC & Lok Nayak Hospital



NAME	:Mr. PRITAM SOLANKI	Barcode No	:10111670
AGE/GENDER	:30 YRS/Male	SPECIMEN DATE	:11/Jan/2022 09:49AM
PATIENT ID	:89825	SPECIMEN RECEIVED	:11/Jan/2022 10:39AM
REFERRED BY	:Dr. MEDIWHEEL	REPORT DATE	:11/Jan/2022 02:09PM
CENTRE NAME	:ONEPLUS ULTRASOUND LAB	LAB NO.	:012201110007

Test Name	Result	Unit	Ref. Range
-----------	--------	------	------------

ENDOCRINOLOGY

PSA TOTAL

Prostatic specific antigen, Total 0.71 ng/ml <4.0

< 40 years	0.21 to 1.72 ng/ml
40 - 49	0.27 to 2.19 ng/ml
50 - 59	0.27 to 3.42 ng/ml
60 - 69	0.22 to 6.16 ng/ml
> 69	0.21 to 6.77 ng/ml

Notes:

PSA is principally produced by the glandular epithelium of the prostate, and is secreted in the seminal fluid. PSA is also present in urine and blood. PSA acts on seminal fluid to fluidify and increase sperm mobility. PSA levels rise in prostatic pathologies such as benign prostatic hyperplasia (BPH) or prostate cancer.

THYROID PROFILE(T3,T4,TSH)

Triiodothyronine total [t3]	0.78	ng/dl	0.52-1.9
Thyroxine total [t4]	8.60	µg/dl	4.4 - 10.8
TSH (Thyroid Stimulating Hormone)	3.00	µIU/ml	0.25-5.0

AGE WISE VARIATION IN TSH

AGE	TSH(µIU/ml)	AGE	TSH(µIU/ml)
1-4 weeks	1.00 - 19.0	16-20 yrs	0.25 - 5.0
1-12 mths	1.70 - 9.1	21 - 80 yrs	0.25 - 5.0
1-5 yrs	0.80 - 8.2	I st trimester	0.25 - 5.0
6-10 yrs	0.25 - 5.0	II nd trimester	0.50 - 5.0
11-15 yrs	0.25 - 5.0	II rd trimester	0.4 - 6.0

Reference ranges - Interpretation of Diagnostic tests - (Jacques Wallach)

1. Primary hypothyroidism is accompanied by depressed serum T3 and T4 values and elevated serum TSH level.

Checked By.

DR. NITIN AGARWAL
MBBS,MD(PATHOLOGIST)

47, Harsh Vihar, Pitampura, New Delhi-110034 | Ph.: 011-42480101, 9599913051
E-mail: oneplusul@gmail.com | Web.: www.oneplusul.in

Page 7 of 9

Clinical correlation is essential for final diagnosis. • If test results are unsatisfactory please contact personally or on phone. • This report is for perusal of doctors only. • All disputes Subject to Delhi Jurisdiction only. • Not for medicolegal purposes. • All congenital anomalies in a foetus may not be diagnosed in routine obstetric ultrasound.



OnePLUS Ultrasound Lab

QUALITY FIRST... ALWAYS!

Dr. Nitin Agarwal
Pathologist & Director
Ex. Sr. Res. MAMC
& Lok Nayak Hospital
Ex. Chief of Lab Dr. Lal Path Labs.

Dr. Pooja (Garg) Agarwal
Radiologist & Director
MAMC & Lok Nayak Hospital



NAME	:Mr. PRITAM SOLANKI	Barcode No	:10111670
AGE/GENDER	:30 YRS/Male	SPECIMEN DATE	:11/Jan/2022 09:49AM
PATIENT ID	:89825	SPECIMEN RECEIVED	:11/Jan/2022 10:39AM
REFERRED BY	:Dr. MEDIWHEEL	REPORT DATE	:11/Jan/2022 02:09PM
CENTRE NAME	:ONEPLUS ULTRASOUND LAB	LAB NO.	:012201110007

Test Name	Result	Unit	Ref. Range
2. Primary hyperthyroidism is accompanied by elevated serum T3 and T4 levels along with depressed TSH values.			
3. Slightly elevated T3 levels may be found in pregnancy and estrogen therapy, while depressed levels may be encountered in severe illness, renal failure and during therapy with drugs like propranolol and propyl thiouracil.			
4. Although elevated TSH levels are nearly always indicative of primary hypothyroidism, and may be seen in secondary thyrotoxicosis			

CLINICAL PATHOLOGY

URINE ROUTINE

Physical examination

Quantity	20		ML
Colour	PALE YELLOW		
Transparency	CLEAR		CLEAR
Sp.gravity	1.015		1.010-1.030
pH	6.00		
Reaction	ACIDIC		ACIDIC

Chemical examination

Urine protein	NIL		NIL
Urine sugar	NIL		NIL
Bilirubin, urine	NEGATIVE		NEGATIVE
Urobilinogen	NORMAL		NORMAL
Ketones	NEGATIVE		NEGATIVE

Microscopic examination

Pus cells.	1-2	/HPF	0-2
Epithelial cells	0-1	/HPF	NIL
R.B.C.	NIL	/HPF	NIL
Casts	NIL	/HPF	NIL
Crystals	NIL	/HPF	NIL
Bacteria	NIL	/HPF	NIL
Others.	NIL	NIL	NIL

*** End Of Report ***

Checked By.

DR. NITIN AGARWAL
MBBS,MD(PATHOLOGIST)

47, Harsh Vihar, Pitampura, New Delhi-110034 | Ph.: 011-42480101, 9599913051
E-mail: oneplusul@gmail.com | Web.: www.oneplusul.in

Page 8 of 9

Clinical correlation is essential for final diagnosis. • If test results are unsatisfactory please contact personally or on phone. • This report is for perusal of doctors only.
• All disputes Subject to Delhi Jurisdiction only. • Not for medicolegal purposes. • All congenital anomalies in a foetus may not be diagnosed in routine obstetric ultrasound.