

NAME : MRS: NIRANCHANA	AGE:40/F	DATE: 24/02/2024
------------------------	----------	------------------

CHEST X-RAY REPORT

CHEST X-RAY PA VIEW : Trachea central  
No cardiomegaly  
Normal vascularity  
No parenchymal lesion.  
Costophrenic and cardiophrenic angles clear

➤ **IMPRESSION** : Normal Chest Xray

ELECTRO CARDIOGRAM : NSR: 82/minute  
No evidence of ischaemia

➤ **IMPRESSION** : Normal Ecg.



*DR SERIN LOPEZ, MBBS*  
Reg No. 77656  
MEDICAL OFFICER  
DDRC AGILUS PATHLABS LTD.  
Aster Square, Medical College. P.O, TVM

Company name: MEDIWHEEL

**DR SERIN LOPEZ MBBS**  
Reg No 77656  
**DDRC AGILUS PATHLABS LTD**

If the examinee is suffering from an acute life threatening situation, you may be obliged to disclose the result of the medical examination to the examinee.

1. Name of the examinee	:	Mr./Mrs./Ms. <b>NIRANCHANA</b>
2. Mark of Identification	:	(Mole/Scar/any other (specify location)):
3. Age/Date of Birth	:	<b>40</b> Gender: <b>♀/M</b>
4. Photo ID Checked	:	(Passport/Election Card/PAN Card/Driving Licence/Company ID)

### PHYSICAL DETAILS:

a. Height .... <b>139</b> ..... (cms)	b. Weight .... <b>63</b> ..... (Kgs)	c. Girth of Abdomen .... <b>78</b> .... (cms)
d. Pulse Rate .... <b>72</b> .... (/Min)	e. Blood Pressure:	Systolic , Diastolic
	1 <sup>st</sup> Reading	<b>120</b> <b>76</b>
	2 <sup>nd</sup> Reading	

### FAMILY HISTORY:

Relation	Age if Living	Health Status	If deceased, age at the time and cause
Father			
Mother			
Brother(s)			
Sister(s)			

### HABITS & ADDICTIONS: Does the examinee consume any of the following?

Tobacco in any form	Sedative	Alcohol
<b>Nil</b>	<b>Nil</b>	<b>Nil</b>

### PERSONAL HISTORY

- |   |   |
|---|---|
| a. Are you presently in good health and entirely free from any mental or Physical impairment or deformity. If No, please attach details. <b>✓/N</b> | c. During the last 5 years have you been medically examined, received any advice or treatment or admitted to any hospital? <b>Y/N ✓</b> |
| b. Have you undergone/been advised any surgical procedure? <b>LSCS ✓/N</b>  | d. Have you lost or gained weight in past 12 months? <b>Y/N ✓</b>   |

### Have you ever suffered from any of the following?

- |  |   |
|--|---|
| • Psychological Disorders or any kind of disorders of the Nervous System? <b>Y/N ✓</b> | • Any disorder of Gastrointestinal System? <b>Y/N ✓</b>                               |
| • Any disorders of Respiratory system? <b>Y/N ✓</b>                                    | • Unexplained recurrent or persistent fever, and/or weight loss <b>Y/N ✓</b>          |
| • Any Cardiac or Circulatory Disorders? <b>Y/N ✓</b>                                   | • Have you been tested for HIV/HBsAg / HCV before? If yes attach reports <b>Y/N ✓</b> |
| • Enlarged glands or any form of Cancer/Tumour? <b>Y/N ✓</b>                           | • Are you presently taking medication of any kind? <b>Y/N ✓</b>                       |
| • Any Musculoskeletal disorder? <b>Y/N ✓</b>   |   |

• Any disorders of Urinary System?

Y/N ✓

• Any disorder of the Eyes, Ears, Nose, Throat or Mouth & Skin

Y/N ✓

**FOR FEMALE CANDIDATES ONLY**

a. Is there any history of diseases of breast/genital organs?

Y/N ✓

d. Do you have any history of miscarriage/ abortion or MTP

Y/N ✓

b. Is there any history of abnormal PAP Smear/Mammogram/USG of Pelvis or any other tests? (If yes attach reports)

Y/N ✓

e. For Parous Women, were there any complication during pregnancy such as gestational diabetes, hypertension etc

Y/N ✓

c. Do you suspect any disease of Uterus, Cervix or Ovaries?

Y/N ✓

f. Are you now pregnant? If yes, how many months?

Y/N ✓

**CONFIDENTIAL COMMENTS FROM MEDICAL EXAMINER**


- Was the examinee co-operative? Y/N ✓
- Is there anything about the examinee's health, lifestyle that might affect him/her in the near future with regard to his/her job? Y/N ✓
- Are there any points on which you suggest further information be obtained? Y/N ✓
- Based on your clinical impression, please provide your suggestions and recommendations below;

..... Patient is clinically well, Reports show elevated lipid & glycaemic profile  
..... which need to be evaluated .....

➤ Do you think he/she is MEDICALLY FIT or UNFIT for employment.

**MEDICAL EXAMINER'S DECLARATION**

I hereby confirm that I have examined the above individual after verification of his/her identity and the findings stated above are true and correct to the best of my knowledge.

Name & Signature of the Medical Examiner : Dr. Praveen S.L. 

Seal of Medical Examiner : Dr. PRAVEEN S.L  
MBBS  
Reg. No: 74089

Name & Seal of DDRC SRL Branch :

Date & Time :



**DDRC agilus Pathlabs Limited.**

Corp. Office : Express House, Second Floor, Opp. Pothys Silks, Banerjee Road, Kaloor -682017  
Contact :- 93334 93334, Web :- www.ddrcagilus.com Email :- info.ddrc@agilus.in

ID: 08685

Diagnosis Information:

Female  
40 Years  
cm / mmHg  
kg

*Altracharya*

HR : 82 bpm  
P : 105 ms  
PR : 149 ms  
QRS : 76 ms  
QT/QTc : 363/426 ms  
P/QRST : 65/65/36 °  
RV5/SVI : 0.432/0.503 mV

Report Confirmed by: *Altracharya*



V1

V2

V3

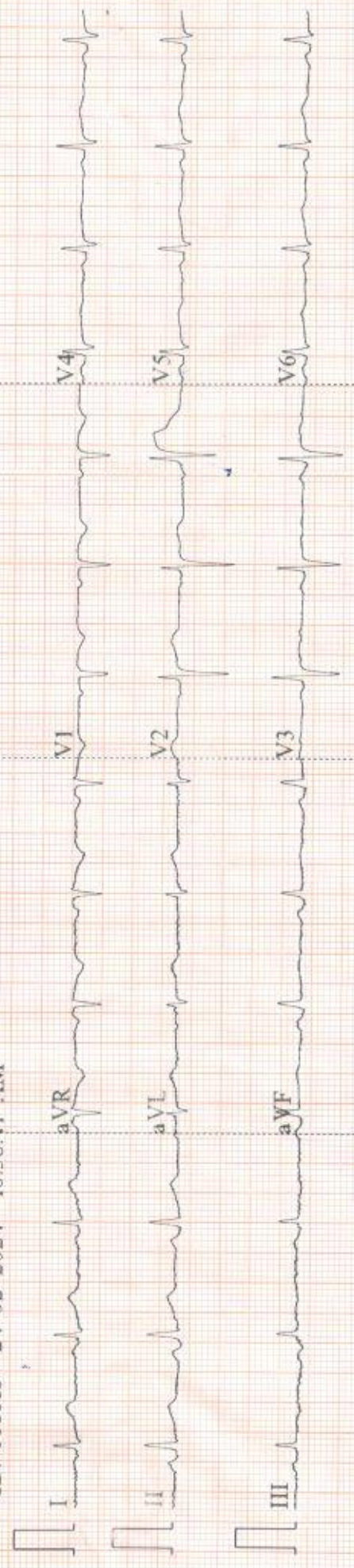
V4

V6

Standard

Standard	L I	L II	L III	L III Inspiration

ID: 008685 24-02-2024 10:58:41 AM



0.5-25Hz AC50 25mm/s 10mm/mV ♥86 V1.0 SEMIP V1.7 DDRC-AGILUS  
A...W CE

From

R. Niranchana,  
EC. NO: 75625,  
W/O. B. Ramesh,  
Bank of Baroda,  
Nagercoil.

To

DDRC Agilus,  
Trivandrum

Dear Sir/Madam,

We are not willing to take Eye checkups  
& Dental checkup outside.

Thanking You

Trivandrum  
24.02.2024.

Yours faithfully,

R. Niranchana



[RAMESH .B]

**ECHO REPORT**

**RADIOLOGY DIVISION**

SRD No :XB008685	Name:NIRANJANA	Age:40Y	Sex:F	Date: 24/02/24
------------------	----------------	---------	-------	----------------

**Left Ventricle:-**

	Diastole	Systole
IVS	1.16cm	1.22cm
LV	3.99cm	2.38cm
LVPW	1.09cm	1.16cm


EF -71%      FS- 40%

AO	LA
2.66cm	3.49cm

PV            - 0.93m/s  
AV            - 1.13m/s  
MVE          - 0.86m/s  
MVA          - 0.58m/s  
E/A           - 1.50

**IMPRESSION:-**

- Normal chambers dimension
- No RWMA
- Good LV systolic function
- No diastolic dysfunction
- No AS,AR,MR,MS,TR,PAH
- IAS/IVS intact.No clots/effussion/coarctation

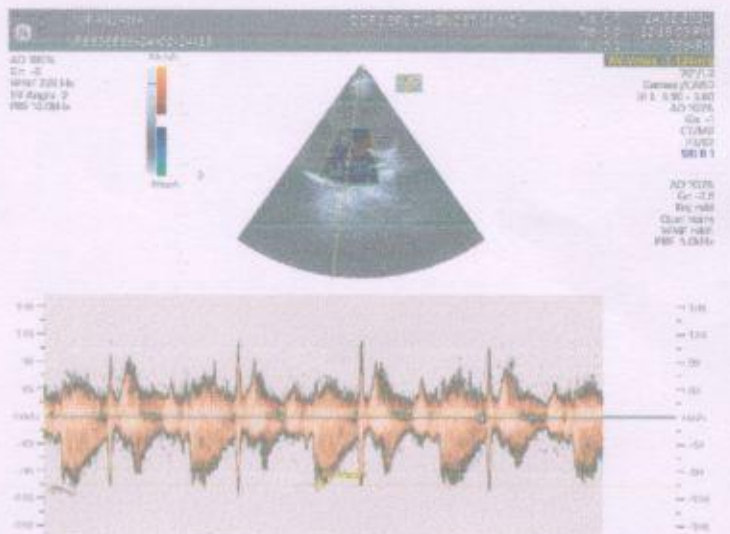
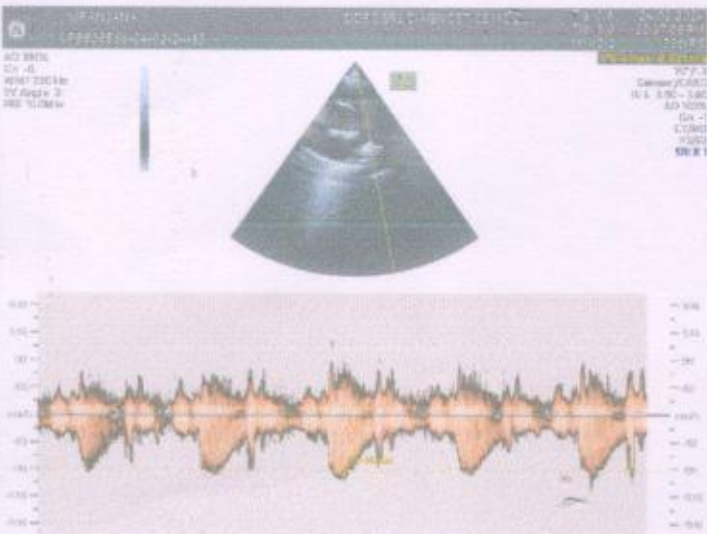
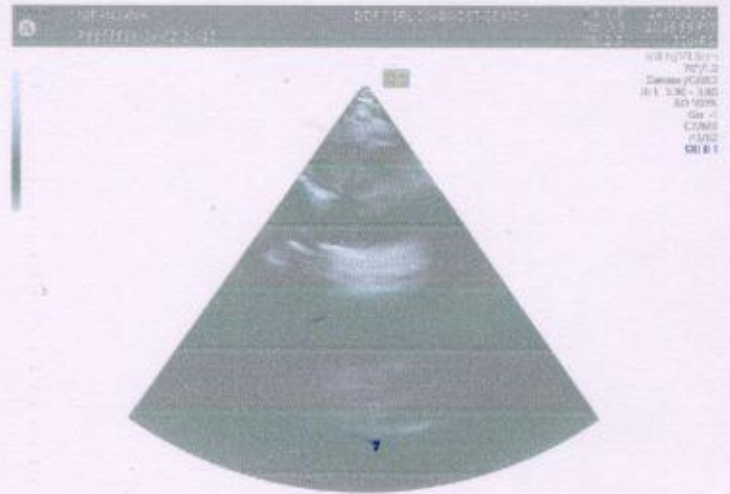
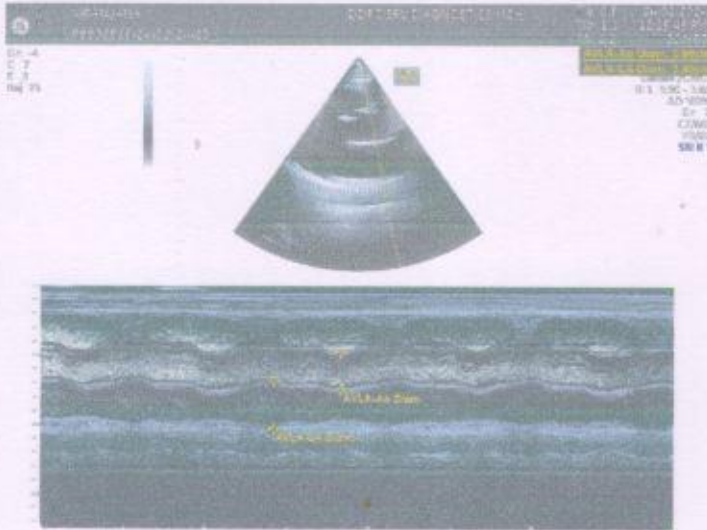


**Dr. SAJITH. K**  
MD,DNB  
CONSULTANT CARDIOLOGIST  
Reg:No: 19436

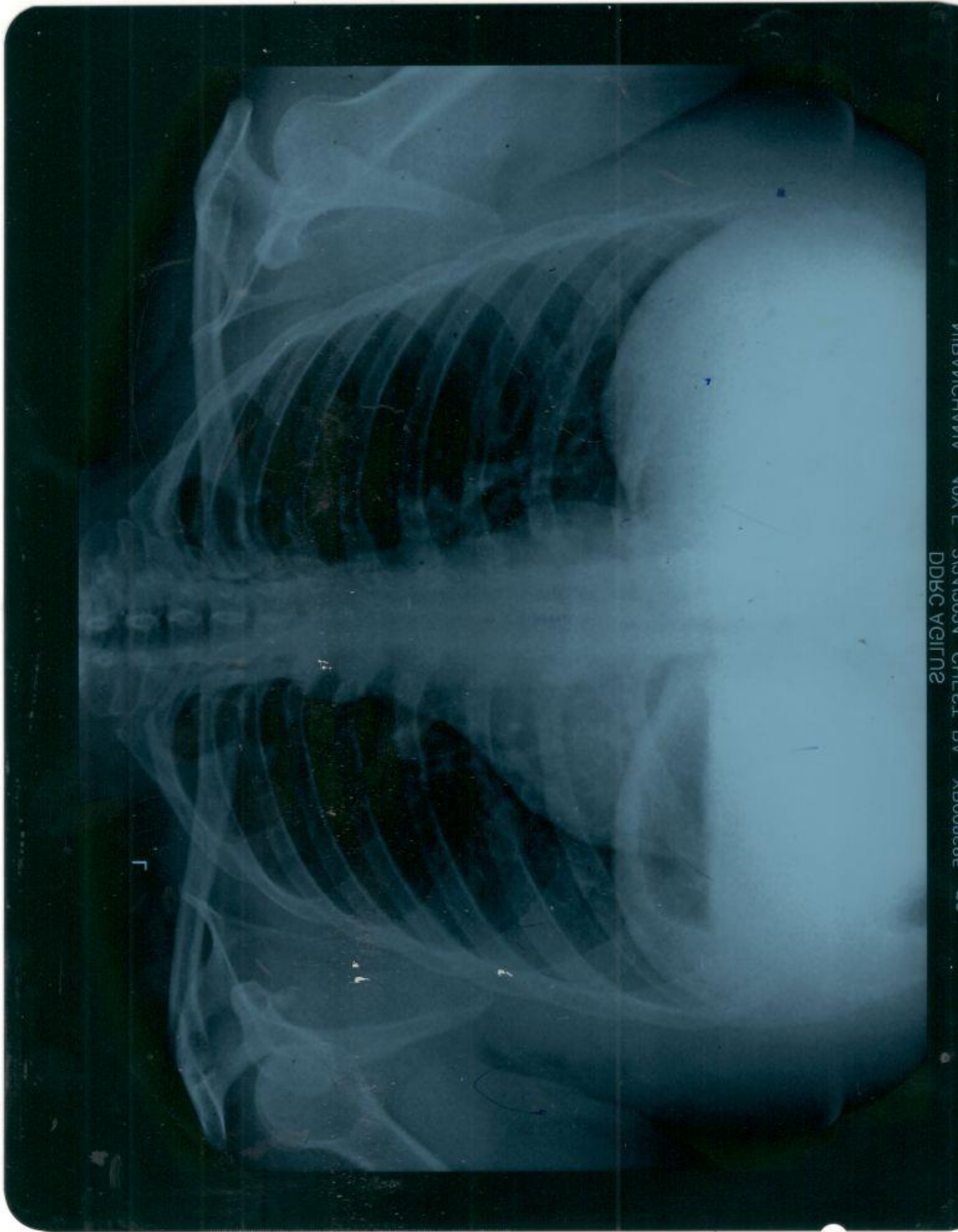
Consultant Cardiologist

**DDRC** **agilus** Pathlabs Limited.

Corp. Office : Express House, Second Floor, Opp. Pothys Silks, Banerjee Road, Kaloor -682017  
Contact :- 93334 93334, Web :- www.ddrcagilus.com Email :- info.ddrc@agilus.in







MIRIAMIANA NOLE SANDOZ CHEST PA APPROX 80  
DDRC AGILUS

R-cc

R-cc

DRRC VIGILUS

RMLTO



olm-5

DDRC VGILUS

Acc no:4182XB008685	Name: Mrs. Niranjana	Age: 40 y	<b>RADIOLOGY DIVISION</b> Sex: Female	Date:24.02.24
---------------------	----------------------	-----------	--	---------------

**US SCAN WHOLE ABDOMEN (TAS ONLY)**

**LIVER** is normal in size (11.9 cm). Margins are regular. Hepatic parenchyma shows normal echogenicity. No focal lesions seen. No dilatation of intrahepatic biliary radicles. CBD is not dilated. Portal vein is normal in caliber (9.5 mm).

**GALL BLADDER** is partially distended and grossly normal. No pericholecystic fluid seen.

**SPLEEN** is normal in size (9.4 cm) and parenchymal echotexture. No focal lesion seen.

**PANCREAS** Head and body visualized, appears normal in size and parenchymal echotexture. Pancreatic duct is not dilated.

**RIGHT KIDNEY** is normal in size (8.9 x 4 cm) and shows normal parenchymal echotexture. Cortico medullary differentiation is maintained. Parenchymal thickness is normal. No echogenic focus with shadowing suggestive of renal calculi seen. No dilatation of pelvicalyceal system seen. Ureter is not dilated. Perinephric spaces are normal.

**LEFT KIDNEY** is normal in size (9.7 x 5.4 cm) and shows normal parenchymal echotexture. Cortico medullary differentiation is maintained. Parenchymal thickness is normal. No echogenic focus with shadowing suggestive of renal calculi seen. No dilatation of pelvicalyceal system seen. Ureter is not dilated. Perinephric spaces are normal.

**PARAAORTIC AREA** (upper part visualised) No retroperitoneal lymphadenopathy or mass seen.

**URINARY BLADDER** is distended, normal in wall thickness, lumen clear.

**UTERUS** measures 10.9 x 3.7 x 5.4 cm, myometrial echopattern normal. No focal lesions seen. Endometrial thickness is 10.1 mm.

Both ovaries are normal. Right ovary measures 2.4 x 1.2 cm. Left ovary measures 3.2 x 1.2 cm. No adnexal mass seen. No fluid in pouch of Douglas.

No ascites or pleural effusion.

**Gaseous distension of bowel loops noted. No obvious bowel wall thickening seen sonologically.**

**CONCLUSION:-**

- **No significant abnormality detected in present study.**

  
**Dr. Nisha Unni MD, DNB (RD)**  
Consultant radiologist.

*Thanks for referral. Your feedback will be appreciated.*

*(Please bring relevant investigation reports during all visits)*

*Because of technical and technological limitations complete accuracy cannot be assured on imaging.*

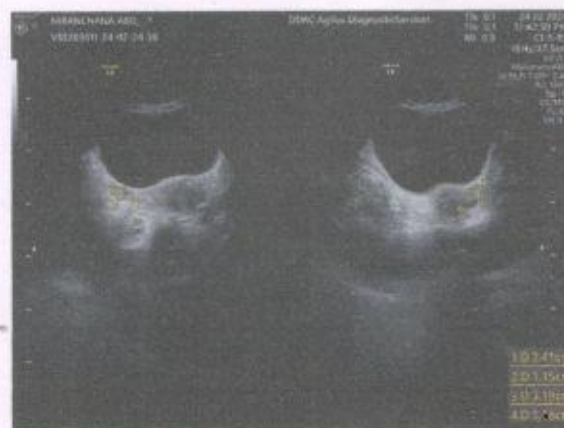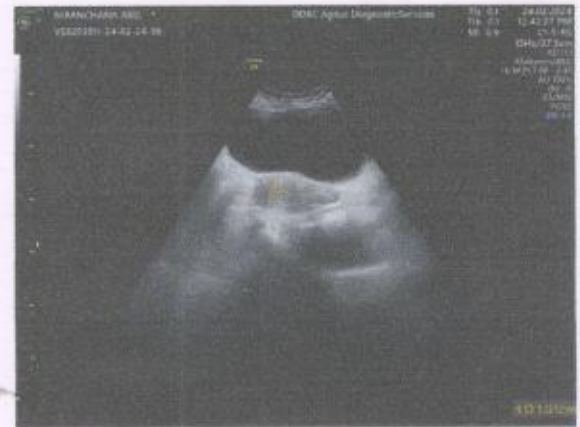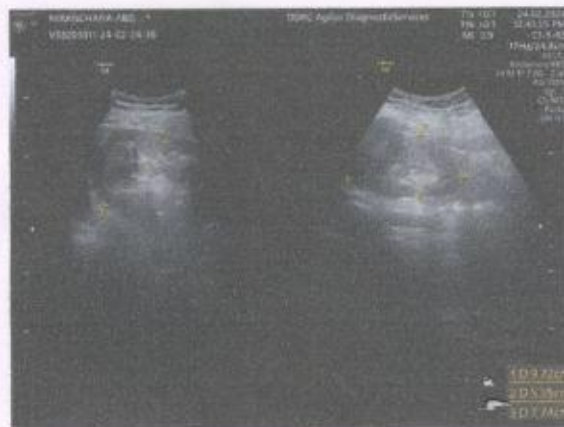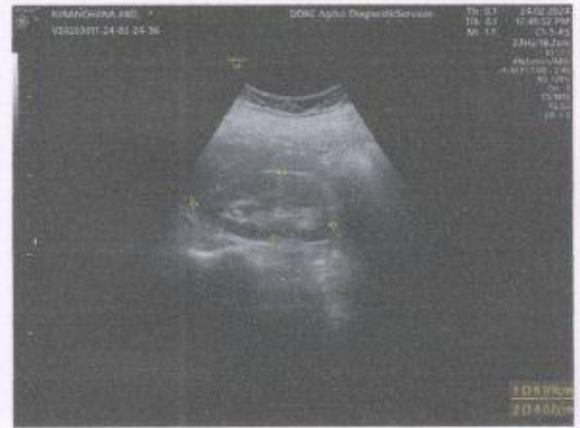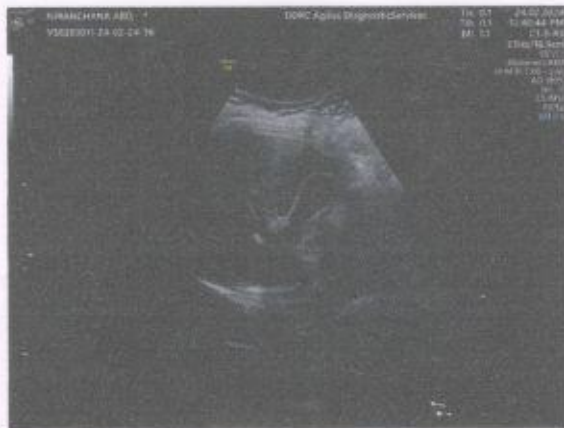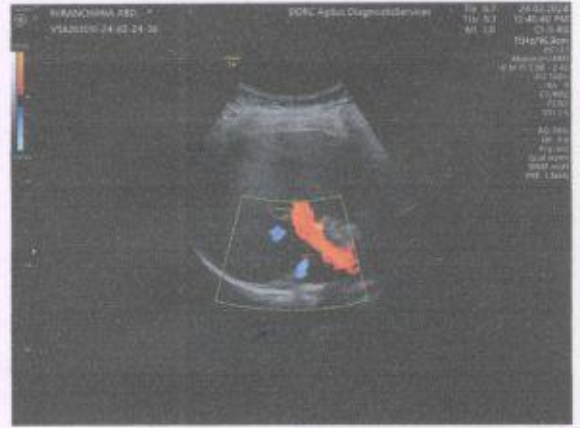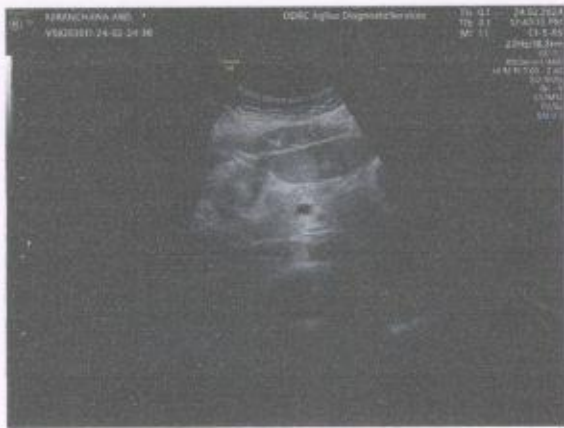*Suggested correlation with clinical findings and other relevant investigations consultations, and if required repeat imaging recommended in the event of controversies. AR*

**(For appointments / any clarification of report please contact 9496005190 between 9 am – 5.30 pm).**

**DDRC** agilus Pathlabs Limited.

Corp. Office : Express House, Second Floor, Opp. Pothys Silks, Banerjee Road, Kaloor -682017

Contact :- 93334 93334, Web :- [www.ddrcagilus.com](http://www.ddrcagilus.com) Email :- [info.ddrc@agilus.in](mailto:info.ddrc@agilus.in)



**MAMMOGRAM REPORT (BOTH) RADIOLOGY DIVISION**

Acc no:4182XB008685	Name: Mrs. Niranjana	Age: 40 y	Sex: Female	Date:24.02.24
---------------------	----------------------	-----------	-------------	---------------

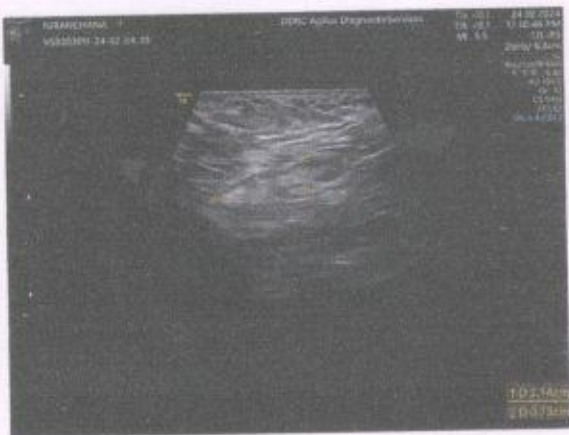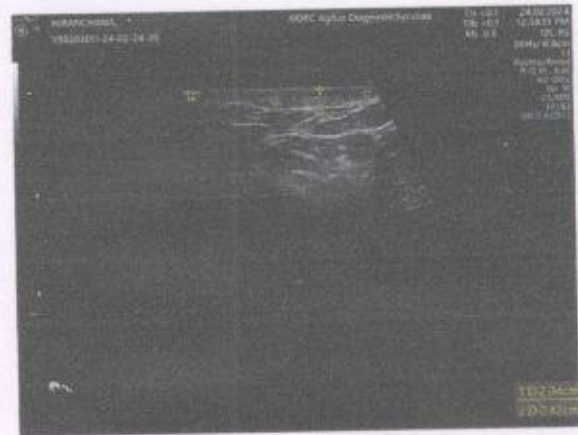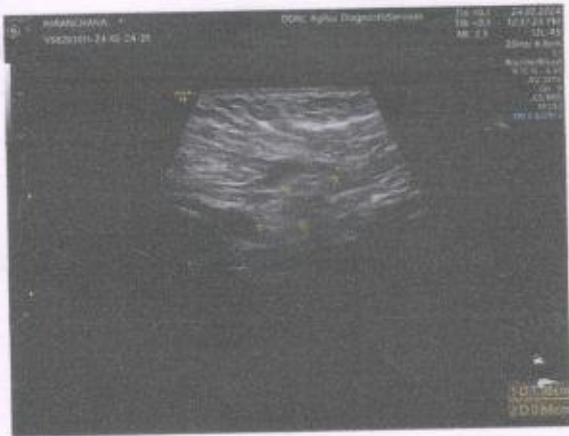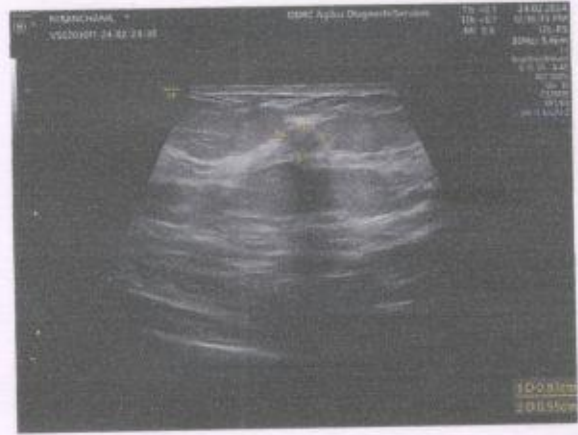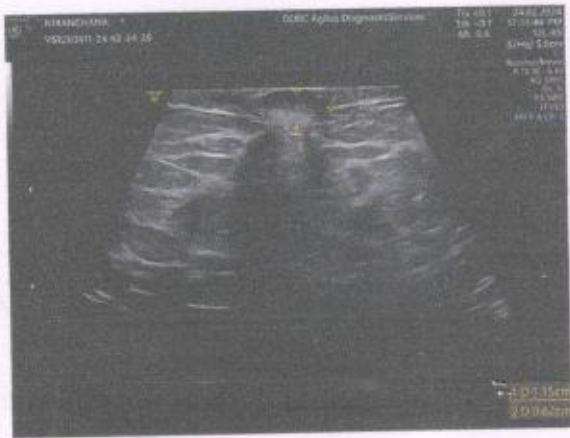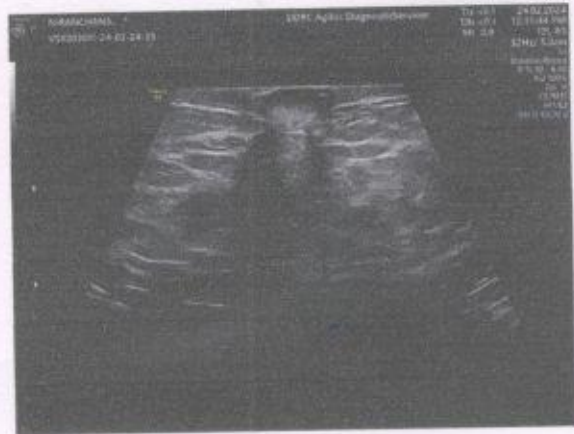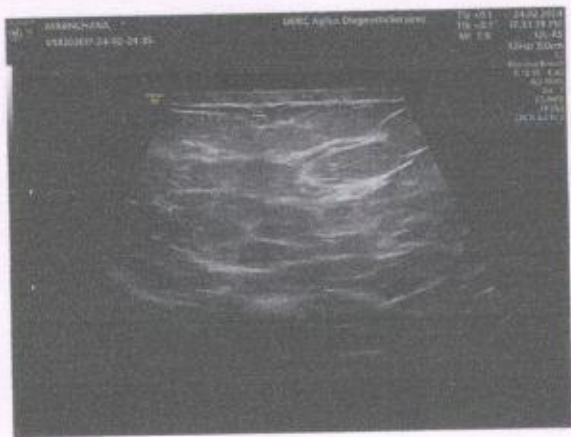- (i) **INDICATION** :- Screening
- (ii) **BREAST COMPOSITION** :-  
RIGHT : Heterogeneously dense breast which may obscure small masses  
LEFT : Heterogeneously dense breast which may obscure small masses.
- (iii) **OBSERVATION** :-  
RIGHT : - Subtle oval hyper density noted in upper outer quadrant with circumscribed margins. No asymmetry / architectural distortion / significant calcifications.  
LEFT :- A few (3 - 4 in nos) coarse calcific foci noted in grouped distribution at upper outer quadrant. No mass / asymmetry / architectural distortion. Suggestion of a few axillary lymphnodes.
- (iv) **COMPARISON WITH THE PREVIOUS STUDIES** :- Mammogram (20.10.23) - Right breast BIRADS 2 ? Fibroadenoma at 10 O' clock position.
- (v) **ULTRASOUND FINDINGS** :-  
RIGHT : Breast composition - Heterogeneous background echotexture.  
Foal skin thickening measuring 1.2 x 0.6 cm noted at about 2 O' clock position at the site of previous surgical incision.  
Oval iso - hypoechoic area measuring 8.3 x 5.5 mm noted at about 10 O' clock position. It shows circumscribed margin, posterior enhancement and no significant internal vascularity - possibly fibroadenoma / intramammary fat lobule - Size of which is decreased when compared to previous scan on 2.10.23. No cysts / intramammary duct dilation. Nipple areolar complex normal. A few morphologically benign axillary lymphnodes noted, largest measuring 1.9 x 0.9 cm.  
**LEFT** :- Breast composition - Heterogeneous background echotexture.  
Focal skin thickening measuring 2 x 0.4 cm noted at 10 O' cock position at the site of previous surgical scar. No mass / cysts / intramammary duct dilation. Nipple areolar complex normal. A few morphologically benign axillary lymphnodes noted, largest measuring 3.1 x 0.1 cm
- (vi) **IMPRESSION** :-  
RIGHT :- BIRADS assessment category - Benign  
BIRADS numeric code - 2  
LEFT :- BIRADS assessment category - Benign.  
BIRADS numeric code - 2.
- (vii) **RECOMMENDATIONS** :- Routine mammography screening.

  
Dr. Nisha Unni MD, DNB (RD)  
Consultant radiologist.

Thanks, your feedback will be appreciated.  
(Please bring relevant investigation reports during all visits).  
Because of technical and technological limitations complete accuracy cannot be assured on imaging.  
Suggested correlation with clinical findings and other relevant investigations consultations, and if required repeat imaging recommended in the event of controversies. AR  
For appointments please contact **9496005190** between 9 am - 5.30 pm).

**DDRC** agilus Pathlabs Limited.

Corp. Office : Express House, Second Floor, Opp. Pothys Silks, Banerjee Road, Kaloore -682017  
Contact :- 93334 93334, Web :- www.ddrcagilus.com Email :- info.ddrc@agilus.in



**PATIENT NAME : MRS. NIRANCHANA**

**REF. DOCTOR : SELF**

**CODE/NAME & ADDRESS :** CA00010147 -  
MEDIWHEEL ARCOFEMI HEALTHCARE LIMITED  
F701A, LADO SARAI, NEW DELHI,SOUTH DELHI,  
DELHI,  
SOUTH DELHI 110030  
8800465156

**ACCESSION NO :** **4182XB008685**  
**PATIENT ID :** NIRAF3007844107  
**CLIENT PATIENT ID:**  
**ABHA NO :**

**AGE/SEX :** 40 Years Female  
**DRAWN :**  
**RECEIVED :** 24/02/2024 09:09:31  
**REPORTED :** 24/02/2024 16:39:33

Test Report Status	<u>Preliminary</u>	Results	Biological Reference Interval	Units
--------------------	--------------------	---------	-------------------------------	-------

**MEDIWHEEL HEALTH CHECKUP ABOVE 40(F)2DECHO**

**PHYSICAL EXAMINATION**

PHYSICAL EXAMINATION

REPORT GIVEN



**DR NISHA UNNI, MBBS,MD**  
**(RD),DNB (Reg.No:50162)**  
**Consultant Radiologist**



View Details



View Report

**PERFORMED AT :**

DDRC AGILUS PATHLABS LIMITED  
ASTER SQUARE BUILDING, ULLOOR,  
MEDICAL COLLEGE P.O  
TRIVANDRUM, 695011  
KERALA, INDIA  
Tel : 93334 93334, Fax : CIN - U85190MH2006PTC161480  
Email : customercare.ddrc@agilus.in



**Patient Ref. No. 66600007977442**



**PATIENT NAME : MRS. NIRANCHANA**

**REF. DOCTOR : SELF**

**CODE/NAME & ADDRESS :** CA00010147 -  
MEDIWHEEL ARCOFEMI HEALTHCARE LIMITED  
F701A, LADO SARAI, NEW DELHI,SOUTH DELHI,  
DELHI,  
SOUTH DELHI 110030  
8800465156

**ACCESSION NO :** **4182XB008685**  
**PATIENT ID :** NIRAF3007844107  
**CLIENT PATIENT ID:**  
**ABHA NO :**

**AGE/SEX :** 40 Years Female  
**DRAWN :**  
**RECEIVED :** 24/02/2024 09:09:31  
**REPORTED :** 24/02/2024 16:39:33

Test Report Status	<u>Preliminary</u>	Results	Units
--------------------	--------------------	---------	-------

**MEDIWHEEL HEALTH CHECKUP ABOVE 40(F)2DECHO**

**ECG WITH REPORT**

**REPORT  
REPORT GIVEN**

**2D - ECHO WITH COLOR DOPPLER**

**REPORT  
REPORT GIVEN**

**USG ABDOMEN AND PELVIS**

**REPORT  
REPORT GIVEN**

**CHEST X-RAY WITH REPORT**

**REPORT  
REPORT GIVEN**

**MAMMOGRAPHY -BOTH**

**REPORT  
REPORT GIVEN**

**HAEMATOTOLOGY**

**MEDIWHEEL HEALTH CHECKUP ABOVE 40(F)2DECHO**

**GLYCOSYLATED HEMOGLOBIN(HBA1C), EDTA WHOLE BLOOD**

HBA1C	<b>6.6 High</b>	Non-diabetic Adult < 5.7 Pre-diabetes 5.7 - 6.4	%
-------	-----------------	--	---

**DR NISHA UNNI, MBBS,MD  
(RD),DNB (Reg.No:50162)  
Consultant Radiologist**

**DR.HARI SHANKAR, MBBS MD  
(Reg No - TCMC:62092)  
HEAD - Biochemistry &  
Immunology**

**DR.VAISHALI RAJAN, MBBS DCP  
(Pathology)  
(Reg No - TCC 27150)  
HOD - HAEMATOTOLOGY**



View Details



View Report

Page 2 Of 10

**PERFORMED AT :**

DDRC AGILUS PATHLABS LIMITED  
ASTER SQUARE BUILDING, ULLOOR,  
MEDICAL COLLEGE P.O  
TRIVANDRUM, 695011  
KERALA, INDIA  
Tel : 93334 93334, Fax : CIN - U85190MH2006PTC161480  
Email : customercare.ddrc@agilus.in



**Patient Ref. No. 66600007977442**

**PATIENT NAME : MRS. NIRANCHANA**

**REF. DOCTOR : SELF**

**CODE/NAME & ADDRESS :** CA00010147 -  
MEDIWHEEL ARCOFEMI HEALTHCARE LIMITED  
F701A, LADO SARAI, NEW DELHI, SOUTH DELHI,  
DELHI,  
SOUTH DELHI 110030  
8800465156

**ACCESSION NO :** **4182XB008685**  
**PATIENT ID :** NIRAF3007844107  
**CLIENT PATIENT ID:**  
**ABHA NO :**

**AGE/SEX :** 40 Years Female  
**DRAWN :**  
**RECEIVED :** 24/02/2024 09:09:31  
**REPORTED :** 24/02/2024 16:39:33

Test Report Status	<u>Preliminary</u>	Results	Units
--------------------	--------------------	---------	-------

Diabetes diagnosis: > or = 6.5  
Therapeutic goals: < 7.0  
Action suggested : > 8.0  
(ADA Guideline 2021)

MEAN PLASMA GLUCOSE	<b>142.7 High</b>	< 116.0	mg/dL
---------------------	-------------------	---------	-------

**BLOOD COUNTS, EDTA WHOLE BLOOD**

HEMOGLOBIN	12.5	12.0 - 15.0	g/dL
RED BLOOD CELL COUNT	<b>4.84 High</b>	3.80 - 4.80	mil/ $\mu$ L
WHITE BLOOD CELL COUNT	7.67	4.0 - 10.0	thou/ $\mu$ L
PLATELET COUNT	264	150 - 410	thou/ $\mu$ L

**RBC AND PLATELET INDICES**

HEMATOCRIT	38.8	36.0 - 46.0	%
MEAN CORPUSCULAR VOL	<b>80.2 Low</b>	83.0 - 101	fL
MEAN CORPUSCULAR HGB.	<b>25.8 Low</b>	27.0 - 32.0	pg
MEAN CORPUSCULAR HEMOGLOBIN CONCENTRATION	32.2	31.50 - 34.50	g/dL
RED CELL DISTRIBUTION WIDTH	12.9	11.60 - 14.0	%
MENTZER INDEX	16.6		
MEAN PLATELET VOLUME	8.3	6.80 - 10.90	fL

**WBC DIFFERENTIAL COUNT**

SEGMENTED NEUTROPHILS	64	40.0 - 80.0	%
LYMPHOCYTES	28	20.0 - 40.0	%
MONOCYTES	5	2.0 - 10.0	%
EOSINOPHILS	3	1.0 - 6.0	%
BASOPHILS	0	0.0 - 1.0	%
ABSOLUTE NEUTROPHIL COUNT	4.87	2.0 - 7.0	thou/ $\mu$ L

**DR. HARI SHANKAR, MBBS MD**  
(Reg No - TCMC:62092)  
**HEAD - Biochemistry & Immunology**

**DR. VAISHALI RAJAN, MBBS DCP**  
(Pathology)  
(Reg No - TCC 27150)  
**HOD - HAEMATOLOGY**

Page 3 Of 10



View Details



View Report

**PERFORMED AT :**

DDRC AGILUS PATHLABS LIMITED  
ASTER SQUARE BUILDING, ULLOOR,  
MEDICAL COLLEGE P.O  
TRIVANDRUM, 695011  
KERALA, INDIA  
Tel : 93334 93334, Fax : CIN - U85190MH2006PTC161480  
Email : customercare.ddrc@agilus.in



**Patient Ref. No. 66600007977442**

**PATIENT NAME : MRS. NIRANCHANA**

**REF. DOCTOR : SELF**

**CODE/NAME & ADDRESS :** CA00010147 -  
MEDIWHEEL ARCOFEMI HEALTHCARE LIMITED  
F701A, LADO SARAI, NEW DELHI,SOUTH DELHI,  
DELHI,  
SOUTH DELHI 110030  
8800465156

**ACCESSION NO :** **4182XB008685**  
**PATIENT ID :** NIRAF3007844107  
**CLIENT PATIENT ID:**  
**ABHA NO :**

**AGE/SEX :** 40 Years Female  
**DRAWN :**  
**RECEIVED :** 24/02/2024 09:09:31  
**REPORTED :** 24/02/2024 16:39:33

Test Report Status	<u>Preliminary</u>	Results	Units	
ABSOLUTE LYMPHOCYTE COUNT		2.15	1.0 - 3.0	thou/ $\mu$ L
ABSOLUTE MONOCYTE COUNT		0.35	0.20 - 1.0	thou/ $\mu$ L
ABSOLUTE EOSINOPHIL COUNT		0.22	0.02 - 0.50	thou/ $\mu$ L
ABSOLUTE BASOPHIL COUNT		0.00		thou/ $\mu$ L
NEUTROPHIL LYMPHOCYTE RATIO (NLR)		2.3		

**ERYTHROCYTE SEDIMENTATION RATE (ESR),EDTA BLOOD**

SEDIMENTATION RATE (ESR) **27 High** 0 - 20 mm at 1 hr

**SUGAR URINE - POST PRANDIAL**

SUGAR URINE - POST PRANDIAL **DETECTED (TRACE)** NOT DETECTED

**Comments**

Rechecked

**SUGAR URINE - FASTING**

SUGAR URINE - FASTING NOT DETECTED NOT DETECTED


**IMMUNOHAEMATOLOGY**


**MEDIWHEEL HEALTH CHECKUP ABOVE 40(F)2DECHO**

**ABO GROUP & RH TYPE, EDTA WHOLE BLOOD**

ABO GROUP TYPE A  
RH TYPE POSITIVE

METHOD : COLUMN AGGLUTINATION TECHNOLOGY

  
**DR.HARI SHANKAR, MBBS MD**  
(Reg No - TCMC:62092)  
**HEAD - Biochemistry & Immunology**

  
**DR.VAISHALI RAJAN, MBBS DCP**  
(Pathology)  
(Reg No - TCC 27150)  
**HOD - HAEMATOLOGY**



View Details



View Report

**PERFORMED AT :**

DDRC AGILUS PATHLABS LIMITED  
ASTER SQUARE BUILDING, ULLOOR,  
MEDICAL COLLEGE P.O  
TRIVANDRUM, 695011  
KERALA, INDIA  
Tel : 93334 93334, Fax : CIN - U85190MH2006PTC161480  
Email : customercare.ddrc@agilus.in



**Patient Ref. No. 66600007977442**

**PATIENT NAME : MRS. NIRANCHANA**

**REF. DOCTOR : SELF**

**CODE/NAME & ADDRESS :** CA00010147 -  
MEDIWHEEL ARCOFEMI HEALTHCARE LIMITED  
F701A, LADO SARAI, NEW DELHI,SOUTH DELHI,  
DELHI,  
SOUTH DELHI 110030  
8800465156

**ACCESSION NO :** **4182XB008685**  
**PATIENT ID :** NIRAF3007844107  
**CLIENT PATIENT ID:**  
**ABHA NO :**

**AGE/SEX :** 40 Years Female  
**DRAWN :**  
**RECEIVED :** 24/02/2024 09:09:31  
**REPORTED :** 24/02/2024 16:39:33

Test Report Status	<u>Preliminary</u>	Results	Units
--------------------	--------------------	---------	-------

<b>Interpretation(s)</b>

ABO GROUP & RH TYPE, EDTA WHOLE BLOOD-Blood group is identified by antigens and antibodies present in the blood. Antigens are protein molecules found on the surface of red blood cells. Antibodies are found in plasma. To determine blood group, red cells are mixed with different antibody solutions to give A,B,O or AB.

Disclaimer: "Please note, as the results of previous ABO and Rh group (Blood Group) for pregnant women are not available, please check with the patient records for availability of the same."

The test is performed by both forward as well as reverse grouping methods.

**BIO CHEMISTRY**

**MEDIWHEEL HEALTH CHECKUP ABOVE 40(F)2DECHO**

**BLOOD UREA NITROGEN (BUN), SERUM**

BLOOD UREA NITROGEN 6 Adult(<60 yrs) : 6 to 20 mg/dL

**BUN/CREAT RATIO**

BUN/CREAT RATIO 10.5

**CREATININE, SERUM**

CREATININE 0.57 18 - 60 yrs : 0.6 - 1.1 mg/dL

**GLUCOSE, POST-PRANDIAL, PLASMA**

GLUCOSE, POST-PRANDIAL, PLASMA **207 High** Diabetes Mellitus : > or = 200. mg/dL  
Impaired Glucose tolerance/  
Prediabetes : 140 - 199.  
Hypoglycemia : < 55.

**DR.HARI SHANKAR, MBBS MD**  
(Reg No - TCMC:62092)  
**HEAD - Biochemistry & Immunology**

**DR.VAISHALI RAJAN, MBBS DCP**  
(Pathology)  
(Reg No - TCC 27150)  
**HOD - HAEMATOLOGY**

Page 5 Of 10



View Details



View Report

**PERFORMED AT :**

DDRC AGILUS PATHLABS LIMITED  
ASTER SQUARE BUILDING, ULLLOOR,  
MEDICAL COLLEGE P.O  
TRIVANDRUM, 695011  
KERALA, INDIA  
Tel : 93334 93334, Fax : CIN - U85190MH2006PTC161480  
Email : customercare.ddrc@agilus.in



**Patient Ref. No. 66600007977442**

**PATIENT NAME : MRS. NIRANCHANA**


**REF. DOCTOR : SELF**

**CODE/NAME & ADDRESS :** CA00010147 -  
MEDIWHEEL ARCOFEMI HEALTHCARE LIMITED  
F701A, LADO SARAI, NEW DELHI,SOUTH DELHI,  
DELHI,  
SOUTH DELHI 110030  
8800465156

**ACCESSION NO :** **4182XB008685**  
**PATIENT ID :** NIRAF3007844107  
**CLIENT PATIENT ID:**  
**ABHA NO :**

**AGE/SEX :** 40 Years Female  
**DRAWN :**  
**RECEIVED :** 24/02/2024 09:09:31  
**REPORTED :** 24/02/2024 16:39:33

**Test Report Status** Preliminary **Results** **Units**



**GLUCOSE FASTING,FLUORIDE PLASMA**

FBS (FASTING BLOOD SUGAR) 118 mg/dL  
Diabetes Mellitus : > or = 126. mg/dL  
Impaired fasting Glucose/  
Prediabetes : 101 - 125.  
Hypoglycemia : < 55.

**DR.HARI SHANKAR, MBBS MD**  
(Reg No - TCMC:62092)  
**HEAD - Biochemistry &  
Immunology**



View Details



View Report

**PERFORMED AT :**

DDRC AGILUS PATHLABS LIMITED  
ASTER SQUARE BUILDING, ULLOOR,  
MEDICAL COLLEGE P.O  
TRIVANDRUM, 695011  
KERALA, INDIA  
Tel : 93334 93334, Fax : CIN - U85190MH2006PTC161480  
Email : customercare.ddrc@agilus.in



**Patient Ref. No. 66600007977442**

**PATIENT NAME : MRS. NIRANCHANA**

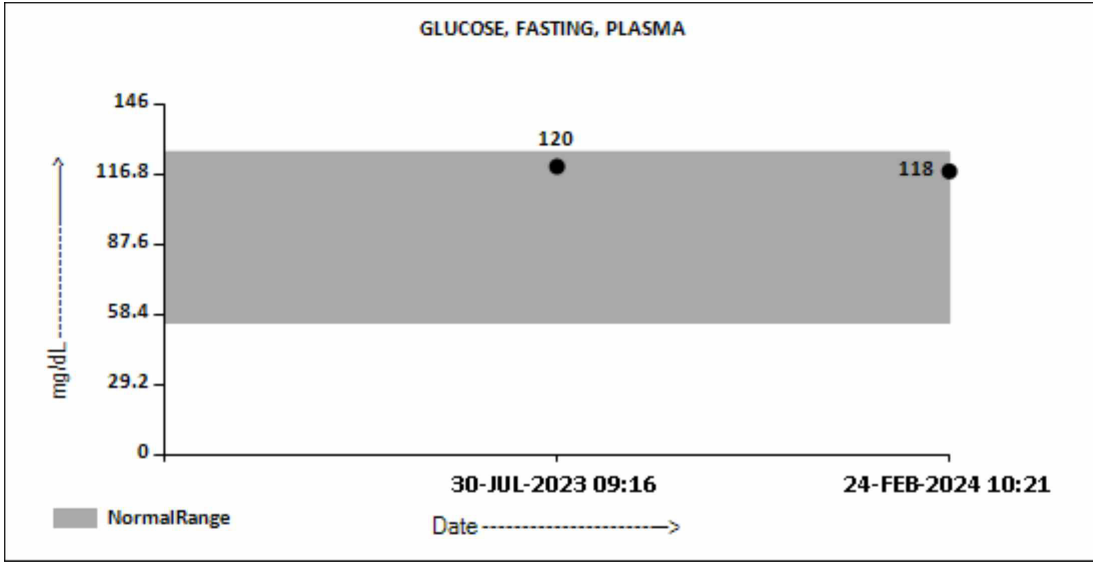
**REF. DOCTOR : SELF**

**CODE/NAME & ADDRESS :** CA00010147 -  
MEDIWHEEL ARCOFEMI HEALTHCARE LIMITED  
F701A, LADO SARAI, NEW DELHI, SOUTH DELHI,  
DELHI,  
SOUTH DELHI 110030  
8800465156

**ACCESSION NO :** **4182XB008685**  
**PATIENT ID :** NIRAF3007844107  
**CLIENT PATIENT ID:**  
**ABHA NO :**

**AGE/SEX :** 40 Years Female  
**DRAWN :**  
**RECEIVED :** 24/02/2024 09:09:31  
**REPORTED :** 24/02/2024 16:39:33

**Test Report Status** Preliminary **Results** **Units**



**LIVER FUNCTION TEST WITH GGT**

BILIRUBIN, TOTAL	0.36	General Range : < 1.1	mg/dL
BILIRUBIN, DIRECT	0.15	General Range : < 0.3	mg/dL
BILIRUBIN, INDIRECT	0.21	General Range : <0.85	mg/dL
TOTAL PROTEIN	6.3	Ambulatory : 6.4 - 8.3 Recumbant : 6 - 7.8	g/dL
ALBUMIN	3.9	20-60yrs : 3.5 - 5.2	g/dL
GLOBULIN	2.4	General Range : 2 - 3.5 Premature Neonates : 0.29 - 1.04	g/dL
ALBUMIN/GLOBULIN RATIO	1.6	General Range : 1.1 - 2.5	RATIO
ASPARTATE AMINOTRANSFERASE (AST/SGOT)	11	Adults : < 33	U/L
ALANINE AMINOTRANSFERASE (ALT/SGPT)	17	Adults : < 34	U/L
ALKALINE PHOSPHATASE	75	Adult (<60yrs) : 35 - 105	U/L
GAMMA GLUTAMYL TRANSFERASE (GGT)	18	Adult (female) : < 40	U/L

**TOTAL PROTEIN, SERUM**

**DR. HARI SHANKAR, MBBS MD**  
(Reg No - TCMC:62092)  
**HEAD - Biochemistry & Immunology**

Page 7 Of 10



View Details



View Report

**PERFORMED AT :**

DDRC AGILUS PATHLABS LIMITED  
ASTER SQUARE BUILDING, ULLOOR,  
MEDICAL COLLEGE P.O  
TRIVANDRUM, 695011  
KERALA, INDIA  
Tel : 93334 93334, Fax : CIN - U85190MH2006PTC161480  
Email : customercare.ddrc@agilus.in



**Patient Ref. No. 66600007977442**

**PATIENT NAME : MRS. NIRANCHANA**

**REF. DOCTOR : SELF**

**CODE/NAME & ADDRESS :** CA00010147 -  
MEDIWHEEL ARCOFEMI HEALTHCARE LIMITED  
F701A, LADO SARAI, NEW DELHI,SOUTH DELHI,  
DELHI,  
SOUTH DELHI 110030  
8800465156

**ACCESSION NO :** **4182XB008685**  
**PATIENT ID :** NIRAF3007844107  
**CLIENT PATIENT ID:**  
**ABHA NO :**

**AGE/SEX :** 40 Years Female  
**DRAWN :**  
**RECEIVED :** 24/02/2024 09:09:31  
**REPORTED :** 24/02/2024 16:39:33

Test Report Status	Preliminary	Results	Units
TOTAL PROTEIN		6.3	Ambulatory : 6.4 - 8.3 Recumbant : 6 - 7.8 g/dL
<b>URIC ACID, SERUM</b>			
URIC ACID		3.5	Adults : 2.4-5.7 mg/dL

**BIOCHEMISTRY - LIPID**

**MEDIWHEEL HEALTH CHECKUP ABOVE 40(F)2DECHO**

**LIPID PROFILE, SERUM**

CHOLESTEROL	<b>254 High</b>	Desirable : < 200 Borderline : 200-239 High : >or= 240	mg/dL
TRIGLYCERIDES	127	Normal : < 150 High : 150-199 Hypertriglyceridemia : 200-499 Very High : > 499	mg/dL
HDL CHOLESTEROL	55	General range : 40-60	mg/dL
LDL CHOLESTEROL, DIRECT	<b>197 High</b>	Optimum : < 100 Above Optimum : 100-129 Borderline High : 130-159 High : 160-189 Very High : >or= 190	mg/dL
NON HDL CHOLESTEROL	<b>199 High</b>	Desirable : < 130 Above Desirable : 130 -159 Borderline High : 160 - 189 High : 190 - 219 Very high : > / = 220	mg/dL
VERY LOW DENSITY LIPOPROTEIN CHOL/HDL RATIO	25.4	</= 30.0	mg/dL
LDL/HDL RATIO	4.6	Low Risk : 3.3 - 4.4 Average Risk : 4.5 - 7.0 Moderate Risk : 7.1 - 11.0 High Risk : > 11.0	
	3.6	Desirable/Low Risk - 0.5-3	

**DR.HARI SHANKAR, MBBS MD**  
(Reg No - TCMC:62092)  
**HEAD - Biochemistry & Immunology**

Page 8 Of 10



View Details



View Report

**PERFORMED AT :**

DDRC AGILUS PATHLABS LIMITED  
ASTER SQUARE BUILDING, ULLOOR,  
MEDICAL COLLEGE P.O  
TRIVANDRUM, 695011  
KERALA, INDIA  
Tel : 93334 93334, Fax : CIN - U85190MH2006PTC161480  
Email : customercare.ddrc@agilus.in



**Patient Ref. No. 66600007977442**

PATIENT NAME : MRS. NIRANCHANA

REF. DOCTOR : SELF

CODE/NAME & ADDRESS : CA00010147 -  
MEDIWHEEL ARCOFEMI HEALTHCARE LIMITED  
F701A, LADO SARAI, NEW DELHI, SOUTH DELHI,  
DELHI,  
SOUTH DELHI 110030  
8800465156

ACCESSION NO : **4182XB008685**  
PATIENT ID : NIRAF3007844107  
CLIENT PATIENT ID:  
ABHA NO :

AGE/SEX : 40 Years Female  
DRAWN :  
RECEIVED : 24/02/2024 09:09:31  
REPORTED : 24/02/2024 16:39:33

Test Report Status	Preliminary	Results	Units
--------------------	-------------	---------	-------

Borderline/Moderate Risk- 3.1-6  
High Risk- >6.0

**HISTOPATHOLOGY**

**MEDIWHEEL HEALTH CHECKUP ABOVE 40(F)2DECHO** RESULT PENDING  
**CYTOLOGY - CS (PAP SMEAR)** RESULT PENDING

**SPECIALISED CHEMISTRY - HORMONE**

**MEDIWHEEL HEALTH CHECKUP ABOVE 40(F)2DECHO**

**THYROID PANEL, SERUM**

T3	113.00	Non-Pregnant : 80-200	ng/dL
		Pregnant Trimester-wise	
		1st : 81-190	
		2nd : 100-260	
		3rd : 100-260	
T4	8.03	Adults : 4.5-12.1	µg/dl
TSH 3RD GENERATION	2.070	Non-Pregnant : 0.4-4.2	µIU/mL
		Pregnant Trimester-wise :	
		1st : 0.1 - 2.5	
		2nd : 0.2 - 3	
		3rd : 0.3 - 3	

**CLINICAL PATH - URINALYSIS**

**MEDIWHEEL HEALTH CHECKUP ABOVE 40(F)2DECHO**

**PHYSICAL EXAMINATION, URINE**

COLOR PALE YELLOW

**DR. HARI SHANKAR, MBBS MD**  
(Reg No - TCMC:62092)  
HEAD - Biochemistry &  
Immunology

**DR. VAISHALI RAJAN, MBBS DCP**  
(Pathology)  
(Reg No - TCC 27150)  
HOD - HAEMATOLOGY

Page 9 Of 10



View Details



View Report

**PERFORMED AT :**

DDRC AGILUS PATHLABS LIMITED  
ASTER SQUARE BUILDING, ULLOOR,  
MEDICAL COLLEGE P.O  
TRIVANDRUM, 695011  
KERALA, INDIA  
Tel : 93334 93334, Fax : CIN - U85190MH2006PTC161480  
Email : customercare.ddrc@agilus.in



Patient Ref. No. 66600007977442



**PATIENT NAME : MRS. NIRANCHANA**

**REF. DOCTOR : SELF**

**CODE/NAME & ADDRESS :** CA00010147 -  
MEDIWHEEL ARCOFEMI HEALTHCARE LIMITED  
F701A, LADO SARAI, NEW DELHI, SOUTH DELHI,  
DELHI,  
SOUTH DELHI 110030  
8800465156

**ACCESSION NO :** **4182XB008685**  
**PATIENT ID :** NIRAF3007844107  
**CLIENT PATIENT ID:**  
**ABHA NO :**

**AGE/SEX :** 40 Years Female  
**DRAWN :**  
**RECEIVED :** 24/02/2024 09:09:31  
**REPORTED :** 24/02/2024 16:39:33

Test Report Status	<u>Preliminary</u>	Results	Units
--------------------	--------------------	---------	-------

APPEARANCE CLEAR

**CHEMICAL EXAMINATION, URINE**

PH	5.0	4.7 - 7.5
SPECIFIC GRAVITY	1.007	1.003 - 1.035
PROTEIN	NEGATIVE	NOT DETECTED
GLUCOSE	NEGATIVE	NOT DETECTED
KETONES	NEGATIVE	NOT DETECTED
BLOOD	NEGATIVE	NOT DETECTED
BILIRUBIN	NEGATIVE	NOT DETECTED
UROBILINOGEN	NORMAL	NORMAL
NITRITE	NEGATIVE	NOT DETECTED

**MICROSCOPIC EXAMINATION, URINE**

RED BLOOD CELLS	NOT DETECTED	NOT DETECTED	/HPF
WBC	0-1	0-5	/HPF
EPITHELIAL CELLS	0-1	0-5	/HPF
CASTS	NEGATIVE		
CRYSTALS	NEGATIVE		
REMARKS	NIL		



**DR. VAISHALI RAJAN, MBBS DCP**  
**(Pathology)**  
**(Reg No - TCC 27150)**  
**HOD - HAEMATOLOGY**

Page 10 Of 10



View Details



View Report

**PERFORMED AT :**

DDRC AGILUS PATHLABS LIMITED  
ASTER SQUARE BUILDING, ULLOOR,  
MEDICAL COLLEGE P.O  
TRIVANDRUM, 695011  
KERALA, INDIA  
Tel : 93334 93334, Fax : CIN - U85190MH2006PTC161480  
Email : customercare.ddrc@agilus.in

  
**Patient Ref. No. 66600007977442**