



**DEPARTMENT OF PATHOLOGY**

Patient Name : Mr. PRANAV SOORMA  
 MR No : 30086  
 Age/Sex : 29 Years 4 Months 20 Days / Male  
 Type : OPD  
 TPA/Corporate : MEDIWHEEL

Bill Date : 23/02/2024  
 Reporting Date : 24/02/2024  
 Sample ID : 68053  
 Bill/Req. No. : 24089694  
 Ref Doctor : Dr.CONULTANT

Test	Result	Bio. Ref. Interval	Units
<b>HB A1C GLYCOSYLATED HAEMOGLOBIN</b>			
HBA1C	5.4		%

**Note : Non-Diabetics 4.0 - 6.0 %**

In Diabetics


Good Control 6.1 - 6.8 %

Fair Control 6.9 - 7.6 %

Poor Control > 7.6 %

\*\*\*\*\* END OF THE REPORT \*\*\*\*\*

OUT SOURCE  
PARK HOSPITAL  
GGN



Sample no.

Dr. VAISHALI YADAV    Dr.REETU JADHAV    Dr. PARDIP KUMAR    S.C.GAUR  
 CONS.PATHOLOGIST    CONS.PATHOLOGIST    MICROBIOLOGIST & ICO    LAB INCHARGE    USER NM    SUNIL

(This is only professional opinion and not the diagnosis, Please correlate clinically)

J-Block, Sector-10, Near Court, Faridabad - 121004, Haryana

Tel.: 0129-4200000 E-mail : parkfaridabad@gmail.com



**DEPARTMENT OF PATHOLOGY**

Patient Name : Mr. PRANAV SOORMA  
 MR No : 30086  
 Age/Sex : 29 Years 4 Months 20 Days / Male  
 Type : OPD  
 TPA/Corporate : MEDIWHEEL

Bill Date : 23/02/2024  
 Reporting Date : 24/02/2024  
 Sample ID : 68053  
 Bill/Req. No. : 24089694  
 Ref Doctor : Dr.CONSULTANT

Test	Result	Bio. Ref. Interval	Units
<b>PSA - TOTAL (PROSTATIC SPECIFIC ANTIGEN) - CANCER MARKER</b>			
PROSTATE SPECIFIC ANTIGEN(PSA)	0.31	0.0 - 4.0	ng/ml

**Note :** Decrease in total PSA level is seen 24 to 48 hours after ejaculation. Decrease in total PSA level occurs after prostatectomy and orchidectomy. successful radiation therapy and therapy with anti-androgen drugs result in decline in PSA levels, over a period of time.  
 \*Results of these tests should always be interpreted in conjunction with patients medical history, clinical presentation and other findings.  
 \*The test has been performed in Park Hospital Sector-47, Gurgaon.

\*\*\*\*\* END OF THE REPORT \*\*\*\*\*

OUT SOURCE  
PARK HOSPITAL  
GGN



Sample no.

Dr. VAISHALI YADAV    Dr. REETU JADHAV    Dr. PARDIP KUMAR    S.C. GAUR  
 CONS. PATHOLOGIST    CONS. PATHOLOGIST    MICROBIOLOGIST & ICO LAB INCHARGE    USER NM SUNIL

(This is only professional opinion and not the diagnosis, Please correlate clinically)

J-Block, Sector-10, Near Court, Faridabad - 121004, Haryana

Tel.: 0129-4200000 E-mail : parkfaridabad@gmail.com



**DEPARTMENT OF PATHOLOGY**

Patient Name : Mr. PRANAV SOORMA  
MR No : 30086  
Age/Sex : 29 Years 4 Months 20 Days / Male  
Type : OPD  
TPA/Corporate : MEDIWHEEL

Bill Date : 23/02/2024  
Reporting Date : 24/02/2024  
Sample ID : 68053  
Bill/Req. No. : 24089694  
Ref Doctor : Dr.CONSULTANT

Test	Result	Bio. Ref. Interval	Units
<b>THYROID PROFILE</b>			
TRI-IODOTHYRONINE (T3)	0.97	0.60 - 1.81	ng/ml
THYROXINE (T4)	9.9	5.01 - 12.45	µg/dL
THYROID STIMULATING HORMONE	2.12	0.5-5.50	µIU/ml

\*\*\*\*\* END OF THE REPORT \*\*\*\*\*

OUT SOURCE  
PARK HOSPITAL  
GGN



Sample no.

Dr. VAISHALI YADAV    Dr.REETU JADHAV    Dr. PARDIP KUMAR    S.C.GAUR  
CONS.PATHOLOGIST    CONS.PATHOLOGIST    MICROBIOLOGIST & ICO    LAB INCHARGE    USER NM    SUNIL

(This is only professional opinion and not the diagnosis, Please correlate clinically)

J-Block, Sector-10, Near Court, Faridabad - 121004, Haryana

Tel.: 0129-4200000 E-mail : parkfaridabad@gmail.com



# Park Hospital

GROUP SUPER SPECIALITY HOSPITAL

## DEPARTMENT OF PATHOLOGY



Patient Name : Mr. PRANAV SOORMA  
 MR No : 30086  
 Age/Sex : 29 Years 4 Months 20 Days / Male  
 Type : OPD  
 TPA/Corporate : MEDIWHEEL

Bill Date : 23/02/2024  
 Reporting Date : 23/02/2024  
 Sample ID : 68053  
 Bill/Req. No. : 24089694  
 Ref Doctor : Dr. CONSULTANT

Test	Result	Bio. Ref. Interval	Units
<b>CBC</b>			
HAEMOGLOBIN	12.4	12 - 16	gm/dL
PACKED CELL VOLUME	40.8	35.0 - 50.0	%
RED BLOOD CELL COUNT	4.61	3.5 - 5.5	millions/ $\mu$ L
MEAN CORPUSCULAR VOLUME	88.5	83 - 101	fL
MEAN CORPUSCULAR HAEMOGLOBIN	<b>26.9 L</b>	27 - 31	pg
MEAN CORPUSCULAR HB CONC	<b>30.4 L</b>	33 - 37	g/dl
RDW	13.1	11.6 - 14.5	%
TOTAL LEUCOCYTE COUNT	8630	4000-11000	/ $\mu$ L
<b>DIFFERENTIAL COUNT</b>			
NEUTROPHILS	64	40.0 - 80.0	%
LYMPHOCYTES	26	20 - 40	%
MONOCYTES	06	2.0 - 10.0	%
EOSINOPHILS	04	0.0 - 5.0	%
BASOPHILS	00	0.0 - 2.0	%
PLATELET COUNT	1.64	1.50 - 4.50	lac/cumm

\*\*\*\*\* END OF THE REPORT \*\*\*\*\*



Sample no.

Dr. VAISHALI YADAV    Dr. REETU JADHAV    Dr. PARDIP KUMAR    S.C. GAUR  
 CONS. PATHOLOGIST    CONS. PATHOLOGIST    MICROBIOLOGIST & ICO    LAB INCHARGE    USER NM    SAMAY

(This is only professional opinion and not the diagnosis, Please correlate clinically)



**DEPARTMENT OF PATHOLOGY**

Patient Name : Mr. PRANAV SOORMA  
MR No : 30086  
Age/Sex : 29 Years 4 Months 20 Days / Male  
Type : OPD  
TPA/Corporate : MEDIWHEEL

Bill Date : 23/02/2024  
Reporting Date : 23/02/2024  
Sample ID : 68053  
Bill/Req. No. : 24089694  
Ref Doctor : Dr. CONSULTANT

Test	Result	Bio. Ref. Interval	Units
<b>BLOOD GROUPING AND rh FACTOR</b>			
BLOOD GROUP	" B " Rh NEGATIVE		

\*\*\*\*\* END OF THE REPORT \*\*\*\*\*



Sample no.

Dr. VAISHALI YADAV    Dr. REETU JADHAV    Dr. PARDIP KUMAR    S.C. GAUR  
CONS. PATHOLOGIST    CONS. PATHOLOGIST    MICROBIOLOGIST & ICO LAB INCHARGE    USER NM SAMAY

(This is only professional opinion and not the diagnosis, Please correlate clinically)

J-Block, Sector-10, Near Court, Faridabad - 121004, Haryana  
Tel.: 0129-4200000 E-mail : parkfaridabad@gmail.com




**DEPARTMENT OF PATHOLOGY**

Patient Name : Mr. PRANAV SOORMA  
MR No : 30086  
Age/Sex : 29 Years 4 Months 20 Days / Male  
Type : OPD  
TPA/Corporate : MEDIWHEEL

Bill Date : 23/02/2024  
Reporting Date : 23/02/2024  
Sample ID : 68053  
Bill/Req. No. : 24089694  
Ref Doctor : Dr. CONSULTANT

Test	Result	Bio. Ref. Interval	Units
<b>BLOOD SUGAR FASTING</b>			
PLASMA GLUCOSE FASTING	92.14	60 - 110	mg/dl

\*\*\*\*\* END OF THE REPORT \*\*\*\*\*



Sample no.

Dr. VAISHALI YADAV    Dr. REETU JADHAV    Dr. PARDIP KUMAR    S.C. GAUR  
CONS. PATHOLOGIST    CONS. PATHOLOGIST    MICROBIOLOGIST & ICO LAB INCHARGE    USER NM SAMAY

(This is only professional opinion and not the diagnosis, Please correlate clinically)

J-Block, Sector-10, Near Court, Faridabad - 121004, Haryana

Tel.: 0129-4200000 E-mail: parkfaridabad@



**DEPARTMENT OF PATHOLOGY**

Patient Name : Mr. PRANAV SOORMA  
MR No : 30086  
Age/Sex : 29 Years 4 Months 20 Days / Male  
Type : OPD  
TPA/Corporate : MEDIWHEEL

Bill Date : 23/02/2024  
Reporting Date : 23/02/2024  
Sample ID : 68053  
Bill/Req. No. : 24089694  
Ref Doctor : Dr. CONSULTANT

Test	Result	Bio. Ref. Interval	Units
<b>LFT (LIVER FUNCTION TEST)</b>			
<b>LFT</b>			
TOTAL BILIRUBIN	0.5	0 - 1.2	mg/dL
DIRECT BILIRUBIN	0.2	0 - 0.4	mg/dL
INDIRECT BILIRUBIN	0.3	0.10 - 0.6	mg/dL
SGOT (AST)	27.1	0 - 45	mg/dL
SGPT (ALT)	25.2	0 - 45	U/L
ALKALINE PHOSPHATASE	49.9	30 - 170	U/L
TOTAL PROTEIN	7.7	6.4 - 8.0	g/dL
ALBUMIN	4.3	3.3 - 5.5	g/dL
GLOBULIN	3.4	2.3 - 4.5	g/dL
A/G RATIO	1.26	1.1 - 2.2	g/dL

\*\*\*\*\* END OF THE REPORT \*\*\*\*\*



Sample no.

Dr. VAISHALI YADAV    Dr. REETU JADHAV    Dr. PARDIP KUMAR    S.C. GAUR  
CONS. PATHOLOGIST    CONS. PATHOLOGIST    MICROBIOLOGIST & ICO LAB INCHARGE    USER NM SAMAY

(This is only professional opinion and not the diagnosis, Please correlate clinically)

J-Block, Sector-10, Near Court, Faridabad - 121004, Haryana

Tel.: 0129-4200000 E-mail : parkfaridabad@gmail.com



**DEPARTMENT OF PATHOLOGY**

Patient Name : Mr. PRANAV SOORMA  
MR No : 30086  
Age/Sex : 29 Years 4 Months 20 Days / Male  
Type : OPD  
TPA/Corporate : MEDIWHEEL

Bill Date : 23/02/2024  
Reporting Date : 23/02/2024  
Sample ID : 68053  
Bill/Req. No. : 24089694  
Ref Doctor : Dr. CONSULTANT

Test	Result	Bio. Ref. Interval	Units
<b>KFT (RENAL PROFILE)</b>			
<b>KFT</b>			
SERUM UREA	21.3	10 - 45	mg/dL
SERUM CREATININE	0.8	0.4 - 1.4	mg/dL
SERUM URIC ACID	5.9	2.5 - 7.0	mg/dL
SERUM SODIUM	139.7	136 - 148	mmol/L
SERUM POTASSIUM	3.8	3.5 - 5.5	mmol/L
CHLORIDE	<b>93.4 L</b> L	96 - 106	mmol/L

\*\*\*\*\* END OF THE REPORT \*\*\*\*\*



Sample no.

Dr. VAISHALI YADAV    Dr. REETU JADHAV    Dr. PARDIP KUMAR    S.C. GAUR  
CONS. PATHOLOGIST    CONS. PATHOLOGIST    MICROBIOLOGIST & ICO LAB INCHARGE    USER NM SAMAY

(This is only professional opinion and not the diagnosis, Please correlate clinically)

J-Block, Sector-10, Near Court, Faridabad - 121004, Haryana

Tel: 0129-4200000 E-mail: parkfaridabad@gmail.com





**DEPARTMENT OF PATHOLOGY**

Patient Name : Mr. PRANAV SOORMA  
MR No : 30086  
Age/Sex : 29 Years 4 Months 20 Days / Male  
Type : OPD  
TPA/Corporate : MEDIWHEEL

Bill Date : 23/02/2024  
Reporting Date : 23/02/2024  
Sample ID : 68053  
Bill/Req. No. : 24089694  
Ref Doctor : Dr.CONSULTANT

Test	Result	Bio. Ref. Interval	Units
<b>LIPID PROFILE</b>			
<b>LIPID PROFILE</b>			
TOTAL CHOLESTEROL	168.65	120.0 - 200.0	mg/dL
SERUM TRIGLYCERIDES	105.37	40.0 - 160.0	mg/dl
HDL-CHOLESTEROL	37.02	30 - 70	mg/dl
VLDL CHOLESTEROL	21.07	6 - 32	mg/dL
LDL	110.56	50 - 135	mg/dl
LDL CHOLESTEROL/HDL RATIO	2.99	1.0 - 3.0	mg/dL
TOTAL CHOLESTEROL/HDL RATIO	4.56	2.0 - 5.0	mg/dl

\*\*\*\*\* END OF THE REPORT \*\*\*\*\*



Sample no.

Dr. VAISHALI YADAV    Dr. REETU JADHAV    Dr. PARDIP KUMAR    S.C. GAUR  
CONS. PATHOLOGIST    CONS. PATHOLOGIST    MICROBIOLOGIST & ICO LAB INCHARGE    USER NM SAMAY

(This is only professional opinion and not the diagnosis, Please correlate clinically)

J-Block, Sector-10, Near Court, Faridabad - 121004, Haryana

Tel : 0129-4200000 E-mail : parkfaridabad@gmail.com



**DEPARTMENT OF PATHOLOGY**

<b>Patient Name</b> :	Mr. PRANAV SOORMA	<b>Bill Date</b> :	23/02/2024
<b>MR No</b> :	30086	<b>Reporting Date</b> :	23/02/2024
<b>Age/Sex</b> :	29 Years 4 Months 20 Days / Male	<b>Sample ID</b> :	68053
<b>Type</b> :	OPD	<b>Bill/Req. No.</b> :	24089694
<b>TPA/Corporate</b> :	MEDIWHEEL	<b>Ref Doctor</b> :	Dr.CONSULTANT

Test	Result	Bio. Ref. Interval	Units
<b>BLOOD SUGAR 2 HR. PP</b>			
BLOOD SUGAR P.P.	97.32	80 - 150	mg/dl

\*\*\*\*\* END OF THE REPORT \*\*\*\*\*



Sample no.

Dr. VAISHALI YADAV    Dr.REETU JADHAV    Dr. PARDIP KUMAR    S.C.GAUR  
CONS.PATHOLOGIST    CONS.PATHOLOGIST    MICROBIOLOGIST & ICO LAB INCHARGE    USER NM DEEPCHAND

(This is only professional opinion and not the diagnosis, Please correlate clinically)

J-Block, Sector-10, Near Court, Faridabad - 121004, Haryana

*[Handwritten signature]*



**DEPARTMENT OF PATHOLOGY**

**Patient Name** : Mr. PRANAV SOORMA  
**MR No** : 30086  
**Age/Sex** : 29 Years 4 Months 20 Days / Male  
**Type** : OPD  
**TPA/Corporate** : MEDIWHEEL

**Bill Date** : 23/02/2024  
**Reporting Date** : 23/02/2024  
**Sample ID** : 68053  
**Bill/Req. No.** : 24089694  
**Ref Doctor** : Dr.CONULTANT

Test	Result	Bio. Ref. Interval	Units
------	--------	--------------------	-------

**URINE ROUTINE AND MICROSCOPY**

**PHYSICAL CHARACTERSTICS**

QUANTITY	30.0 ML	5 - 100	ML
COLOUR	Pale Yellow		
TURBIDITY	TURBID	clear	
SPECIFIC GRAVITY	1.000	1.003 - 1.030	
PH	5.0	Acidic	

**CHEMICAL EXAMINATION-1**

URINE PROTEIN	TRACE	NIL	
GLUCOSE	NIL	NIL	

**MICRO.EXAMINATION**

PUS CELL	10 - 15/HPF		CELLS/HPF
RED BLOOD CELLS	Nil	0-2	CELLS/HPF
EPITHELIAL CELLS	1-2/HPF	0-5	CELLS/HPF
CASTS	NIL	NIL	CELLS/HPF
CRYSTALS	NIL	NIL	CELLS/HPF
OTHER	NIL		

\*\*\*\*\* END OF THE REPORT \*\*\*\*\*



Sample no.

Dr. VAISHALI YADAV    Dr.REETU JADHAV    Dr. PARDIP KUMAR    S.C.GAUR  
CONS.PATHOLOGIST    CONS.PATHOLOGIST    MICROBIOLOGIST & ICO    LAB INCHARGE    USER NM    DEEPCHAND

(This is only professional opinion and not the diagnosis, Please correlate clinically)

J-Block, Sector-10, Near Court, Faridabad - 121004, Haryana



**DEPARTMENT OF RADIOLOGY**

Patient Name	Mr PRANAV SOORMA	Billed Date	: 23/02/2024	9.38 AM
Reg No	30086	Reported Date	: 23/02/2024	
Age/Sex	29 Years 4 Months 20Days / Male	Req. No.	: 24089694	
Type	OPD	Consultant Doctor	: Dr. CONSULTANT	

**X-RAY CHEST AP/PA**

Bilateral lungs appears normal.

Both hila are normal in size, have equal density and bear normal relationship.

The heart and trachea are central in position and no mediastinal abnormality is visible.

The cardiac size is normal for patient age and view.

The domes of the diaphragms are normal in position and show smooth outline.

**To be correlated clinically**

DR BINOD KR CHAUDHARY  
MBBS,MD  
CONSULTANT RADIOLOGIST

(This is only professional opinion and not the diagnosis, Please correlate clinically)

J-Block, Sector-10, Near Court, Faridabad - 121004, Haryana

Tel.: 0129-4200000 E-mail : parkfaridabad@gmail.com



## DEPARTMENT OF RADIOLOGY

Patient Name	Mr PRANAV SOORMA	Billed Date	: 23/02/2024	9.38 AM
Reg No	30086	Reported Date	: 23/02/2024	
Age/Sex	29 Years 4 Months 20Days / Male	Req. No.	: 24089694	
Type	OPD	Consultant Doctor	: Dr. CONSULTANT	

### USG WHOLE ABDOMEN

**LIVER** : The liver is normal in size, shape and echotexture. No evidence of any focal lesion. IHBR is NOT dilated. Portal vein is normal.

**GALL BLADDER** :The gall bladder is well distended. No evidence any calculus or mass seen. GB wall thickness with in normal limits. No evidence of pericholecystic fluid is seen. The common bile duct is normal.

**SPLEEN** :The spleen is normal in size and shape. Its echotexture is homogeneous. No evidence of focal lesion is noted. Splenic vein is normal.

**PANCREAS** :The pancreas is normal in size, shape, contours and echotexture.

**BILATERAL KIDNEYS** : The bilateral kidneys are normal in size and echotexture. Cortico-medullary differentiation is maintained. There is no evidence of obvious calculus or hydronephrosis seen.

**URINARY BLADDER** :The urinary bladder is well distended. Wall thickness within normal limits. No evidence of calculus is seen. No evidence of mass or diverticulum is noted.


**PROSTATE**: Prostate appears normal in size, shape and echotexture.

No free fluid is seen in peritoneal cavity.

No evidence of obvious retroperitoneal or mesenteric lymphadenopathy is seen.

**IMPRESSION:- USG WHOLE ABDOMEN REVEALS NO OBVIOUS ABNORMALITY.**

**TO BE CORRELATED CLINICALLY.**

  
DR BINOD KR CHAUDHARY  
MBBS,MD  
CONSULTANT RADIOLOGIST

(This is only professional opinion and not the diagnosis, Please correlate clinically)

J-Block, Sector-10, Near Court, Faridabad - 121004, Haryana  
Tel.: 0129-4200000 E-mail : parkfaridabad@gmail.com



## ECHO REPORT

Name of the patient: MR. PRANAV SOORMA Age: 29 Sex:  Male  Female

UHID No: 30086 <sup>Bill No</sup> 24089694 <sup>IPD No:</sup> 24089694 Date: 23/2/24

Refer By Doctor: DR. RAKESH ARORA

LVEF% 60-1

### 2D ECHO

> Mitral Value Normal Pulmonary Value N Pulm  
> Artery N  
> Aortic aive N Tricuspid valve N

### 2D RWMA

> NO RWMA (Regional wall motion abnormality) at rest

### COLD DOPPLER

> NO Significant Vavular stenosis / Regurgiation

### COMMENTS AND SUMMARY

> All cardiac chambers of N size and shape NO dilatation or hypertrophy.  
> NO RWMA (Regional wall motion abnormality) at rest  
> NO Cloth / Vegetation / pericardial effusion  
> LV -60-1 Systolic function  
> NO Significant Vavular stenosis / Regurgiation

### Final Impression

> EF at Rest 60-1

COMMENTS 2 DECUO & Color Doppler study was

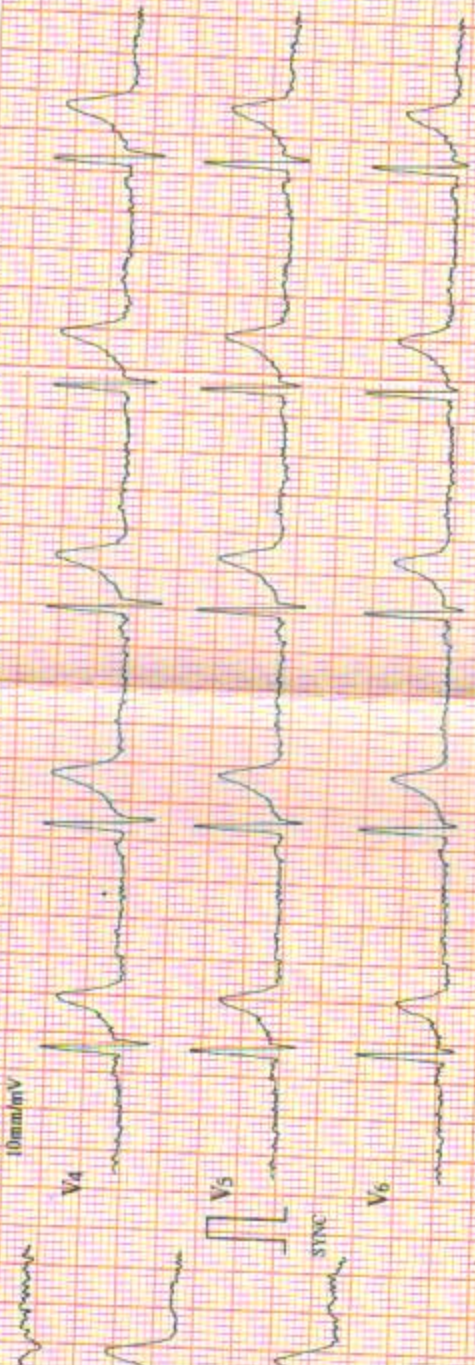### Consultant Cardiology

Doctor Name : Dr.  
Date :

Rakesh Kumar Arora  
M.D. (D. Cardiology)  
18292  
Cardiology  
Fundaand

Signature  
Time

10mm/mV



ID : 4103

Name :

Sex :

Age :

HR : 51  
 PR : 170  
 P-R : 130  
 QRS : 108  
 QT/QTc : 402/371  
 P/QRS/T : 24/75/68  
 RV5/SVL : 1.00/0.560 mV  
 RV5/SVL : 1.060 mV

----- Sinus Bradycardia  
 ----- Unspecified ST-T Abnormality

PRANAV SORMA

Unconfirmed report verified by: **CARDIOPRINT**