

DR. NETRAVALKAR'S ASHWINI PATHOLOGY LABORATORY

(For all investigations in Histopathology, Cytopathology, Haematology, Clinical Pathology, Microbiology & Hormonal Chemistry)

Consultant Pathologist : **Dr. Prasad Netravalkar** MBBS, MD. (Path) BOM

(HOME COLLECTION FACILITY AVAILABLE)

Panaji : 1st, Floor, Rizvi Sadan, Above Saroj Emporium, Near Inox Theatre, Opp. Municipal Market, Panaji.

Ph.: 2229142, 8407912840, 8390242524

E-mail : ashwinilabpanaji@gmail.com, drprasadnetravalkar@gmail.com

Mapusa : F8, Ramchandra Chambers, 1st Floor, Mapusa Clinic Road, Mapusa - Bardez, Goa. Ph.: 2252320

Pt.No. : 69 100824

Pt.Name : - Sangeeta Alias M A Vaingankar

Age : 54 Yrs. Sex : F

Ref. By : -

Date : 10-08-2024

Normal Range

COMPLETE HEMOGRAM

Haemoglobin	: 12.4	g/dl	11.5 - 16.5 g/dl
W.B.C Count	: 7200	cells/ cu-mm	4000 - 11000 cells/ cu-mm
R.B.C Count	: 5.54	millions / cu-mm	3.8 - 4.5 millions / cu-mm
MCV	: 70.7	fl	80 - 99 fl
MCH	: 22.4	Pg	27 - 33 Pg
MCHC	: 31.7	%	32 - 37 %
PCV	: 39.2	%	37 - 47 %
Platelet Count	: 3.27	lakhs /cu mm	1.5 - 4.5 lakhs /cu mm
E.S.R (Westergren)	: 25	mm/hr	0 - 20 mm/hr

DIFFERENTIAL COUNT

Stab Cells	: 03	%	1-5 %
Neutrophils	: 48	%	40- 60 %
Lymphocytes	: 38	%	20 - 45 %
Eosinophils	: 04	%	1 - 6 %
Monocytes	: 07	%	0 - 10 %
Basophils	: 00	%	0 - 1 %
Abnormal Cells	: Nil		

SMEAR EXAMINATION

RBC Morphology	: Normocytic , Normochromic
W.B.C Morphology	: Within Normal Limits
Platelets on Smear	: Adequate
Parasites	: Absent
Blood Group	: 'A' Rh Positive



Dr. Prasad Netravalkar

MBBS, MD (Bom)
GMC Reg. No. 1294

We Care

All Diagnostic facilities under one roof in Panaji centre - Lab, ultrasound, X ray, ECG, TMT, ECHO

DR. NETRAVALKAR'S ASHWINI PATHOLOGY LABORATORY

(For all investigations in Histopathology, Cytopathology, Haematology, Clinical Pathology, Microbiology & Hormonal Chemistry)

Consultant Pathologist : **Dr. Prasad Netravalkar** MBBS, MD. (Path) BOM

(HOME COLLECTION FACILITY AVAILABLE)

Panaji : 1st, Floor, Rizvi Sadan, Above Saroj Emporium, Near Inox Theatre, Opp. Municipal Market, Panaji.
Ph.: 2229142, 8407912840, 8390242524

E-mail : ashwinilabpanaji@gmail.com, drprasadnetravalkar@gmail.com

Mapusa : F8, Ramchandra Chambers, 1st Floor, Mapusa Clinic Road, Mapusa - Bardez, Goa. Ph.: 2252320

Pt.No. : 69 100824

Pt.Name : - Sangeeta Alias M A Vaingankar

Age : 54 Yrs. Sex : F

Ref. By : -

Date : 10-08-2024

EXAMINATION OF URINE

PHYSICAL EXAMINATION

Quantity : 20 ml
Colour : Pale Yellow
Appearance : Slightly Hazy
pH : 6.5
Specific Gravity : 1.010

CHEMICAL EXAMINATION

Proteins : Absent
Glucose : Absent
Ketone Bodies : Absent
Bile Salts : Absent
Bile Pigments : Absent
Occult Blood : Negative
Urobilinogen : Normal

MICROSCOPIC EXAMINATION [As per hpf]

Epithelial Cells : 10 - 12 /hpf
Pus Cells : 2 - 3 /hpf
Red Blood Cells : Absent
Casts : Absent
Crystals : Absent



Pathologist

Dr. Prasad Netravalkar
MBBS, MD (Bom)
GMC Reg. No. 1294

We Care

All Diagnostic facilities under one roof in Panaji centre - Lab, ultrasound, X ray, ECG, TMT, ECHO

**DR. NETRAVALKAR'S
ASHWINI PATHOLOGY LABORATORY**

(For all investigations in Histopathology, Cytopathology, Haematology, Clinical Pathology, Microbiology & Hormonal Chemistry)

Consultant Pathologist : **Dr. Prasad Netravalkar** MBBS, MD. (Path) BOM.

(HOME COLLECTION FACILITY AVAILABLE)

Panaji : 1st, Floor, Rizvi Sadan, Above Saroj Emporium, Near Inox Theatre, Opp. Municipal Market, Panaji.
Ph.: 2229142, 8407912840, 8390242524

E-mail : ashwinilabpanaji@gmail.com, drprasadnetravalkar@gmail.com

Mapusa : F8, Ramchandra Chambers, 1st Floor, Mapusa Clinic Road, Mapusa - Bardez, Goa. Ph.: 2252320

Pt.No. : 69 100824

Pt.Name : - Sangeeta Alias M A Vaingankar

Age : 54 Yrs. Sex : F

Ref. By : -

Date : 10-08-2024

		Normal Range
Fasting Blood Sugar	: 98.0 mg/dl	70-110 mg/dl
2 Hrs. Blood Sugar	: 118.0 mg/dl	110-140 mg/dl

GLYCOSYLATED HAEMOGLOBIN IN BLOOD (HPLC METHOD)

HbA1C : **7.30** %

Mean Blood Glucose : **162** mg %

INTERPRETATION:

HbA1c %

NORMAL

Below 6.5 %

GOOD DIABETIC CONTROL

6.5 % - 7.5 %

FAIR CONTROL

7.5 % - 8.0 %

UNSATISFACTORY CONTROL

8.0 % - 10.0 %

POOR CONTROL

Above 10.0 %

Pathologist



Dr. Prasad Netravalkar
MBBS, MD (Bom)
GMC Reg. No. 1294

We Care

All Diagnostic facilities under one roof in Panaji centre - Lab, ultrasound, X ray, ECG, TMT, ECHO

DR. NETRAVALKAR'S ASHWINI PATHOLOGY LABORATORY

(For all investigations in Histopathology, Cytopathology, Haematology, Clinical Pathology, Microbiology & Hormonal Chemistry)

Consultant Pathologist : **Dr. Prasad Netravalkar** MBBS, MD. (Path) BOM.

(HOME COLLECTION FACILITY AVAILABLE)

Panaji : 1st, Floor, Rizvi Sadan, Above Saroj Emporium, Near Inox Theatre, Opp. Municipal Market, Panaji.

Ph.: 2229142, 8407912840, 8390242524

E-mail : ashwinilabpanaji@gmail.com, drprasadnetravalkar@gmail.com

Mapusa : F8, Ramchandra Chambers, 1st Floor, Mapusa Clinic Road, Mapusa - Bardez, Goa. Ph.: 2252320

Pt.No. : 69 100824

Pt.Name : - Sangeeta Alias M A Vaingankar

Age : 54 Yrs. Sex : F

Ref. By : -

Date : 10-08-2024

		<u>Normal Range</u>
Fasting Blood Sugar	: 98.0 mg/dl	70-110 mg/dl
2 Hrs. Blood Sugar	: 118.0 mg/dl	110-140 mg/dl

GLYCOSYLATED HAEMOGLOBIN IN BLOOD (HPLC METHOD)

HbA1C : **7.30** %

Mean Blood Glucose : **162** mg %

INTERPRETATION:

	HbA1c %
NORMAL	Below 6.5 %
GOOD DIABETIC CONTROL	6.5 % - 7.5 %
FAIR CONTROL	7.5 % - 8.0 %
UNSATISFACTORY CONTROL	8.0 % - 10.0 %
POOR CONTROL	Above 10.0 %



[Handwritten Signature]
10/8/24
Pathologist

Dr. Prasad Netravalkar
MBBS, MD (Bom)
GMC Reg. No. 1294

We Care

All Diagnostic facilities under one roof in Panaji centre - Lab, ultrasound, X ray, ECG, TMT, ECHO

DR. NETRAVALKAR'S ASHWINI PATHOLOGY LABORATORY

(For all investigations in Histopathology, Cytopathology, Haematology, Clinical Pathology, Microbiology & Hormonal Chemistry)

Consultant Pathologist : **Dr. Prasad Netravalkar** MBBS, MD. (Path) BOM.

(HOME COLLECTION FACILITY AVAILABLE)

Panaji : 1st, Floor, Rizvi Sadan, Above Saroj Emporium, Near Inox Theatre, Opp. Municipal Market, Panaji.
Ph.: 2229142, 8407912840, 8390242524

E-mail : ashwinilabpanaji@gmail.com, drprasadnetravalkar@gmail.com

Mapusa : F8, Ramchandra Chambers, 1st Floor, Mapusa Clinic Road, Mapusa - Bardez, Goa. Ph.: 2252320

Pt.No. : 69 100824

Pt.Name : - Sangeeta Alias M A Vaingankar

Age : 54 Yrs. Sex : F

Ref. By : -

Date : 10-08-2024

		<u>Normal Range</u>
Fasting Blood Sugar	: 98.0 mg/dl	70-110 mg/dl
2 Hrs. Blood Sugar	: 118.0 mg/dl	110-140 mg/dl

GLYCOSYLATED HAEMOGLOBIN IN BLOOD (HPLC METHOD)

HbA1C : 7.30 %

Mean Blood Glucose : 162 mg %

INTERPRETATION:

	HbA1c %
NORMAL	Below 6.5 %
GOOD DIABETIC CONTROL	6.5 % - 7.5 %
FAIR CONTROL	7.5 % - 8.0 %
UNSATISFACTORY CONTROL	8.0 % - 10.0 %
POOR CONTROL	Above 10.0 %



[Handwritten Signature]
10/8

Pathologist

Dr. Prasad Netravalkar
MBBS, MD (Bom)
GMC Reg. No. 1294

We Care

All Diagnostic facilities under one roof in Panaji centre - Lab, ultrasound, X ray, ECG, TMT, ECHO

DR. NETRAVALKAR'S ASHWINI PATHOLOGY LABORATORY

(For all investigations in Histopathology, Cytopathology, Haematology, Clinical Pathology, Microbiology & Hormonal Chemistry)

Consultant Pathologist : **Dr. Prasad Netravalkar** MBBS, MD. (Path) BOM.

(HOME COLLECTION FACILITY AVAILABLE)

Panaji : 1st, Floor, Rizvi Sadan, Above Saroj Emporium, Near Inox Theatre, Opp. Municipal Market, Panaji.

Ph.: 2229142, 8407912840, 8390242524

E-mail : ashwinilabpanaji@gmail.com, drprasadnetravalkar@gmail.com

Mapusa : F8, Ramchandra Chambers, 1st Floor, Mapusa Clinic Road, Mapusa - Bardez, Goa. Ph.: 2252320

Pt.No. : 69 100824

Pt.Name : - Sangeeta Alias M A Vaingankar

Age : 54 Yrs. Sex : F

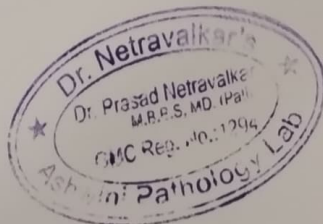
Ref. By : -

Date : 10-08-2024

Normal Range

LIPID PROFILE

Total Cholesterol	: 229.0 mg/dl	130 - 220 mg/dl
S. Triglycerides	: 128.0 mg/dl	35 - 170 mg/dl
HDL Cholesterol	: 38.0 mg/dl	> 45 mg/dl
LDL Cholesterol	: 165 mg/dl	< 130 mg/dl
VLDL Cholesterol	: 26 mg/dl	Upto 35 mg/dl
TC/HDLC Ratio	: 6	< 4.5
LDLC/HDLC Ratio	: 4.3	2.5 - 3.5



Pathologist

Dr. Prasad Netravalkar
MBBS, MD (Bom)
GMC Reg. No. 1294

We Care

All Diagnostic facilities under one roof in Panaji centre - Lab, ultrasound, X ray, ECG, TMT, ECHO

DR. NETRAVALKAR'S ASHWINI PATHOLOGY LABORATORY

(For all investigations in Histopathology, Cytopathology, Haematology, Clinical Pathology, Microbiology & Hormonal Chemistry)
Consultant Pathologist : **Dr. Prasad Netravalkar** MBBS, MD (Path) BOM.

(HOME COLLECTION FACILITY AVAILABLE)

Panaji : 1st, Floor, Rizvi Sadan, Above Saroj Emporium, Near Inox Theatre, Opp. Municipal Market, Panaji.
Ph.: 2229142, 8407912840, 8390242524

E-mail : ashwinilabpanaji@gmail.com, drprasadnetravalkar@gmail.com

Mapusa : F8, Ramchandra Chambers, 1st Floor, Mapusa Clinic Road, Mapusa - Bardez, Goa. Ph.: 2252320

Pt.No. : 69 100824

Pt.Name : - Sangeeta Alias M A Vaingankar

Age : 54 Yrs. Sex : F


Ref. By : -

Date : 10-08-2024

Normal Range

LIVER FUNCTION TEST

S. Bilirubin (Total)	: 0.32	mg/dl	0 - 1 mg/dl
S. Bilirubin (Direct)	: 0.20	mg/dl	0 - 0.25 mg/dl
S. Bilirubin (Indirect)	: 0.12	mg/dl	0 - 0.75 mg/dl
S.G.O.T	: 27.0	U/L	0 - 42 U/L
S.G.P.T	: 38.0	U/L	0 - 42 U/L
S. Alkaline Phosphatase	: 36.0	IU/L	15 - 112 IU/L
GGTP	: 21.0	U/L	9-37 U/L
Total Proteins	: 6.50	g/dl	6.0 - 10.0 g/dl
S. Albumin	: 3.75	gm%	3.2 - 5.5 gm%
S. Globulin	: 2.8	g/dl	2.3 - 3.5 g/dl
A/G Ratio	: 1.4 : 1		



Pathologist

Dr. Prasad Netravalkar
MBBS, MD (Bom)
GMC Reg. No. 1294

We Care

All Diagnostic facilities under one roof in Panaji centre - Lab, ultrasound, X ray, ECG, TMT, ECHO

DR. NETRAVALKAR'S ASHWINI PATHOLOGY LABORATORY

(For all investigations in Histopathology, Cytopathology, Haematology, Clinical Pathology, Microbiology & Hormonal Chemistry)

Consultant Pathologist : **Dr. Prasad Netravalkar** MBBS, MD. (Path) BOM.

(HOME COLLECTION FACILITY AVAILABLE)

Panaji : 1st, Floor, Rizvi Sadan, Above Saroj Emporium, Near Inox Theatre, Opp. Municipal Market, Panaji.
Ph.: 2229142, 8407912840, 8390242524

E-mail : ashwinilabpanaji@gmail.com, drprasadnetravalkar@gmail.com

Mapusa : F8, Ramchandra Chambers, 1st Floor, Mapusa Clinic Road, Mapusa - Bardez, Goa. Ph.: 2252320

Pt.No. : 69 100824

Pt.Name : - Sangeeta Alias M A Vaingankar


Ref. By : -

Age : 54 Yrs. Sex : F

Date : 10-08-2024

Normal Range

<u>KIDNEY FUNCTION TESTS</u>		
Blood Urea	: 24.0 mg/dl	15 - 40 mg/dl
S. Creatinine	: 0.88 mg/dl	0.5 - 1.2 mg/dl
S. Uric Acid.	: 6.40 mg/dl	1.5 - 6.0 mg/dl
S. Sodium	: 141.6 mEq/L	135 - 155 mEq/L
S. Potassium	: 3.89 mEq/L	3.5 - 5.5 mEq/L
S. Chlorides	: 101.2 mEq/L	99 - 108 mEq/L



Pathologist

Dr. Prasad Netravalkar
MBBS, MD (Bom)
GMC Reg. No. 1294

We Care

All Diagnostic facilities under one roof in Panaji centre - Lab, ultrasound, X ray, ECG, TMT, ECHO

**DR. NETRAVALKAR'S
ASHWINI PATHOLOGY LABORATORY**

Investigations in Histopathology, Cytopathology, Haematology, Clinical Pathology, Microbiology & Hormonal Chemistry)
Consultant Pathologist : **Dr. Prasad Netravalkar** MBBS, MD. (Path) BOM.

(HOME COLLECTION FACILITY AVAILABLE)

Panaji : 1st, Floor, Rizvi Sadan, Above Saroj Emporium, Near Inox Theatre, Opp. Municipal Market, Panaji.
Ph.: 2229142, 8407912840, 8390242524

E-mail : ashwinilabpanaji@gmail.com, drprasadnetravalkar@gmail.com

Mapusa : F8, Ramchandra Chambers, 1st Floor, Mapusa Clinic Road, Mapusa - Bardez, Goa. Ph.: 2252320

Pt.No. : 69 100824

Pt.Name : - Sangeeta Alias M A Vaingankar

Age : 54 Yrs. Sex : F


Ref. By : -


Date : 10-08-2024

BIOCHEMISTRY REPORTS

Fasting Urine Glucose : Absent

2 Hrs. Urine Glucose : Absent




Pathologist

Dr. Prasad Netravalkar
MBBS, MD (Bom)
GMC Reg. No. 1294

We Care

All Diagnostic facilities under one roof in Panaji centre - Lab, ultrasound, X ray, ECG, TMT, ECHO

x-ray

DR. NETRAVALKAR'S ASHWINI PATHOLOGY LABORATORY

(For all investigations in Histopathology, Cytopathology, Haematology, Clinical Pathology, Microbiology & Hormonal Chemistry)

Consultant Pathologist : **Dr. Prasad Netravalkar** MBBS, MD. (Path) BOM.

(HOME COLLECTION FACILITY AVAILABLE)

Panaji : 1st, Floor, Rizvi Sadan, Above Saroj Emporium, Near Inox Theatre, Opp. Municipal Market, Panaji.

Ph.: 2229142, 8407912840, 8390242524

E-mail : ashwinilabpanaji@gmail.com, drprasadnetravalkar@gmail.com

Mapusa : F8, Ramchandra Chambers, 1st Floor, Mapusa Clinic Road, Mapusa - Bardez, Goa. Ph.: 2252320

Patient Name : SANGEETA ALIAS M A VAINGANAKR

Age / Gender : 54 / Male

Patient ID : 34127

Source : DIRECT

Referral : SELF

Reporting Time : Aug 10, 2024, 01:35 p.m.

Sample ID :




242230007

Test Description	Value(s)	Reference Range	Unit
Thyroid Profile			
T3 (Total) Method : Serum ECL	2.24	1.30 - 3.10	nmol/l
T4 (Total)* Method : Serum ECL	47.36	66.0 - 181.0	nmol/l
TSH(Ultrasensitive)* Method : Srum ECL	36.0	0.270 - 4.20	uIU/ml

END OF REPORT

Pathologist



Dr. Prasad Netravalkar
MBBS, MD (Bom)
GMC Reg. No. 1294

We Care

All Diagnostic facilities under one roof in Panaji centre - Lab, ultrasound, X ray, ECG, TMT, ECHO



नाम: संगीता अलायस एम.ए. वायगणकर

Name : SANGEETA ALIAS M. A. VAIGANKAR

पदनाम / Designation **पार्ट टाइम स्वीपर / Part Time Sweeper**

 कर्मचारी क्र. / Employee No. **645199**

 जन्म तिथि / Birth Date: **22/08/1971**

 रक्त ग्रुप / Blood Group: **A+**



 हस्ताक्षर / Signature

जारी करने का स्थान - क्षेत्रीय कार्यालय, गोवा


 Place of Issue - **REGIONAL OFFICE - GOA**

 जारी करने की तारीख / Date of Issue - **01/07/2020**



 जारीकर्ता प्राधिकारी / Issuing Authority

Handwritten signature




CERTIFICATE OF MEDICAL FITNESS

This is to certify that I have conducted the clinical examination


of Sangeeta Alias M.A Vaigankar 10/8/24

After reviewing the medical history and on clinical examination it has been found that he/she is

	Tick
<ul style="list-style-type: none">• Medically Fit	<input checked="" type="checkbox"/>
<ul style="list-style-type: none">• Fit with restrictions/recommendations <p>Though following restrictions have been revealed, in my opinion, these are not impediments to the job.</p> <p>1.....</p> <p>2.....</p> <p>3.....</p> <p>However the employee should follow the advice/medication that has been communicated to him/her.</p> <p>Review after _____</p>	
<ul style="list-style-type: none">• Currently Unfit. <p>Review after _____ recommended</p>	
<ul style="list-style-type: none">• Unfit	

Dr. 
Medical Officer
The Apollo Clinic, (Location)


This certificate is not meant for medico-legal purposes



MER- MEDICAL EXAMINATION REPORT

Date of Examination	10/8/24		
NAME	Sangeeta Alia Na Naugen		
AGE	54	Gender	female
HEIGHT(cm)	149	WEIGHT (kg)	68kg
B.P.	116/74 mmHg		
ECG	Normal		
X Ray	Normal		
Vision Checkup	Color Vision : Normal		
	Far Vision Ratio : 6/6		
	Near Vision Ratio : 6/6		
Present Ailments	No		
Details of Past ailments (If Any)	No		
Comments / Advice : She /He is Physically Fit	fit		

Signature with Stamp of Medical Examiner



201,202,203, Rizvi Sadan, 2nd Floor, Near Municipal Market, Next to Vaidya Hospital, Panaji - Goa.
Tel.: 0832 2238122 | Email : drashanetravalkar@gmail.com

Cardiology Report

Page 1/2

ASHWINI LABORATORY

Patient / Exam Information

Date of Exam: **13.08.2024**

Patient ID	VS8802280-24-08-13-1	Height
Name	SANGEETA VAINGANKAR 54	Weight
DOB, Age		BSA
Sex	Other	HR

Perf. Phys.	Ref. Phys.	Sonographer
Comment	Indication	

M-Mode Measurements	Value	m1	m2	m3	m4	m5	m6	Meth.
AV/IA								
Ao Root Diam.	2.70 cm	2.70						avg.
LA Diam.	2.80 cm	2.80						avg.
Left Ventricle								
IVSd	0.75 cm	0.75						avg.
LVDd	4.39 cm	4.39						avg.
LVPWd	1.05 cm	1.05						avg.
IVSs	1.55 cm	1.55						avg.
LVDs	2.95 cm	2.95						avg.
LVPWs	0.70 cm	0.70						avg.
EDV (Teich)	87.221 ml	87.221						
EDV (Cubed)	84.605 ml	84.605						
ESV (Teich)	33.590 ml	33.590						
ESV (Cubed)	25.672 ml	25.672						
SV (Teich)	53.631 ml	53.631						
SV (Cube)	58.933 ml	58.933						
EF (Teich)	61.49 %	61.49						
EF (Cube)	69.66 %	69.66						
Fract. Short.	32.80 %	32.80						
LV Mass	145.08 g	145.08						

2D Generic	Value	m1	m2	m3	m4	m5	m6	Meth.
Dist.								
D	4.02 cm	4.02						avg.

1 / 2
13.08.2024 10:34:30 AM

Netravalkar's ging Centre

Dr. Ashadevi Netravalkar

MBBS., MD, AFIH

Consultant Radiologist & Sonologist

201,202,203, Rizvi Sadan, 2nd Floor, Near Municipal Market, Next to Vaidya Hospital, Panaji - Goa.
Tel.: 0832 2238122 | Email : drashanetravalkar@gmail.com

Name: **SANGEETA VAINGANKAR 54**

Patient ID: **VS8802280-24-08-13-1**

Comment

NON-DILATED AND NON-HYPERTROPHIED LEFT VENTRICLE WITH PRESERVED EJECTION FRACTION.
NO REGIONAL WALL MOTION ABNORMALITIES. VALVES ARE GROSSLY NORMAL. AORTIC ROOT IS NORMAL.
PERICARDIUM IS NORMAL.

Aue b

Date: **13.08.2024**

Perf. Physician: _____

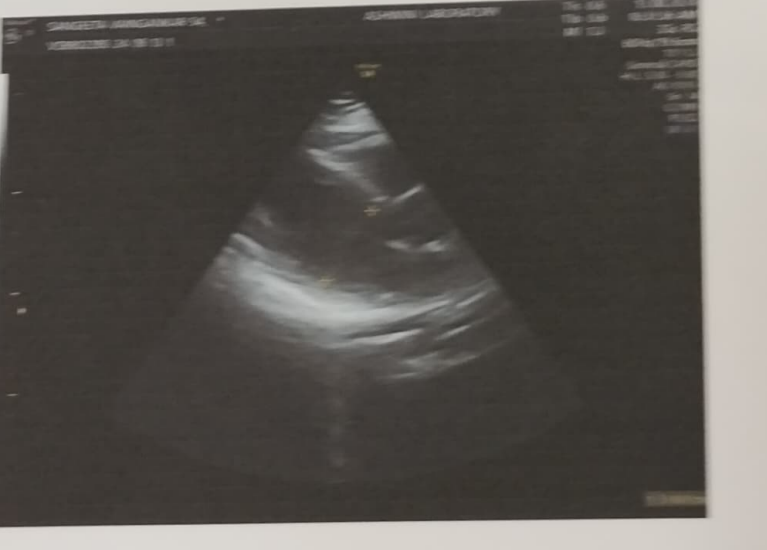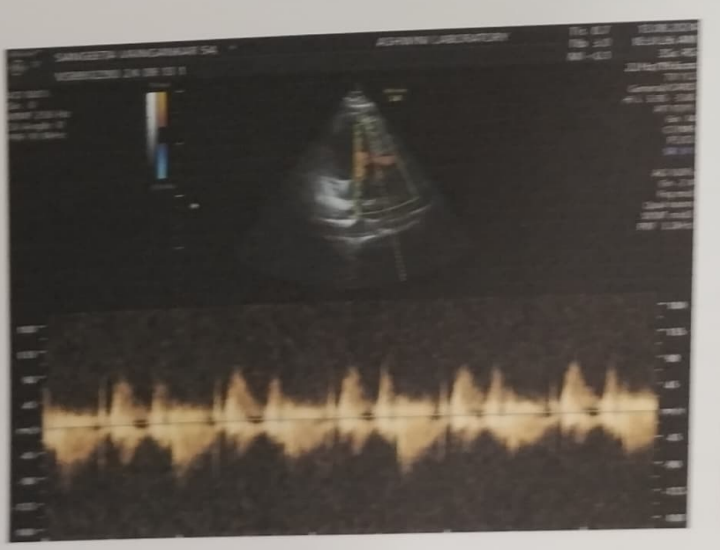
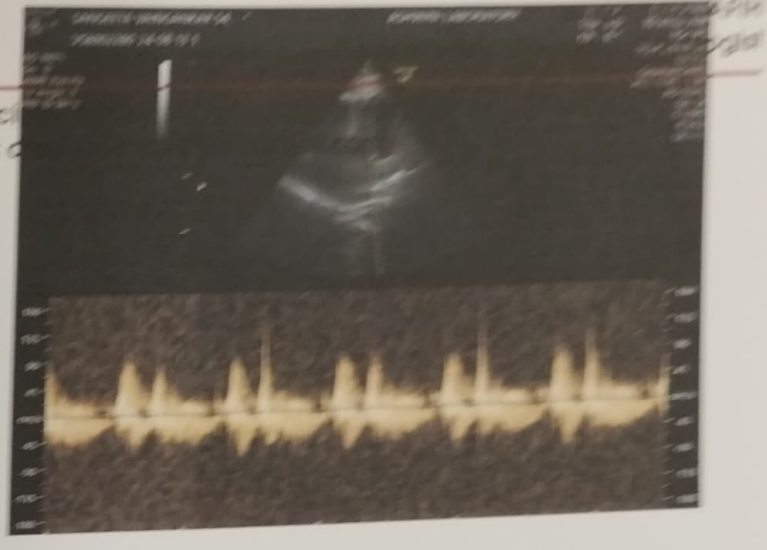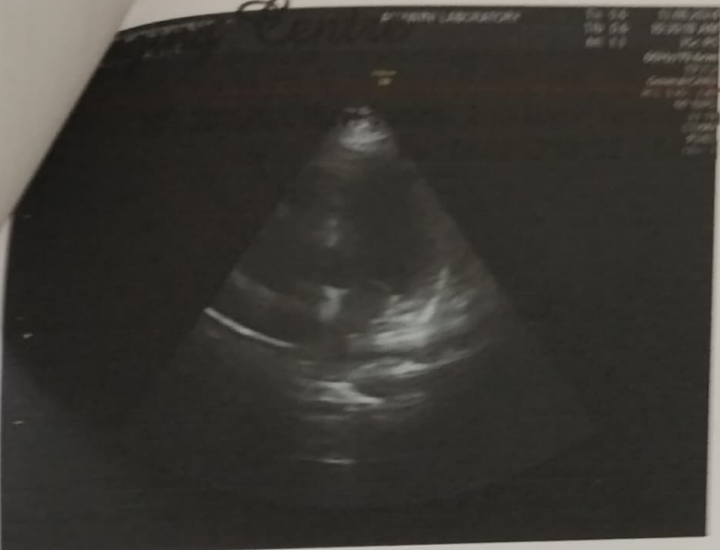Sonographer: _____

2/2

13.08.2024 10:34:30 AM

■ Sonography ■ Digital X-ray ■ Echocardiography ■ TMT Stress Test ■ ECG ■ Audiometry ■ Spirometry

Timing : 8.00 am to 1.00 pm | 4.00 pm to 7.00 pm



201,202,203, Rizvi Sadan, 2nd Floor, Near Municipal Market, Next to Vaidya Hospital, Panaji - Goa.
Tel.: 0832 2238122 | Email : drashanetravalkar@gmail.com

NAME: MRS .SANGEETA VAINGANKAR
AGE: 54/YRS
REF BY: SELF

DATE: 10/08/2024
SEX: F

ULTRASONOGRAPHY OF ABDOMEN AND PELVIS

LIVER – It shows increased echotexture and normal size. Intrahepatic biliary and portal radicals appear normal. Length of liver is 13.4cm.PV -9mm.

PANCREAS— It shows normal echotexture and size. No focal lesions are seen.

GALL BLADDER---It is not well distended. Lumen is not seen entirely . CBD is 2mm.

SPLEEN----- It shows normal echotexture and size. Length of spleen is 7.9cm

BOTH KIDNEYS show normal echotexture and size. Corticomedullary differentiation is seen well. No calculus or hydronephrosis is seen in both kidneys. Perirenal space is normal.

Right kidney--measures 9.9cm x 3.3cms .

Left kidney—measures 11cms x4.5cms.

Urinary Bladder is well distended.No calculus and mass is seen.Both vesicoureteric junctions are normal.

UTERUS : It is anteverted and It measures 8.8cms x 4cms x 3.8cms.

Myometrium show normal echotexture .A fibroid measuring 1.5cm is seen in fundus.

Endometrial thickness is 9mm.

Both ovaries show normal echotexture and size.

Right ovary—measures 3.1ms x .1.4 cms.

Left ovary -measures 3.2cms x 1.5cms .

No adnexal mass is seen.No free fluid is seen in pelvis .Plenty of bowel gases are seen.

Impression : FATTY LIVER-GRADE-1.
SMALL UTERINE FIBROID.

With regards,

DR.ASHADEVI NETRAVALKAR,MD
RADIOLOGIST

DR.ASHADEVI NETRAVALKAR
MBBS, MD, AFIH
Consultant Radiologist
2nd Floor, Rizvi Sadan Panaji
Tel: 0832-2238122 / 9822125224

201, 202, 203, Rizvi Sadan, 2nd Floor, Near Municipal Market, Next to Vaidya Hospital, Panaji - Goa.
Tel.: 0832 2238122 | Email : drashanetravalkar@gmail.com

NAME: MRS.SANGEETA VAINGANKAR
AGE: 54/YRS
REF BY: SELF

DATE: 10/08/2024
SEX: F


SONOMAMMOGRAPHY OF BOTH BREASTS

BOTH BREASTS:

Normal fibroglandular and fatty tissue is seen.
Grossly no mass or calcification or cystic lesion is seen.
Axillary tail and areolar region appears normal.
No lymphnodes are seen in axillary region.

Impression : Normal study.

With regards,



DR.ASHADEVI NETRAVALKAR, MD
RADIOLOGIST

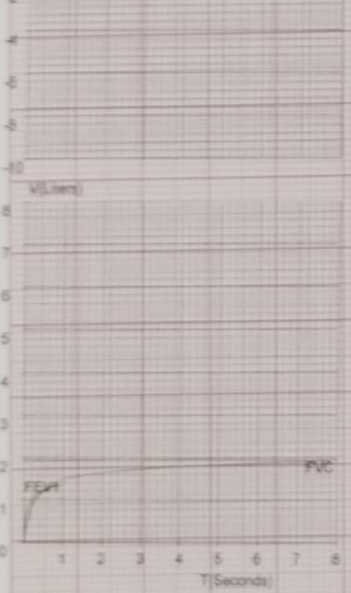
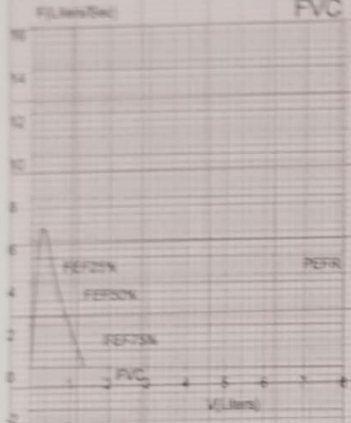
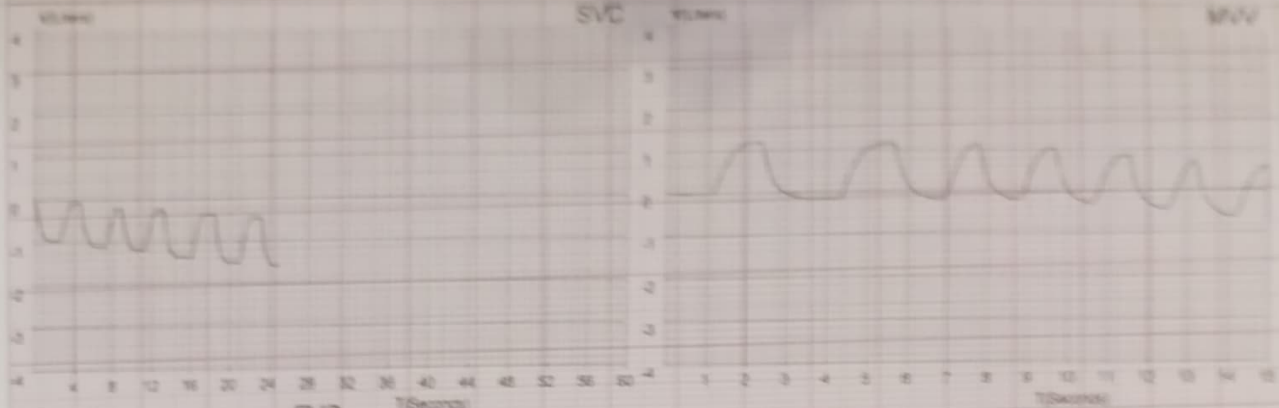
DR. ASHADEVI NETRAVALKAR
MBBS, MD, AFIH
Consultant Radiologist
2nd Floor, Rizvi Sadan Panaji
Tel: 0832-2238122 / 9822125224

8882614 - SANGEETA VANGANKAR
 54 Years / Female / Ht 142 Cms / 65 Kgs / Non-Smoker

ALL ON ONE

Date: 10-08-2024 (T3)

Pred Eign: CLARITY Etn: Qry: 108 Test: PFC
 Ref By: MONE



Parameter	Unit	Pred	Pre	Prc%	Post	Post%	Imp%
FVC	[L]	1.96	1.35	69	-	-	-
FEV1	[L]	1.49	1.35	91	-	-	-
FEV.5	[L]	-	1.29	-	-	-	-
FEV3	[L]	1.80	-	-	-	-	-
FEV6	[L]	-	-	-	-	-	-
PEFR	[L/s]	5.17	6.59	127	-	-	-
FEF25-75	[L/s]	1.90	3.59	189	-	-	-
FEF75-85	[L/s]	-	1.45	-	-	-	-
FEF2-12	[L/s]	3.71	3.51	94	-	-	-
FEF25%	[L/s]	5.15	6.96	136	-	-	-
FEF50%	[L/s]	3.79	3.67	102	-	-	-
FEF75%	[L/s]	1.67	1.60	96	-	-	-
FEV.5/FVC	[%]	-	80.77	-	-	-	-
FEV1/FVC	[%]	76.37	100.00	131	-	-	-
FEV3/FVC	[%]	97.00	-	-	-	-	-
FEV6/FVC	[%]	-	-	-	-	-	-
FEV1/FEV6	[%]	-	-	-	-	-	-
FET	[S]	-	0.82	-	-	-	-
ExpTime	[S]	-	0.05	-	-	-	-
LungAge	[Y]	54.00	59.00	109	-	-	-
FVC	[L]	-	-	-	-	-	-
PIFR	[L/s]	-	-	-	-	-	-
SVC	[L]	-	1.59	-	-	-	-
ERV	[L]	0.83	0.10	11	-	-	-
IRV	[L]	-	-2.44	-	-	-	-
VE	[L]	-	26.47	-	-	-	-
RF	[%]	-	19.96	-	-	-	-
TI	[S]	-	1.90	-	-	-	-
TE	[S]	-	1.11	-	-	-	-
VT	[L]	-	1.43	-	-	-	-
VT/TI	[%]	-	0.75	-	-	-	-
TI/Tot	[%]	-	0.63	-	-	-	-
MVV	[L]	83.60	37.40	45	-	-	-
MRF	[%]	-	6.49	-	-	-	-
MVT	[M]	-	1.33	-	-	-	-
TI	[S]	-	6.54	-	-	-	-
TE	[S]	-	7.26	-	-	-	-
TE/TI	[%]	-	1.11	-	-	-	-

Pre: Spirometry shows Mild Restriction as FVC% < 80 And FEV1/FVC% > 70

Dr. Ashadevi

DR. ASHADEVI NETRAVALKA
 MBBS, MD, AFI

Consultant Radiologist
 2nd Floor, Rizvi Sadan Panaji
 Tel: 0832-2238122 / 9822125224

NAME: MRS.SANGEETA VAINGANKAR
AGE: 54/YRS
REF BY: SELF

DATE: 10/08/2024
SEX: F

X-RAY CHEST--- PA VIEW

Slight obliquity is present.

Prominent bronchovascular markings are seen in the lungs.

Lung fields are clear.

Heart appears enlarged .? Apparent due to obliquity.


Both costophrenic angles are clear.

Both domes of diaphragm are normal.

Rib cage is normal.

IMPRESSION : NORMAL STUDY.

With regards,



DR.ASHADEVI NETRAVALKAR,MD
RADIOLOGIST

Dr. Netravalkar's
Imaging Centre

Dr. Ashadevi Netravalkar

MBBS., MD, AFIH

Consultant Radiologist & Sonologist

Name : SANGEETA VAINIGANKAR

Age : 54 M/F F Date : 10.08.24

Investigation : ECG

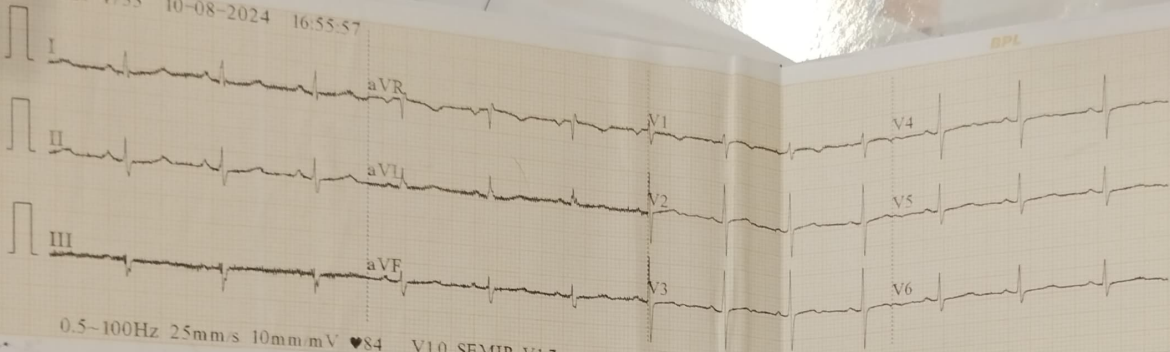
Ref. by Dr. : _____

201,202,203, Rizvi Sadan, 2nd Floor, Near Municipal Market,
Next to Vaidya Hospital, Panaji - Goa.

Tel.: 0832 2238122 | Email : drashanetravalkar@gmail.com

Timing : 8.00 am to 1.00 pm | 4.00 pm to 7.00 pm

ID: 4733 10-08-2024 16:55:57



0.5-100Hz 25mm/s 10mm/mV ♥84 V1.0 SEMIP V1.7

CARDIART


ID: 4733

Female mmHg
54Years
cm kg

Prasad

HR	:	81	bpm
P	:	94	ms
PR	:	141	ms
QRS	:	74	ms
QT/QTc	:	399/464	ms
P:QRS:T	:	35/-41/41	°
RV5/SV1	:	0.286/0.276	mV

ELG & Wound



10/8/24

DR. SIGN.