




भारत सरकार

Government of India



विवेक कुमार त्रिपाठी

Vivek Kumar Tripathi

जन्म तिथि / DOB : 18/02/1987

पुरुष / Male




5119 3574 4064

आधार - आम आदमी का अधिकार



GPS Map Camera



Varanasi, Uttar Pradesh, India

44-B3, Durgakund, Bhelupur, Varanasi,

Uttar Pradesh 221001, India

Lat 25.289234°

Long 82.993354°

13/02/23 05:51 PM GMT +05:30

Google

Facilities:

All clinical Biomedical & Hematology Investigations including Bone Marrow Examination
VPT, Podiascan & Complete Foot Care (First Time in Purvanchal)
All Hormonal Investigation by Chemiluminescent Method
Visceral Fat by (AB-140) Ambulatory BP Monitoring
CGMS & Insulin Pump Available
PFT, 2D-ECHO (Color Doppler), Holter, TMT, Cardiac-3 available
VIA, VILI, Colposcopy available
Special Endocrinological Investigation Protocols.

ISO 9001:2008 Certified
Mobile: 9389994334, 9554572190, 9453837595



Panacea Pathology

Clinical Reference Lab

Persistence, Preparedness and Precision
EQAS (CMC Vellore Attached) & IQAS System
पूर्वांचल की सर्वोत्तम गुणवत्ता वाली पैथोलॉजी

PATIENT NAME : VIVEK KUMAR TRIPATH

AGE/GENDER : 36YRS/MALE

REFD BY DR. : ARCO FEMI HEALTHCARE LTD.

RECEIVED DATE : 12-02-2023 (09:00 AM)

SAMPLE : BLOOD & URINE

REPORT DATE : 13-02-2023 (02:00 PM)

PATHOLOGY REPORT

COMPLETE BLOOD COUNT (CBC)

TEST	LAB TEST VALUES	NORMAL RANGE
HEMOGRAM		
HEMOGLOBIN (FLOW CYTOMETRY)	14.8	13 – 16 gm/dl
TOTAL LEUCOCYTE COUNT (TLC)	5,300	4000 – 11000
RBC COUNT	5.17	3.5 – 5.5
PCV (HCT)	45.3	37 – 47
MCV	87.8	80 – 95
MCH	28.7	28 – 34
MCHC	30.3	30 – 36
PLATELET COUNT	1,65,000	1,50,000 – 4,00,000
E.S.R. (WINTROBE FIRST HOURS)	12.0	20 mm/1 st hr
DIFFERENTIAL LEUCOCYTE		
NEUTROPHILS	57	40 – 75%
LYMPHOCYTES	39	20 – 45%
EOSINOPHILS	02	1 – 6%
MONOCYTES	02	2 – 8%
BASOPHILS	00	< 2%

RANDOM/FASTING BLOOD SUGER

TEST	LAB TEST VALUES	NORMAL RANGE
RBS/FBS		
RANDOM BLOOD SUGAR	100.0	125-140 mg/dl
FASTING BLOOD SUGER	87.0	70-125 mg/dl

GLYCOSYLATED HEMOGLOBIN (HBA1C)

TEST	LAB TEST VALUES	NORMAL RANGE
HBA1C	5.2	Normal : <5.97 % Good Control : 5.97 – 6.81% Fair Control : 6.81 – 7.65% Poor Control : >7.65%

PAGE 1

Lab Technician

PANACEA HOSPITAL
(A UNIT OF AAROHAN HEALTH CARE PVT. LTD.,
REG. NO.: AL-1500
B.36/44, B.4, KABIR NAGAR
M.D. Pathology VARANASI

Timing : 8.00 a.m. to 9.00 p.m. (Sunday 8.00 a.m. to 3.00 p.m.)

This Report is not valid for medico legal purpose

Note: These tests have technical limitations. Clinico-pathological interpretation is necessary. In case of any disparity test may be repeated immediately.

Address : 36/44 FK Kabir Nagar, Durgakund, Varanasi – 221005

Email: dramishra@gmail.com, drpallaviojha@gmail.com Website: panaceahospital.org

Facilities:
 All clinical Biomedical & Hematology Investigations
 including Bone Marrow Examination
 VPT, Podiascan & Complete Foot Care (First Time in Purvanchal)
 All Hormonal Investigation by Chemiluminescent Method
 Visceral Fat by (AB-140) Ambulatory BP Monitoring
 CGMS & Insulin Pump Available
 PFT, 2D-ECHO (Color Doppler), Holter, TMT, Cardiac-3 available
 VIA, VILI, Colposcopy available
 Special Endocrinological Investigation Protocols.

ISO 9001:2008 Certified
 Mobile: 9389994334, 9554572190, 9453837595



Panacea Pathology

Clinical Reference Lab

Persistence, Preparedness and Precision
 EQAS (CMC Vellore Attached) & IQAS System
 पूर्वांचल की सर्वोत्तम गुणवत्ता वाली पैथोलॉजी

PATIENT NAME : VIVEK KUMAR TRIPATH	AGE/GENDER : 36YRS/MALE
REFD BY DR. : ARCO FEMI HEALTHCARE LTD.	RECEIVED DATE :12-02-2023 (09:00 AM)
SAMPLE : BLOOD & URINE	REPORT DATE :13-02-2023 (02:00 PM)

PATHOLOGY REPORT

LIPID PROFILE, SERUM

TEST	LAB TEST VALUES	NORMAL RANGE
BLOOD CHEMISTRY		
TOTAL CHOLESTEROL (SERUM)	183.0	Desirable:- & lt; 200 mg/dl Borderline:- 200 – 239 mg/dl High:- & gt; 240 mg/dl
TRIGLYCERIDES (SERUM)	162.0	35 – 170 mg/dl
HDL CHOLESTEROL (SERUM)	48.0	35.30 – 79.50 mg/dl
LDL CHOLESTEROL (SERUM)	102.2	& lt; 130 mg/dl
VLDL	32.4	& lt; 40 mg/dl
CHOLESTROL/HDL RATIO	4.1	& lt; 3.0 Low Risk Ratio 3.0 – 5.0 Avg Risk & lt; 5.0 High Risk
LDL/HDL RATIO	0.32	& lt; 3 Ratio

BLOOD GROUP

TEST	LAB TEST VALUES
BLOOD GROUP ABO & RH FACTOR	
BLOOD GROUP	"B"
RH FACTOR	POSITIVE

LIVER PROFILE TEST, SERUM

TEST	LAB TEST VALUES	NORMAL RANGE
BIO CHEMISTRY		
TOTAL BILIRUBIN	0.67	0.0 – 1.1 mg/dl
DIRECT BILIRUBIN	0.25	0.0 – 0.2 mg/dl
INDIRECT BILIRUBIN	0.42	< 0.90 mg/dl
SGOT (AST)	25.6	0 – 52 mg/dl
SGPT (ALT)	31.3	0 – 39 mg/dl
GGT (GYT)	15.4	< 55 U/L

THYROID PROFILE (T3, T4, TSH)

TEST	LAB TEST VALUES	NORMAL RANGE
THYROID FUNCTION TEST		
T3	1.10	0.60 – 1.81 ng/ml
T4	7.56	4.50 – 10.90 ug/dl
TSH	2.16	0.39 – 6.10 uIU/ml

PAGE 2

Lab Technician

PANACEA HOSPITAL
 (A UNIT OF AAROH HEALTHCARE PVT. LTD.)
 REG. NO. 2-1500
 B.36/44, KABIR NAGAR
 DURGAKUND, VARANASI

Timing : 8.00 a.m. to 9.00 p.m. (Sunday 8.00 a.m. to 3.00 p.m.)

This Report is not valid for medico legal purpose

Note: These tests have technical limitations. Clinico-pathological interpretation is necessary. In case of any disparity test may be repeated immediately.

Address : 36/44 FK Kabir Nagar, Durgakund, Varanasi – 221005

Email: dramishra@gmail.com, drpallaviojha@gmail.com Website: panaceahospital.org

Facilities:
 All clinical Biomedical & Hematology Investigations
 including Bone Marrow Examination
 VPT, Podiascan & Complete Foot Care (First Time in Purvanchal)
 All Hormonal Investigation by Chemiluminescent Method
 Visceral Fat by (AB-140) Ambulatory BP Monitoring
 CGMS & Insulin Pump Available
 PFT, 2D-ECHO (Color Doppler), Holter, TMT, Cardiac-3 available
 VIA, VILI, Colposcopy available
 Special Endocrinological Investigation Protocols.

ISO 9001:2008 Certified
 Mobile: 9389994334, 9554572190, 9453837595



Panacea Pathology

Clinical Reference Lab

Persistence, Preparedness and Precision
 EQAS (CMC Vellore Attached) & IQAS System
 पूर्वांचल की सर्वोत्तम गुणवत्ता वाली पैथोलॉजी

PATIENT NAME : VIVEK KUMAR TRIPATH	AGE/GENDER : 36YRS/MALE
REFD BY DR. : ARCO FEMI HEALTHCARE LTD.	RECEIVED DATE :12-02-2023 (09:00 AM)
SAMPLE : BLOOD & URINE	REPORT DATE :13-02-2023 (02:00 PM)

PATHOLOGY REPORT

RENAL & KIDNEY PROFILE, SERUM

TEST	LAB TEST VALUES	NORMAL RANGE
RENAL FUNCTION TESTS		
BLOOD UREA NITROGEN (BUN)	11.3	10 – 50 mg/dl
SERUM CREATININE	0.97	0.60 – 1.60 mg/dl
URIC ACID	3.87	3.60 – 7.70 mg/dl
ALKALINE PHOSPHATASE (ALP)	86.0	142 – 353 mg/dl
TOTAL PROTIENS	7.56	0 – 39 mg/dl
ALBUMIN	4.26	3.8 – 5.4 mg/dl
SERUM GLOBULIN	3.30	2.1 – 3.5 mg/dl
CALCIUM	9.2	8.80 – 10.20
PHOSPHORUS	3.04	2.50 – 5.00
SERUM SODIUM NA+	140.6	135.00 – 155.00 mEq/Ltr
SERUM POTASIUM K+	4.32	3.60 – 5.50 mEq/Ltr
ICALCIUM	1.24	1.10 – 1.35 mmol/L
SERUM CHLORIDE CL+	105.9	98.00 – 110.00 mEq/Ltr

URINE ROUTINE EXAMINATION

TEST	LAB TEST VALUES	NORMAL RANGE
PHYSICAL EXAMINATION		
QUANTITY	30	ML
COLOUR	STRAW	PALE YELLOW
APPEARANCE	CLEAR	CLEAR
SPECIFIC GRAVITY	1.010	1.01 – 1.03
PH	5.5	4.7 – 7.5
CHEMICAL EXAMINATION		
GLUCOSE	Not Detected	Not Detected
PROTEIN	NIL	Not Detected
MICROSCOPIC EXAMINATION		
PUS CELLS	1-2	0-5
RBC	Not Detected	Not Detected
EPITHELIAL CELLS	1-2	0-5
CASTS	Not Detected	Not Detected
CRYSTALS	Not Detected	Not Detected
BACTERIA	Not Detected	Not Detected

----- End of Report -----

Lab Technician

PANACEA HOSPITAL
 (A UNIT OF ARCO FEMI HEALTHCARE PVT. LTD.)
 REG. NO. AL-1500
 B.38, KABIR NAGAR
 DURGAKUND, VARANASI
 M.D., Pathology

Timing : 8.00 a.m. to 9.00 p.m. (Sunday 8.00 a.m. to 3.00 p.m.)

This Report is not valid for medico legal purpose

Note: These tests have technical limitations. Clinico-pathological interpretation is necessary. In case of any disparity test may be repeated immediately.

Address : 36/44 FK Kabir Nagar, Durgakund, Varanasi – 221005

Email: dramishra@gmail.com, drpallaviojha@gmail.com Website: panaceahospital.org



PANACEA HOSPITAL

B 36/44 F.K KABIR NAGAR, DURGAKUND
TOLLFREE NO-18001233070.
Whatsapp No - 8795832852
www.piire.org



OP Slip

Print Date : 12-Feb-2023 08:56AM



UHID No	:- UD-22230003604	OP No	:- OP-22230013380	OP Date	:- 12 Feb 2023 8:56AM
Patient Name	:- Mr VIVEK KUMAR TRIPATHI	Age/Sex	:- 36/Male	Mobile No	:- 9984215485
Father	:- T P TRIPATHI	Department	:- DIABETES, ENDOCRINOLOGY & METABOLIC PHYSICIAN		
Pay Type	:- Cash	Consultant	:- Dr ASHUTOSH MISHRA (MD(MEDICINE), IMS, BHU)		
Token No	:- NOR. - 1	Paid/Bal	:- 0.00 / 500.00		
Patient Type	:- Normal				
Address	:- BOB, varanasi				

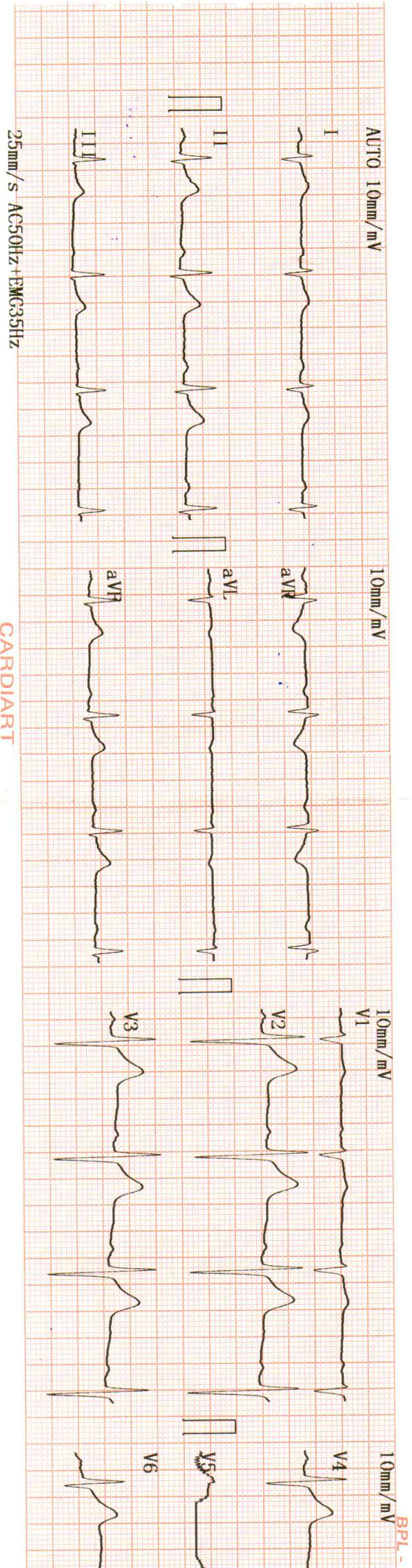
BP :- 110/80
height :- 171
Weight (kg) :- 80.4
BMI :-

Rx

SPO2 - 95
PR - 76
WC - 108
MC - 41
RBS - 99

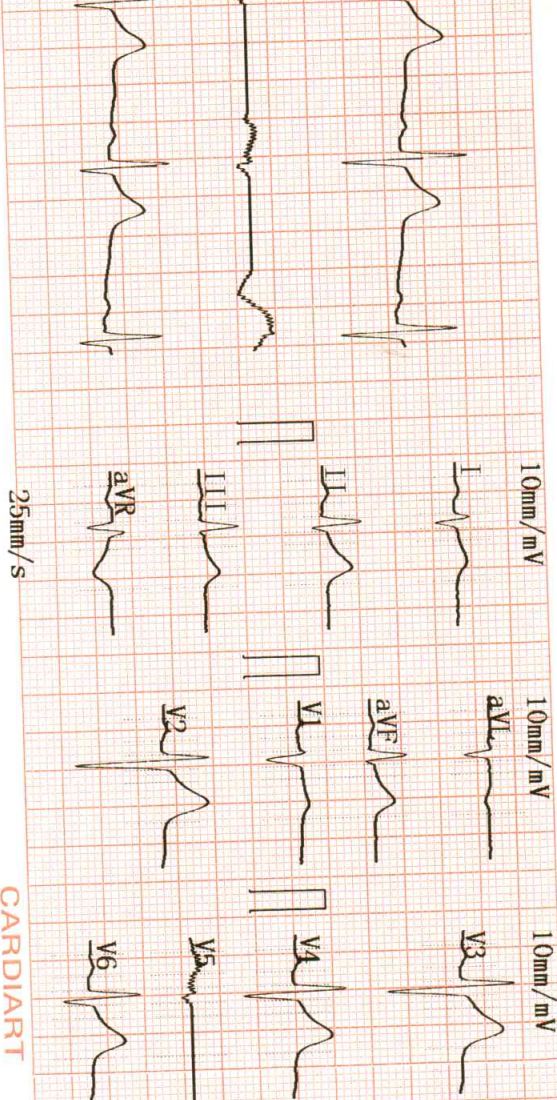
AKU

Printed By : Mr NITIN YADAV
Created By : Mr NITIN YADAV



CARDIART

BPL-



CARDIART

2023-02-12 10:25

ID :
 Name : **Vivek Ksh. Tripathi**
 Sex : **male**
 Height :
 SYS :
 DIA :
 HR : 66 bpm
 PR Interval : 196 ms
 P Duration : 120 ms
 QRS Duration : 82 ms
 T Duration : 217 ms
 QT/QTc : 368/387 ms
 P/QRS/T Axis : 47.3/95.8/65.9 deg
 R(V5)/S(V1) : 0.08/0.42 mV
 R(V5)+S(V1) : 0.50 mV

Age : 36
 Weight : kg

Report need physician confirm

<< Conclusions >>

Normal Sinus Rhythm;
 Longitudinal Right axis deviation;

Physician _____

Pallavi
DR. PALLAVI MISHRA
 MBBS, MD (GENERAL MEDICINE)
 MCI Reg. No. 52033



Call Now - 1800-123-3070

PANACEA HOSPITAL

A shelter for many hearts A Home for many lives

(An ISO 9001:2008 Certified Organisation)

Lab Attached with CMC Vellore Under EQAS Scheme

Name	MR.VIVEK KUMAR TRIPATHI	Sex /Age	36/M	Date	13/02/2023
Ref. by	Dr.Pallavi Mishra(MD)	BSA - m ²		Echo window	fair

Echo - Cardiography

MITRAL VALVE Doppler	AML - normal morphology MV Flow - E - 0.7 A-0.7 E/A=0.96	PML - normal morphology MVA - 3.0 cm ² Mitral Regurgitation - No
TRICUSPID VALVE Doppler	Normal TV Flow -No	Tricuspid Regurgitation - No
PULMONARY VALVE Doppler	Normal PV Flow -No	Pulmonary Regurgitation - No
AORTIC VALVE Doppler	Trileaflet-No AV Flow - no	Aortic Regurgitation - no
MEASUREMENT	Aorta - 26.8 (20-38) mm IVS ed - 13.1 (6 -12) mm LVID ed - 25.1 (35 - 55) mm LVPW ed - 12.0 (6 -12) mm OA - 7 (> 5) mm	LA - 28.6 (24-32) mm IVS es -16.4 (6 - 12) mm LVID es - 18.8 (24 - 40) mm LVPW es - 17.7 (6 -12) mm EPSS - 7 (< 9) mm

CONCLUSION

All cardiac chamber dimensions are WNL
No valvular abnormalities
Good LV systolic function present Modified Simpson's method (4C, 2C) (LVEF-52%)
No diastolic dysfunction present (E/A = 0.96) by tissue Doppler (E/e'=6.2)
No RWMA
No pericardial effusion
Intact IAS / IV
No PAH
No intra cardiac mass /thrombus /vegetation

IMPRESSION **Normal Echocardiogram**

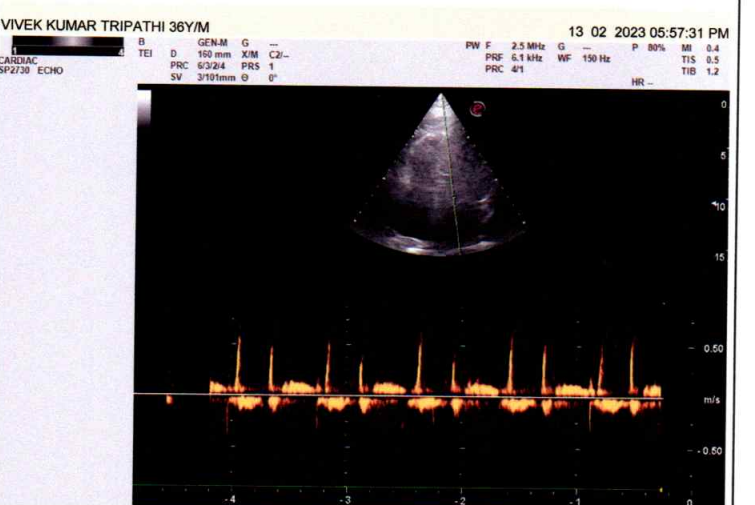
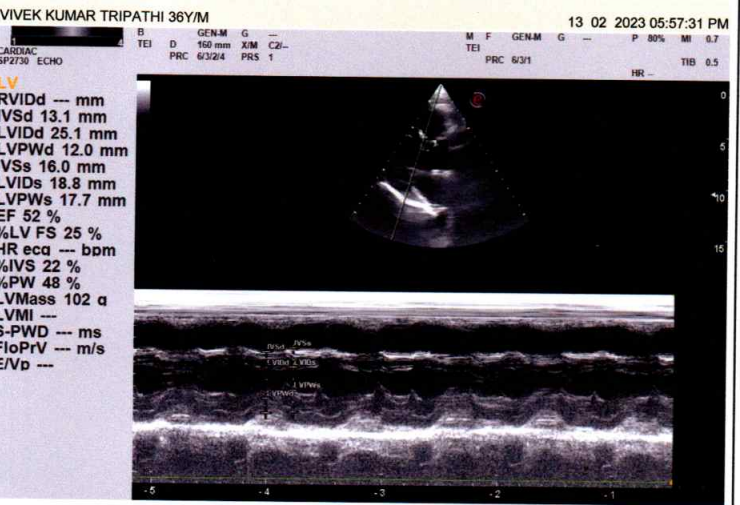
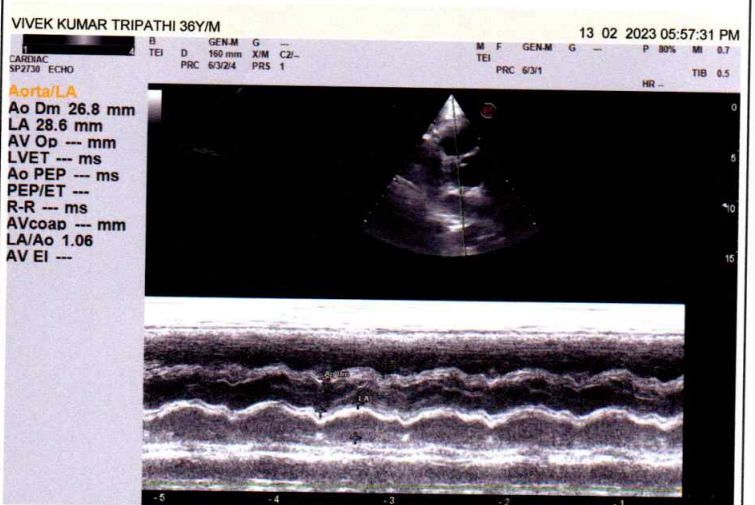
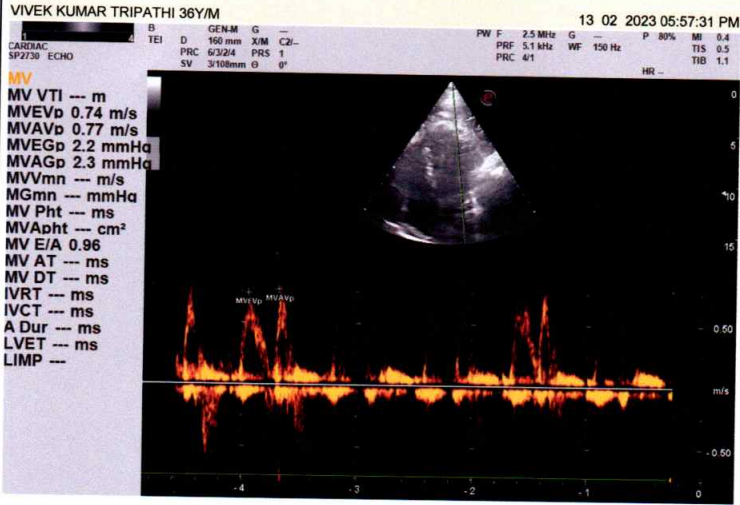
Niraj Mishra
Physician Assistant
(PIIRE)

DR. PALLAVI MISHRA
MBBS, MD (GENERAL MEDICINE)
MCI Reg. No. 52033
Dr. Pallavi Mishra
MBBS, MD (MED) Lucknow
Echocardiography Specialist, MIAE
Non-invasive cardiologist
Women Cardiologist
Diabetocardiologist

Address : Kabir Nagar (Near Sanjay Shiksha Niketan), Durgakund, Varanasi

Mobile : 9554572190 / 9453837595 / Recpn. 9389994334

E-mail : dramishra@gmail.com, drpallaviojha@gmail.com, Website: www.piire.org





 GPS Map Camera



Varanasi, Uttar Pradesh, India
44-B3, Durgakund, Bhelupur, Varanasi,
Uttar Pradesh 221001, India
Lat 25.28924°
Long 82.993309°
13/02/23 05:52 PM GMT +05:30

Google

PANACEA HOSPITAL

A shelter for many hearts A Home for many lives

(An ISO 9001:2008 Certified Organisation)

Lab Attached with CMC Vellore Under EQAS Scheme



NAME: MR.VIVEK KUMAR TRIPATHI

AGE/SEX: 36 YRS / MALE

REF BY: DR. ASHUTOSH MISHRA (MD)

DATE: 13/02/2023

ULTRA SOUND WHOLE ABDOMEN REPORT

Liver: Normal in shape and size and shows smooth and regular margin.
No diffuse/focal lesion seen.

Gall bladder: Partially distended with normal wall thickness and echo-free lumen.

CBD diameter Visualized part normal in course & caliber.

Pancreas: Normal in size, shape & echogenicity.
Margins are smooth & regular.
No diffuse/ focal lesion seen. Pancreatic tail obscured.

Spleen: Normal in size, shape & echogenicity.
Margins are smooth & regular. No diffuse / focal lesion seen.
Splenic vessels at hilum is normal.

Kidney: Both normal in size, shape, echogenicity & position.
Cortical-medullary differentiation is maintained.
Pelvicalyceal system normal.
No calculus/mass lesion seen.
No hydronephrosis/ hydroureter seen.
No suprarenal mass lesion.

Address : Kabir Nagar (Near Sanjay Shiksha Niketan), Durgakund, Varanasi

Mobile : 9554572190 / 9453837595 / Recpn. 9389994334

E-mail : dramishra@gmail.com, drpallaviojha@gmail.com, **Website:** www.piire.org



PANACEA HOSPITAL

A shelter for many hearts A Home for many lives

(An ISO 9001:2008 Certified Organisation)

Lab Attached with CMC Vellore Under EQAS Scheme

NAME: MR. VIVEK KUMAR TRIPATHI

AGE/SEX: 36 YRS / MALE

REF BY: DR. ASHUTOSH MISHRA (MD)

DATE: 13 /02/2023

X-RAY CHEST PA

BOTH LUNG FIELDS AND PLEURAE:

Both lungs show normal bronchovascular pattern.

Right & left hila are normal

No focal mass or calcification is seen

There is no evidence of any fluid in the both the pleural cavities.

Both domes of diaphragms are normal in position.

MEDIASTINUM:

Trachea is central in position.

Cardiac silhouette is of normal size and configuration.

No evidence of pericardial effusion.

No significant lymphadenopathy is seen.

Visualized skeleton is normal.

NO SIGNIFICANT RADIOGRAPHIC ABNORMALITY.

REPORTED BY

DR. Rahul Kumar Tiwari

MBBS, MD (Radio Diagnosis)

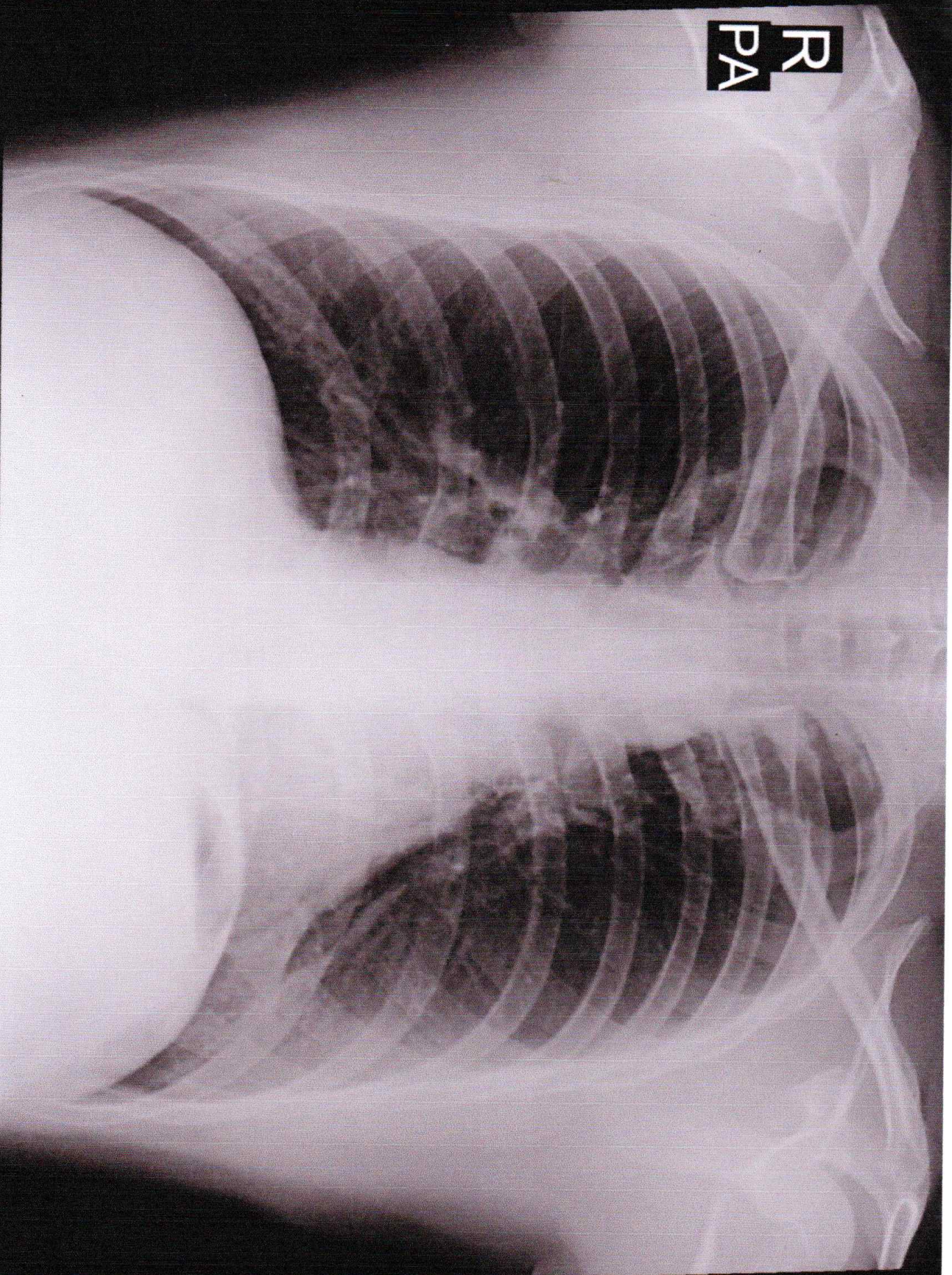
Reg.No. 57557

Address : Kabir Nagar (Near Sanjay Shiksha Niketan), Durgakund, Varanasi

Mobile : 9554572190 / 9453837595 / Recpn. 9389994334

E-mail : dramishra@gmail.com, drpallaviojha@gmail.com, Website: www.paire.org

R
PA



VIVEK KUMAR TRIPATHI 36Y/M 4552 O CHEST P.A. 13-Feb-23 05:33 PM

PANACEA HOSPITAL, KABIR NAGAR, DURGAKUND, VARANASI