

Date : 11-04-2023
MR NO : CMYS.0000056270

Department : GENERAL
Doctor : ROHITH. H.K.

Name : Mr. PRASAD KUMAR B C

Registration No :

Age/ Gender : 32 Y / Male

Qualification :

Consultation Timing: 08:35

Height :	Weight :	BMI :	Waist Circum :
Temp :	Pulse :	Resp :	B.P :

General Examination /
Allergies History

Clinical Diagnosis & Management Plan

Pt came for Annual Health check up.
No fresh complaints
No h/o DM, HTN.


11/04

Apollo Clinic
23, 1st Floor,
Kalidasa Road, Mysore - 6
Ph : 0821-4006040/41

Follow up date :

Doctor Signature

Date : 11-04-2023
MR NO : CMYS.0000056270

Department : GENERAL Dietetics
Doctor : Madhura B.S

Name : Mr. PRASAD KUMAR B C

Registration No :

Age/ Gender : 32 Y / Male

Qualification :

M.Sc Nutrition & Dietetics
PhD*

Consultation Timing: 08.35

Height : 161 cm	Weight : 72 kg	BMI : 28 kg/m ²	Waist Circum : 61 cm
Temp :	Pulse :	Resp :	B.P :

General Examination /
Allergies History

Clinical Diagnosis & Management Plan

- ⇒ Advised low calorie fiber rich foods.
- ⇒ Take small frequent meals. Do not skip meals.
- ⇒ Regular physical activity.
- ⇒ Drink 10-12 cup glasses of water (day).
- ⇒ Include all variety of seasonal fruits, vegetables and green leafy vegetables.
- ⇒ Include nuts like Almonds & walnuts.
- ⇒ Include dry-fruits like ~~dry~~ raisins and dried dates.
- ⇒ Include seeds like flaxseeds, Pumpkin seeds, sunflower seeds, watermelon seeds & sesame seed - 1 teaspoon each [dry roasted]
- ⇒ Avoid seed neat regularly.

Follow up date :

Doctor Signature

- ⇒ Avoid Maida, Sugar, too much of salt, baking soda & creams.

- ⇒ Avoid bakery products, chats, junk foods, deep fried foods, packed & processed foods.

Date : 11-04-2023
MR NO : CMYS 0000056270

Department : GENERAL
Doctor :

Name : Mr. PRASAD KUMAR B C

Registration No : Dr. Praveen Kumar R
MC (Gen)

Age/ Gender : 32 Y / Male

Qualification :

Consultation Timing : 08:35

Height :	Weight :	BMI :	Waist Circum :
Temp :	Pulse :	Resp :	B.P :

General Examination /
Allergies History

Clinical Diagnosis & Management Plan

Come for regular health checkup

Deviated nasal septum to (L)

HIS Tonsillar hypertrophy

O/E Ear - Bilateral Tar - normal

Nose - nasal mucosa - (R) :

Deviated nasal septum to (L)

Oral cavity & oropharynx - (R) Tonsillar

Neck - normal Hypertrophy Grade II

Adv

Follow up date :

Doctor Signature

- Fluticason FS nasal spray (1)

1 - 07 X 1 month

Review after 3 weeks

Dr
Apollo Clinic
23, 1st Floor,
Kalidasa Road, Mysore - C
Ph : 0821-4006040/41

Date : 11-04-2023
MR NO : CMYS.0000056270

Department : GENERAL Dental
Doctor : DR. Jyothishree

Name : Mr. PRASAD KUMAR B C

Registration No :

Age/ Gender : 32 Y / Male

Qualification :

Consultation Timing: 08:35

Height :	Weight :	BMI :	Waist Circum :
Temp :	Pulse :	Resp :	B.P :

General Examination /
Allergies History

Clinical Diagnosis & Management Plan

O/E

Ca+p, St+r

Adv:- Oral prophylaxis

Apollo Clinic
23, 1st Floor,
Kalidasa Road, Mysore
Ph : 0821-4906011

Jyothishree

Follow up date :

Doctor Signature

Patient Name	: Mr. PRASAD KUMAR B C	Age	: 32 Y M
UHID	: CMYS 0000056270	OP Visit No	: CMYSOPV112692
Reported on	: 11-04-2023 11:01	Printed on	: 11-04-2023 11:02
Adm/Consult Doctor	:	Ref Doctor	: SELF

DEPARTMENT OF RADIOLOGY

X-RAY CHEST PA

Both lung fields and hila are normal .
No obvious active pleuro-parenchymal lesion seen .
Both costophrenic and cardiophrenic angles are clear .
Both diaphragms are normal in position and contour .
Thoracic wall and soft tissues appear normal.

IMPRESSION :NORMAL STUDY.



Printed on: 11-04-2023 11:01

---End of the Report---

Dr. PRADEEP KUMAR C N
MBBS DNB(RADIOLOGY)
Radiology

Apollo Health and Lifestyle Limited

REGD. OFFICE: 110/20/20/KK/PC/115819

REGD. OFFICE: 110/20/20/2/ Ashoka Raghupathi Chambers 5th Floor, Begumpet, Hyderabad, Telangana - 500 016

PH: No. 4364 7777 Fax No. 4364 7744 | Email ID: enquiry@apolloh.com | www.apolloh.com

APOLLO CLINICS NETWORK KARNATAKA

Bangalore: basavanajudi | Bellandur | Electronic City | Fraser Town | HSR Layout | Indira Nagar | JP Nagar | Kundalahalli |
Kumarajaya | Sarajayal Road, **Mysore:** VV Mohalla

Online appointments: www.apolloclinic.com

TO BOOK AN APPOINTMENT

 **1860 500 7788**

Page 1 of 1

Patient Name: Mr. Prasad Kumar	Date :11.04.2023	Referring Doctor:Dr.Self
Age / Sex : 32yrs /Male	UHID No :56270	: OP
ULTRASONOGRAPHY – ABDOMEN & PELVIS		

LIVER: It is normal in size, outline and echotexture. No focal lesions seen. IHBR are not dilated. CBD and Portal vein are normal.

GALL BLADDER: It is well distended and normal. No calculi seen.

SPLEEN: It is normal in size, outline and echopattern. No e/o focal lesions.

PANCREAS: It is normal in size, outline and echopattern.

RIGHT KIDNEY: It Measures 94x48 mm with parenchymal thickness of 15 mm. It is normal in size, outline and echotexture. No e/o calculus or hydronephrosis seen.

LEFT KIDNEY: It measures 105x53 mm with parenchymal thickness of 17 mm. It is normal in size, outline and echotexture. No e/o calculus or hydronephrosis seen.


URINARY BLADDER: It is well distended. The UB wall is normal. No e/o calculi.

PROSTATE: It measures 26x28x20 mm with a volume of 112cc. It is normal in size, outline and echotexture. The vascularity of prostate is normal.

RIE: No evidence of focal collection or mass lesion seen. Appendix is not visualized.

OTHERS: No e/o free fluid in the abdomen. No e/o lymphadenopathy. No e/o gut wall thickening. No mass lesion seen in the abdomen.

IMPRESSION: NORMAL STUDY.


Dr. Pradeep Kumar C N, DNB
Consultant Radiologist.

Apollo Health and Lifestyle Limited

CIN: U05130TG200009315819

Regional Office: 11/10/11/2, Ashoka Raghupathi Chambers, 5th Floor, Begumpet, Hyderabad, Telangana - 500 016

Ph: No. 080 4348 7777 Fax No: 4348 7744 | Email: info.enquiry@apollohosp.com | www.apollohosp.com

APOLLO CLINICS NETWORK KARNATAKA

Bangalore: Saracasaiguda | Bellandur | Electronic City | Fraser Town | HSR Layout | Indira Nagar | JP Nagar | Kundalahalli |

Karnataka one: Saracasaiguda | **Mysore:** SV Mohalla |

Online appointments: www.apolloclinics.com

TO BOOK AN APPOINTMENT

 **1860 500 7788**

Patient's Name : Mr Prasad Kumar

Age & Sex : 32yrs/Male

Date : 11.04.2023

UHID No : 56270

MORPHOLOGICAL DATA:

Left Atrium	Normal
Left Ventricle	Normal
Right Atrium	Normal
Right Ventricle	Normal
Interatrial septum	Intact
Interventricular septum	Intact
Aorta	Normal
Pulmonary artery	Normal
Mitral valve	Normal
Tricuspid valve	Normal
Aortic valve	Normal
Pulmonary valve	Normal
Pericardium	Normal

DIMENSIONS:

RVIDd	1.44 cms
LVIDd	4.13 cms
LVIDs	2.48 cms
IVSd	0.95 Cms
LVPWd	1.02 Cms
AORTA	2.89 cms
LA	2.95 Cms
LVEF	70 %

Apollo Health and Lifestyle Limited

CIN: L28110TN2005ANPL0115819

Regd. Office: Apollo Clinic, K. Anand Kaghupathi Chambers, 5th Floor, Begumpet, Hyderabad, Telangana - 500 016
Ph: No. 4844 4844 / 4844 1111 Fax: No. 4844 7744 | mail ID: enquiry@apollohosp.com | www.apollohosp.com

APOLLO CLINICS NETWORK KARNATAKA

Bangalore: Basavanaguda | Bannerghatta | Electronic City | Frazer Town | HSR Layout | Indira Nagar | JP Nagar | Kulkarni Halli |
Koramangala | Sarjapur Road | Mysore: VV Mohalla

Online appointments: www.apolloclinics.com

TO BOOK AN APPOINTMENT

1860 500 7788



Patient's Name : Mr Prasad Kumar

Age & Sex : 32yrs/Male *Interfere Closer to you*

Date : 11.04.2023

UHID No : 56270

DOPPLER DATA:

VALVES	Velocity (Cm/s)	Peak Gradient (mmHg)	Mean Gradient (mmHg)	Regurgitation
Mitral	E : 0.69 A : 0.52 E/A : 1.34 E/e' : 7.74	1.93		NIL
Tricuspid	E: A:			TRIVIAL JET Grdt 31 mmHg
Aortic	1.23	6.10		NIL
Pulmonary	1.29	6.57		NIL

IMPRESSION:

NORMAL VALVES AND CHAMBERS

NO RWMA

NORMAL LV FUNCTION

NO e/o CLOT/ VEGETATION/ PE

Dr GOWTHAM H G

MD, DM CARDIOLOGY

Apollo Health and Lifestyle Limited

CIN : U95101TG2000PTC015875

Regd Office : 1-10-10-02, Ashoka Raghupathi Chambers, 5th Floor, Begumpet, Hyderabad, Telangana - 500 016

Ph: No: 044-4904 1111 Fax: No: 4904 7744 | Email: enquiry@apollohl.com | www.apollohl.com

APOLLO CLINICS NETWORK KARNATAKA

Bangalore : Basavanagudi | Bellandur | Electronic City | Fraser Town | HSR Layout | Indra Nagar | JP Nagar | Kundalahalli |

Kowtharepete | Marapet Road | **Mysore** (VV Mahalla)

Online appointments: www.apolloclinic.com

TO BOOK AN APPOINTMENT

1860 500 7788

Date : 11-04-2023
MR NO : CMYS.0000056270

Department : GENERAL
Doctor :

Name : Mr. PRASAD KUMAR B C
Age/ Gender : 32 Y / Male

Registration No :
Qualification :

Consultation Timing: 08:35

Height :	Weight :	BMI :	Waist Circum :
Temp :	Pulse :	Resp :	B.P :

General Examination /
Allergies History

Clinical Diagnosis & Management Plan

	<u>Rt eye</u>	<u>Lt eye</u>
Distance	6/6	6/6
near vision	NC	NC
cataract vision	Normal	Normal

Follow up date :

Apollo Clinic
23, 1st Floor,
Kalidasa Road, Mysore - 02
Ph : 0821-4006010/11

Doctor Signature

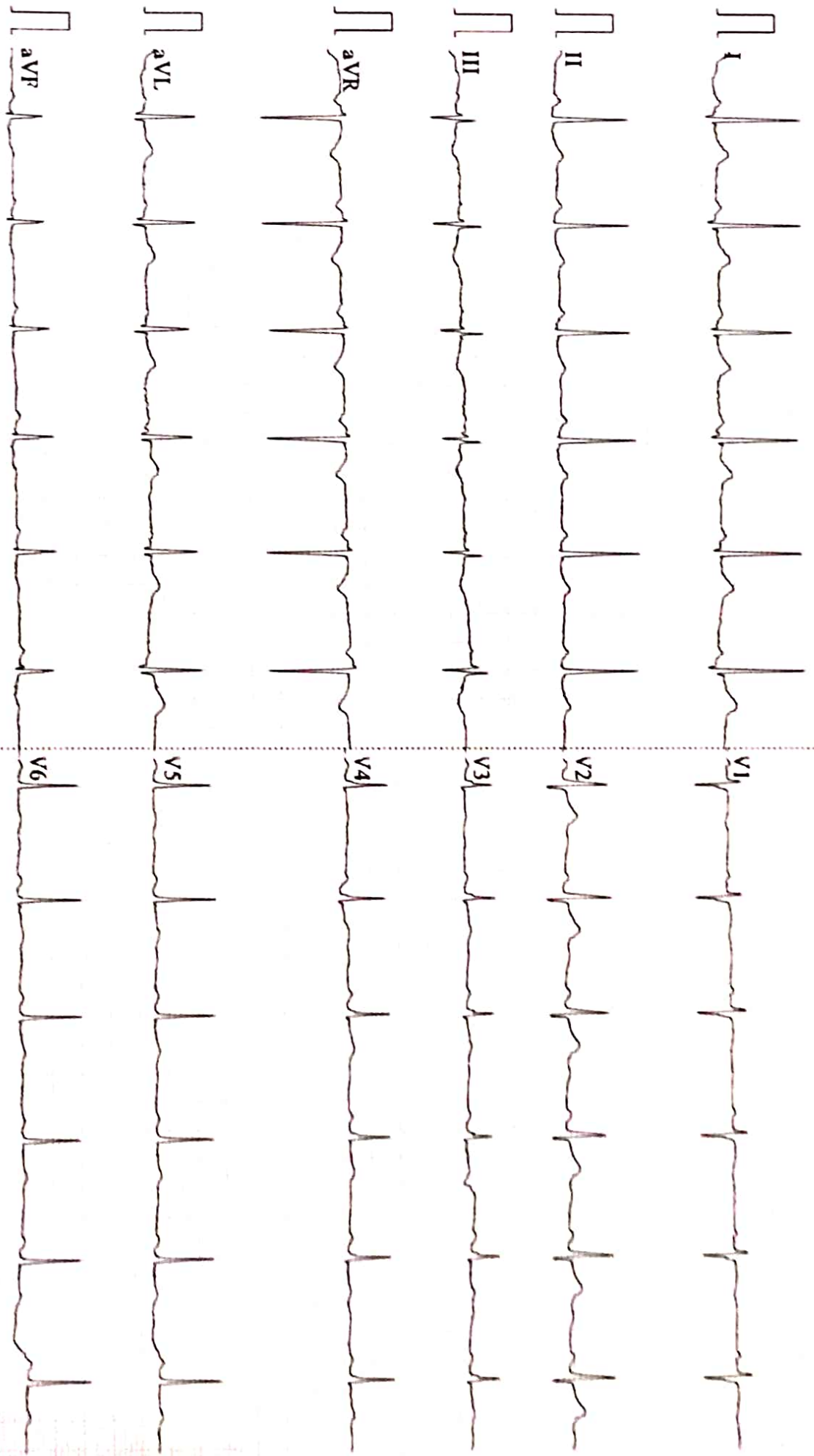
ID: 56270
MR PRASAD KUMAR B C
Male 32Years
161cm 72kg 120/70 mmHg

11-04-2023 10:49:12 AM

Diagnosis Information:

Apollo Clinic
23, 1st Floor,
Kallidasa Road, Mysore - 02
Ph : 0821-4006090/41

Unconfirmed Report.



0.5-45Hz AC50 25mm/s 10mm/mV 2*5.0s 73 CARDIART 9 ID V1.43 Glasgow V28.6.0 APOLLO CLINIC MYSURU