

Patient Name : Mrs.JYOTI PANDEY	Collected : 29/Oct/2024 03:27PM
Age/Gender : 42 Y 2 M 20 D/F	Received : 31/Oct/2024 01:22PM
UHID/MR No : CSAR.0000145944	Reported : 02/Nov/2024 03:26PM
Visit ID : CSAROPV359799	Status : Final Report
Ref Doctor : Self	Sponsor Name : ARCOFEMI HEALTHCARE LIMITED
Emp/Auth/TPA ID : 22S31254	

DEPARTMENT OF CYTOLOGY


LBC PAP SMEAR , CERVICAL BRUSH SAMPLE

	CYTOLOGY NO.	24045
I	SPECIMEN	
a	SPECIMEN ADEQUACY	ADEQUATE
b	SPECIMEN TYPE	LIQUID-BASED PREPARATION (LBC)
	SPECIMEN NATURE/SOURCE	CERVICAL SMEAR
c	ENDOCERVICAL-TRANSFORMATION ZONE	ABSENT
d	COMMENTS	SATISFACTORY FOR EVALUATION
II	MICROSCOPY	Superficial and intermediate squamous epithelial cells with benign morphology. Inflammatory cells predominantly neutrophils.
III	RESULT	
a	EPITHEIAL CELL	
	SQUAMOUS CELL ABNORMALITIES	NOT SEEN
	GLANDULAR CELL ABNORMALITIES	NOT SEEN
b	ORGANISM	NIL
IV	INTERPRETATION	NEGATIVE FOR INTRAEPITHELIAL LESION OR MALIGNANCY

Pap Test is a screening test for cervical cancer with inherent false negative results. Regular screening and follow-up is recommended (Bethesda-TBS-2014) revised

*** End Of Report ***

Result/s to Follow:
PERIPHERAL SMEAR



Dr. Reshma Stanly
M.B.B.S, DNB(Pathology)
Consultant Pathologist



SIN No: SAR241003172

This test has been performed at Apollo Health & Lifestyle Ltd, Global Reference Laboratory, Hyderabad

Regd. Office: 102/2/20, Anand Nagar, Rajaganga 4th Cross, 4th Block, Rajanganga, Hyderabad, Telangana - 500016
www.apolloclinic.com | Email ID: enquiry@apolloclinic.com, Ph: No: 040-6661 7777, Fax No: 4661 7766

APOLLO CLINIC'S NETWORK

Telangana: Hyderabad (45) | Andhra Pradesh: Amaravati | Karnataka: Bangalore | Kerala: Kochi | Maharashtra: Mumbai | Odisha: Bhubaneswar | West Bengal: Kolkata | Gujarat: Gandhinagar | Rajasthan: Jaipur | Haryana: Gurgaon | Punjab: Ludhiana | Uttar Pradesh: Lucknow | Bihar: Patna | Jharkhand: Ranchi | Chhattisgarh: Raipur | Madhya Pradesh: Bhopal | Himachal Pradesh: Chandigarh | Jammu & Kashmir: Srinagar | Arunachal Pradesh: Itanagar | Assam: Dispur | Mizoram: Aizawl | Nagaland: Kohima | Manipal: Imphal | Tripura: Agartala | Meghalaya: Shillong | Assam: Dispur | Mizoram: Aizawl | Nagaland: Kohima | Manipal: Imphal | Tripura: Agartala | Meghalaya: Shillong



Patient Name	: Mrs. Jyoti Pandey	Age	: 42Yrs 2Mths 21Days
UHID	: CSAR.0000145944	OP Visit No.	: CSAROPV359799
Printed On	: 22-10-2024 12:46 PM	Advised/Pres Doctor	: --
Department	: Radiology	Qualification	: --
Referred By	: Self	Registration No.	: --
Employee Id	: 22S31254		

DEPARTMENT OF RADIOLOGY

ULTRASONOGRAPHY OF ABDOMEN &

PELVIS

LIVER : Normal in size & echotexture normal. No focal lesion. No intra hepatic biliary duct dilatation. Portal & hepatic veins appear normal. PV: Normal. CBD: Normal.

GALL BLADDER : Minimally distended.

PANCREAS : Obscured by bowel gas. However the visualized parts of the pancreas appear grossly normal. Para-Aortic areas could not be seen.

SPLEEN : Normal in size & echotexture normal. No focal / diffuse lesions.

KIDNEYS : RIGHT KIDNEY : 9.7 x 4.5cms, LEFT KIDNEY : 10.8 x 4.6cms, normal parenchymal thickness. Both kidneys are normal in size and echotexture. No calculi. No pelvicalyceal dilatation on both sides. Corticomedullary differentiation is well maintained.

URINARY BLADDER : Normal in wall thickness and lumen are normal. Contents clear. No calculus seen.

UTERUS : Anteverted. Normal in size and echotexture. Endometrial and myometrium appears normal. Endometrial thickness: 12mm.

POD – clear.


OVARIES : Both ovaries are normal in size & echopattern. No obvious mass noted.

IMPRESSION : 1. Few calcification seen in right lobe of liver, largest measuring 7mm.
2. A simple cyst seen in right ovary measuring 2.5 x 2.2cm.

(The sonography findings should always be considered in correlation with the clinical and other investigation findings where applicable). It is only a professional opinion. Not valid for medico-legal purpose) Higher imaging techniques to be done, depending on

the condition of the patient, if clinically needed.

---End Of The Report---




Dr. RAMESH G
MBBS, DMRD
27462
Radiology

Patient Name	: Mrs. Jyoti Pandey	Age	: 42Yrs 2Mths 21Days
UHID	: CSAR.0000145944	OP Visit No.	: CSAROPV359799
Printed On	: 22-10-2024 12:46 PM	Advised/Pres Doctor	: --
Department	: Radiology	Qualification	: --
Referred By	: Self	Registration No.	: --
Employer Id	: 22S31254		

DEPARTMENT OF RADIOLOGY

DONE BY NIRAMA I

---End Of The Report---



Dr. RAMESH G
MBBS, DMRD
27462
Radiology

Patient Name	: Mrs. Jyoti Pandey	Age	: 42Yrs 2Mths 21Days
UHID	: CSAR.0000145944	OP Visit No.	: CSAROPV359799
Printed On	: 22-10-2024 12:47 PM	Advised/Pres Doctor	: --
Department	: Radiology	Qualification	: --
Referred By	: Self	Registration No.	: --
Employeer Id	: 22S31254		

DEPARTMENT OF RADIOLOGY


CHEST PA VIEW

Trachea central.
Mediastinum is central.
Cardiac silhouette appear normal.
visualized lung fields appear normal.
Bilateral hilum appear normal.
CP angles are clear.

IMPRESSION : No obvious gross abnormality noted in the x-ray.

ADVICE : Higher imaging techniques to be done, if clinically needed, depending on the clinical condition of the patient for further evaluation.

---End Of The Report---



Dr. RAMESH G
MBBS, DMRD
27462
Radiology

Patient Name	: Mrs. Jyoti Pandey	Age	: 42Yrs 2Mths 21Days
UHID	: CSAR.0000145944	OP Visit No.	: CSAROPV359799
Printed On	: 22-10-2024 12:04 PM	Advised/Pres Doctor	: --
Department	: Cardiology	Qualification	: --
Referred By	: Self	Registration No.	: --
Employee Id	: 22S31254		

DEPARTMENT OF CARDIOLOGY

2D ECHO CARDIOGRAPHY REPORT

M-MODE MEASUREMENTS

AORTA : 2.6cm LV (D) 4.3cm IVS (D) : 1.1cm
LA : 3.5cm LV (S) : 2.5cm PW (S) : 1.0 cm
EF : 59%

VALVES

MITRAL VALVE : NORMAL
AORTIC VALVE : NORMAL
TRICUSPID VALVE : NORMAL
PULMONARY VALVE : NORMAL

CHAMBERS

LEFT ATRIUM : NORMAL SIZED
RIGHT ATRIUM : NORMAL SIZED
LEFT VENTRICLE : NORMAL SIZED, NORMAL LV SYSTOLIC FUNCTION
RIGHT VENTRICLE : NORMAL SIZED, TAPSE-18 MM, NORMAL RV FUNCTION

SEPTAE

IAS : INTACT
IVS : INTACT

GREAT ARTERIES

AORTA :NORMAL
PULMONARY ARTERY :NORMAL
PERICARDIUM :NORMAL

DOPPLER FLOW VELOCITIES

MITRAL FLOW - E/A 0.5/0.6 m/sec, Grade II LV Diastolic Dysfunction, MR- Trivial
AORTIC FLOW PG-06 mmHg
TRICUSPID FLOW PASP -27 mmHg, TR-Trivial
PULMONARY FLOW PG-04 mmHg

REGIONAL WALL MOTION: NO RWMA

OTHER FINDINGS

IVC -15 MM, NORMAL SIZED, COLLAPSING, NORMAL RA PRESSURE

IMPRESSION

NORMAL CHAMBER DIMENSIONS
NORMAL VALVES
NORMAL PA PRESSURE
NO REGIONAL WALL MOTION ABNORMALITY
NORMAL LV SYSTOLIC FUNCTION
NO CLOT / EFFUSION / VEGETATION

DR .SAIKAT KANJILAL
CONSULTANT INTERVENTIONAL CARDIOLOGY

PRASAD.B
CARDIAC SONOGRAPHER

Note: investigations have their limitations solitary pathological/ Radiological and investigations never confirm the final diagnosis they are help in diagnosing the disease in correlation to clinical symptoms and other related tests. Please interpret accordingly ,this report is not for medico-legal Purpose

---End Of The Report---



Mr.PRASAD BOODUGURI
BSC, DIP IN CARDIO TECH
19XXMCC04712/TSPMB
Cardiology

Patient Name	: Mrs. Jyoti Pandey	Age	: 42Yrs 2Mths 21Days
UHID	: CSAR.0000145944	OP Visit No.	: CSAROPV359799
Printed On	: 22-10-2024 12:14 PM	Advised/Pres Doctor	: --
Department	: Cardiology	Qualification	: --
Referred By	: Self	Registration No.	: --
Employer Id	: 22S31254		

DEPARTMENT OF CARDIOLOGY

Observation :-

1. Normal Sinus Rhythm.
2. Heart rate is Normal
3. No pathological Q wave or ST-T changes seen.
4. Normal P,QRS,T waves and axis.
5. No evidence of chamber, hypertrophy or enlargement seen.

Impression:-

NORMAL RESTING ECG.

NOTE:-KINDLY TAKE A PHOTOCOPY OF THE GRAPH FOR FUTURE REFERENCE IF NEEDED

---End Of The Report---



Dr. SUMANJITA BORA
MBBS, PGDCC
MCI-IMR-13/903
Cardiology

APOLLO CLINIC CONSENT FORM

Patient name Jyoti Pandey Age 42y/e

UHID Number 145944 Company Name Medimarket.

Company want to inform u that I am ^{labr.} ~~not~~ interested in getting LBC Pap, Opthal, diob
dental.....Urine @ gynaecology, ENT, fitness by g.p.
And I claim the above statement in my full Consciousness.

Patient signature Rishav Date 22/10/24

Name : Mrs. Jyoti Pandey

Age : 42Y 2M 20D

UHID : CSAR.0000145944

Address : Carmelaram Bangalore Rural Karnataka INDIA 560035

sex : Female



CSAR.0000145944

Plan : ARCOFEMI MEDIWHEEL FEMALE AHC
CREDIT PAN INDIA OP AGREEMENT

OP No: CSAROPV359799

Bill No: CSAR-OCR-49292

Date: Oct 22nd, 2024, 8:49 AM

Sno.	Service Type/Service Name	Department
1	ARCOFEMI - MEDIWHEEL - FULL BODY ANNUAL PLUS CHECK ADVANCED - FEMALE - 2D ECHO - PAN INDIA - FY2324	
1	ULTRASOUND - WHOLE ABDOMEN	Ultrasound Radiology
2	FITNESS BY GENERAL PHYSICIAN	Consultation
3	HbA1c, GLYCATED HEMOGLOBIN	Biochemistry
4	LBC PAP TEST- PAPSURE - 6 by 12:30	Histopathology
5	COMPLETE URINE EXAMINATION	Clinical Pathology
6	SONO MAMMOGRAPHY - SCREENING Nix - 18 by 12:30	Mammography
7	BLOOD GROUP ABO AND RH FACTOR	Blood Bank
8	LIVER FUNCTION TEST (LFT)	Biochemistry
9	GLUCOSE, POST PRANDIAL (PP), 2 HOURS (POST MEAL) - 8	Biochemistry
10	GLUCOSE, FASTING	Biochemistry
11	OPHTHAL BY GENERAL PHYSICIAN	Consultation
12	DIET CONSULTATION	General
13	DENTAL CONSULTATION - 15	Consultation
14	BODY MASS INDEX (BMI)	General
15	X-RAY CHEST PA - 9	X Ray Radiology
16	HEMOGRAM + PERIPHERAL SMEAR	Haematology
17	PERIPHERAL SMEAR	Haematology
18	LIPID PROFILE	Biochemistry
19	2 D ECHO - 18 by 9:30	Cardiology
20	GYNAECOLOGY CONSULTATION	Consultation
21	ECG - 10	Cardiology
22	THYROID PROFILE (TOTAL T3, TOTAL T4, TSH)	Biochemistry
23	ENT CONSULTATION - 3 by 10:30	Consultation
24	URINE GLUCOSE(POST PRANDIAL)	Clinical Pathology
25	URINE GLUCOSE(FASTING)	Clinical Pathology
26	GAMMA GLUTAMYL TRANSFERASE (GGT)	Biochemistry
27	RENAL PROFILE/RENAL FUNCTION TEST (RFT/KFT)	Biochemistry

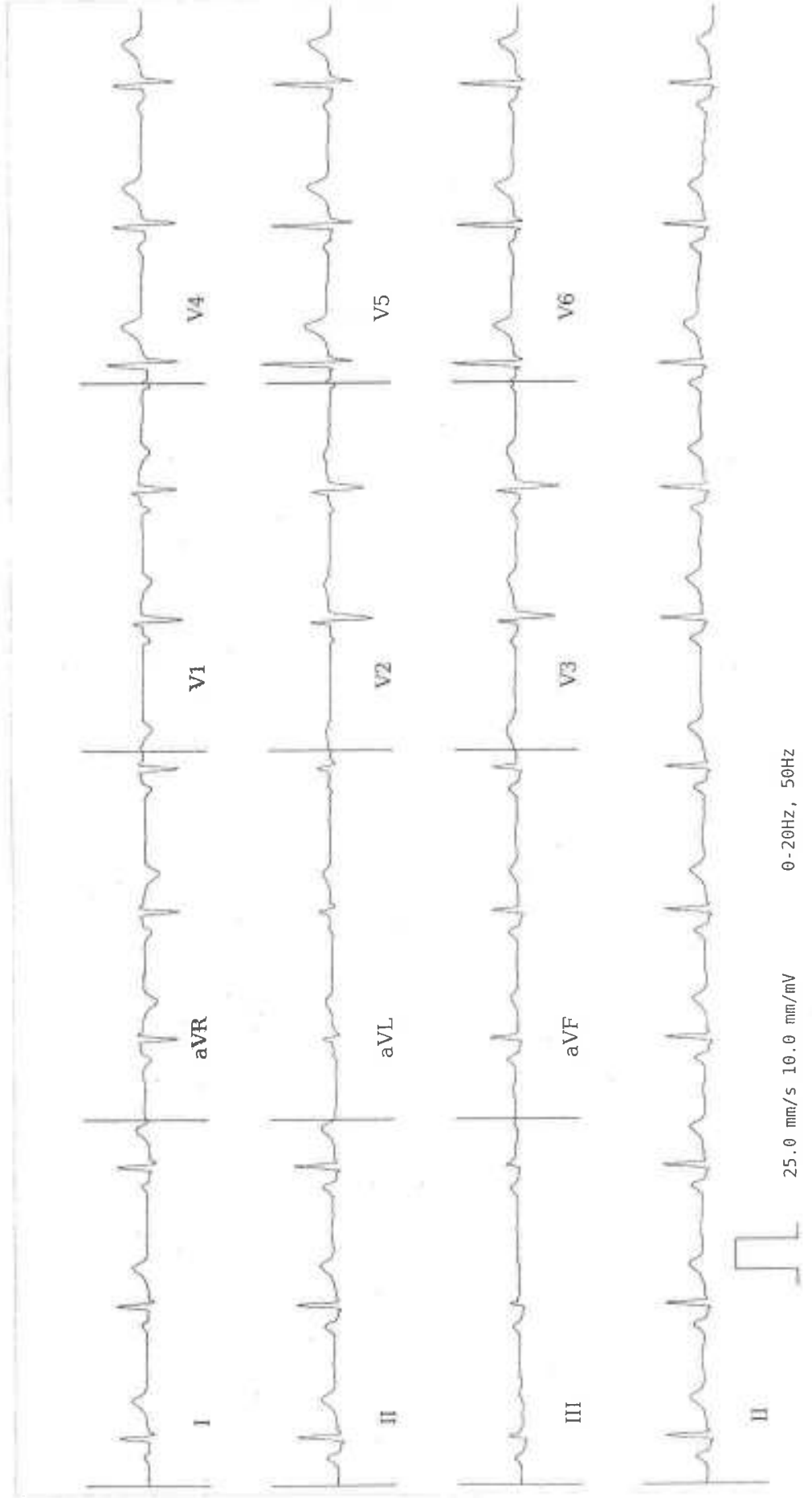
Dental - 15
Physio - 2

Wt - 89.3kg
Ht - 170cm
BP - 119/78mm
P - 83b/m
BMI - 30.8kg/m²



Age / Gender: 42/Female
Patient ID: JYOTI

Date and Time: 22nd Oct 24 10:22 AM



AR: 68bpm VR: 68bpm QRSD: 90ms QT: 382ms QTcB: 406ms PRI: 156ms P-R-T: 64° 51° 43°

ECG Within Normal Limits: Sinus Rhythm. Please correlate clinically.

REPORTED BY

Dr. Kavitha A

Disclaimer: Analysis in this report is based on ECG alone and should only be used as an adjunct to clinical history, symptoms and results of other invasive and non-invasive tests, and must be interpreted by a qualified physician

2D ECHO CARDIOGRAPHY REPORT

PATIENT NAME: MRS.JYOTI PANDEY

AGE : 42 YEARS/FEMALE

Date:22/10/2024

M-MODE MEASUREMENTS

AORTA : 2.6cm LV (D) 4.3cm IVS (D) : 1.1cm
LA : 3.5cm LV (S) : 2.5cm PW (S): 1.0 cm
EF :59%

VALVES

MITRAL VALVE : NORMAL
AORTIC VALVE : NORMAL
TRICUSPID VALVE : NORMAL
PULMONARY VALVE : NORMAL

CHAMBERS

LEFT ATRIUM : NORMAL SIZED
RIGHT ATRIUM : NORMAL SIZED
LEFT VENTRICLE : NORMAL SIZED, NORMAL LV SYSTOLIC FUNCTION
RIGHT VENTRICLE : NORMAL SIZED, TAPSE-18 MM, NORMAL RV FUNCTION

SEPTAE

IAS : INTACT
IVS : INTACT

GREAT ARTERIES

AORTA : NORMAL
PULMONARY ARTERY : NORMAL

PERICARDIUM :NORMAL

DOPPLER FLOW VELOCITIES

MITRAL FLOW - E/A 0.5/0.6 m/sec, Grade II LV Diastolic Dysfunction, MR- Trivial
AORTIC FLOW PG-06 mmHg
TRICUSPID FLOW PASP -27 mmHg, TR-Trivial
PULMONARY FLOW PG-04 mmHg

REGIONAL WALL MOTION: NO RWMA

Apollo Health and Lifestyle Limited

(CIN - U85110TG2000PLC115819)

Regd. Office: 1-10-60/62, Ashoka Raghupathi Chambers, 5th Floor, Begumpet, Hyderabad, Telangana - 500 016.


Ph No: 040-4904 7777, Fax No: 4904 7744 | Email ID: enquiry@apollohl.com | www.apollohl.com

APOLLO CLINICS NETWORK KARNATAKA

Bangalore (Basavanagudi | Bellandur | Electronic City | Fraser Town | HSR Layout | Indira Nagar | JP Nagar | Kundalahalli | Koramangala | Satjapur Road) **Mysore** (VV Mohalla)

Online appointments: www.apolloclinic.com

TO BOOK AN APPOINTMENT

 **1860 500 7788**

OTHER FINDINGS

IVC -15 MM, NORMAL SIZED, COLLAPSING, NORMAL RA PRESSURE

IMPRESSION

NORMAL CHAMBER DIMENSIONS
NORMAL VALVES
NORMAL PA PRESSURE
NO REGIONAL WALL MOTION ABNORMALITY
NORMAL LV SYSTOLIC FUNCTION
NO CLOT / EFFUSION / VEGETATION

DR .SAIKAT KANJILAL
CONSULTANT INTERVENTIONAL CARDIOLOGY



PRASAD.B
CARDIAC SONOGRAPHER

Note: investigations have their limitations solitary pathological/ Radiological and investigations never confirm the final diagnosis they are help in diagnosing the disease in correlation to clinical symptoms and other related tests. Please interpret accordingly ,this report is not for medico-legal Purpose

Apollo Health and Lifestyle Limited

(CIN - U85110TG2000PLC115819)

Regd. Office: 1-10-60/62, Ashoka Raghupathi Chambers, 5th Floor, Begumpet, Hyderabad, Telangana - 500 016.


Ph No: 040-4904 7777, Fax No: 4904 7744 | Email ID: enquiry@apollohl.com | www.apollohl.com

APOLLO CLINICS NETWORK KARNATAKA

Bangalore (Basavanagudi | Bellendur | Electronic City | Fraser Town | HSR Layout | Indira Nagar | JP Nagar | Kundalahalli | Koramangala | Sarjapur Road) **Mysore** (VV Mohalla)

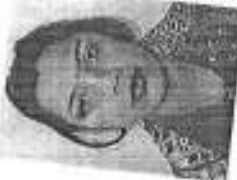Online appointments: www.apolloclinic.com

TO BOOK AN APPOINTMENT

 **1860 500 7788**



भारत सरकार
Government of India



ज्योती पण्डे
Jyoti Pandey

जन्म तिथि / DOB 09/08/1982
लिंग / Female



6768 6778 6100

आधार - आम आदमी का अधिकार

 Outlook


Health Check up Booking Request(22S31254), Package Code(Arcofemi MediWheel Full Body Annual Plus Check Advanced Female 2D ECHO)

From Wellness : Mediwheel : New Delhi <wellness@mediwheel.in>

Date Wed 14-08-2024 11:21

To rahul.pandey2@bankofbaroda.co.in <rahul.pandey2@bankofbaroda.co.in>

Cc Customer Care :Mediwheel : New Delhi <customercare@mediwheel.in>



011-41195959

Dear Rahul Pandey,

We have received your booking request for the following health checkup, please upload your approval letter as soon as possible to enable us to confirm your booking.

User Package Name : Mediwheel Full Body Health Checkup Female Above 40

Package Code : Arcofemi MediWheel Full Body Annual Plus Check Advanced Female 2D ECHO

Name of Diagnostic/Hospital : Apollo Clinic - Sarjapur Road

Address of Diagnostic/Hospital : Apollo Clinic, #769, GYR Chambers, Opp South Indian Bank, Kaikondanahalli, Sarjapur Road -560034

Appointment Date : 17-08-2024

Preferred Time : 09:00 am - 09:30 am

Member Information		
Booked Member Name	Age	Gender
Jyoti Pandey	42 year	Female

Tests Included In this Package

- Urine Analysis
- Blood Group
- CBC
- HbA1c
- Lipid Profile
- Kidney Profile
- Liver Profile
- Blood Glucose (Post Prandial)
- Thyroid Profile