

Name: Santosh Age: 51 Sex: M Date: 4/3/24  
Korgaonkar H/O HTN } ↓ medical  
 DM }

Rx

→ Teeth carious  $\frac{843}{876} \mid \frac{8}{67}$

- Root pieces  $\frac{8}{87} \mid \frac{8}{7}$

- Generalised plaque, calculus & stains ++

Rx required

→ Extrn  $\frac{8}{87} \mid \frac{8}{7}$

→ RCT  $\frac{6}{6} \mid \frac{6}{6}$

→ Restn  $\frac{43}{43} \mid \frac{43}{43}$

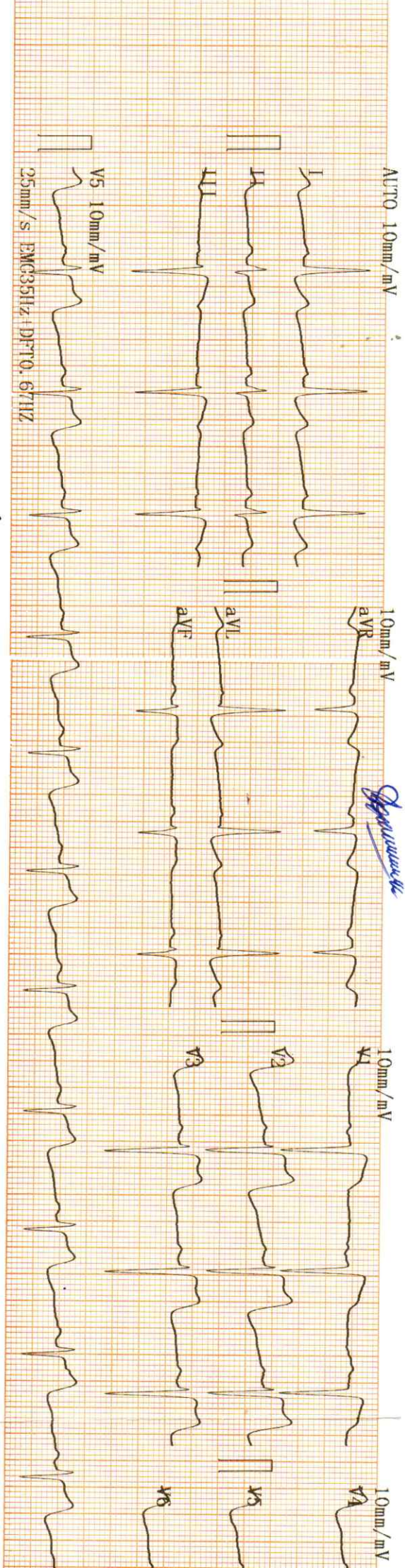
→ Oral prophylaxis

→ PD  $\frac{7}{7} \mid \frac{7}{7}$

→ FC  $\frac{6}{6} \mid \frac{6}{6}$



*[Signature]*  
**Dr. Nijita R. Madhukar**  
 B.D.S., M.D.S. (GO)  
 Consulting Prosthodontist & Implantology  
 Reg. No: A-758



AUTO 10mm/mV

10mm/mV

10mm/mV

10mm/mV

I

II

III

aVR

aVL

aVF

V1

V2

V3

V4

V5

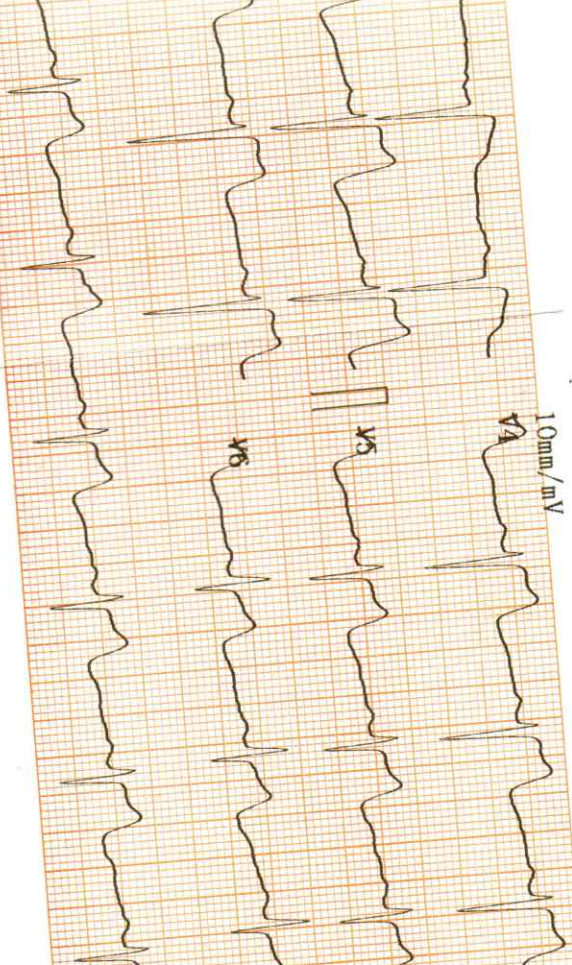
V6

V5 10mm/mV

25mm/s EMG35Hz+DF10.67Hz

*[Signature]*

2024-03-04 09:26



10mm/mV

VA V5 V6

ID : santosh korgaonkar  
 Name : Male  
 Sex : Age : 51  
 Height : cm  
 Weight : kg  
 SYS : mmHg  
 DIA : mmHg

HR : 71 bpm  
 PR Interval : 176 ms  
 P Duration : 120 ms  
 QRS Duration : 85 ms  
 T Duration : 172 ms  
 QT/QTc : 356/386 ms  
 P/QRS/T Axis : 46.4/-23.2/93.0 deg  
 R (V5) / S (V1) : 0.34/1.10 mV  
 R (V5) / S (V1) : 1.43 mV



Physician

**DR. SUDHIR SHET**  
 M.D.  
 CONSULTANT PHYSICIAN  
 Reg. No.: GMC 3776

<< Conclusions >>

Normal Sinus Rhythm,  
 Middling left axis deviation,  
 ST depression, high lateral myocardial ischemia.

**DR. O. MORAES DE SOUZA**

M.S (BOM.), D.O.M.S. (C.P.S)

Ex -Sr. Ophthalmic Surgeon - Hospicio Hospital  
EYE SPECIALIST & MICRO - SURGEON

**Clinic :**

Ashirwad Bldg. II,  
Above City Hospital,  
Opp. Meenaxi Hotel,  
MARGOA - GOA - 403601  
Tel.: (C) 2713804 / 8237886021

**Timings :**

Morning : 10 a.m. to 1p.m.  
Evening : 4.30 p.m to 7 p.m.  
Except SATURDAY EVENINGS  
& SUNDAYS

Date 4/3/24

Santosh. Kargantkar

No complaints.

VA 6/6 for distance

Near vision N/5

Colour vision: Normal

Fundus: Normal B/E

  
DR. O. MORAES DE SOUZA  
M.S (Bom.), D.O.M.S. (C.P.S.)  
Ex -Sr. Ophthalmic Surgeon - Hospicio Hospital  
EYE SPECIALIST & MICRO - SURGEON  
Reg. No. GMC 410

Please bring this prescription on your next visit.

# CITY ULTRASOUND CLINIC

Dr Madkaiker's City hospital  
"Ashirwad bldg" 1<sup>st</sup> floor,  
Opp Meenaxi hotel  
Isidor Baptista road,  
Margao- Goa 403601

Name: MR SANTOSH KORGAONKER  
Age: 51 years/M.

Ref: CITY HOSPITAL/Mediwheel  
Date: 4/3/2024

## ABDOMINAL SONOGRAPHY

### LIVER

Liver parenchyma shows bright echotexture  
Size of liver WITHIN NORMAL LIMITS  
No echogenic or echolucent mass lesion seen.  
Intrahepatic branching of hepatic & portal radicles within  
Normal limits.  
No abscess formation noted. No cyst or hematoma.  
Epigastria tenderness NIL

### GALL-BLADDER:

Well DISTENDED no evidence of biliary calculi.  
No free fluid around gall bladder

### SPLEEN

: Normal in size 11x7.3cms with no any focal lesion.

### PANCREAS

: Maintained in its size with normal echotexture. No per pancreatic fluid seen

### RIGHT KIDNEY:

Measures 9.4 x 5.3cms.  
Pelvi -calyceal system appears normal.  
No hydronephrosis.

### LEFT KIDNEY :

Measures 10. X 5.1 cms  
Echotexture is normal.

### PARA AORTIC REGION

: Appears Normal.  
No free fluid seen

### URINARY BLADDER

: Fully distended.  
No free fluid in abdomen. Wall thickening present 4mm

### Prostate:

, Normal echotexture vol 37.22 CC

### IMPRESSION:

Fatty Liver  
Prostatomegaly



SONOLOGIST  
CITY HOSPITAL  
Dr R MADKAIKER





सत्यमेव जयते

भारत सरकार

GOVERNMENT OF INDIA

Issue Date: 04/02/2012



Santosh Gokuldas Korgaonkar

जन्म तिथि / DOB: 20/06/1973

पुरुष / MALE

Mobile No.: 9730231759

**5058 4107 4514**

VID : 9102 4646 2630 9491

मेरा **आधार**, मेरी पहचान

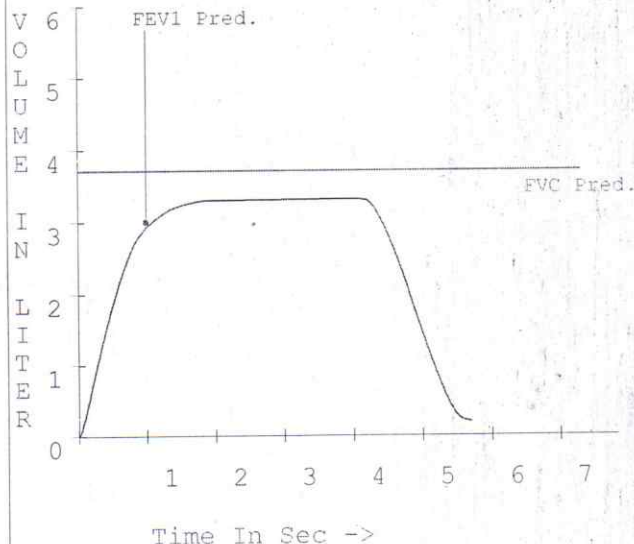
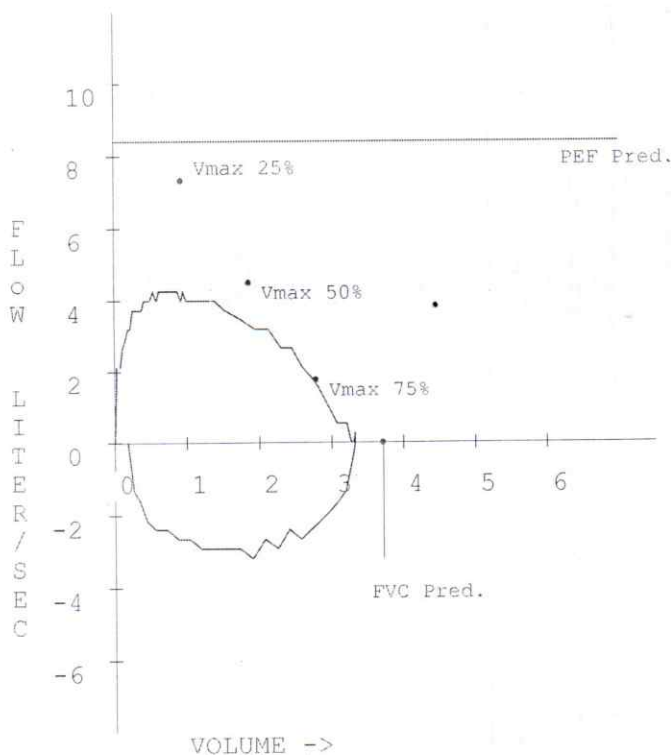
**Dr.Madkaiker's CITY HOSPITAL**  
**Margao Goa**

**Patient Information**

Name : **Santosh Gokuldas Korgaonkar** DATE : 04/03/24 10:28:07

AGE : 51 /M ID : 237 Height : 170  
REF.BY : Dr.Mediwheel Weight : 82  
Indication: Smoker : Non Smoker

Pre \_\_\_\_\_  
Post \_\_\_\_\_



Parameter	Predict Value	Observed		Pre.dif%
		Pre	%Pred	
FVC (L)	3.71	3.32	89.38	
FEV0.5 (L)		1.82		
FEV1 (L)	3.01	2.92	97.12	
FEV1/FVC %	80.97	87.98	108.65	
PEF (L/S)	8.40	4.39	52.27	
PIF (L/S)		3.19		
FEF25-75% (L/S)	3.81	3.37	88.58	
VMax25 %	7.33	4.39	59.84	
VMax50 %	4.51	3.59	79.58	
VMax75 %	1.77	2.39	135.16	
FET100 %		4.07		
FEF50 % (L/S)		3.59		
FIF50 % (L/S)		2.79		
FEF50/FIF50 %		1.29		



**Diagnosis :**

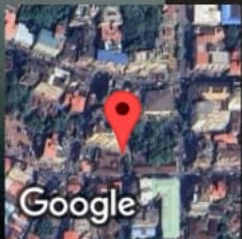
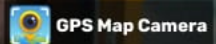
Normal Spirometry ( FVC and FEV1/FVC > 80% of Predicted value )  
Lung Age : 54

**Dr. Raj R. Madkaiker**  
MBBS, DGO, DMAS, FMAS, AFM  
GMC Reg. No. 3474

*[Handwritten signature]*

Dr. \_\_\_\_\_

Dr. Raj R. Madkaikar  
M. B. B. S. D.G.O. D.M.A.S. F.I.C.S. AFIH  
Consulting Obstetrician & Gynaecologist  
Laparoscopist & Assisted Reproductive Medicine



## Margao, Goa, India

Isidor Baptista road City hospital, Ashirwad building first floor,  
opposite Meenaxi Hotel, Pajifond, Margao, Goa 403601, India  
Lat 15.272167°

Long 73.961546°

04/03/24 09:08 AM GMT +05:30



Dr. Madkaikar's  
**CITY HOSPITAL**

4/3/24

Mr. Santosh Gokuldas Forgaonkar  
Age : 51yrs

Patient Doesn't want to do TMT  
because of the knee problem.



*Handwritten signature/initials*

*Handwritten signature*

---

**CONS. / HOSP.:**  
ASHIRWAD BLDG., 1ST FLOOR, OPP. MINAXI HOTEL,  
MARGAO - GOA. PH.: 0832-2714354 (HOSP.) Cell : 9784788585

---

# CITY LAB

(clinical laboratory)

Dr Madkaikar's City hospital

"Ashirwad bldg, 1<sup>st</sup> floor ,

opp meenaxi hotel,

Isidor Baptista road,

Margao- Goa 403601

Ph. : 2714354

NAME: Mr. Santosh Koregaunkar

51 yrs/M

Date: 04-03-2024

REF. BY: MEDI WHEEL

## BLOOD BIOCHEMISTRY

TEST	PATIENT'S VALUE	NORMAL RANGE
Fasting Blood Glucose	<b>217.0</b> mg./dl	70-110 mg./dl
Post Prandial Glucose	<b>305.0</b> mg./dl	Upto 145 mg./dl
<b>RFT</b>		
Blood Urea	32.0 mg./dL	14-40mg./dL
Serum Creatinine	1.0 mg./dL	0.5-1.4mg./dL
Serum Uric Acid	3.4 mg./dL	M: 2.4-7.0 F: 2.4-6.0mg./dL
BUN	10.0 mg./dl	5-25 mg/dl
<b>LFT</b>		
Total Bilirubin	0.8 mg./dL	0.2-1.0 mg./dL
Direct Bilirubin	0.2 mg./dL	0.1-0.2 mg./dL
Indirect Bilirubin	0.6 mg./dL	Up to 0.8 mg/dl
S.G.P.T	27.0 Units/L	0-49 units/L
S.G.O.T	23.0 Units/L	0-46 units/L
Alkaline Phosphatase	195.0 Units/L	108-306 units/L
Total Protein	7.0 gm./dL	6-8 gm.dL
Albumin	4.0 gm./dL	3.5-5.5gm./dL
Globulin	3.0 gm./dL	1.8-3.6gm/dL
A/G	1.3	1.2-2.1
<b>LIPID PROFILE</b>		
Serum Cholesterol	189.0 mg./dL	25- 260 mg./dL
Serum Triglycerides	125.0 mg./dL	M:60-165 F:40 140mg./dL
HDL Cholesterol	40.0 mg./dL	M:30-63 F: 35- 75 mg./dL
LDL Cholesterol	124.0 mg./dL	Upto 145 mg./dL
Total Chol/HDL Chol Ratio	4.4	2-5
LDL Chol/HDL Chol Ratio	2.7	Up to 3.5
Sr. GGT	35.0 Units/L	Upto 50 U/L



Dr. Shet Sunayana Sudhir  
M.D. (Path.)  
Reg. No. GMC 3311

Pathologist/Analyst

# CITY LAB

(clinical laboratory)

Dr Madkaikar's City hospital  
"Ashirwad bldg, 1<sup>st</sup> floor ,  
opp meenaxi hotel,  
Isidor Baptista road,  
Margao- Goa 403601  
Ph. : 2714354

NAME: Mr. Santosh Koregaunkar

51 yrs/M

Date: 04-03-2024

REF. BY: MEDI WHEEL

## COMPLETE HAEMOGRAM

		MALE	FEMALE
Haemoglobin	14.2 gm%	(13.0-18)	(11.5-16.5)
PCV	40.0 cc%	(40-50)	(37-47)
ESR(westergren's method)	10 mm/hr	(up to 15)	(up to 20)
R.B.C COUNT	5.2 millions/cmm	(4.5-6.0)	(4.0-5.5)

### Erthrocytes Indices

MCH	31 pg	27-32
MCHC	32 %	32-36
MCV	91 cu-microns	82-92
Platelet Count	2,12,000 cells/cmm	(150,000-500,000)
Total W.B.C Count	7,200 /cmm	(4,000-10,000)

### Differential Count

Neutrophils	61 %	(50-70)
Lymphocytes	29 %	(20-50)
Eosinophils	05 %	(0-8)
Basophils	00 %	(0-2)
Monocytes	05 %	(0-8)



Dr. Shet Sunayana Sudhir  
M.D. (Path.)  
Reg. No. GMC 3311

Pathologist/Analyst

# CITY LAB

(clinical laboratory)

Dr Madkaikar's City hospital  
"Ashirwad bldg, 1<sup>st</sup> floor ,  
opp meenaxi hotel,  
Isidor Baptista road,  
Margao- Goa 403601  
Ph. : 2714354

NAME: Mr. Santosh Koregaunkar

51 yrs/M

Date: 04-03-2024

REF. BY: MEDI WHEEL

## EXAMINATION OF URINE

### PHYSICAL EXAMINATION

Colour ... Pale yellow

Odour ... Ammonical

Appearance ..... Clear

pH. .... 6.0

Sp. Gravity ...1.010

Deposits ...Nil

### CHEMICAL EXAMINATION

Albumin ... Absent

Sugar ... Absent

Ketone bodies ...Nil

Bilirubin ....Nil

Occult Blood ... Nil

Urobilinogen.... Nil

### MICROSCOPIC EXAMINATION

Pus cells/HPF ..... 1-2

R.B.C.s /HPF ..... Nil

Epithelial Cells/HPF ... 1-2

Crystals/HPF .....Nil

Casts/HPF .....Nil

### OTHER FINDINGS : Nil



Dr. Shet Sunayana Sudhir  
M.D. (Path.)  
Reg. No. GMC 3311

Pathologist/Analyst

# CITY LAB

(Clinical laboratory)

Dr Madkaikar's City hospital  
"Ashirwad bldg, 1<sup>st</sup> floor ,  
opp meenaxi hotel,  
Isidor Baptista road,  
Margao- Goa 403601  
Ph. : 2714354

NAME: Mr. Santosh Koregaunkar

51 yrs/M

Date: 04-03-2024

REF. BY: MEDI WHEEL

## X-RAY Chest PA

Lungs are clear.

Hilar and the mediastinal shadows are normal.

Pleura, the c.p angles are clear.

Cardiac aortic Silhouette is normal

Soft tissues of the chest wall and Bony cage are normal.

Impression: Normal



*Dr. R.N. Madkaikar*  
M.D.; D.G.O., D.F.P. C.P.S.  
Reg. No. GMC 689  
Medical Director

# CITY LAB

(Clinical laboratory)

Dr Madkaikar's City hospital  
"Ashirwad bldg, 1<sup>st</sup> floor ,  
opp meenaxi hotel,  
Isidor Baptista road,  
Margao- Goa 403601  
Ph. : 2714354

NAME: Mr. Santosh Koregaunkar

51 yrs/M

Date: 04-03-2024

REF. BY: MEDI WHEEL

---

## General Examination & Lifestyle

Height: 170cms

Weight: 82kgs      BMI : 28.4

B.P: 130/80mHg      Diet : Mix

Pulse Rate: 71per min

**Personal H/o:** 1) illness, fracture, operation, hospitalization, Hypertension, Diabetes and IHD : No

**Past/ Family H/o:** Diabetes, TB, Asthma, Hypertension, Allergy and IHD : No

## System Examination

CVS: Normal      RS : Normal

CNS: Normal

Abdomen: Normal

## Others

Hernia: Nil

Varicose Veins: Nil

Extremities: Nil

Deformities: Nil

Skin: Normal



Dr. Shet Sunayana Sudhir  
M.D. (Path.)  
Reg. No. GMC 3311

Pathologist/Analyst

# CITY LAB

(Clinical laboratory)

Dr Madkaikar's City hospital  
"Ashirwad bldg, 1<sup>st</sup> floor ,  
opp meenaxi hotel,  
Isidor Baptista road,  
Margao- Goa 403601  
Ph. : 2714354

NAME: Mr. Santosh Koregaunkar

51 yrs/M

Date: 04-03-2024

REF. BY: MEDI WHEEL

## THYROID FUNCTION TEST

<u>Investigation</u>	<u>Observed Value</u>	<u>Ref. Range</u>	<u>Unit</u>
T3	145	80 - 200	ng/dL
T4	5.2	4.8-12.7	µg/dl
TSH	2.58	0.55 – 4.78	µIU/ml

Sample : Serum.

Method : FULLY AUTOMATED ELFA METHOD

## REPORT

<i>TEST</i>	<i>PATIENT'S VALUE</i>	<i>REFERANCE RANGE</i>
<b>PROSTATE SPECIFIC ANTIGEN (PSA)</b>  (TECHNOLOGY C.L.I.A)	0.53 ng/mL	Normal : < 4.00 ng/ml Border line : 4.01 to 10.00 ng/ml

## GLUCOSE TEST

Time	Blood Sugar	Urine sugar
'0' Hrs (fasting)	<b>217.0</b> mg/dl	++
2Hrs.after Breakfast	<b>305.0</b> mg/dl	++



Dr. Shet Sunayana Sudhir  
M.D. (Path.)  
Reg. No. GMC 3311

Pathologist/Analyst

# CITY LAB

(Clinical laboratory)

Dr Madkaikar's City hospital  
"Ashirwad bldg, 1<sup>st</sup> floor ,  
opp meenaxi hotel,  
Isidor Baptista road,  
Margao- Goa 403601  
Ph. : 2714354

NAME: Mr. Santosh Koregaunkar

51 yrs/M

Date: 04-03-2024

REF. BY: MEDI WHEEL

## REPORT

TEST	PATIENT'S VALUE	REFERANCE RANGE
1) 25 OH- VITAMIN D (TOTAL)  (TECHNOLOGY C.L.I.A)	18.0 ng/ml	DEFICIENCY : <20 ng/ml INSUFFICIENCY : 20-<30 ng/ml SUFFICIENCY : 30-100 ng/ml TOXICITY : >100 ng/ml
2) VITAMIN B-12	374 pg/ml	211-911 pg/ml

TEST	RESULT	UNITS	NORMAL RANGE
GLYCOSYLATED HB (HbA1c) (A.B.G – 206.0 mg/dl)	9.1	%	Normal : Up to 6% Good control : 6-7 % Fair control : 7-8 % Unsatisfactory: 8-10 % Poor control : > 10

### EYE CHECKUP :

- Far Vision : Right Eye- 6/6      Left Eye- 6/6 (With Glasses)
- Near Vision : Right Eye – N/5      Left Eye-N/6 (With Glasses)
- Color Vision:      Normal.



Dr. Shet Sunayana Sudhir  
M.D. (Path.)  
Reg. No. GMC 3311

Pathologist/Analyst