



Wt: - 73 kgs
Ht: 164 cms
Bmi: 27.2



17/8/21

Yadav Bathini Anil Kumar
Age: - 30 male.
Bp: 110/80 mmHg.

Dr. M. Tafazzul Hussain
MBBS,
General Physician
Regd. No: 19584

17/8/2021
10:00 AM

Self - Medical Health Checkup.

Bp: 110/80 mmHg

Abdomen

Max/Fem/Oral cavity - N/A

Ht: JVP S4 NO MURMUR

Chest. Cli. Clear (R/L)

A&O: Mict/Bml NO

Ext Genti: N/A

Cms: N/A

Junt: N/A

Skin: @

Clinical Exam Seemed
Healthy.

Past Hx:

tho Covid-19 - 4 months
R- Home Isolation
Treated by
Hosp

Vaccinated:
Covid - 19

Shales...
No H/O, NO SW
No Asthma
No HTN
No Diabetes

no smoking
family - H/O

MAL - H/O - R

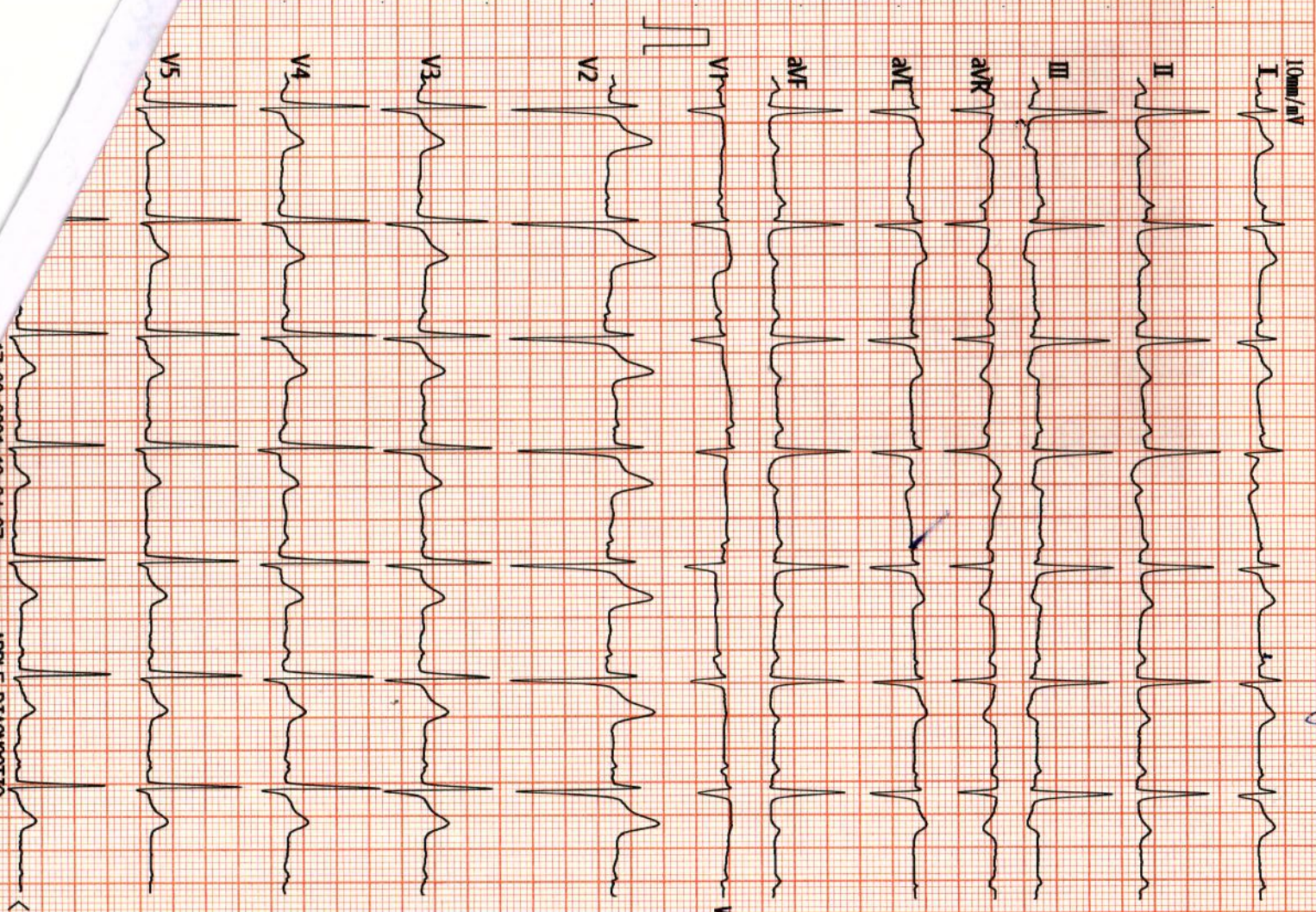
father - CAD - 50

Mother - 2 hrs
one daughter
2 yrs

Dr. Hussain

Dr. M. TAFAZZUL HUSSAIN
MBBS
General Physician
Regd. No.: 19584

wt: - 73 kgs



Vent. Rate(BPM) : 86

PR Int.(ms) : 148

P/QRS/T Int.(ms) : 115 99 165

QT/QTc Int.(ms) : 342 412

P/QRS/T Axis(Deg) : 71 90 42

RV1/SV5 Amp.(mV) : 0.06 0.13

RV5/SV1 Amp.(mV) : 1.40 0.48

<ECG Analysis Result>

800 Normal Sinus Rhythm

*** Normal ECG ***

Technician : V2.35

Note: Unconfirmed Report Need to Review.

Normal

| | I | II | III | aVR | aVL | aVF |
|--------------|-------|-------|-------|-------|-------|-------|
| ST LEVEL(mV) | +0.03 | +0.00 | -0.02 | -0.01 | +0.03 | -0.01 |
| | V1 | V2 | V3 | V4 | V5 | V6 |
| | +0.02 | +0.12 | +0.04 | +0.03 | +0.01 | +0.01 |

2-08-2021 10-34-07

APPL E DIAGNOSTIC

> 0000000000 M 82Y

/ cm/Kg

/ ml/kg



Name : **YADAV BATHINI ANIL KUMAR**
 Age/Gender : 30YEARS/MALE
 Sample Type : --
 Reff By : MEDIWHEEL

Patient Id : 5315
 Sample Drawn Date : 17-Aug-2021
 Reported Date : 17-Aug-2021

HEMATOLOGY

| TEST DESCRIPTION | RESULT | UNITS | REFERENCE RANGE |
|---|-------------------------|------------|--|
| COMPLETE BLOOD COUNT | | | |
| Hemoglobin | 16.0 | gm/dL | Male : 13.0 - 18.0 Female : 11.5 - 16.0 |
| Erythrocyte Count (RBC Count) | 5.3 | mill/uL | Male : 4.5 - 5.5 Female : 3.8 - 4.8 |
| Hematocrit (HCT) | 48.2 | % | Male : 40 - 54 Female : 35 - 47 |
| Platelet (Method :Cell Counter) | 3.0 | lakhs/cumm | 1.50 - 4.50 |
| Red Cell Indices | | | |
| MCV | 79 | fl | 83 - 101 |
| MCH | 26 | pg | 27 - 32 |
| MCHC (Method :Cell Counter) | 33 | pg | 31.5 - 34.5 |
| Total Count and Differential Count | | | |
| Total WBC Count | 6,100 | cells/cumm | 4000 - 11000 |
| Nuetrophils | 55 | % | 40 - 75 |
| Lymphocytes | 40 | % | 20 - 40 |
| Eosinophils | 03 | % | 0 - 6 |
| Monocytes | 02 | % | 2 - 10 |
| Basophils (Method :Cell Counter) | 00 | % | 0 - 1 |
| MICROSCOPIC BLOOD PICTURE | | | |
| RBC Morphology | NORMOCYTIC/NORMOCHROMIC | | |
| WBC Morphology | NORMAL IN MORPHOLOGY | | |
| Platelete Morphology | ADEQUATE | | |
| Method: Cell Counter | | | |

-----End of the Report-----

DR. S. V. RAMANA MD.,
Chief Pathologist

Assay result should be correlated clinically with other laboratory finding and the total clinical status of the patient.
 Note : This Report is subject to the terms and conditions mentioned overleaf
 Note : PARTIAL REPRODUCTION OF THIS REPORT IS NOT PERMITTED



APPLE DIAGNOSTIC

— MEDICAL SERVICES —

AN ISO CERTIFIED



Name : **YADAV BATHINI ANIL KUMAR**
Age/Gender : 30YEARS/MALE
Sample Type : --
Reff By : MEDIWHEEL

Patient Id : 5315
Sample Drawn Date : 17-Aug-2021
Reported Date : 17-Aug-2021

HEMATOLOGY

| TEST DESCRIPTION | RESULT | UNITS | REFERENCE RANGE |
|--|--------|-------|-----------------|
| ERYTHROCYTE SEDIMENTATION RATE(ESR) | | | |
| FIRST HOUR | 05 | mm | 1 - 10 |
| -----End of the Report----- | | | |



DR. S. V. RAMANA MD.,
Chief Pathologist

Assay result should be correlated clinically with other laboratory finding and the total clinical status of the patient.
Note : This Report is subject to the terms and conditions mentioned overleaf
Note : PARTIAL REPRODUCTION OF THIS REPORT IS NOT PERMITTED

A Unit of **Avanthy Health Care PVT. LTD.**

Note: This Report is subject to the terms and conditions mentioned overleaf
web: www.applediagnostic.com
e-mail: applediagnostichyd@gmail.com

Healthy testing for Healthy living



Name : **YADAV BATHINI ANIL KUMAR**
Age/Gender : 30YEARS/MALE
Sample Type : WB EDTA
Reff By : MEDIWHEEL

Patient Id : 5315
Sample Drawn Date : 17-Aug-2021
Reported Date : 17-Aug-2021

HEMATOLOGY

| TEST DESCRIPTION | RESULT | UNITS | REFERENCE RANGE |
|--|----------|-------|-----------------|
| Blood Grouping (A B O) and Rh typing* | | | |
| Blood Grouping (ABO) | "O" | | |
| Rh Typing | Positive | | |
| Method: Tube method | | | |

-----End of the Report-----



DR. S. V. RAMANA MD.,
Chief Pathologist

Assay result should be correlated clinically with other laboratory finding and the total clinical status of the patient.
Note : This Report is subject to the terms and conditions mentioned overleaf
Note : PARTIAL REPRODUCTION OF THIS REPORT IS NOT PERMITTED

Healthy testing for Healthy living



Name : **YADAV BATHINI ANIL KUMAR**
Age/Gender : 30YEARS/MALE
Sample Type : --
Reff By : MEDIWHEEL

Patient Id : 5315
Sample Drawn Date : 17-Aug-2021
Reported Date : 17-Aug-2021

CLINICAL BIOCHEMISTRY

| TEST DESCRIPTION | RESULT | UNITS | REFERENCE RANGE |
|---|--------|-------|-----------------|
| FBS & PLBS | | | |
| Fasting Blood Sugar | 102 | mg/dl | 60 - 110 |
| Fasting Urine Glucose (Method :Strip) | NIL | | |
| Post Prandial Blood Sugar - PLBS | 126 | mg/dL | 110 - 160 |
| Post Prandial Urine Glucose (Method :Strip) | NIL | | |

-----End of the Report-----



DR. S. V. RAMANA MD.
Chief Pathologist

Assay result should be correlated clinically with other laboratory finding and the total clinical status of the patient.
Note : This Report is subject to the terms and conditions mentioned overleaf
Note : PARTIAL REPRODUCTION OF THIS REPORT IS NOT PERMITTED



Name : **YADAV BATHINI ANIL KUMAR**
Age/Gender : 30YEARS/MALE
Sample Type : EDTA BLOOD
Reff By : MEDIWHEEL

Patient Id : 5315
Sample Drawn Date : 17-Aug-2021
Reported Date : 17-Aug-2021

CLINICAL BIOCHEMISTRY

| TEST DESCRIPTION | RESULT | UNITS | REFERENCE RANGE |
|----------------------------------|--------|-------|---|
| GHB/HbA1c | | | |
| GLYCOSYLATED HAEMOGLOBIN (HbA1c) | 5.7 | | < 6.0 : Non Diabetic 6.0 - 7.0 : Good Control 7.0 - 8.0 : Poor Control > 8 : Alert |

-----End of the Report-----



DR. S. V. RAMANA MD.
Chief Pathologist

Assay result should be correlated clinically with other laboratory finding and the total clinical status of the patient.
Note : This Report is subject to the terms and conditions mentioned overleaf
Note : PARTIAL REPRODUCTION OF THIS REPORT IS NOT PERMITTED

Healthy testing for Healthy living



Name : **YADAV BATHINI ANIL KUMAR**
 Age/Gender : 30YEARS/MALE
 Sample Type : --
 Reff By : MEDIWHEEL

Patient Id : 5315
 Sample Drawn Date : 17-Aug-2021
 Reported Date : 17-Aug-2021

CLINICAL BIOCHEMISTRY

| TEST DESCRIPTION | RESULT | UNITS | REFERENCE RANGE |
|--|--------|-------|---|
| LIPID PROFILE | | | |
| Total Cholesterol (Method :CHOD/PAP) | 165 | mg/dL | <200:Desirable 200 - 239 : Borderline risk >240:High Risk |
| Cholesterol - HDL (Method :Direct) | 33 | mg/dL | < 40 : Low 40 - 60 : Optimal > 60 : Desirable 0 - 5.0 |
| Total cholesterol/HDL ratio (Method :Calculated) | 5.0 | | 0 - 5.0 |
| Cholesterol - LDL (Method :Calculated) | 96 | mg/dL | < 100 : Normal 100 - 129 : Desirable 130 - 159 : Borderline-High 160 - 189 : High > 190 : Very High |
| Cholesterol VLDL (Method :Calculated) | 36 | mg/dL | 7-40 |
| Triglycerides (Method :Lipase/Glycerol Kinase) | 182 | mg/dL | < 150 :Normal 150-199 :Borderline-High 200-499 :High > 500 :Very High |

-----End of the Report-----

DR. S. V. RAMANA MD.
Chief Pathologist

Assay result should be correlated clinically with other laboratory finding and the total clinical status of the patient.
 Note : This Report is subject to the terms and conditions mentioned overleaf
 Note : PARTIAL REPRODUCTION OF THIS REPORT IS NOT PERMITTED

Healthy testing for Healthy living



Name : **YADAV BATHINI ANIL KUMAR**
 Age/Gender : 30YEARS/MALE
 Sample Type : --
 Ref By : MEDIWHEEL

Patient Id : 5315
 Sample Drawn Date : 17-Aug-2021
 Reported Date : 17-Aug-2021

CLINICAL BIOCHEMISTRY

| TEST DESCRIPTION | RESULT | UNITS | REFERENCE RANGE |
|------------------|--------|-------|---------------------------------------|
| KID-PRO | | | |
| SERUM CREATININE | 1.0 | mg/dL | Male : 0.8 - 1.5 Female: 0.8 - 1.4 |
| BLOOD UREA | 26 | mg/dL | 15 - 45 |
| SERUM URIC ACID | 6.1 | mg/dL | Male : 3.4 - 7.0 Female: 2.4 - 5.7 |
| SERUM CALCIUM | 9.4 | mg/dL | 8.4 - 10.5 |

-----End of the Report-----



DR. S. V. RAMANA MD.
Chief Pathologist

Assay result should be correlated clinically with other laboratory finding and the total clinical status of the patient.

Note : This Report is subject to the terms and conditions mentioned overleaf

Note : PARTIAL REPRODUCTION OF THIS REPORT IS NOT PERMITTED

A Unit of Avanthi Health Care PVT. LTD.

Note: This Report is subject to the terms and conditions mentioned overleaf

web: www.applediagnostic.com

e-mail: applediagnostichyd@gmail.com

Hearing testing for hearing loss



Name : **YADAV BATHINI ANIL KUMAR**
Age/Gender : 30YEARS/MALE
Sample Type : --
Reff By : MEDIWHEEL

Patient Id : 5315
Sample Drawn Date : 17-Aug-2021
Reported Date : 17-Aug-2021

CLINICAL BIOCHEMISTRY

| TEST DESCRIPTION | RESULT | UNITS | REFERENCE RANGE |
|----------------------------------|--------|--------|--|
| LIVER FUNCTION TEST (LFT) | | | |
| BILIRUBIN - TOTAL | 1.0 | mg/dL | Upto 1.0 |
| BILIRUBIN - DIRECT | 0.2 | mg/dL | 0.0 - 0.2 |
| BILIRUBIN - INDIRECT | 0.8 | mg/dL | 0.0 - 0.8 |
| S.G.O.T | 30 | U/L | UP TO 35 |
| S.G.P.T | 27 | IU/L | UP TO 40 |
| ALKALINE PHOSPHATASE | 65 | U/L | Adults : 15 - 112 Children : 45 - 325 |
| TOTAL PROTEINS | 6.9 | Gms/dL | 6.0 - 8.0 |
| ALBUMIN | 4.3 | Gms/dL | 3.5 - 5.0 |
| GLOBULIN | 2.6 | Gms/dL | 1.5- 3.5 |
| A / G Ratio | 1.6 | | |
| G.G.T | 20 | U/L | Male : 10 - 50 Female : 05 - 30 |

-----End of the Report-----

DR. S. V. RAMANA MD.
Chief Pathologist

Assay result should be correlated clinically with other laboratory finding and the total clinical status of the patient.
Note : This Report is subject to the terms and conditions mentioned overleaf
Note : PARTIAL REPRODUCTION OF THIS REPORT IS NOT PERMITTED



APPLE DIAGNOSTIC

— MEDICAL SERVICES —

AN ISO CERTIFIED



Name : **YADAV BATHINI ANIL KUMAR**
Age/Gender : 30YEARS/MALE
Sample Type : --
Reff By : MEDIWHEEL

Patient Id : 5315
Sample Drawn Date : 17-Aug-2021
Reported Date : 17-Aug-2021

CLINICAL BIOCHEMISTRY

| TEST DESCRIPTION | RESULT | UNITS | REFERENCE RANGE |
|-----------------------------------|--------|--------|-----------------|
| Thyroid Profile | | | |
| TOTAL TRIIODOTHYRONINE (T3) | 149.31 | ng/dL | 60 - 181 |
| TOTAL THYROXINE (T4) | 10.35 | ug/dL | 6.09 - 12.23 |
| THYROID STIMULATING HORMONE (TSH) | 2.71 | μIU/mL | 0.35 - 5.50 |

-----End of the Report-----



DR. S. V. RAMANA MD.
Chief Pathologist

Assay result should be correlated clinically with other laboratory finding and the total clinical status of the patient.
Note : This Report is subject to the terms and conditions mentioned overleaf
Note : PARTIAL REPRODUCTION OF THIS REPORT IS NOT PERMITTED

A Unit of **Avanthy Health Care PVT. LTD.**

Note: This Report is subject to the terms and conditions mentioned overleaf
web: www.applediagnostic.com
e-mail: applediagnostichyd@gmail.com

Healthy testing for Healthy living



Name : **YADAV BATHINI ANIL KUMAR**
 Age/Gender : 30YEARS/MALE
 Sample Type : --
 Reff By : MEDIWHEEL

Patient Id : 5315
 Sample Drawn Date : 17-Aug-2021
 Reported Date : 17-Aug-2021

CLINICAL PATHOLOGY

| TEST DESCRIPTION | RESULT | UNITS | REFERENCE RANGE |
|------------------|--------|-------|-----------------|
|------------------|--------|-------|-----------------|

CUE- (OP)

PHYSICAL EXAMINATION

| | |
|------------------|-------------|
| Quantity | 10 ml |
| Colour | PALE YELLOW |
| Clarity | CLEAR |
| Reaction (pH)* | Acidic |
| Specific gravity | 1.020 |

CHEMICAL EXAMINATION

| | |
|---------------|--------|
| Albumin | Nil |
| Sugar | Nil |
| Bile salts | Absent |
| Bile pigments | Absent |

MICROSCOPIC EXAMINATION

| | | |
|------------------|--------|-------|
| PUS CELLS | 2-3 | / HPF |
| Epithelial Cells | 1-2 | / HPF |
| R.B.Cs | Nil | |
| CASTS | Nil | |
| CRYSTALS | Nil | |
| OTHERS | Absent | |

Method: Strip/Microscopy

-----End of the Report-----

DR. S. V. RAMANA MD.
Chief Pathologist

Assay result should be correlated clinically with other laboratory finding and the total clinical status of the patient.
 Note: This Report is subject to the terms and conditions mentioned overleaf
 Note: PARTIAL REPRODUCTION OF THIS REPORT IS NOT PERMITTED

Healthy testing for Healthy living

2D ECHO CARDIOGRAM – COLOUR DOPPLER REPORT

Name of the Patient : MR.YADAV BATHINI ANIL KUMAR

Age -/Sex30/MALE

BILL NUMBER :5315

DATE: 17/08/2021

MITRAL VALVE : NORMAL
AORTIC VALVE : NORMAL
TRICUSPID VALVE : Normal
PULMONARY VALVE : normal
RIGHT ATRIUM : normal
RIGHT VENTRICLE : Normal
LEFT ATRIUM : 3.0 cm
LEFT VENTRICLE : IVSD – 0.9 Cm LVEDD — 4.4 cm, EF –68 %
PWD - 0.8 cm LVEDD – 2.5 cm
RWMA : NO RWMA OF LV
IAS : Intact
IVS : Intact
AORTA : 2.7 cm
PULMONARY ARTERY : Normal
PERICARDIUM : Normal
PULMONARY VEINS : Normal
SVC / IVC / CORONARY SINUS : Normal
INTRACARDIAC MASSES : Normal
OTHERS :
DOPPLER STUDY : MITRAL E/A : E > A

AORTIC JET VEL: 1.1 m/sec

PULM. JET VEL : 0.9 mt/sec

TRICUSPID VEL : mt/sec, RVSP - mmHg

CONCLUSION:


NO RWMA OF LV

NORMAL LV FUNCTION

NORMAL VALVES AND CHAMBERS

TRIVIAL TR, NO PAH

NO PERICARDIAL EFFUSION/CLOT


CONSULTANT CARDIOLOGIST

A Unit of Avanathi Health Care PVT. LTD.

266, Main Road, Vivekananda Nagar, Kukatpally, Hyderabad-500 072., P: 040-23 16 11 20, M: +91 8008804014

S.R. Nagar Circle, Near Umesh Chandra Statue, Hyderabad-500 038., P: 040-29 56 56 56, M: +91 8008804014

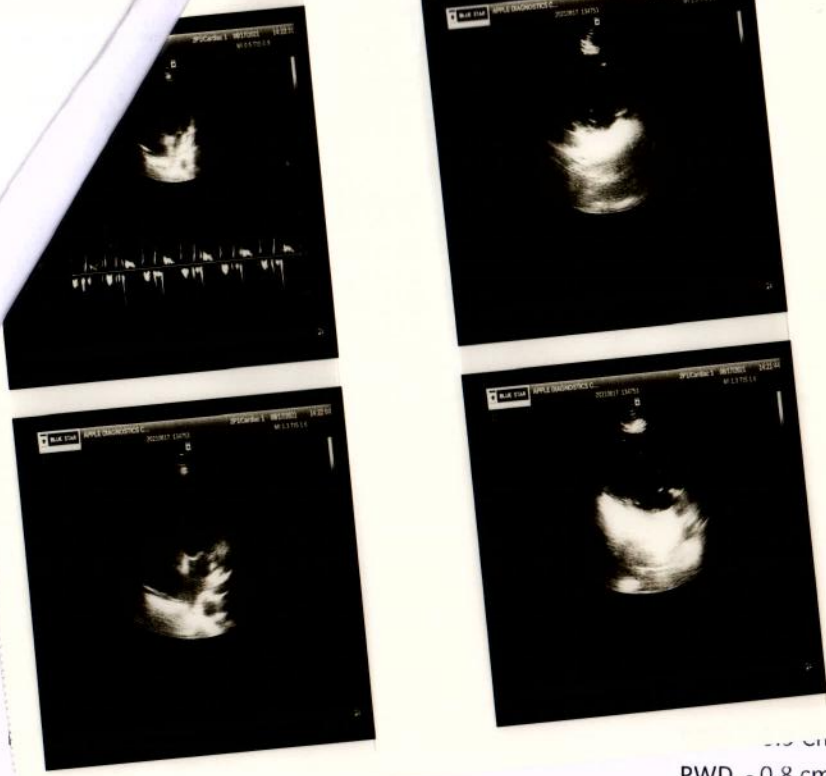2-48/98/a/nr, Telecom Nagar, Main Road, Opp to Cultfit, Beside Medplus, Gachibowli - 500032., M: +91 9515978234

#13-199/1, IDA Bollaram, Rangareddy-502325., P: +916309309111

DRT

ex30/MALE

7/08/2021



LVEDD — 4.4 cm, EF -68 %
LVEDS — 2.5 cm
PWD - 0.8 cm

- RV : NO RWMA OF LV
- IAS : Intact
- IVS : Intact
- AORTA : 2.7 cm
- PULMONARY ARTERY : Normal
- PERICARDIUM : Normal
- PULMONARY VEINS : Normal
- SVC / IVC / CORONARY SINUS : Normal
- INTRACARDIAC MASSES : Normal
- OTHERS :
- DOPPLER STUDY** :

MITRAL E/A : E > A
AORTIC JET VEL: 1.1 m/sec
PULM. JET VEL : 0.9 mt/sec
TRICUSPID VEL : mt/sec, RVSP - mmHg

CONCLUSION:

NO RWMA OF LV
NORMAL LV FUNCTION
NORMAL VALVES AND CHAMBERS
TRIVIAL TR, NO PAH
NO PERICARDIAL EFFUSION/CLOT

[Signature]
COSULTANT CARDIOLOGIST

Name : **YADAV BATHINI ANIL KUMAR**
Age/Gender : 30YEARS/MALE
Reff By : **MEDIWHEEL**

Patient Id : 5315
Sample Drawn Date : 17-Aug-2021
Reported Date : 18-Aug-2021

RADIOLOGY

DEPARTMENT OF RADIOLOGY
ULTRASOUND SCAN OF WHOLE ABDOMEN

LIVER : Normal in size 113 mm with normal echotexture. No focal lesions or dilated biliary radicles. No IHBD / CBD dilatation. Portal vein is normal.

GALL BLADDER : Partially distended.

SPLEEN : Normal in size 87 mm with normal echotexture. No focal lesions.

PANCREAS : Head, body, visualized parts of tail are normal. No focal lesions or peripancreatic collections are seen

RIGHT KIDNEY : Measuring 101 x 45 mm. Normal in size and echotexture. Pelvicalyceal system is normal. No calculi or hydronephrosis.

LEFT KIDNEY : Measuring 90 x 52 mm. Normal in size and echotexture. Pelvicalyceal system is normal. No calculi or hydronephrosis.

URINARY BLADDER : Well distended and normal. No calculi/wall thickening.


PROSTATE : Normal in size (Vol : 12 cc), contour and echotexture.

No ascites or lymphadenopathy is seen.

IMPRESSION :

*** NO SONOGRAPHIC ABNORMALITY.**

FOR CLINICAL CORRELATION AND FURTHER EVALUATION IF INDICATED.



Radiologist

A Unit of Avanthi Health Care PVT. LTD.

266, Main Road, Vivekananda Nagar, Kukatpally, Hyderabad-500 072., P: 040-23 16 11 20, M: +91 8008804014
S.R. Nagar Circle, Near Umesh Chandra Statue, Hyderabad-500 038., P: 040-29 56 56 56, M: +91 8008804014
2-48/98/a/nr, Telecom Nagar, Main Road, Opp to Cultfit, Beside Medplus, Gachibowli - 500032., M: +91 9515978234
#13-199/1, IDA Bollaram, Rangareddy-502325., P: +916309309111

Assay result should be correlated clinically with other laboratory finding and the total clinical status of the patient

Note : This Report is subject to the terms and conditions mentioned on the back of the report
e-mail : apple@medicover.com | apple@medicover.com | website : www.applediagnostic.com

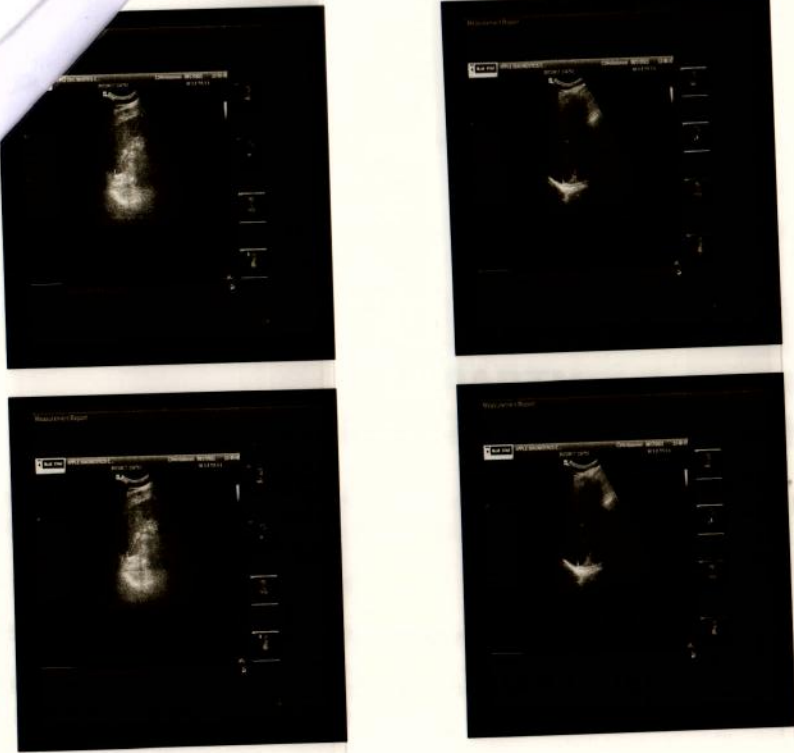
Note : PARTIAL REPRODUCTION OF THIS REPORT IS NOT PERMITTED

: 5315
 e : 17-Aug-2021
 : 18-Aug-2021

**LOGY
 ABDOMEN**

iliary radicles.

LIV
 No I
 GAL
 SPLI
 PAN
 or pe



RIGH
 Pelvic/urinary system is normal. No calculi or hydronephrosis.

LEFT KIDNEY : Measuring 90 x 52 mm. Normal in size and echotexture. Pelvic/urinary system is normal. No calculi or hydronephrosis.

URINARY BLADDER : Well distended and normal. No calculi/wall thickening.


PROSTATE : Normal in size (Vol : 12 cc), contour and echotexture.

No ascites or lymphadenopathy is seen.

IMPRESSION :

*** NO SONOGRAPHIC ABNORMALITY.**

FOR CLINICAL CORRELATION AND FURTHER EVALUATION IF INDICATED.



Radiologist

A Unit of Avanthi Health Care PVT. LTD.

266, Main Road, Vivekananda Nagar, Kukatpally, Hyderabad-500 072., P: 040-23 16 11 20, M: +91 8008804014

S.R. Nagar Circle, Near Umesh Chandra Statue, Hyderabad-500 038., P: 040-29 56 56 56, M: +91 8008804014

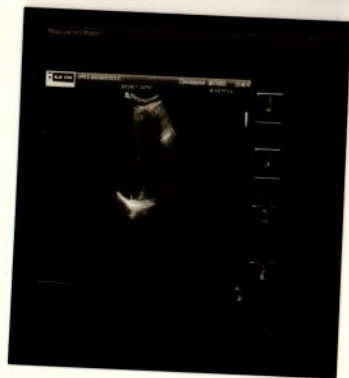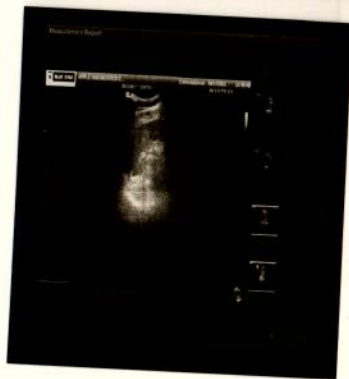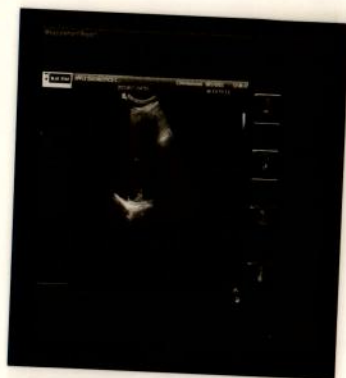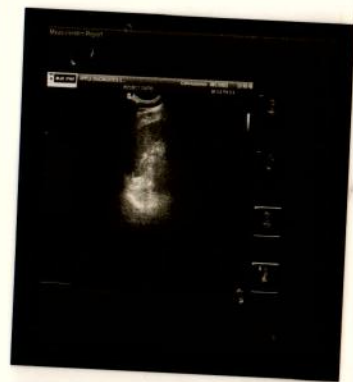2-48/98/a/nr, Telecom Nagar, Main Road, Opp to Cultfit, Beside Medplus, Gachibowli - 500032., M: +91 9515978234

#13-199/1, IDA Bollaram, Rangareddy-502325., P: +916309309111

Assay result should be correlated clinically with other laboratory findings and the total clinical status of the patient.

Note : This Report is subject to the terms and conditions mentioned on the report cover @gmail.com website : www.appliediagnostic.com

Note : PARTIAL REPRODUCTION OF THIS REPORT IS NOT PERMITTED








| | |
|---------------------------------------|--|
| Patient ID: 5315 | Patient Name: YADAV BATHINI ANIL KUMAR 3 2YM |
| Age: | Sex: |
| Accession Number: ACCNO002610 | Modality: CR |
| Referring Physician: MEDIWHEEL | Study: CHEST |
| Study Date: 17-Aug-2021 | |

X - RAY CHEST PA VIEW

Trachea is in midline.
Both hila normal in density.
Cardiac silhouette maintained.
Both CP angles are clear.
Both lung parenchyma are normal.
Bony cage and soft tissues are normal.



IMPRESSION: NORMAL STUDY.

For clinical correlation.

Dr. Sukumar., MDRD
Consultant Radiologist

Date: 17-Aug-2021 10:16:23

Healthy testing for Healthy living