

LETTER OF APPROVAL / RECOMMENDATION

To,

The Coordinator,
Mediwheel (Arcofemi Healthcare Limited)
Helpline number: 011- 41195959

Dear Sir / Madam,

Sub: Annual Health Checkup for the employees of Bank of Baroda

This is to inform you that the following employee wishes to avail the facility of Cashless Annual Health Checkup provided by you in terms of our agreement.

PARTICULARS	EMPLOYEE DETAILS
NAME	MR. MONIRULLAH MD
EC NO.	100410
DESIGNATION	CREDIT
PLACE OF WORK	KOLKATA, SALT LAKE SECTOR 3
BIRTHDATE	02-05-1983
PROPOSED DATE OF HEALTH CHECKUP	25-06-2021
BOOKING REFERENCE NO.	21J100410100000836E

This letter of approval / recommendation is valid if submitted along with copy of the Bank of Baroda employee id card. This approval is valid from **24-06-2021** till **31-03-2022** The list of medical tests to be conducted is provided in the annexure to this letter. Please note that the said health checkup is a **cashless facility** as per our tie up arrangement. We request you to attend to the health checkup requirement of our employee and accord your top priority and best resources in this regard. The EC Number and the booking reference number as given in the above table shall be mentioned in the invoice, invariably.

We solicit your co-operation in this regard.

Yours faithfully,

Sd/-

**Chief General Manager
HRM Department
Bank of Baroda**

(Note: This is a computer generated letter. No Signature required. For any clarification, please contact Mediwheel (Arcofemi Healthcare Limited))

Dr. N. H. Sankar Das
MBBS (Hons) - WBMC
DM (Geriatrics) - WBMC
Reg. No. 84909 (WBMC)



भारत सरकार
GOVERNMENT OF INDIA



Md Monirullah

DOB: 02/05/1983
MALE



~~2918 2419~~ 2095

MERA AADHAAR, MERI PEHCHAN

Pa. tho Treat Diagnostic Centre
& Poly Clinic
75 Dum Dum Road, Kol-700074
Phone No. - (033) 2580 3641

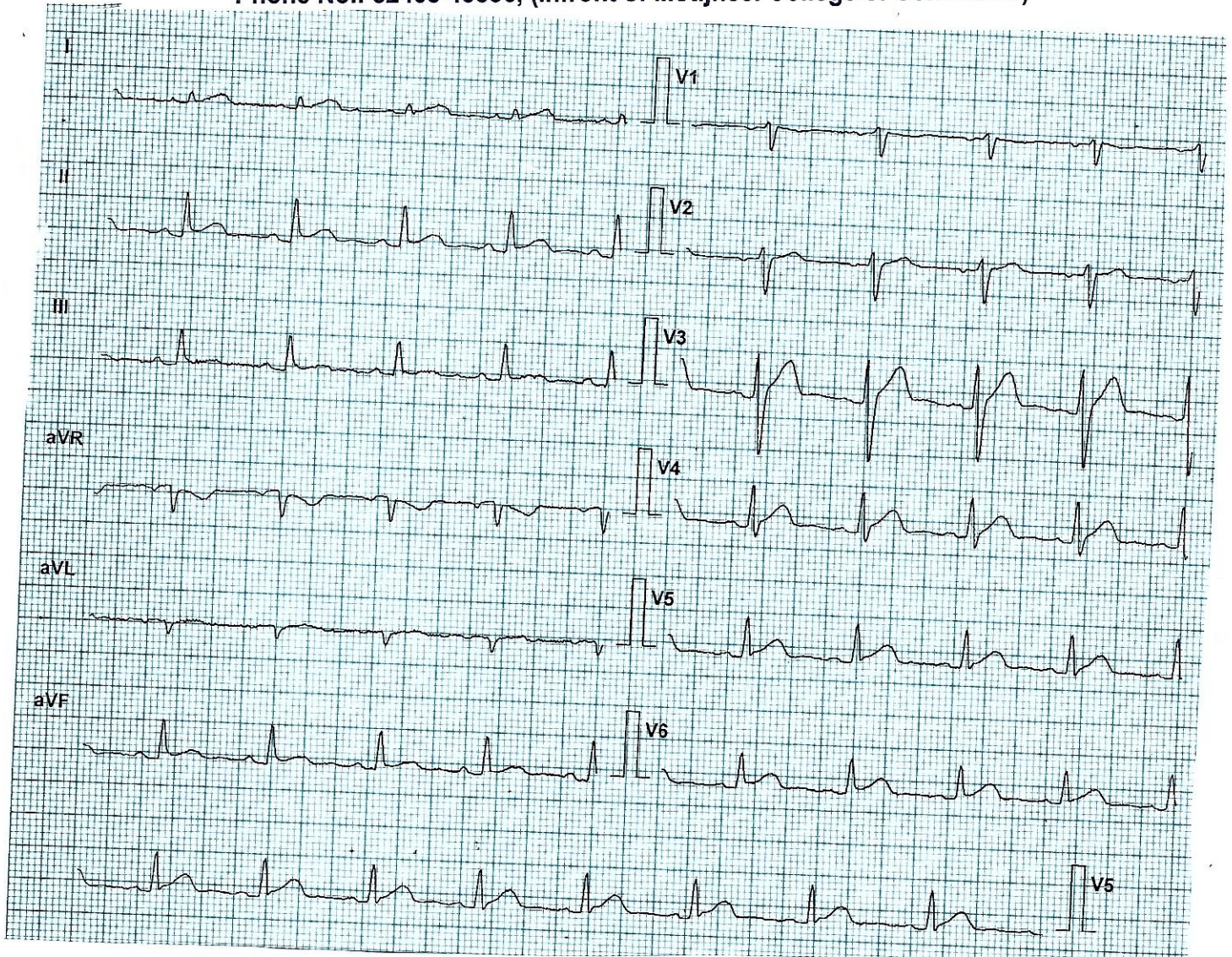


Patho Treat

DIAGNOSTIC CENTRE & POLYCLINIC

TEST REPORT

Regd. Off : 75, Dum Dum Road, Kolkata - 700 074
Phone No.: 82403 48836, (Infront of Motijheel College of Commerce)



Mr. Md. Monirullah.
37 yrs male.
ref by B.O.B
7/09/2021

H/R. 86 bpm.
Rhythm Sinus.
ST ———
normal ECG.

Dr. Uday Sankar Das
MBBS(Hon), MD(Med),
DM(Cardio), DNB(Cardio)
Reg. No. - 84909(WBMC)



Patho Treat

DIAGNOSTIC CENTRE & POLYCLINIC

TEST REPORT

Regd. Off : 75, Dum Dum Road, Kolkata - 700 074
Phone No.: 82403 48836, (Infront of Motijheel College of Commerce)

MD Monirullah (38 yrs/male)

He is Physically fit & fine.
all reports are normal. There
was no abnormalities found.

Dr. Debasis Banerjee
M.B.B.S., MD (Medicine)
Reg. No. - 42951



Patho Treat

DIAGNOSTIC CENTRE & POLYCLINIC

TEST REPORT

Regd. Off : 75, Dum Dum Road, Kolkata - 700 074
Phone No.: 82403 48836, (Infront of Motijheel College of Commerce)

ID NO: B/09/04
PT.NAME= MR MD MONIRULLAH
SEX: M AGE: 37 YRS


DATE OF RECEIPT: 07.09.2021


DATE OF REPORT: 07.09.2021

Reference By: BANK OF BARODA

HEMATOLOGY

<u>TEST</u>	<u>RESULT</u>
"ABO" GROUPING	" A"
Rh (D) FACTOR	POSITIVE


DR. SUMANA MAJUMDAR
M.B.B.S., MD
(PATHOLOGIST)



Patho Treat

DIAGNOSTIC CENTRE & POLYCLINIC

TEST REPORT

Regd. Off : 75, Dum Dum Road, Kolkata - 700 074
Phone No.: 82403 48836, (Infront of Motijheel College of Commerce)


ID NO: B/09/04
PT.NAME= MR MD MONIRULLAH
SEX: M AGE: 37 YRS


DATE OF RECEIPT: 07.09.2021

DATE OF REPORT: 07.09.2021

Reference By: BANK OF BARODA

<u>INVESTIGATION</u>	<u>RESULT / UNIT</u>	<u>REFERENCE VALUE</u>
TOTAL TRI-iodothyronin (T3)	98ng/dl	(60 – 181)
TOTAL THYROXINE (T4)	6.20ng/dl	(4.5 – 10.9)
THYROID STIMULATING HORMONE	3.10 nl/ml	(0.35 – 5.5)


DR.SUMANA MAJUMDAR
M.B.B.S.,MD
(PATHOLOGIST)



Patho Treat

DIAGNOSTIC CENTRE & POLYCLINIC

TEST REPORT

Regd. Off : 75, Dum Dum Road, Kolkata - 700 074
Phone No.: 82403 48836, (Infront of Motijheel College of Commerce)

ID NO: B/09/04
PT.NAME= MR MD MONIRULLAH
SEX: M AGE: 37 YRS

DATE OF RECEIPT: 07.09.2021

DATE OF REPORT: 07.09.2021

Reference By: BANK OF BARODA

REPORT ON EXAMINATION OF BLOOD

INVESTIGATION


RESULT & UNIT


GLYCOSYLATED HB%
(HBA1C)

4.60%

REFERENCE RANGE :-

Below 6.0 % ----- Normal Value
6.0 % - 7.0 % ----- Good Control
7.0 % - 8.0 % ----- Fair Control
8.0 % - 10.0 % ----- Unsatisfactory Control
Above 10.0 % ----- Poor Control


DR.SUMANA MAJUMDAR
M.B.B.S.,MD
(PATHOLOGIST)



Patho Treat

DIAGNOSTIC CENTRE & POLYCLINIC

TEST REPORT

Regd. Off : 75, Dum Dum Road, Kolkata - 700 074
Phone No.: 82403 48836, (Infront of Motijheel College of Commerce)

ID NO: B/09/04
PT.NAME= MR MD MONIRULLAH
SEX: M AGE: 37 YRS

DATE OF RECEIPT: 07.09.2021

DATE OF REPORT: 07.09.2021


Reference By: BANK OF BARODA

DIGITAL X-RAY CHEST PA VIEW

- No focal lesion seen bilateral lung fields.
- Domes of diaphragms are smooth and regular.
- Costophrenic angles are clear.
- Cardiac shadow is normal.
- Mediastinum is central.
- Both hila are normal in position and density.
- Bony thorax shows no abnormality.

IMPRESSION

Normal Study.


DR. VIMLESH JI VIMAL
M.B.B.S., MD,
DMRD (Radiologist)



Patho Treat

DIAGNOSTIC CENTRE & POLYCLINIC

TEST REPORT

Regd. Off : 75, Dum Dum Road, Kolkata - 700 074
Phone No.: 82403 48836, (Infront of Motijheel College of Commerce)

ID NO: B/09/04
PT.NAME= MR MD MONIRULLAH
SEX: M AGE: 37 YRS

DATE OF RECEIPT: 07.09.2021


DATE OF REPORT: 07.09.2021

Reference By: BANK OF BARODA

<u>TEST</u>	<u>RESULT</u>	<u>VALUE RANGE</u>
COTININE TEST	POSITIVE	(<200 ng / ml)

METHOD : - Qualitative Immunochromatographic Assay

SAMPLE : - URINE


DR.SUMANA MAJUMDAR
M.B.B.S.,MD
(PATHOLOGIST)



Patho Treat

DIAGNOSTIC CENTRE & POLYCLINIC

TEST REPORT

Regd. Off : 75, Dum Dum Road, Kolkata - 700 074
Phone No.: 82403 48836, (Infront of Motijheel College of Commerce)

ID NO: B/09/04
PT.NAME= MR MD MONIRULLAH
SEX: M AGE: 37 YRS

DATE OF RECEIPT: 07.09.2021

DATE OF REPORT: 07.09.2021

Reference By: BANK OF BARODA

REPORT ON THE EXAMINATION OF STOOL

Physical Examination

Colour : Brownish

Consistency : Semi Liquid

Blood : Not Found

Mucus : Present

Parasite : Not Found

Chemical Examination

Reaction : Acidic

Occult Blood : Acidic

PH : **

Reducing Substance : **

Microscopical Examination

Vegetable Cell : Present Few .

Starch : Not Found .

Epithelial Cell : Not Found .

Pus Cells : 1-2/ H.P.F .

R . B . C : Not Found .

Helminthic Ova : Not Found .

Protozoal Cysts : Not Found .

Trophozoite : Not Found .

Larva : Not Found .


Fat Droplets : Not Found .


Macrophage Cells : Not Found .

Crystal : Not Found .

Micro Organisms : (+) .

Others : Not Found .


DR.SUMANA MAJUMDAR
M.B.B.S.,MD(PATHOLOGIST)



Patho Treat

DIAGNOSTIC CENTRE & POLYCLINIC

TEST REPORT

Regd. Off : 75, Dum Dum Road, Kolkata - 700 074
Phone No.: 82403 48836, (Infront of Motijheel College of Commerce)

ID NO: B/09/04
PT.NAME= MR MD MONIRULLAH
SEX: M AGE: 37 YRS

DATE OF RECEIPT: 07.09.2021


DATE OF REPORT: 07.09.2021

Reference By: BANK OF BARODA

REPORT ON THE BIO - CHEMICAL EXAMINATION

<u>TEST</u>	<u>RESULT</u>	<u>UNIT</u>	<u>NORMAL VALUE</u>
TRIGLYCERIDES	164.00	mg / dL	(65.00 - 170.00)
HDL - CHOLESTEROL	57.00	mg / dL	(30 . 00 - 55 . 00)
LDL - CHOLESTEROL (By Enzyaatic Mathod at 370C)	115.00	mg / dL	(Upto 150.00)
VLDL	33.0	mg / dL	(16 . 00 - 40 . 00)
CHOLESTEROL - TOTAL	205.00	mg / dL	(150 . 00 - 250 . 00)
LDL/HDL	2.0:1		
CHOLESTEROL TOTAL/HDL	3.5:1		

DR. SUMANA MAJUMDAR
M.B.B.S., MD (PATHOLOGIST)



Patho Treat

DIAGNOSTIC CENTRE & POLYCLINIC

TEST REPORT

Regd. Off : 75, Dum Dum Road, Kolkata - 700 074
Phone No.: 82403 48836, (Infront of Motijheel College of Commerce)

ID NO: B/09/04
PT.NAME= MR MD MONIRULLAH
SEX: M AGE: 37 YRS

DATE OF RECEIPT: 07.09.2021


DATE OF REPORT: 07.09.2021

Reference By: BANK OF BARODA

REPORT ON THE BIO - CHEMICAL EXAMINATION

<u>TEST</u>	<u>RESULT</u>	<u>UNIT</u>	<u>NORMAL VALUE</u>
SUGAR (F)	78	mg / dl	(70 - 110)
SUGAR (PP)	82	mg / dl	(110 - 140)
CREATININE	1.0	mg /dL	(0.70 - 1.20)
URIC - ACID	5.1	mg/dL	(Male -3.4 - 7.0 Female - 2.4 - 5.7)
BUN	12.7	mg/dL	(5 - 23)
BUN/CREATININE	12.7/1		

DR. SUMANA MAJUMDAR
M.B.B.S., MD
(PATHOLOGIST)



Patho Treat

TEST REPORT

DIAGNOSTIC CENTRE & POLYCLINIC

Regd. Off : 75, Dum Dum Road, Kolkata - 700 074
Phone No.: 82403 48836, (Infront of Motijheel College of Commerce)

ID NO: B/09/04
PT.NAME= MR MD MONIRULLAH
SEX: M AGE: 37 YRS

DATE OF RECEIPT: 07.09.2021

DATE OF REPORT: 07.09.2021

Reference By: BANK OF BARODA

PHYSICAL EXAMINATION

Quantity 45 ml
Colour pale yellow
Appearance clear
Sediment Nil
Sp. Gravity 1.015


CHEMICAL EXAMINATION

Reaction Acidic
Albumin Nil
Proteins Nil
Sugar Nil
Acetone Negative
Bile Salt Negative
Bile Pigment Negative
Phosphates Nil
Chyle -----
Occult Blood Negative
Urobilinogen -----
Bence-Jones -----

MICROSCOPIC EXAMINATION

Unorganised Examination
Crystals Not Found
Organised Constituents Not Found
CASTS
Cellular(Pus Cell) Not Found
Hyaline Not Found
Granular Not Found
Fatty Not Found
Others Not Found
CELLS
Epithelial Cells (3 - 4 / HPF)
Pus Cells (0 - 1 /HPF)
R.B.C. Not Found
Others Nil
Bacteria Not Found

DR.SUMANA MAJUMDAR
M.B.B.S.,MD
(PATHOLOGIST)



Patho Treat

DIAGNOSTIC CENTRE & POLYCLINIC

TEST REPORT

Regd. Off : 75, Dum Dum Road, Kolkata - 700 074
Phone No.: 82403 48836, (Infront of Motijheel College of Commerce)

DATE OF RECEIPT: 07.09.2021

ID NO: B/09/04
PT.NAME= MR MD MONIRULLAH
SEX: M AGE: 37 YRS

DATE OF REPORT: 07.09.2021

Reference By: BANK OF BARODA

TEST	RESULT & UNIT	NORMAL RANGE
HAEMOGLOBIN (Cyanmethmaglobin Method)	12.80 gm %	Male :- (13 - 18) Female :- (11.5 - 16.5)
Total R.B.C	3.92 Million / cmm	3.5 - 6.5 Million / cmm
Total W.B.C	6200 / cmm	(4000 - 11000) / cmm
Platelets Count	1.80 lac / cmm	(1.5 - 4.0) lac / cmm

Differential Count W.B.C


TEST	RESULT & UNIT	NORMAL RANGE
Neutrophils	64%	(40 - 80) %
Lymphocytes	32%	(20 - 40) %
Eosinophils	03%	(2 - 10) %
Monocytes	01 %	(1 - 6) %
Basophils	00 %	(0 - 2) %


Haemogram

TEST	RESULT & UNIT	NORMAL RANGE
PCV	40.5%	(38 - 54) %
MCV	82.5Um ³	(77 - 93) Um ³
MCH	29.5 g %	(26 - 32) g %
MCHC	28.5 %	(27 - 35) %

Morphology of RBC : Normocytic, Normochromic.

ESR(Westergern Method): 1st Hour-17/mm (MALE : 0 -14 FEMALE : 0-20)


DR. SUMANA MAJUMDAR
M.B.B.S., MD
(PATHOLOGIST)



Patho Treat

DIAGNOSTIC CENTRE & POLYCLINIC

TEST REPORT

Regd. Off : 75, Dum Dum Road, Kolkata - 700 074
Phone No.: 82403 48836, (Infront of Motijheel College of Commerce)

ID NO: B/09/04
PT.NAME= MR MD MONIRULLAH
SEX: M AGE: 37 YRS


DATE OF RECEIPT: 07.09.2021


DATE OF REPORT: 07.09.2021

Reference By: BANK OF BARODA

REPORT ON THE BIO – CHEMICAL EXAMINATION

<u>TEST</u>	<u>RESULT</u>	<u>UNIT</u>	<u>NORMAL VALUE</u>
BILIRUBIN TOTAL	0.65	mg /dL	(Upto 1.00)
Bilirubin Conjugated	0.21	mg /dL	(Upto 0.25)
Bilirubin Unconjugated	0.44	mg /dL	(Upto 0.75)
SGOT/AST	24.00	U/L	(Male : 10 -35 Female : 10 – 31)
SGPT/ALT	30.00	U/L	(9.00 - 43.00)
TOTAL PROTEIN	7.40	g/dL	(6.00 - 8.50)
ALBUMIN	4.26	gm/dL	(3.5 – 5.2)
GLOBULIN :	3.14	gm/dL	(2.3 – 3.6)
A G Ratio :	1.3:1		
GAMA GT (G . G . T)	34.5	IU/L	(7.00 - 52.00)
ALKALINE PHOSPHATSE	90.5	IU/L	<i>Upto 5Yrs. F: 48-406, M: 75-389 5-10 Yrs.F: 96-332, M: 93-362 11- 15 Yrs. F: 52-162, M:74-390 16- 19 Yrs.F: 47-119, M:52-171 Adult – F: 35-141, M: 40-129</i>
AST/ALT RATIO	1.25:1		


DR.SUMANA MAJUMDAR
M.B.B.S.,MD(PATHOLOGIST)



Patho Treat

DIAGNOSTIC CENTRE & POLYCLINIC

TEST REPORT

Regd. Off : 75, Dum Dum Road, Kolkata - 700 074

Phone No.: (033) 2560 3641 / 3642, (033) 6526 0026, (Infront of Motijheel College of Commerce)

Associate Code : D1

Received On : 07/09/2021

Patient's Name : MD. MONIRULLAH

Reported On : 08/09/2021

ID Number : 10473/I-836

Age/Sex : 37Y/MALE

Referred By : SELF

Sample Source :

ClinicPro/debjan

Page 1 of 1

ULTRASONOGRAPHY OF WHOLE ABDOMEN

LIVER

It is normal (13.7 cm) in size. **Parenchymal echotexture is raised**. No focal parenchymal lesion is seen. Intrahepatic biliary radicles not dilated.

PORTA

PV : Normal in diameter with echofree lumen. PV measures 0.9 cm.

CD : Normal in caliber. No calculus is seen upto tracable part. CD measures 0.3 cm.

GALL BLADDER

Gall bladder is normally distended with normal wall thickness. No intraluminal calculus is noted.

PANCREAS

Normal in size & **echotexture is raised**. No focal S.O.L. or calcification noted. Main pancreatic duct – not dilated.

SPLEEN

Spleen is normal in size (8.9 cm). Parenchymal echotexture is normal. Splenic vein at its hilum is not dilated.

KIDNEY

Both kidneys are normal in size, shape and outline. Cortical echogenicity appears normal on both sides. Central echocomplexes are normal. Corticomedullary differentiation is maintained. No evidence of stone, hydronephrosis or any mass lesion seen on either side.

DR. S. PAL
M.B.B.S.(KOL),
APUSC-CBET(WBUHS)
CONSULTANT SONOLOGIST


DR. V. J. VIMAL
MD,DMRD
CONSULTANT RADIOLOGIST

Checked by.....

Regd. Off : 75, Dum Dum Road, Kolkata - 700 074

Phone No.: (033) 2560 3641 / 3642, (033) 6526 0026, (Infront of Motijheel College of Commerce)

URETERS

Not visualized hence not dilated.

URINARY BLADDER

Urinary bladder is well distended and normal in wall thickness. No intraluminal pathology or intramural mass lesion seen.

PROSTATE

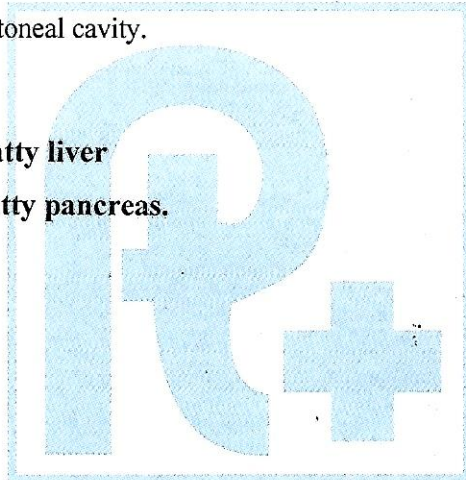
Prostate is normal in size, shape and echotexture. Capsule is intact. No sizeable mass lesion is seen. Both seminal vesicles appear normal.

No appreciable retroperitoneal lymphadenopathy noted at present.

No detectable ascites seen in peritoneal cavity.

IMPRESSION

1. Mild fatty liver
2. Mild fatty pancreas.



DR. S. PAL
M.B.B.S.(KOL),
APUSC-CBET(WBUHS)
CONSULTANT SONOLOGIST

DR. V. J. VIMAL
MD,DMRD
CONSULTANT RADIOLOGIST

Checked by.....