

REVIVAL DIAGNOSTICS



HEALTH CHECK-UP SUMMARY

Name: Snehal chamberi

Date: 2-10-2021

Email ID:

Sex: Female Age: 40 Years Contact No: 937656655 Remarks:

Under-weight	-
Normal	✓
Over-weight	-

i> BMI

Height (in Cm): <u>157</u>	Weight (in Kg): <u>49.</u>	BMI: <u>19.9</u>
Hip (in Cm): <u>91.</u>	Waist (in Cm): <u>80.</u>	Hip to Waist Ratio: <u>1.13</u>

ii> Blood Pressure & Pulse

120/80 mmHg
78/min regular

- Diabetes - 2013
- Tab (metformin, CO-01)

If high or low, whether the person is on medication: YES / NO

iii> Blood Tests & Lung Function Remarks

na

If abnormal, whether the person is on medication: YES / NO

iv> Eye Test Remarks

Eye Sight: normal
Color Vision: normal

v> Heart Disease

Whether any specific heart ailment detected (ECG findings):
na ECG - Normal

vi> Any other problems needing attention / Overall Assessment:

na

L.B.

Revival Diagnostic
401, Aqua Corridor,
B/s. Star Bazar, Surat-395009
Mo. 91062-28601

C. Chirag Patel
Signature of the Doctor
Dr. Chirag Patel
M.B.B.S. G-49432

Laboratory Test Result are Subject to technical limitation and should be clinically correlate for final diagnosis



NAME: Snehal Chaudhari SEX: Female
BIRTHDATE: 20-07-1981 AGE: 40.

DEPARTMENT OF OPHTHALMOLOGY

EYE TEST:

1. VISION:

RIGHT EYE - +1.
LEFT EYE - +0.25

2. COLOR VISION:

RIGHT EYE - 6/6
LEFT EYE - 6/6

3. FUNDUS:

RIGHT EYE - 6/6
LEFT EYE - 6/6

REMARKS:

[Handwritten signature]

Revival Diagnostics
401, Aqua Corridor
B/s. Star Bazar, Surat-395009
Mo. 91062-28601

Ophthalmologist/Optometrist

Laboratory Test Result are Subject to technical limitation and should be clinically correlate for final diagnosis



2D-ECHOCARDIOGRAPHY & COLOR DOPPLER REPORT

Name:	SNEHAL CHAUDHARI	Age/Gender	40Yrs /Female
Referred by.	MEDI WHEEL	Date	02/10/2021

VITALS: BP = 120/80mmHg, PULSE =90 bpm, SPO2 =98%

INDICATION: Preventive Health check up

- **CARDIAC CHAMBERS:** Left Ventricle: Normal size, Left Atrium: Normal size.
- No e/o thrombus in LA/LV.
- **Right Atrium:** Normal size. **Right Ventricle:** Normal size,
- **Normal Right Ventricular function.** (TAPSE=21mm)
- **Normal Left Ventricular systolic function.** LVEF = 65% ,
No regional wall abnormality. No thinning / scarring / dyskinesia of LV wall.
- **No Concentric Left Ventricular Hypertrophy.** (IVSd= 10 mm),
- **LV Compliance :**
No Left Ventricular Diastolic Dysfunction [LVDD]. No Doppler e/o raised LVEDP.
- **VALVES:**
- Structurally Normal Mitral valve/ Aortic valve/Tricuspid valve/ Pulmonary valve .
No significant Valvular Stenosis.
- **Doppler findings:** AV max = 1.23 m/s, PV max = 0.9 m/s.
Trivial Pulmonary Regurgitation, Trivial Tricuspid regurgitation.
- **No Pulmonary Arterial Hypertension.** PASP by TRjet vel.method = 23 mmHg.
- **SEPTAE:** IAS / IVS Appear Intact.
- **IVC :** Normal in dimension and shows good inspiratory collapse.
- **OTHERS:** No e/o Pericardial effusion / vegetation.

IMPRESSION:

NORMAL STUDY

**NORMAL LV SYSTOLIC FUNCTION, LVEF= 65%, NO RWMA,
NO LVH , NO LVDD ,TRIVIAL PR/TR, NO PAH.**

Revival Diagnostic

401, Aqua Corridor,
B/s. Star Bazar, Surat-395009
Mo. 91062-28601

DR SUSHIL YADAV
CONSULTING & CLINICAL
CARDIOLOGIST

Laboratory Test Result are Subject to technical limitation and should be clinically correlate for final diagnosis

📍 4th Floor, Aqua Corridor, Hazira Road, Adajan Paal, Surat-395009.

☎ 0261 2747788

✉ revivaldiagnostics.surat@gmail.com

🌐 www.revivaldiagnostics.com

This medical report is not intended for medico-legal purposes.



NAME	SNEHAL CHAUDHARI	DATE	2-Oct-21
REFERRED BY	MEDI WHEEL	AGE / SEX	40 YRS / F

Thanks for the reference

USG ABDOMEN AND PELVIS

LIVER: is normal in size and shows homogenous echotexture.
No evidence of intrahepatic biliary radicles dilatation / focal space occupying lesion.
The portal vein and common bile duct shows normal caliber.

GALL BLADDER: is distended and shows smooth walls. Wall thickness is normal.
No evidence of sludge / calculus. No evidence of pericholecystic collection.

SPLEEN: Is normal in size and shows normal echo pattern.

PANCREAS: shows normal echo anatomy and its relationship with splenic vein is normal.

KIDNEYS: Both the kidneys are normal in size, shape and location and show normal cortico-medullary differentiation.

Right kidney measures- cms.

Left kidney measures- cms.

No evidence of hydronephrosis or calculus.

URINARY BLADDER: is distended with smooth walls.

No evidence of diverticulum or calculus.

UTERUS: is anteverted and shows normal endometrial echo reflectivity.

OVARY: Both ovaries are normal in size and appear normal.

No evidence of ascites or pleural effusion.

Fluid and gas filled bowel loops with normal wall thickness and peristalsis noted.

IMPRESSION:

No significant abdominal pathology noted...

Dr. CHIRAG K. PATEL
MBBS-DMHD

Reg. No. G-23509

DR. CHIRAG K. PATEL
RADIUS DIAGNOSTICS

4th Floor, Aqua Corridor,

Nr. Star Bazar, Hazira Main Road,

Adajan, Surat-395009

Mo.No. 9726672668

Laboratory Test Result are Subject to technical limitation and should be clinically correlate for final diagnosis

📍 4th Floor, Aqua Corridor, Hazira Road, Adajan Paal, Surat-395009.

☎ 0261 2747788

✉ revivaldiagnostics.surat@gmail.com

🌐 www.revivaldiagnostics.com

This medical report is not intended for medico-legal purposes.



Name : SNEHAL A CHAUDHARI
Age/Sex : 40 Yrs. Female
UHID : 12107
Ref. By Dr. : MEDI WHEEL

Date : 02-Oct-2021 9:39 am
Receipt No : 5650

CBC HAEMOGRAM

PARAMETER	RESULT	UNITS	NORMAL RANGE
Hemoglobin	10.8	gm/dL	11.5-16.4
RBC Count	5.10	m/c.mm.	3.9-5.6
WBC Count	9700	c. mm.	4,000 - 10,000
Platelet Count	3.69	c. mm.	1.5 Lac - 4.5 Lac
Blood Indices			
Hematocrit (PCV)	35.5	%	36-47 %
MCV	69.6	fl	75-96
MCH	21.2	pg	27-32
MCHC	30.4	g/dL	30-36
RDW	17.9	%	11- 16
ESR (WINTORBE)	12	mm./hr.	0-30 below the age of 50 yrs.
DIFF WBC Count			
Neutrophils	50	%	40-75
Lymphocytes	45	%	20-50
Eosinophils	03	%	1-6
Monocytes	02	%	2-10
Basophils	00	%	0-5
Band Form	00	%	0-5
Smear Study			
Platelets in Smear	Adequate		
Malarial Parasites	Malarial Parasites Not Detected		
Blood Group	"O"		
RH Factor	Positive		

Revival Diagnostic

401, Aqua Corridor,
B/s. Star Bazar, Surat-395009
Mo. 91062-28601

Lab Technician/Technologist
Zarna K Gandhi (Msc. Biotech)

Pathologist
Dr. Mihir Icecreamwala

Operator Name: Zarna Gandhi Print Date & Time: 02-Oct-2021 02:06:00PM
Laboratory Test Results are subject to technical limitation and should be clinically correlate for final diagnosis

4th Floor, Aqua Corridor, Hazira Road, Adajan Paal, Surat-395009.

0261 2747788

revivaldiagnostics.surat@gmail.com

www.revivaldiagnostics.com

This medical report is not intended for medico-legal purposes.

REVIVAL DIAGNOSTICS



Name : SNEHAL A CHAUDHARI
Age/Sex : 40 Yrs./Female
UHID : 12107
Ref. By Dr. : MEDI WHEEL


Date : 2-Oct-2021 9:39 am
Rec. No : 5650

BIOCHEMISTRY

TEST	RESULTS	Unit	REFERENCE RANGE
GGT	: 22	U/L	5 - 50 U/L
SGOT	: 18	U/L	0 - 50 U/L
SGPT	: 15	U/L	0 - 50 U/L
Alkaline Phosphatase	: 68	IU/l	38 - 126 IU/l
Total Bilirubin	: 0.2	mg/dl	0.2 - 1.2 mg/dl
Direct Bilirubin	: 0.1	mg/dl	0.1 - 0.4 mg/dl
Indirect Bilirubin	: 0.1	mg/dl	0.1 - 0.8 mg/dl
Blood Urea Nitrogen (BUN)	: 12	mg/dl	9 - 20 mg/dl
Creatinine	: 0.5	mg/dl	0.5 - 1.5 mg/dl
Uric Acid	: 5.8	mg/dl	2.7 - 7.3 mg/dl
Blood Sugar, - F	: 94	mg/dL	70 - 110 mg/dL
Urine Sugar - F	: Absent		
Urine Ketone - F	: Absent		
Blood Sugar- PP	: 112	mg/dL	80 - 140 mg/dL
Urine Sugar - PP	: Absent		
Urine Ketone - PP	: Absent		
Total Protein	: 6.9	gm/dl	6.3 - 8.2 gm/dl
S.Albumin	: 4.0	gm/dl	3.7 - 5.3 gm/dl
Globulin	: 2.9	gm/dl	2.4 - 3.2 gm/dl

Lab Technician/Technologist
Zarna K Gandhi (Msc. Biotech)

Revival Diagnostic
401, Aqua Corridor,
B/s. Star Bazar. Surat-395009
Mo. 91062-28601


Pathologist
Dr. Mihir Icecreamwala

Operator Name : Zarna Gandhi

Print Date & Time : 02-Oct-2021

Laboratory Test Result are Subject to technical limitation and should be clinically correlate for final diagnosis

📍 4th Floor, Aqua Corridor, Hazira Road, Adajan Paal, Surat-395009.
☎ 0261 2747788 ✉ revivaldiagnostics.surat@gmail.com 🌐 www.revivaldiagnostics.com

This medical report is not intended for medico-legal purposes.

REVIVAL DIAGNOSTICS



A/G Ratio

: 1.38

gm/dl

1 - 2.3 gm/dl



REVIVAL
DIAGNOSTICS

Lab Technician/Technologist
Zarna K Gandhi (Msc. Biotech)

Revival Diagnostic
401, Aqua Corridor,
B/s. Star Bazar, Surat-395009
Mo. 91062-28601


Pathologist
Dr. Mihir Icecreamwala

Operator Name : Zarna Gandhi

Print Date & Time : 02-Oct-2021

Laboratory Test Result are Subject to technical limitation and should be clinically correlate for final diagnosis

📍 4th Floor, Aqua Corridor, Hazira Road, Adajan Paal, Surat-395009.

☎ 0261 2747788

✉ revivaldiagnostics.surat@gmail.com

🌐 www.revivaldiagnostics.com

This medical report is not intended for medico-legal purposes.



Name : SNEHAL A CHAUDHARI

Date : 02-Oct-2021

Age/Sex : 40 Yrs. Female

09:39:00AM

UHID : 12107

Receipt No : 5650

Ref. By Dr. : MEDI WHEEL

REPORT OF SERUM LIPID PROFILE

Test	Result	Reference Range
Serum Cholesterol	208	Normal : Less than 200 mg / dl Borderline : 200 to 239 mg / dl Undesirable : More than 240 mg / dl
Serum Triglyceride	249	Normal : Less than 150 mg / dl Borderline High : 150 to 199 mg / dl High : 200 - 499 mg / dl Very High : More than 500 mg / dl
Serum HDL - Cholesterol (Good Cholesterol)	52	Desirable : More than 65 mg / dl Borderline : 45 to 65 mg / dl Undesirable : Less than 45 mg / dl
Serum LDL - Cholesterol (Bad Cholesterol)	106.2	Optimal : Less than 100 mg / dl Above Optimal : 100 - 129 mg / dl Borderline High : 130 to 159 mg / dl High : 160 to 189 mg / dl Very High : More than 190 mg / dl
VLDL	49.8	Normal : 5 to 30 mg / dl
Chol. / HDL - Chol. Ratio	4	Low Risk : Less than 3.1 Vedium Risk : 3.1 to 5.9 High Risk : More than 6
LDL / HDL - Chol. Ratio	2.04	Low Risk : Less than 3.55 Medium Risk : 3.55 - 4 High Risk : More than 6

Revival Diagnostic

401, Aqua Corridor,
B/s. Star Bazar, Surat-395009
Mo. 91062-28601

Lab Technician/Technologist
Zarna K Gandhi (Msc. Biotech)


Pathologist
Dr. Mihir Icecreamwala

Operator Name: Zarna Gandhi

PrintDate & Time: 02-Oct-2021 02:08:00PM

Laboratory Test Result are Subject to technical limitation and should be clinically correlate for final diagnosis

4th Floor, Aqua Corridor, Hazira Road, Adajan Paal, Surat-395009.

☎ 0261 2747788

✉ revivaldiagnostics.surat@gmail.com

🌐 www.revivaldiagnostics.com

This medical report is not intended for medico-legal purposes.



Name : SNEHAL A CHAUDHARI
Age/Sex : 40 Yrs. / Female
UHID : 12107
Ref. By Dr. : MEDI WHEEL

Date : 02-Oct-2021 9:39 am
Receipt No : 5650

ROUTINE URINE EXAMINATION REPORT

PHYSICAL EXAMINATION :

Quantity : 25 ml
Colour : Pale Yellow
Appearance : Clear
Reaction : Acidic
Specific Gravity : 1.025

CHEMICAL EXAMINATION :


Proteins : Absent
Sugar : Absent
Acetone : Absent
Bile Salts : Absent
Bile Pigments : Absent
Urobilinogen : Normal
O.B.T. : Negative

MICROSCOPIC EXAMINATION :

Pus Cells : 2-3/hpf.
R. B. C. : Absent
Epithelial Cells : 1-2/hpf.
Bacteria : Absent
Casts : Absent
Crystals : Absent
Yeast cell : Absent
Mucus : Absent
Other Findings : NIL

Lab Technician/Technologist
Zarna K Gandhi (Msc. Biotech)

Revival Diagnostic
401, Aqua Corridor,
B/s. Star Bazar, Surat-395009
Mo. 91062-28601


Pathologist
Dr. Mihir Icecreamwala

Laboratory Test Result are Subject to technical limitation and should be clinically correlate for final diagnosis

Operator Name: Zarna Gandhi

PrintDate & Time: 02-Oct-2021 02:04:00PM

4th Floor, Aqua Corridor, Hazira Road, Adajan Paal, Surat-395009.

☎ 0261 2747788

✉ revivaldiagnostics.surat@gmail.com

🌐 www.revivaldiagnostics.com

This medical report is not intended for medico-legal purposes.



Name : SNEHAL A CHAUDHARI

Date : 02-Oct-2021

Age/Sex : 40 Yrs. Female

Receipt No : 5650

UHID : 12107

Ref. By Dr. : MEDI WHEEL

REPORT OF GLYCOSYLATED HEMOGLOBIN [HbA1C]

Parameter	Result	Unit	Biological Reference Interval
Hemoglobin A1C(HbA1C)	: 6.7	%	HbA1C Degree of Glucose Control

< 5.6 % Non Diabetics
5.7 - 6.4 % Prediabetics
> = 6.5 % Diabetics

(REF : Wallace, 11th Edition)

REMARKS:

6 - 7 % Excellent Control
7 - 8 % Good Control
8 -10 % Unsatisfactory Control
> 10 % Poor Control

Method : High performance liquid chromatography (HPLC)

MEAN BLOOD GLUCOSE OVER THE PAST 60 DAYS FROM THE HbA1C RESULT : 000 mg/dl

Remarks : GHb test is useful for the long term control and monitoring of diabetes mellitus since it reflects the integration of blood glucose levels during past 4-8 weeks.

Revival Diagnostic
401, Aqua Corridor,
B/s. Star Bazar, Surat-395009
Mo. 91062-28601

Lab Technician/Technologist
Zarna K Gandhi (Msc. Biotech)
Operator Name : Zarna Gandhi


Pathologist
Dr. Mihir Icecreamwala
Print Date & Time : 02-Oct-2021 03:59:00PM

Laboratory Test Result are Subject to technical limitation and should be clinically correlate for final diagnosis



Name : SNEHAL A CHAUDHARI
Age/Sex : 40 Yrs. Female
UHID : 12107
Ref. By Dr. : MEDI WHEEL

Date : 02-Oct-2021 9:39 am
Receipt No : 5650

THYROID TEST

TEST	RESULT	NORMAL RANGE
T3	1.556	0.87 - 1.78 ng/ml
T4	8.224	4.60 - 13.5 ug/dl
TSH	1.007	0.50 - 5.50 uIU/ml 5.5 to 15 uIU/ml - Suggested Clinical co-relation Or Repeat test with new sample as physiological factors can give falsely high TSH Above 15uIU/ml Hypothyroid

PREGNANT WOMEN normal ranges for TSH:
1st Trimester :0.0878 - 2.8293 uIU/ml
2nd Trimester :0.1998 - 2.7915 uIU/ml
3rd Trimester :0.307 - 2.9028 uIU/ml
Ref:Tietz Fundamentals of Clinical Chemistry.

Lab Technician/Technologist
Zarna K Gandhi (Msc. Biotech)

Revival Diagnostic
401, Aqua Corridor,
B/s. Star Bazar, Surat-395009
Mo. 91062-28601


Pathologist
Dr. Mihir Icecreamwala

Operator Name : Zarna Gandhi
Print Date & Time : 02-Oct-2021 02:05:00PM
Laboratory Test Result are Subject to technical limitation and should be clinically correlate for final diagnosis

REVIVAL DIAGNOSTICS



Name : SNEHAL A CHAUDHARI
Age/Sex : 40 Yrs. Female
UHID : 12107
Ref. By Dr : MEDI WHEEL

Date : 02-Oct-2021
Rec No : 5650

ECG

Test	Observed Value	Biological Reference Interval
------	----------------	-------------------------------

ECG

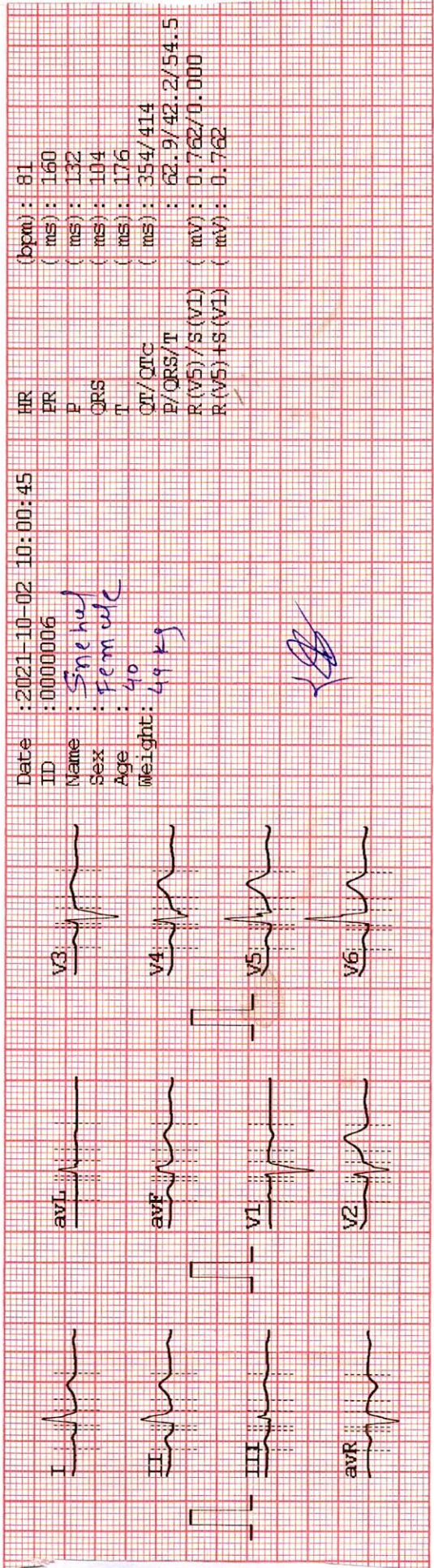
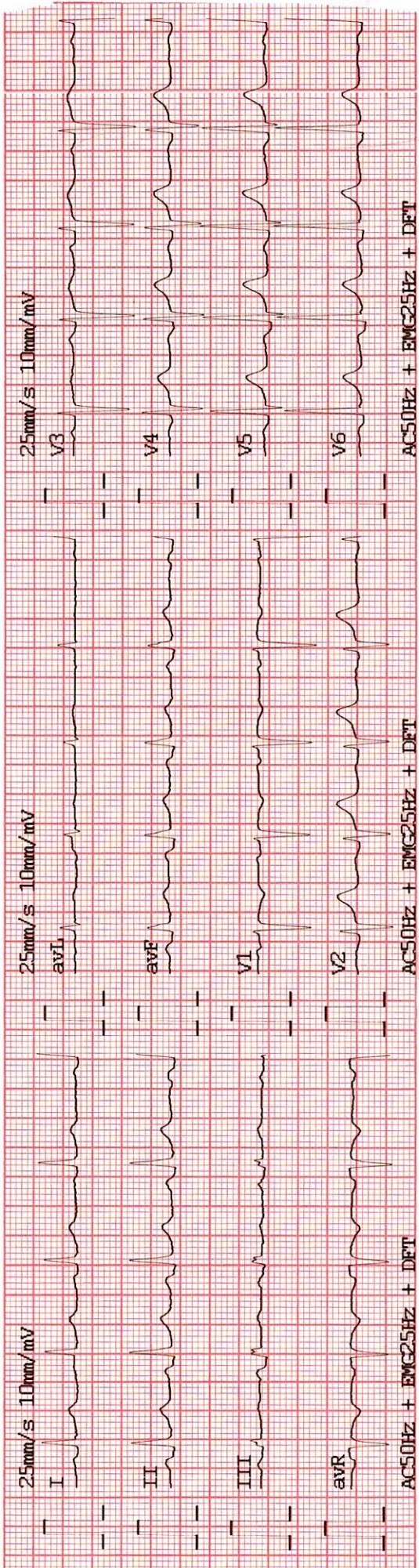
1. The rhythm is sinus.
2. Heart rate is **81** beats per minute.
3. Normal P,QRS,T wave axis.
4. Normal PR,QRS,Q.T. Duration.
5. No pathological q wave or ST-T changes seen.
6. No evidence of chamber hypertrophy or enlargement seen.

IMPRESSION : ECG WITHIN NORMAL LIMITS.

DR. ADITI PATEL
M.B.B.S., D. CARD (MUM)
CLINICAL CARDIOLOGIST
REG. NO. 8742901

Revival Diagnostic
401, Aqua Corridor,
P.O. Star Bazar, Surat-395009,
Mo. 91062-28601

Laboratory Test Result are Subject to technical limitation and should be clinically correlate for final diagnosis



Date : 2021-10-02 10:00:45
 ID : 0000006
 Name : *Snehaj*
 Sex : *Female*
 Age : *40*
 Weight : *49 kg*

HR : 81
 PR : 160 (ms)
 P : 132 (ms)
 QRS : 104 (ms)
 T : 176 (ms)
 QT/QTc : 354/414 (ms)
 P/QRS/T : 62.9/42.2/54.5 (mV)
 R (V5)/S (V1) : 0.762/0.000 (mV)
 R (V5)+S (V1) : 0.762 (mV)

YB

DR. ADITI PATEL
 M.B.B.S., D. CARD (MUM)
 CLINICAL CARDIOLOGIST
 REG. NO. G-42907

Revival Diagnostic
 401, Aqua Corridor,
 S/S. Star Bazar, Surat-395009,
 Mo. 91062-28601



NAME	SNEHAL A CHAUDHARI	REPORTING DATE	02/06/2021
REF BY	MEDI WHEEL	AGE / SEX	40YRS / F

CHEST RADIOGRAPH-PA VIEW

Hilar shadows are within normal limits.

Pulmonary vasculature appears normal.

Cardiac appears normal in size.

Both domesh of the diaphragm are smooth.

Both costophrenic recesses are clear.

Both lung fields appear normal.

Visualized bones and soft tissue shadows appear normal.

IMPRESSION:

NORMAL STUDY.

Dr. CHIRAG K. PATEL
MBBS-DMHD
Reg. No. 1428509
RADIUS RADIOLOGIST
4th Floor, Aqua Corridor,
Nr Star Bazar Hazira Main Road,
Adajan, Surat-395009
Mo.No 9726872668

Laboratory Test Result are Subject to technical limitation and should be clinically correlate for final diagnosis

R

NAME : SNEHAL A CHAUDHARI
AGE : 40 YRS / MALE
REF BY : MEDI WHEEL

