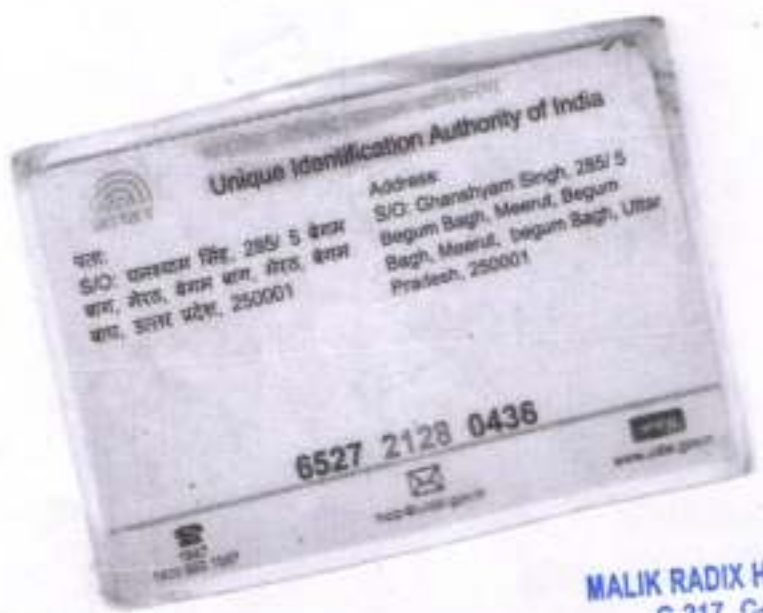

4



*Ankit Kumar*



**MALIK RADIX HEALTH CARE PVT. LTD.**  
C-217, C-218, Nirman Vihar,  
Delhi-110092  
Ph.: 011-49287456, 011-61381379  
Regd. No. 607

**MALIK RADIX HEALTHCARE PVT LTD**  
 UNI-EMC-217/218 NIRMAN VIHAR VIKAS MARG  
 DELHI 110092

*Abhishek Kumar*

ANKIT KUMAR  
 LD : 2851

AGE/SEX : 37 Yr / M  
 HT/WT : / /  
 DATE : 13-02-2024 10:23:25 AM  
 REF BY : Dr.

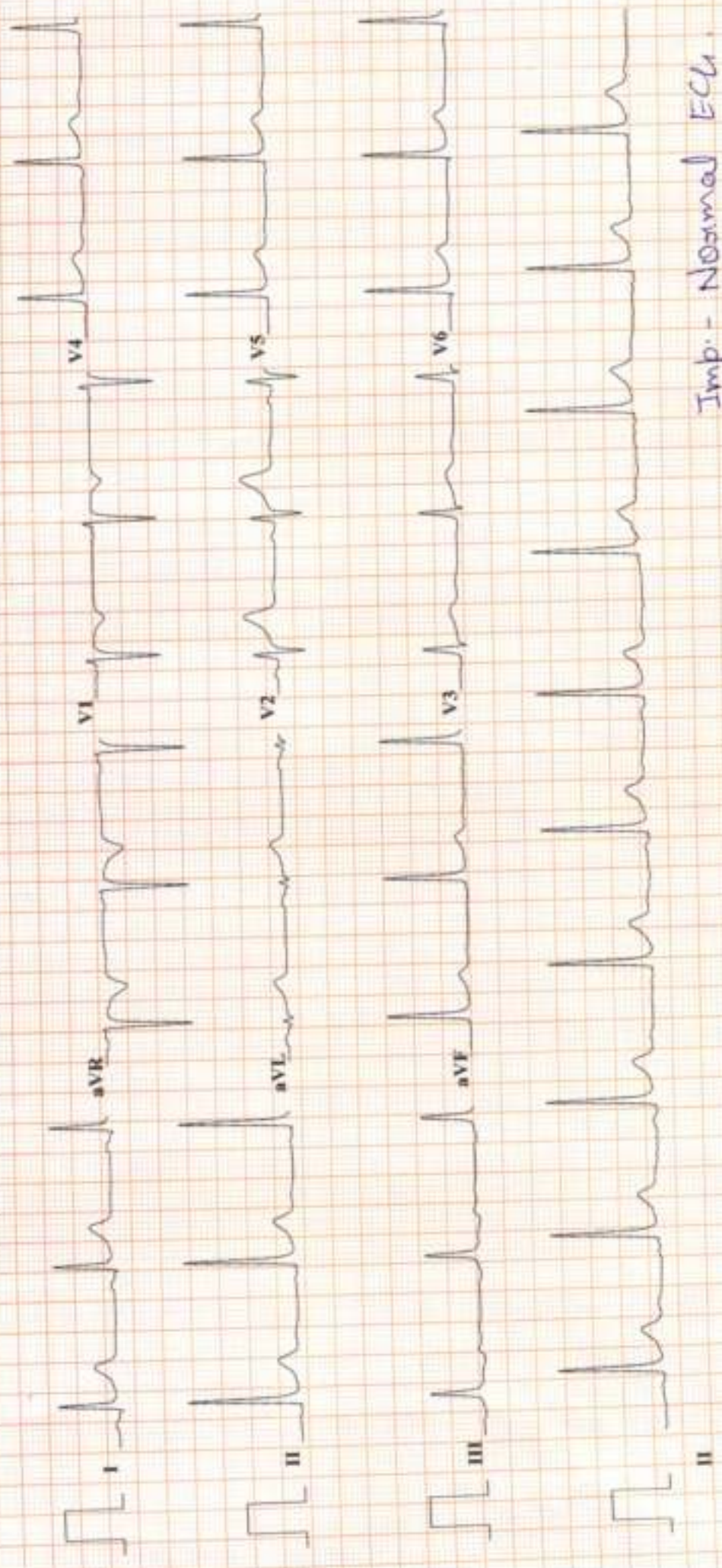
MACHINE INTERPRETATION : Normal ECG.

P Duration : 82 ms  
 PR Duration : 135 ms  
 QRS Duration : 89 ms  
 QT Interval : 350 ms  
 QTc Interval : 363 ms

RATE : 65 bpm  
 BP : N/A  
 P Axis : -14 deg.  
 QRS Axis : 59 deg.  
 T Axis : 26 deg.

Linked Median

Speed : 25 mm/s  
 Sensitivity : 10 mm/mV



Imp. - Normal ECG

*Dr. SHEKH NAZIR AHMED*  
 M.D. Physician  
 P.DCC  
 DMC-48499

Dr.



# RADIX MALIK HOSPITAL

RADIX MALIK HOSPITAL

NIRMAN VIHAR DELHI 110092

## TREADMILL TEST REPORT

ANKIT KUMAR

ID : F394  
 DATE : 13-02-2024  
 AGE/SEX : 37 / M  
 HT/WT : 0 / 0  
 REF. BY :

PROTOCOL : Bruce  
 HISTORY : HTN  
 INDICATION :  
 MEDICATION :

PHASE	TOTAL TIME	STAGE TIME	SPEED Km/Hr	GRADE %	H.R. bpm	B.P. mmHg	RPP x100	ST LEVEL (MG)		METS
								V1	V5	
SUPINE					64	130 / 80	83	0.5	-0.1	0.4
STANDING					63	130 / 80	81	0.7	-0.1	0.4
HYPERVENT					63	130 / 80	81	0.6	0	0.4
Stage 1	0:20		2.7	10	86	134 / 80	115	0.4	0.1	0.4
Stage 2	2:55		4	12	97	138 / 82	133	0.6	0.2	0.3
Stage 3	5:55		5.4	14	122	144 / 84	175	0.1	-0.1	0.6
Stage 4	8:55		6.7	16	160	150 / 86	240	1	0	0.8
PK-EXERCISE	11:55		8	18	157	160 / 90	251	1	-0.1	0.7
RECOVERY	12:7				96	200 / 80	192	0.6	0.2	0.3
RECOVERY	15:14				91	140 / 80	127	0.3	0.3	0.4
RECOVERY	18:14									
RECOVERY	5:55									

### RESULTS

EXERCISE DURATION : 12:7  
 MAX HEART RATE : 162 bpm 88 % of target heart rate 183 bpm  
 MAX BLOOD PRESSURE : 200 / 80 mm Hg  
 REASON OF TERMINATION : Achieved THR,  
 : Hypertensive Response, B.P was 200/80 mmHg at the recovery stage.  
 BP RESPONSE : None,  
 ARRHYTHMIA : None,  
 H.R. RESPONSE : None

### IMPRESSIONS

Negative for Provocable myocardial ischemia.

MAX WORK LOAD : 14.23 METS

Dr. SHEHNAZ NAZIR AHMED  
 MD - Physician  
 PGCC  
 DMC-4B-198

Technician :







# RADIX MALIK HOSPITAL

ANKIT KUMAR

I.D. 2394

Age 37/M

Date 13-02-2024

RATE 63bpm

B.P. 130/80

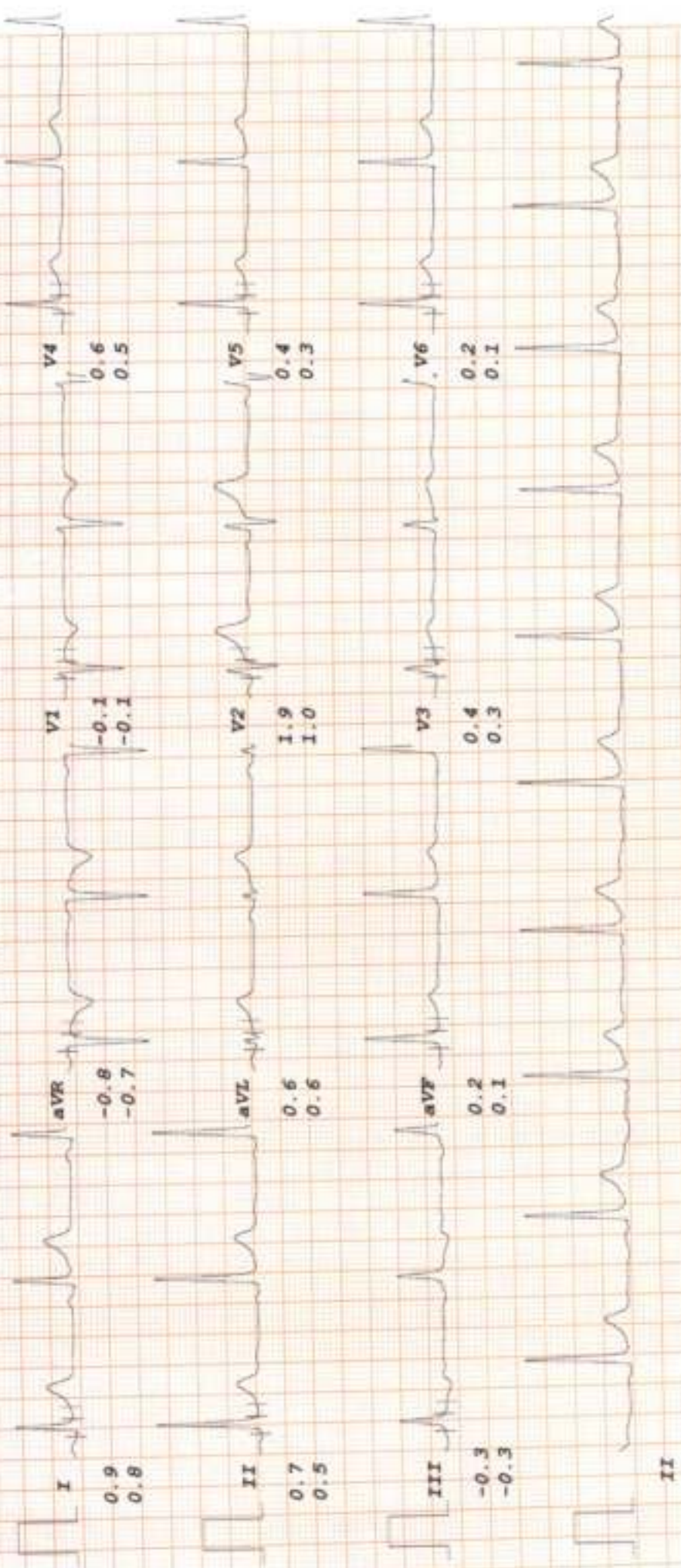
PRETEST

STANDING

ST  $\theta$  10mm/mV

80ms PostJ

LINKED MEDIAN





# RADIX MALIK HOSPITAL

ANKIT KUMAR

I.D. 2394

Age 37/M

Date 13-02-2024

RATE 63bpm

B.P. 130/80

ST @ 10mm/mV

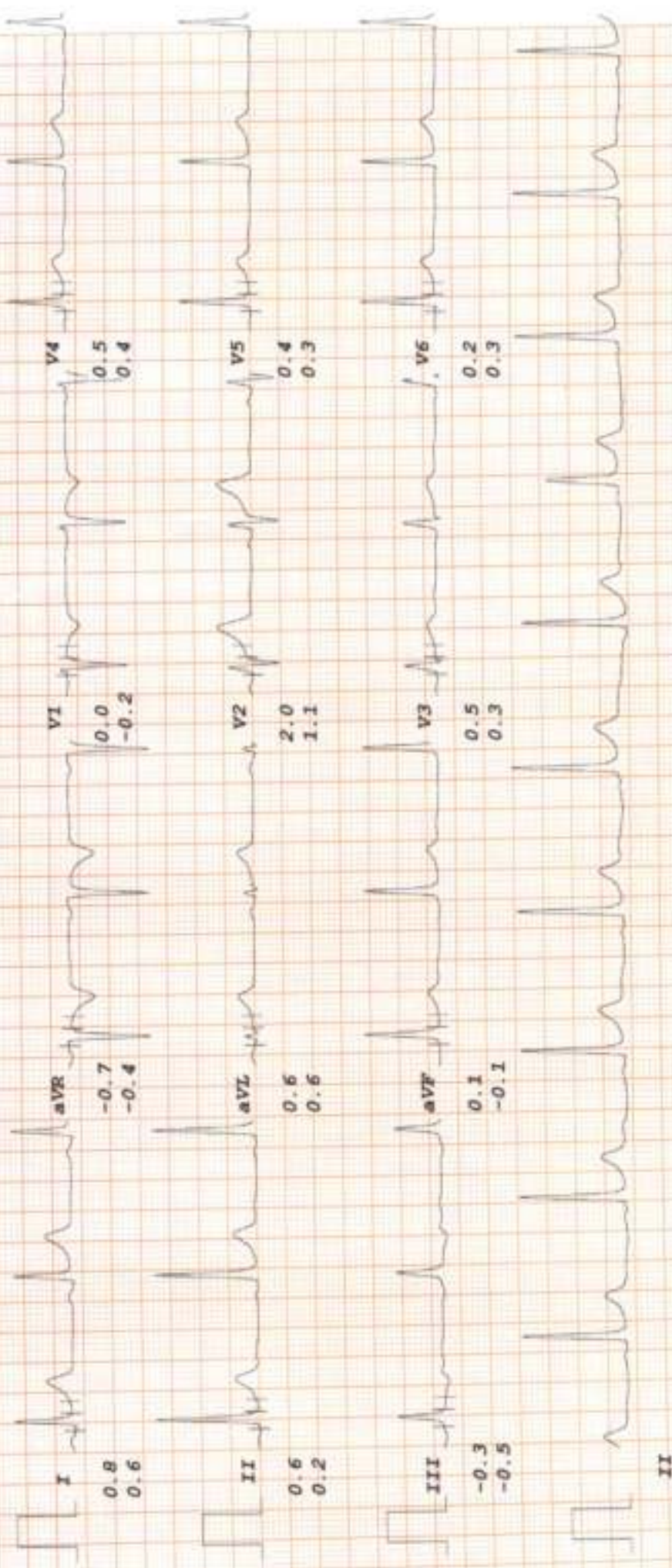
80ms PostJ

PRETEST

HYPERVENT

PHASE TIME 0:20

LINKED MEDIAN





# RADIX MALIK HOSPITAL

ST @ 10mm/mV  
80ms PostJ

LINKED MEDIAN

Bruce

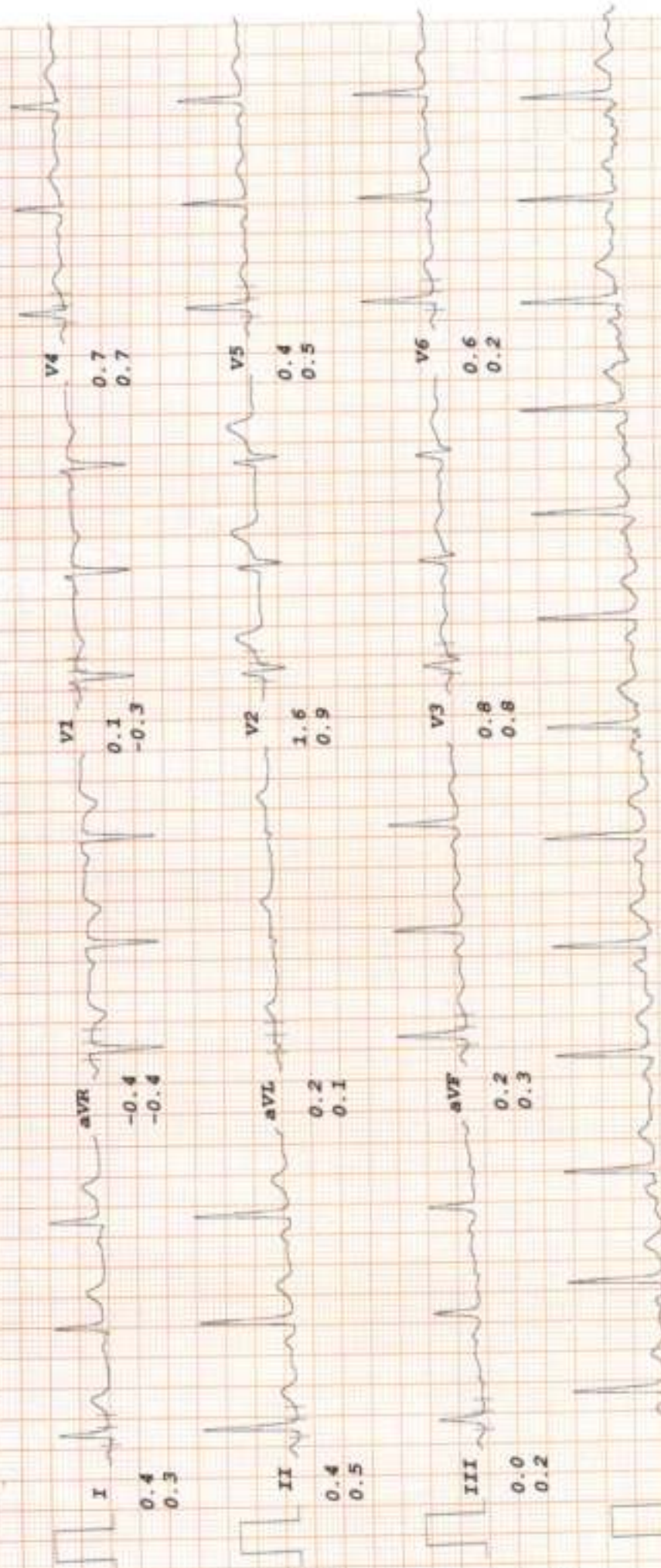
Stage I

TOTAL TIME 2:55

PHASE TIME 2:55

RATE 86bpm  
B.P. 134/80

ANKIT KUMAR  
I.D. 2394  
Age 37/M  
Date 13-02-2024









# RADIX MALIK HOSPITAL

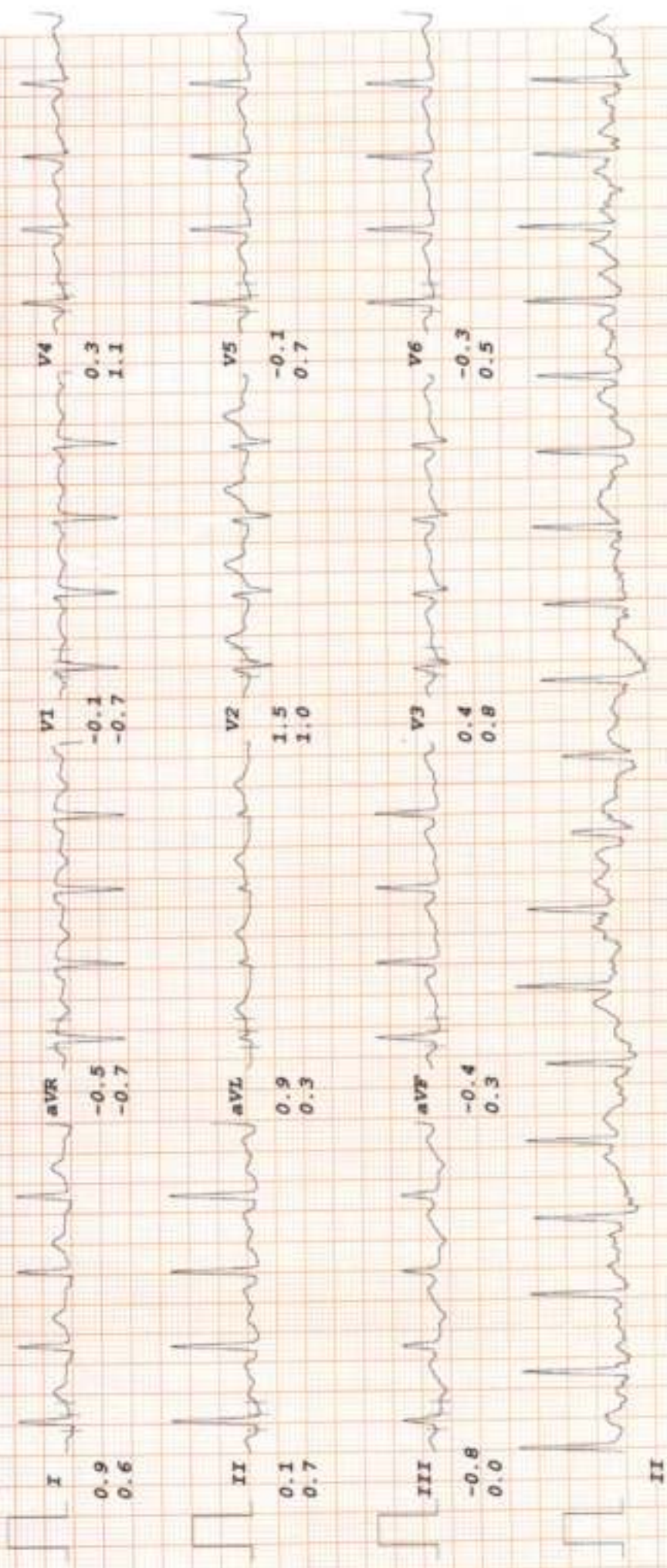
ANKIT KUMAR  
I.D. 2394  
Age 37/M  
Date 13-02-2024

RATE 122bpm  
B.P. 144/84

Bruce  
Stage 3  
TOTAL TIME 8:55  
PHASE TIME 2:55

ST @ 10mm/mV  
80ms Post J  
Speed 5.4 km/hr  
SLOPE 14.8

LINKED MEDIAN





# RADIX MALIK HOSPITAL

ANKIT KUMAR

I.D. 2394

Age 37/M

Date 13-02-2024

RATE 160bpm

B.P. 150/86

Bruce

Stage 4

TOTAL TIME 11:55

PHASE TIME 2:55

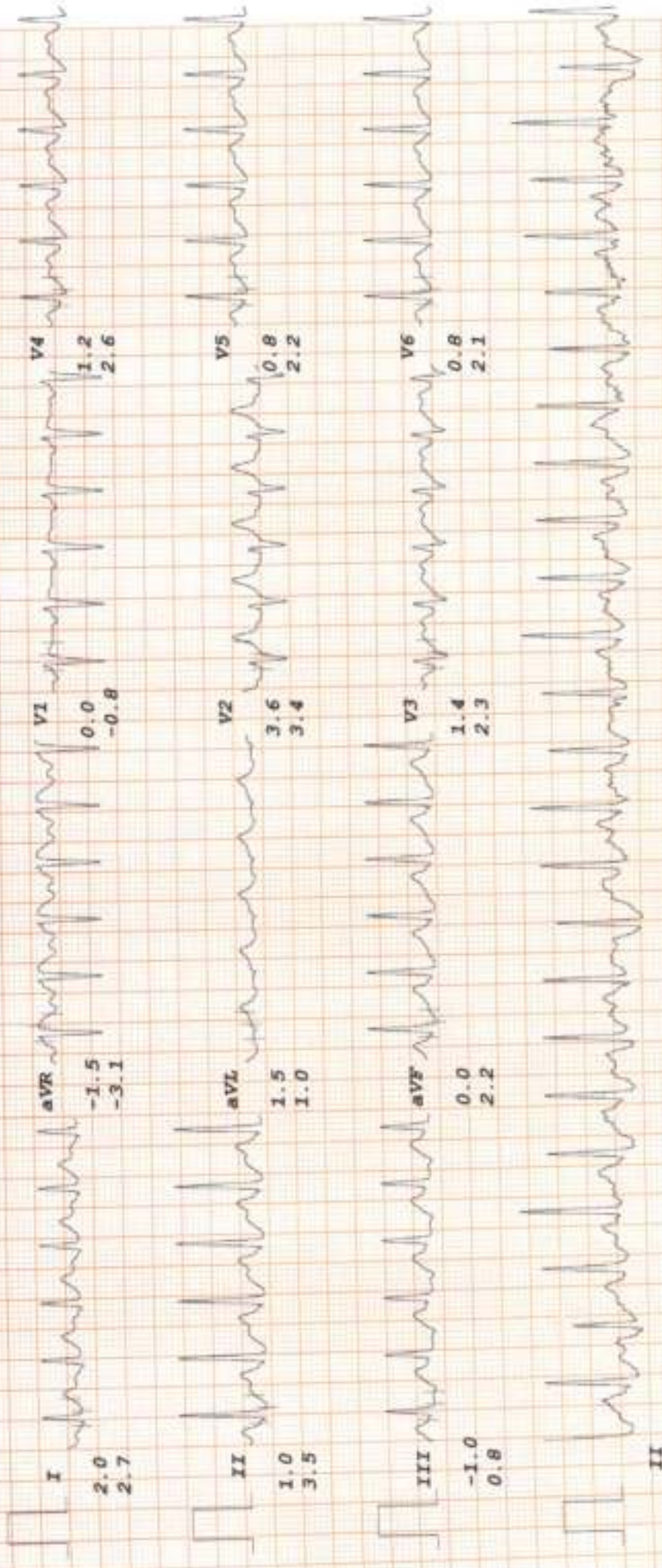
ST @ 10mm/mV

80ms PostJ

Speed 6.7 km/hr

SLOPE 16 %

LINKED MEDIAN





# RADIX MALIK HOSPITAL

ANKIT KUMAR  
I.D. 2394

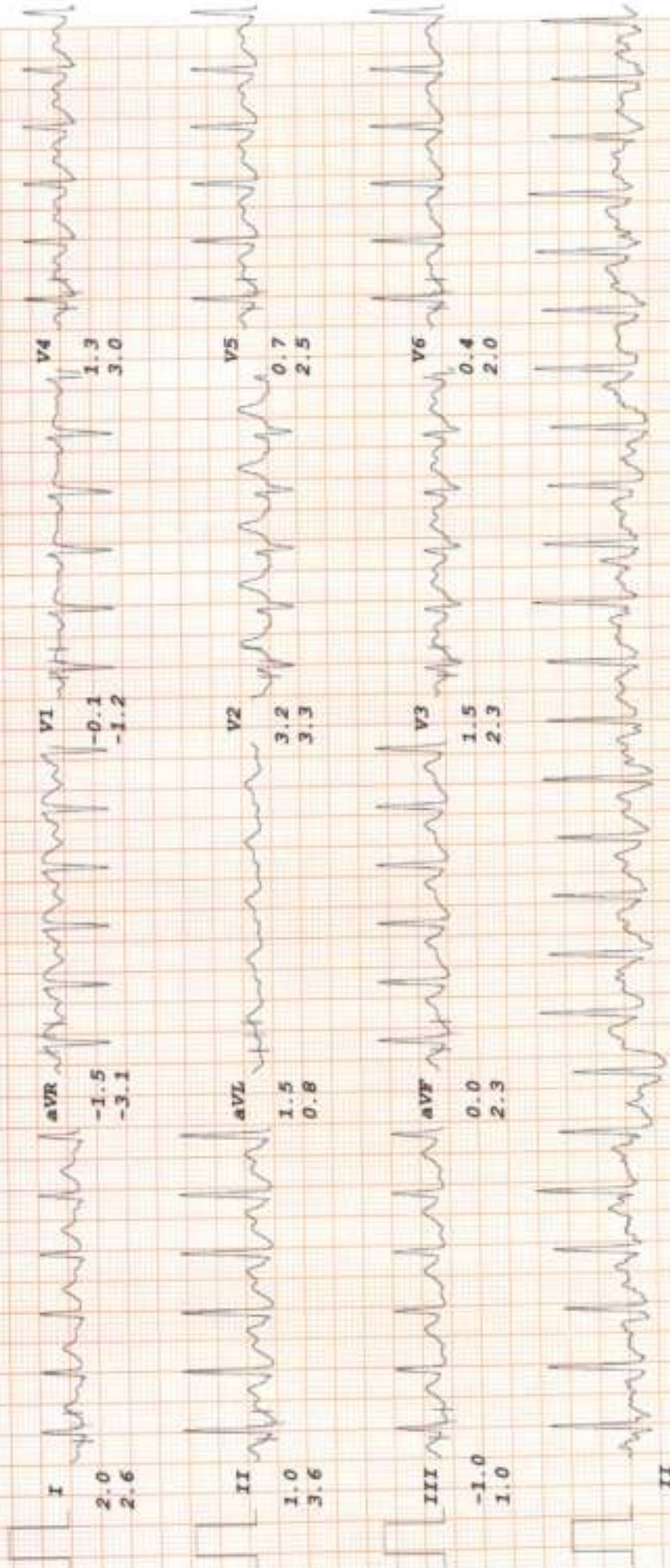
Age 37/M  
Date 13-02-2024

RATE 157bpm  
B.P. 160/90

Bruce  
PK-EXERCISE  
TOTAL TIME 12:07  
PHASE TIME 0:07

ST # 10mm/mV  
80ms PostJ  
Speed 8 km/hr  
SLOPE 18 %

LINKED MEDIAN









# RADIX MALIK HOSPITAL

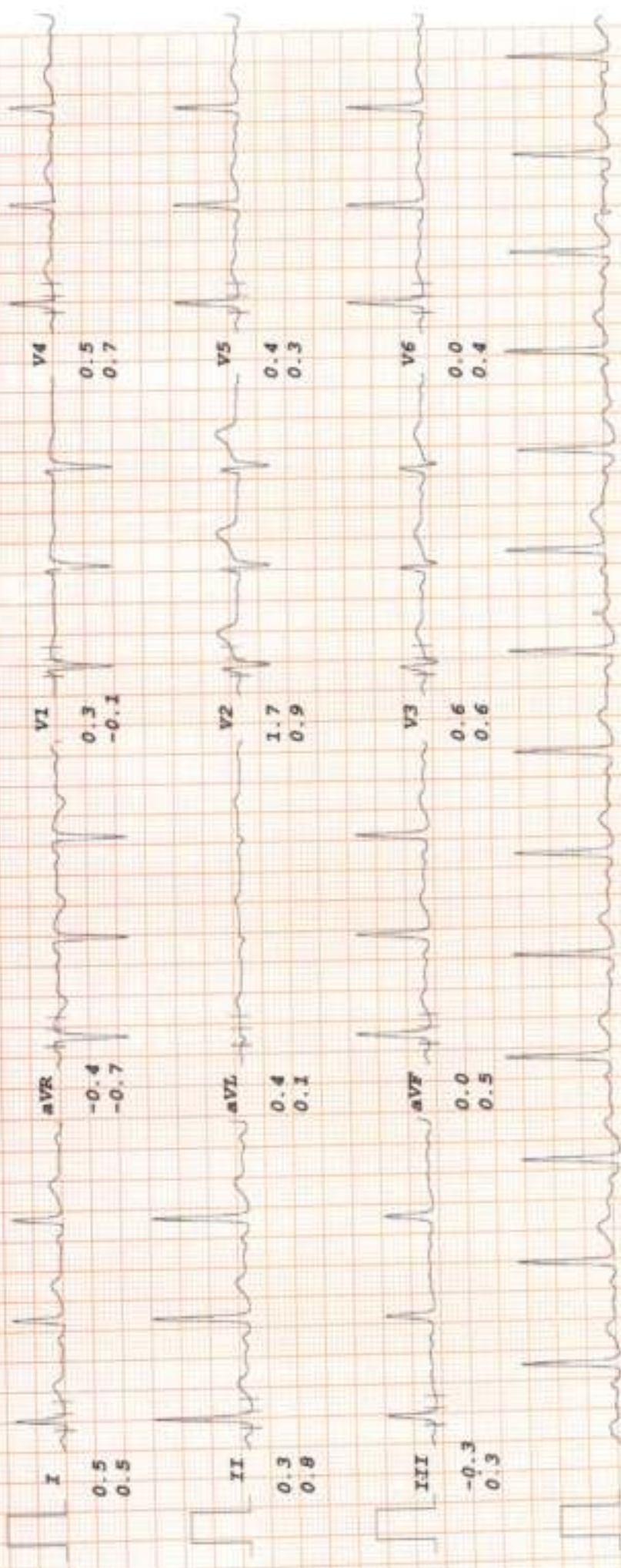
ANKIT KUMAR  
I.D. 2394  
Age 37/M  
Date 13-02-2024

Rate 91bpm  
B.P. 140/80

Bruce  
RECOVERY  
TOTAL TIME 18:14  
PHASE TIME 5:55

ST # 10mm/mV  
80ms PostJ

LINKED MEDIAN







**CONSULTANTS ON PANEL**

- PAEDIATRICS**  
Dr. Ravi Malik (MBBS, MD)  
Dr. Harit Prasad (MBBS, MD, FRI)  
Dr. Ritu Jain (MBBS, MD)
- GYNAECOLOGY**  
Dr. Renu Malik (MBBS, MD)  
Dr. Meenu Mathew (MBBS, MD)  
Dr. Ravi (MBBS, MD)  
Dr. Manu Gupta (MBBS, MD)  
Dr. Vanshika Saxi (MBBS, DGO)  
Dr. Pooja Arora (MBBS, MD)
- DENTAL**  
Dr. Shruti Malik (BDS, MEd)  
Dr. Anu Sam (BDS, MEd)  
Dr. Rashmi Thakur (BDS, MEd)  
Dr. Manvi Mangla (BDS, MEd)  
Dr. Tarun Mittal (BDS, MEd)  
Dr. Geetika Sharma (BDS)  
Dr. Shilpa Verma (BDS)
- CHILD GASTROENTEROLOGY**  
Dr. S. K. Mittal (MBBS, MD)
- MEDICINE**  
Dr. A. S. Talwar (MBBS, MD)  
Dr. Surana Gopal (MBBS, MD)  
Dr. Surekha Rajar (MBBS, MD)
- RESPIRATORY MEDICINE PULMONOLOGY**  
Dr. Apolona Shrivastava (MBBS, DNB)
- LAPAROSCOPIC SURGERY**  
Dr. Anu Jain (MBBS, MD)  
Dr. Deepak Datta (MBBS, MD)  
Dr. Pradeep Sam (MBBS, MD)  
Dr. S. S. Garg (MBBS, MD)
- ORTHOPAEDICS**  
Dr. Vikas Shrivastava (MBBS, MS, DOrtho, DNB)  
Dr. Pradeep Aggarwal (MBBS, MS, DOrtho)  
Dr. KB Tawar (MBBS, MS, DOrtho)  
Dr. Deepak Kumar Arora (MBBS, MS, DOrtho)
- EYE OPHTHALMOLOGY**  
Dr. Nishi Gupta (MBBS, MS, DNB, FICSM)  
Dr. Himanshu Singh Pandey (MBBS, MS)
- ENT**  
Dr. Shweta Kumar Singh (MBBS, MD)  
Dr. Pradeep Sharma (MBBS, MD)  
Dr. Anshu Singh (MBBS, MD)  
Dr. A. K. Lather (MBBS, MD)
- RADIOLOGY (ULTRASOUND)**  
Dr. K. K. Saha (MBBS, DNB)  
Dr. T. K. Verma (MBBS, MD)  
Dr. Neeraj Mathew (MBBS, MD)  
Dr. Anshu Kumar (MBBS, MD)
- PATHOLOGY**  
Dr. Renuka Datta (MBBS, MD, FRC)  
Dr. Meenu Aggarwal (MBBS, MD, FRC)
- ANAESTHESIA**  
Dr. Rashmi Dhill (MBBS, MD)  
Dr. Rakesh Arora (MBBS, MD)  
Dr. R. K. Arora (MBBS, MD)  
Dr. Seema Garg (MBBS, MD)
- DERMATOLOGY**  
Dr. Shikha Jha (MBBS, MD)
- PLASTIC & COSMETIC SURGERY**  
Dr. Anshu Jain (MBBS, MS, MCh)
- PEDIATRIC SURGERY**  
Dr. Dharmendra Singh (MBBS, MS, MCh)
- PEDIATRIC NEPHROLOGY**  
Dr. S. S. Vasudevan (MD, Dip. in Paed.)
- NEPHROLOGY**  
Dr. Jyoti (MBBS, MD, Nephro)
- CARDIOLOGY**  
Dr. Nishant Tyagi (MBBS, MD)
- NEUROLOGY**  
Dr. Anil Bhatia (MBBS, MD)
- GASTROENTEROLOGY**  
Dr. Deepak Lata (MBBS, MD)  
Dr. Suresh Aggarwal (MBBS, MD)  
Dr. Anshu Garg (MBBS, MD)  
Dr. Ankur Singhal (MBBS, MD)
- UROLOGY**  
Dr. Nand Sharma (MBBS, MCh)  
Dr. Ankur Singhal (MBBS, MD)
- PSYCHIATRY**  
Dr. Moha Sharma (MBBS, MD)
- PHYSIOTHERAPY**  
Dr. Rishi Dwarvedi  
Dr. Ravi Kumar
- NUTRITIONIST**  
Dr. Deepika Ashi  
Dr. Sakshi Rana
- CLINICAL PSYCHOLOGIST**  
Dr. Sanku Singh

## Dr. Shruti Malik

BDS, MDS (Endodontics)  
(+91-9899561092)

Name : Ankit Kumar  
Age/Sex : 37y / M  
Date : 13/2/24

Timings : 10:00 am. to 2:00 pm.  
6:00 pm. to 8:30 pm.

**For Appointment**  
011-45152510  
+91-9999254639

**CLINICAL EXAMINATION:-**

Routine Checkup

1. TMJ:-

2. DENTAL STATUS:

M.H.      h/o hypertension

- a. Caries Teeth :
- b. Fracture Teeth :
- c. Root Stumps :
- d. Gingivitis :
- e. Periodontitis :
- f. Impacted Teeth :
- g. Malaligned Teeth :

0/E

Calculus ++

Stains +

Cervical Abrasion  $\frac{5}{4} \mid \frac{4}{4}$

3. ORAL LESIONS:-

Rp  
- Peribond Mucositis - Bd

4. DIAGNOSIS:-

- Ultra soft TARTARUS -

5. TREATMENT PLANNING:

Adv. P-kit

1  
Geelbon

Referral To Other Consultant: Yes/ No

If Yes, please mention the Name: .....

Doctor's Signature .....

**Facilities Available :**

- \* MULTI-SPECIALITY HOSPITAL \* MODULAR FULLY EQUIPPED OT \* NURSERY \* LAPROSCOPIC SURGERY
- \* 24X7 EMERGENCY \* OPG \* DENTAL \* 24X7 DIAGNOSTICS \* LABOUR ROOM \* ECHO \* EEG \* DIGITAL X-RAY \* CT SCAN
- \* ECG \* ULTRASOUND \* RICU/ICU \* ALL SPECIALITY OPD \* PLASTIC & COSMETIC SURGERY \* DIALYSIS \* PHARMACY





Name - Mr. Ankit Kumari  
Age - 37 yrs / Male

13/02/2024

Heart Package

Vu  
E  
Glass  
4/6  
E  
2/1

Measure L No  
NB

Color the WNL

  
**Dr. Nidhi Gupta**  
MBBS, MS, DNB  
Casualty Ophthalmologist  
Malik Radix Healthcare Pvt. Ltd.  
DMC No. 121661

Facilities Available

- Multispecialty Hospital - 24 Hours Emergency - X-Ray/ECG/Ultrasound/CT Scan - Dental - Fully Equipped Operation Theatre
- Fully Functional Lab - 24/7 Casualty/ICU-Nursery - 24/7 Pharmacy - Labour Room - All Speciality OPD - Laproscopic Surgery -
- ECMO - Plastic Surgery





**LAB REPORT**

Reg. Date	13/02/2024	Patient Id	2402130003	DOB.	24/04/1986
Name	MR. ANKIT KUMAR	Gender	M	Perm. ID	
Age	37 Yrs. 9 Mn. 22 Day	Panel	MEDIWHEEL	Reported	16/02/2024 16:31:15
Ref. By	MEDIWHEEL				

Test Name	Result	Units	Ref. Range
-----------	--------	-------	------------

MEDIWHEEL ANNUAL PLUS

**HAEMATOLOGY**

**COMPLETE HAEMOGRAM**

HAEMOGLOBIN (HB%)	15.2	gm/dl	13 - 18
TOTAL LEUCOCYTE COUNT (TLC)	6,500	/cumm	4000 - 11000
<b>DIFFERENTIAL LEUCOCYTE COUNT (DLC)</b>			
NEUTROPHIL	52	%	40 - 80
LYMPHOCYTE	39	%	28 - 55
MONOCYTE	05	%	02 - 10
EOSINOPHIL	04	%	01 - 06
BASOPHIL	00	%	0 - 0
ESR (WESTEGREN'S METHOD)	10	mm/1st hr.	0 - 10
R B C COUNT	5.40	Millions/cmm	4.247 - 5.4
P.C.V / HAEMATOCRIT	48.4	%	40 - 54
M C V	89.6	fL	80 - 100
M C H	28.2	Picogram	27.0 - 31.0
M C H C	31.4	gm/dl	33 - 37
PLATELET COUNT	2.54	Lakh/cu mm	1.50 - 4.50
BLOOD GROUP ABO	" B "		
RH TYPING	Positive		
BLOOD SUGAR FASTING	91.3	mg/dl	70 - 100
BLOOD SUGAR PP	79.9	mg/dl	90 - 140
HB A1C	5.4	%	

**Interpretation**

Checked by : \_\_\_\_\_  
Page 1 Contd...2

If test results are alarming or unexpected, patient is advised to contact the laboratory immediately for possible remedial action.

**Facilities Available**

- Multispecialty Hospital - 24 Hours Emergency - X-Ray/ ECG/ Ultrasound/ CT Scan - Dental- Fully Equipped Operation Theatre  
- Fully Functional Lab - 24/7 Casualty/ ICU-Nursery 24/7 Pharmacy - Labour Room - All Speciality OPD - Laproscopic Surgery -  
ECHO - Plastic Surgery





## LAB REPORT

Reg. Date	13/02/2024	Patient Id	2402130003	DOB	24/04/1986
Name	MR. ANKIT KUMAR	Gender	M	Perm. ID	
Age	37 Yrs. 9 Mn. 22 Day	Panel	MEDIWHEEL	Reported	16/02/2024 16:31:15
Ref. By	MEDIWHEEL				

Test Name	Result	Units	Ref. Range
-----------	--------	-------	------------

Non Diabetic	: 4-6%		
--------------	--------	--	--

Good Diabetic Control	: 6-8%		
-----------------------	--------	--	--

Fair Control	: 8-10%		
--------------	---------	--	--

Poor Control	: >10%		
--------------	--------	--	--

The Glycosylated haemoglobin assay has been validated as a reliable indicator Of mean blood glucose levels for a period of 8-12 week period. ADA recommended the testing twice a year in patients with stable blood glucose and quarterly. If treatment change, or if blood glucose levels are unstable.

TO BE CORRELATED CLINICALLY.

**THYROID PROFILE**

Free T3 ELFA	2.91	ng/ml	02 - 04
Free T4 ELFA	0.97	ug/dl	0.8 - 2.7
TSH Serum/ELFA	1.410	uIU/ml	0.25 - 5.50 uIU/ml

**Interpretation****Clinical Use**

- Diagnose Hypothyroidism and Hyperthyroidism
- Monitor T4 replacement or T4 suppressive Therapy
- Quantify TSH levels in the subnormal range

Increased Levels : Primary Hypothyroidism Subclinical Hypothyroidism, TSH dependent, Thyroid Hormone Resistance.

Checked by : \_\_\_\_\_  
Page 2 Contd...3

If test results are alarming or unexpected, patient is advised to contact the laboratory immediately for possible remedial action.

**Facilities Available**

- Multispeciality Hospital - 24 Hours Emergency - X-Ray/ ECG/ Ultrasound/ CT Scan - Dental- Fully Equipped Operation Theatre  
- Fully Functional Lab - 24/7 Casualty/ ICU-Nursery 24/7 Pharmacy - Labour Room - All Speciality OPD - Laproscopic Surgery -  
ECHO - Plastic Surgery





**LAB REPORT**

Reg. Date	13/02/2024	Patient Id	2402130003	DOB	24/04/1986
Name	MR. ANKIT KUMAR	Gender	M	Perm. ID	
Age	37 Yrs, 9 Mn, 22 Day	Panel	MEDIWHEEL	Reported	16/02/2024 16:31:15
Ref. By	MEDIWHEEL				

Test Name	Result	Units	Ref. Range
Decreased Levels : Grave's Disease, Autonomous Thyroid Hormone Secretion, TSH Deficiency			

**LIPID PROFILE**

TOTAL CHOLESTEROL	217.20	mg/dL	130.0 - 200.0 (<200)
TRIGLYCERIDES	124.50	mg/dL	80.5 - 150.0 (<150)
H D L CHOLESTEROL DIRECT	46.0	mg/dL	35.0 - 60.0 (<40->59)
V L D L	24.9	mg/dL	4.0 - 30. (23-45)
L D L CHOLESTEROL	146.3	mg/dL	50.0 - 150.0 (50-150)
TOTAL CHOLESTEROL / HDL RATIO	4.7		3.3 - 5.1
LDL / HDL CHOLESTEROL RATIO	3.2		1.5 - 3.5

**LIVER FUNCTION TEST (LFT)**

BILIRUBIN TOTAL	0.30	mg/dl	0.2 - 1.2
CONJUGATED (D. BILIRUBIN)	0.20	mg/dl	0.00 - 0.3
UNCONJUGATED (I.D. BILIRUBIN)	0.10	mg/dl	0.2 - 0.9
SGOT / AST	30.00	IU/L	0 - 35
SGPT / ALT	37.2	IU/L	0 - 35
ALKALINE PHOSPHATASE	147.10	U/L	64 - 306
TOTAL PROTEIN	7.50	gm/dl	6.0 - 8.3
ALBUMIN	4.70	gm/dl	3.2 - 5.0
GLOBULIN	2.80	gm/dl	2.5 - 5.6
A/G RATIO	1.68		0.9 - 2.0
GAMMA GT	22.30	IU/L	0.0 - 45.0

Checked by : \_\_\_\_\_  
Page 3 Contd..4

If test results are alarming or unexpected, patient is advised to contact the laboratory immediately for possible remedial action.

**Facilities Available**

- Multispeciality Hospital - 24 Hours Emergency - X-Ray/ ECG/ Ultrasound/ CT Scan - Dental- Fully Equipped Operation Theatre  
- Fully Functional Lab - 24/7 Casualty/ ICU-Nursery 24/7 Pharmacy - Labour Room - All Speciality OPD - Laproscopic Surgery -  
ECHO - Plastic Surgery





## LAB REPORT

Reg. Date	13/02/2024	Patient Id	2402130003	DOB.	24/04/1986
Name	MR. ANKIT KUMAR	Gender	M	Perm. ID	
Age	37 Yrs. 9 Mn. 22 Day	Panel	MEDIWHEEL	Reported	16/02/2024 16:31:15
Ref. By	MEDIWHEEL				

Test Name	Result	Units	Ref. Range
SERUM CREATININE	0.92	mg/dl	0.7 - 1.4
SERUM URIC ACID	6.45	mg/dl	3.4 - 7.0
BLOOD UREA NITROGEN (BUN)	8.32	mg/dl	6.0 - 21.0
BUN/CREAT RATIO	9.04	mg/dl	10 - 20
Urine Routine Examination			
<b>PHYSICAL EXAMINATION</b>			
QUANTITY	20	ml.	
COLOUR	Pale Yellow		Pale Yellow
TRANSPARENCY	Clear		
SPECIFIC GRAVITY	1.025		
PH	6.5		
<b>CHEMICAL EXAMINATION</b>			
ALBUMIN	Nil		
SUGAR	Nil		
<b>MICROSCOPIC EXAMINATION</b>			
PUS CELLS	2-3	/HPF	
RBCS	Nil	/HPF	
CASTS	Nil		
CRYSTALS	NIL		
EPITHELIAL CELLS	0-1	/HPF	
BACTERIA	Nil		
OTHERS	Nil		

Dr. **REKHA CHAWLA**  
M.B.B.S, MD (Path.)  
Checked by:   
C-217, C-218, Nirman Vihar,

DR. MEENU AGGARWAL  
M.B.B.S, MD (Path.)

If test results are alarming or unexpected, patient is advised to contact the laboratory immediately for possible remedial action.

## Facilities Available

- Multispeciality Hospital - 24 Hours Emergency - X-Ray/ ECG/ Ultrasound/ CT Scan - Dental- Fully Equipped Operation Theatre  
- Fully Functional Lab - 24/7 Casualty/ ICU-Nursery 24/7 Pharmacy - Labour Room - All Speciality OPD - Laproscopic Surgery -  
ECHO - Plastic Surgery



R

THE UNIVERSITY OF CHICAGO PRESS





UHID	PT206534	LAB No.	XRY2309679
Name	Mr. ANKIT KUMAR	Regn. No.	GEN2338571
Age / Sex	37.Yrs / M	Receiving Dt/Time	13-Feb-2024 10:21
		Reporting Dt/Time	13-Feb-2024 10:18 AM



## XRAY

CHEST (PA)

Both lung fields are normal.

Cp angles are clear.

Hila are normal...

Heart size appears within normal limits.

Soft tissue shadows and bony thorax are normal.

Advised....please correlate clinically.

\*\*\*\*\* END OF REPORT \*\*\*\*\*

DR. K.K. SINHA  
M.B.B.S. D.M. (R)  
SENIOR CONSULTANT  
Reg. No. 26437 (DMC)

DR. RAJESH MALHOTRA  
MBBS, MD (RADIOLOGY)  
CONSULTANT RADIOLOGIST  
Reg.No DMC3298

DR. T. K. YADAVA  
MD (RADIODIAGNOSIS)  
SENIOR CONSULTANT  
Reg. No. 3272 (DMC)

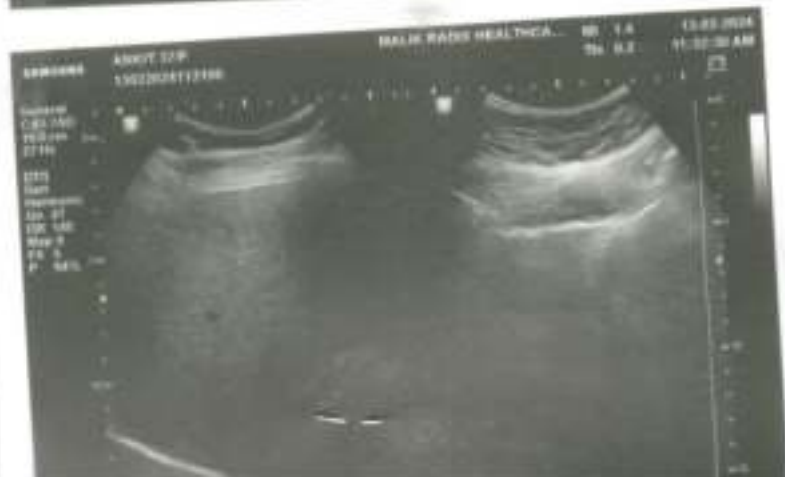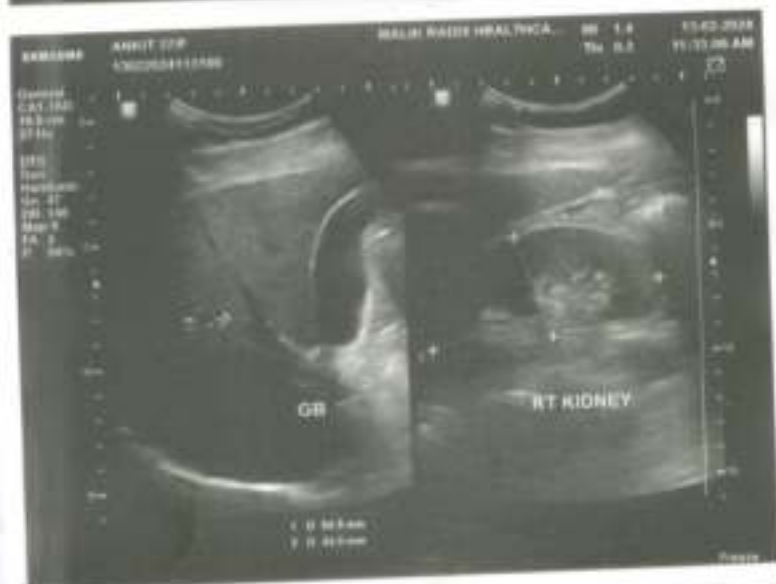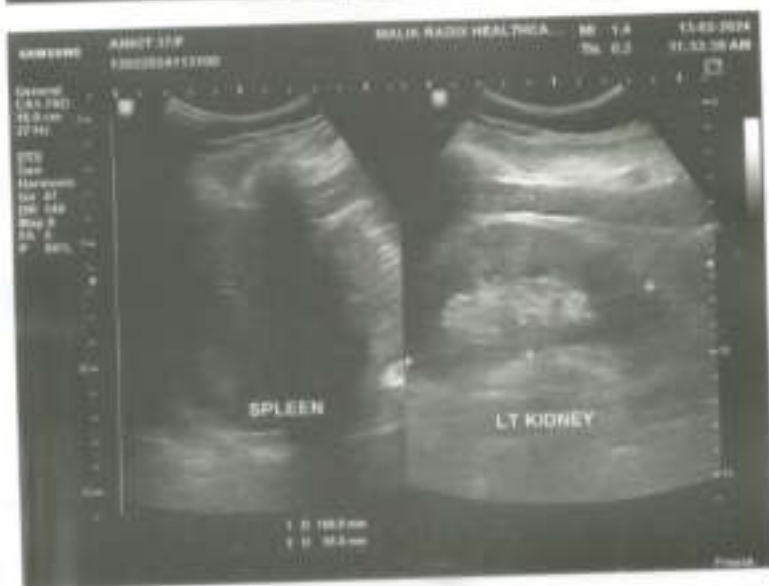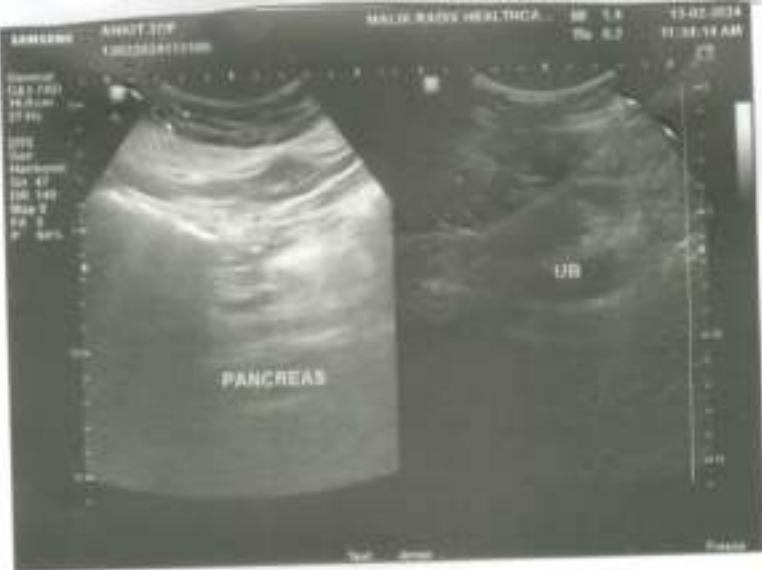DR. MUKESH KOSHAL  
MBBS, MD (RADIOLOGY)  
CONSULTANT RADIOLOGY  
Reg.No.DMC13407

DR. SHREYASH TIWARY  
MBBS, MD (RADIOLOGY)  
CONSULTANT RADIOLOGY  
Reg.No.DMC35802

## Facilities Available

- Multispecialty Hospital - 24 Hours Emergency - X-Ray/ ECG/ Ultrasound/ CT Scan - Dental - Fully Equipped Operation Theatre
- Fully Functional Lab - 24/7 Casualty/ ICU-Nursery 24/7 Pharmacy - Labour Room - All Speciality OPD - Laproscopic Surgery - ECHO - Plastic Surgery









NAME	MR ANKIT KUMAR	AGE	37 YRS/M
REFD. BY.	HELATH CHEK UP	DATE	13.02.24

### Ultrasound Examination of Whole Abdomen & Pelvis :

**Liver:** Liver shows grade 1 fatty changes . No focal SOL is seen in liver. IHBR & portal radicles are normal.

**Gallbladder:** Gallbladder shows normal anechoic pattern. No evidence of cholecystitis or cholelithiasis seen. Common bile duct is normal in course & caliber.

**Pancreas:** Pancreas shows normal size & echotexture.

**Spleen:** Spleen shows normal size, outline & echotexture.

**Kidneys:** Kidneys show normal size, shape, position & echotexture. No calculus, hydronephrosis or SOL is seen in kidneys. Cortico- medullary differentiation and cortical thickness is normal on both sides.

No supra- renal mass seen.

Great abdominal vessels are normal.

Domes of diaphragm are seen to move normally & synchronously in respiration. No infra- or supradiaphragmatic collection seen.

No ascites or pericardial effusion seen.

No para aortic lymph nodes seen.

**Urinary bladder:** Urinary bladder shows normal anechoic pattern. No calculus, SOL or diverticulum seen.

**Prostate:** Prostate is normal in size & echotexture. Seminal vesicles are sonographically normal.

**IMP- GRADE 1 FATTY LIVER**

Regards,

Dr Mukesh Koshal MD ( Rad- diag)

Regn. No. DMC 10407

RADIOLOGIST :

Facilities Available