

Dr. Girish B Navasundi
 MBBS, DNB (Cardiology)
 Senior Consultant &
 Interventional Cardiologist
 Director Cathlab
 M: +91-96110 99226
 Email : navasundi@rediffmail.com

Place Label Here
Mrs. Ashwini Bhat
 If label not available, write Pt. Name, UHID No.,
 Age, Sex, Date, Name of Treating Physician



HEART INSTITUTE

16/1/22

Dr. (Prof) Venkatesh T K
 MD, DNB (Cardiology)
 FACC (USA), FSCAI (USA)
 FCC FESC
 Senior Consultant &
 Interventional Cardiologist
 M: +91-98440 75579
 venkateshtekur@yahoo.com

Allergies : -	Fall Risk Assessment				Wt: _____	Ht: _____	T: _____	P: <i>93/60</i>	BP: <i>100/60</i>
	H/o fall (within 1 year)	Yes	No	Mobility Aid	Yes	No	Gait Dep. Indep. Pain ____/10 <input type="checkbox"/> Psychological & Social Assessment done		

Dr. Praneeth .S
 MD, DM, (Cardiology)
 Associate Consultant &
 Interventional Cardiologist
 M: +91-99869 74438
 praneethsuryadevara@gmail.com

*JMO
 HTNO
 Family % -*

(for healthy heart checkup)

Dr. Maria Jyothi F. B.
 MBBS, MD (Gen Med)
 DNB (Cardiology)
 Associate Consultant &
 Interventional Cardiologist
 M: +91-87224 20773
 mariajyothi57@gmail.com

*→ No cardiac % -
 → Gastritis*

Dr. Vijeth H.
 MBBS, MD (Gen. Med),
 DNB (Cardiology)
 Associate Consultant &
 Interventional Cardiologist
 M : +91-9481714844
 drvijeth23@gmail.com

Medicine Reconciliation Dose & Frequency
 Advice & Plan

ECG → (N) Sinus rhythm

Ech → (N) LVP, NO RWMA

*TMT → Neg for myocardial ischemia -
 Mex test 1.1.*

For Appointment :
 +91-80-2630 4105
 +91-70222 36051
 +91-96636 78737

Previous Investigations

ECG

TMT

ECHO

**Past Cath Findings
 Planed Investigation
 Advice**

ECG

TMT

ECHO

CAG / PTCA

Gastro open - Do (pran amna)

*MED
 MEXIN*

Kindly get this document scanned at the counter for the record purpose

[Signature]
Signature and Date

DEPARTMENT OF RADIOLOGY

Patient's Details : Ms. ASHWINI BHAT	F 032Y
UHID : AHB.0001086019	Ward/Bed No. : AHC /
I.P.No./Bill No. : AHBHC106566	Scanned on : 16-Jul-2022 12:47
Accession Number : 10601.222059064	Reported On :
Referring Doctor : Dr. MHC	

ULTRASOUND WHOLE ABDOMEN

Clinical Information: General health checkup.

Liver appears normal in size, shape and echopattern. No focal parenchymal lesions identified. No evidence of intra/extrahepatic biliary tree dilatation noted. Portal vein appears to be of normal size.

Gall bladder is partially distended.

Spleen appears normal in size, shape and echopattern. No focal parenchymal lesions identified.

Pancreas appears normal in size, shape and echopattern. No definite calcification or ductal dilatation noted.

Both kidneys appear normal in size, shape and echopattern. Corticomedullary differentiation appears maintained. No evidence of calculi or hydronephrosis seen on either side.

Urinary bladder is distended and appears normal. No evidence of abnormal wall thickening noted.

Uterus appears normal in size. Myometrial echoes appear normal. Endometrial thickness measures ~ 6 mm.

Both ovaries appear normal in size and echopattern.

No evidence of ascites or pleural effusion seen.

IMPRESSION:

USG study of the abdomen shows no significant abnormality.

- *Suggested clinical correlation.*

(Enclose reports) Ak

DR. VINEELA THALLA
RADIOLOGIST

Ultrasound is a subjective investigation. The results depend on distension of organ, bowel gas, patient co-operation and patient's body habitus. Patients are requested to inform the radiologist in advance regarding their clinical details and also any other prior surgeries (like gall bladder, uterus, ovaries, kidney stones etc..) that the study can be targeted according to the particular clinical condition.

N.B. : This is only a professional opinion and not the final diagnosis. Radiological investigations are subject to variations due to technical limitations. Hence, correlation with clinical findings and other investigations should be carried out to know true nature of illness.

CON - 106566

QF400AHB.pf.8203



DEPT. OF APOLLO HEALTH CHECK

GYNAECOLOGY CONSULT

Name	AHB.0001088018 MS. ASHWINI BHAT Age: 32 Year(s) Year(s)/Female 16 Jul 2022 9:11:26 AM	UHID :	Date : 16.7.22
	Age	Consultant Gynaecologist : Xi. Bati Anfy	

DRUG ALLERGIES : NIL

Complaints (related to Gynaec) - NIL SPECIFIC / YES

Known to have Diabetes / Hypertension / IHD / Asthma / Thyroid / Others NIL

Past Medical / Surgical History : hscs. Bartholin cyst - (L) operated.

Family History : NIL

OTHER SYSTEMS : WNL

GYNAEC HISTORY :

- Marital Status - S/M Others
- Children - 1
- Deliveries - hscs
- L.C.B. - Syn
- Abortion - -
- Periods - Regular 5-6/30 days
- L.M.P. - 19.6.22 severe dysmenorrhoea - not on medicine
- Menopause - -
- Contraception - -

Present Medication :

NIL

GYNAEC EXAMINATION :

P/A
P/V
S/E
P/R

Not co-operative
did not allow exam.

GENERAL EXAMINATION :

Weight : _____ Kgs, Height : _____ cm
General Condition :
Blood Pressure :
Thyroid : - NAD
Others :-

BREASTS : No mass palpable

PAP SMEAR Taken / Not Taken (Reason)

OPINION & ADVICE : USG - NAD

Tab Mefal spas 150s -
(after food
max 3 tabs/day)

REVIEW DETAILS : (with date)
With Patient / With reports only
→ lap smear sync
→ b/h sonar 8 months

Signature with Date & Time

16.7.22
11.55 AM

P.T.O. For more space

Dr. MEHTA .Y
 MBBS, DNB (Family Medicine)
 Senior Consultant
 Reg. No. : ANP20010000845KTK

Place Label Here
MS. Ashwini BHAT
1086019 30/17
 If label not available, write Pt. Name, UHID No.,
 Age, Sex, Date, Name of Treating Physician



Allergies : NRDA	Fall Risk Assessment		Wt: 48.7	Ht: 156cm	P: 86	BP: 102/62
	H/o fall (within 1 year)	Yes No	Pain 0 /10 <input type="checkbox"/> Psychological & Social Assessment done			
Mobility Aid	Yes No					
Gait	Dep. Indep.					

1. LDL-C - 107 mg/dl
2. TMT - Negative

Adv

- Balanced diet
- Good Hydration
- Regular exercise

**Medicine Reconciliation Dose & Frequency
 Advice & Plan**

Kindly get this document scanned at the counter for the record purpose

[Signature]
Signature and Date

DEPT. OF APOLLO HEALTH CHECK



CASE RECORD

Name	Age :	Sex : M/F
Age :	UHID :	

AHB.0001088018
 MS. ASHWINI BHAT
 Age: 32 Year(s) Year(s)/Female
 18 Jul 2022 9:11:28 AM



Physical Examination

General : Build Height ¹⁵⁶ 80 cm Weight 48.7 kg BMI :

Anaemia Icterus Cyanosis Clubbing

Oedema Glands

HEAD & NECK :

ENT :

CVS : Heart Rate & Rhythm 86 bpm SpO2 : 98 %

B.P. : Supine Sitting Standing

Chest shape 102/62 mmHg echo screening

Heart Sounds Normal LV systolic function

Murmurs EF-60% , NORWMA

Thrills RVSP - 15 + RAP

JVC Normal.

RS : Rate & Type

Breath Sounds

YOUR CLINICAL TEST RESULTS

Ms. ASHWINI BHAT

FEMALE / 32 Yrs / AHB.0001086019 / AHBHC106566

2022 MEDIWHEEL FULL BODY HEALTH CHECK UP FEMALE BELOW 40 YEARS

HEMOGRAM

Test Name	Result	Unit	Level	Range
Hemoglobin :Oxyhemoglobin method(Photometric measurement)	14.0	g/dL	●	11.5 - 15.5
RBC Count (Impedance)	4.3	x(10) ¹² /l	●	3.7 - 4.8
Packed cell volume (Calculated)	40	%	●	34 - 46
MCV (Derived from RBC histogram)	92	fl	●	83 - 101
MCH (Calculated)	32	pg	●	27 - 32
RDW (Calculated)	12.1	%	●	11.60-14.00
MCHC (Calculated)	35 *	g/dl	●	31.5 - 34.5
Platelet Count (Impedance)	232	x(10) ⁹ /l	●	150 - 450
WBC Count (Impedance)	6.64	x(10) ⁹ /l	●	4 - 11
Neutrophils	54	%	●	40 - 80
Lymphocytes	34	%	●	8.6 -23.8
Monocytes	6	%	●	2 - 10
Eosinophils	6	%	●	1 - 6
Basophils	0	%	●	0 - 2
ERYTHROCYTE SEDIMENTATION RATE (ESR) (Teflon Capillary Photometry)	11	mm/1st hr	●	Adult Female- 0 - 20

STOOL ROUTINE

Test Name	Result	Unit	Level	Range
Color :	Brownish			Yellow
Consistency :	Semi Solid			
Reaction:	Acidic			7.2-7.8
Blood :	NEGATIVE			NEGATIVE

● Within Normal Range

● Boderline High/Low

● Outside Range

YOUR CLINICAL TEST RESULTS

Ms. ASHWINI BHAT

FEMALE / 32 Yrs / AHB.0001086019 / AHBHC106566

2022 MEDIWHEEL FULL BODY HEALTH CHECK UP FEMALE BELOW 40 YEARS

Mucus:	Absent		
Pus Cells	1-2 /h.p.f	/HPF	0 - 5
RBC	Nil	Cells/hpf	0 - 2
Ova:	Absent		
Cysts:	Absent		
Trophozoite	Absent		
Yeast Cells	Yeast Cells Not Seen		
Vegetable Matter	Absent		

URINE ROUTINE (CUE)

Test Name	Result	Unit	Level	Range
Color :	Yellow			Yellow
Appearance	Clear			Clear
Volume :	30	ml		
pH	6.0			
Specific Gravity	1.020			1.016 - 1.022
Protein :	NEGATIVE			NEGATIVE
Glucose:	NEGATIVE			NEGATIVE
Ketone	NEGATIVE			NEGATIVE
Bile Salts :	NEGATIVE			NEGATIVE
Bile Pigments:	NEGATIVE			NEGATIVE
Urobilinogen	0.2	E.U./dL		0.2 - 1.0
Blood :	NEGATIVE			NEGATIVE
Nitrate:	NEGATIVE			NEGATIVE
Leucocyte Esterases	NEGATIVE			NEGATIVE
RBC	Nil	Cells/hpf		0 - 2
Pus Cells	1-2 /h.p.f	/HPF		0 - 5
Epithelial Cells	Occasional			Occasional - Few

BLOOD GROUPING AND TYPING (ABO and Rh)

APOLLO HOSPITALS
BANNERGATTA ROAD
BANGALORE

Station
Telephone:

EXERCISE STRESS TEST REPORT

Patient Name: ASHWINI BHAT,
Patient ID: AHB/1086019
Height: 156 cm
Weight: 49 kg

DOB: 17.07.1989
Age: 32yrs
Gender: Female
Race: Indian

Study Date: 16.07.2022
Test Type: Treadmill Stress Test
Protocol: BRUCE

Referring Physician: AHC
Attending Physician: DR K M NAIR
Technician: Vaishnavi

Medications:
--

Medical History:
--

Reason for Exercise Test:
Screening for CAD

Exercise Test Summary

Phase Name	Stage Name	Time in Stage	Speed (mph)	Grade (%)	HR (bpm)	BP (mmHg)	Comment
PRETEST	SUPINE	00:02	0.00	0.00	93	100/60	
	STANDING	00:06	0.00	0.00	93	100/60	
	HYPERV.	00:02	0.00	0.00	93		
	WARM-UP	00:05	0.00	0.00	92	100/60	
EXERCISE	STAGE 1	03:00	1.70	10.00	133	100/60	
	STAGE 2	03:00	2.50	12.00	146	110/60	
	STAGE 3	01:11	3.40	14.00	166	120/70	
RECOVERY		03:15	0.00	0.00	107	110/70	

The patient exercised according to the BRUCE for 7:11 min:s, achieving a work level of Max. METS: 10.10. The resting heart rate of 93 bpm rose to a maximal heart rate of 166 bpm. This value represents 88 % of the maximal, age-predicted heart rate. The resting blood pressure of 100/60 mmHg, rose to a maximum blood pressure of 130/70 mmHg. The exercise test was stopped due to Leg discomfort, Target heart rate achieved.

Interpretation

Summary: Functional Capacity: normal.
HR Response to Exercise: appropriate.
BP Response to Exercise: normal resting BP - appropriate response.
Chest Pain: none.
Arrhythmias: none.
ST Changes: none.


Conclusions

IMP:- STRESS TEST IS NEGATIVE FOR INDUCIBLE ISCHEMIA.

Physician



Technician

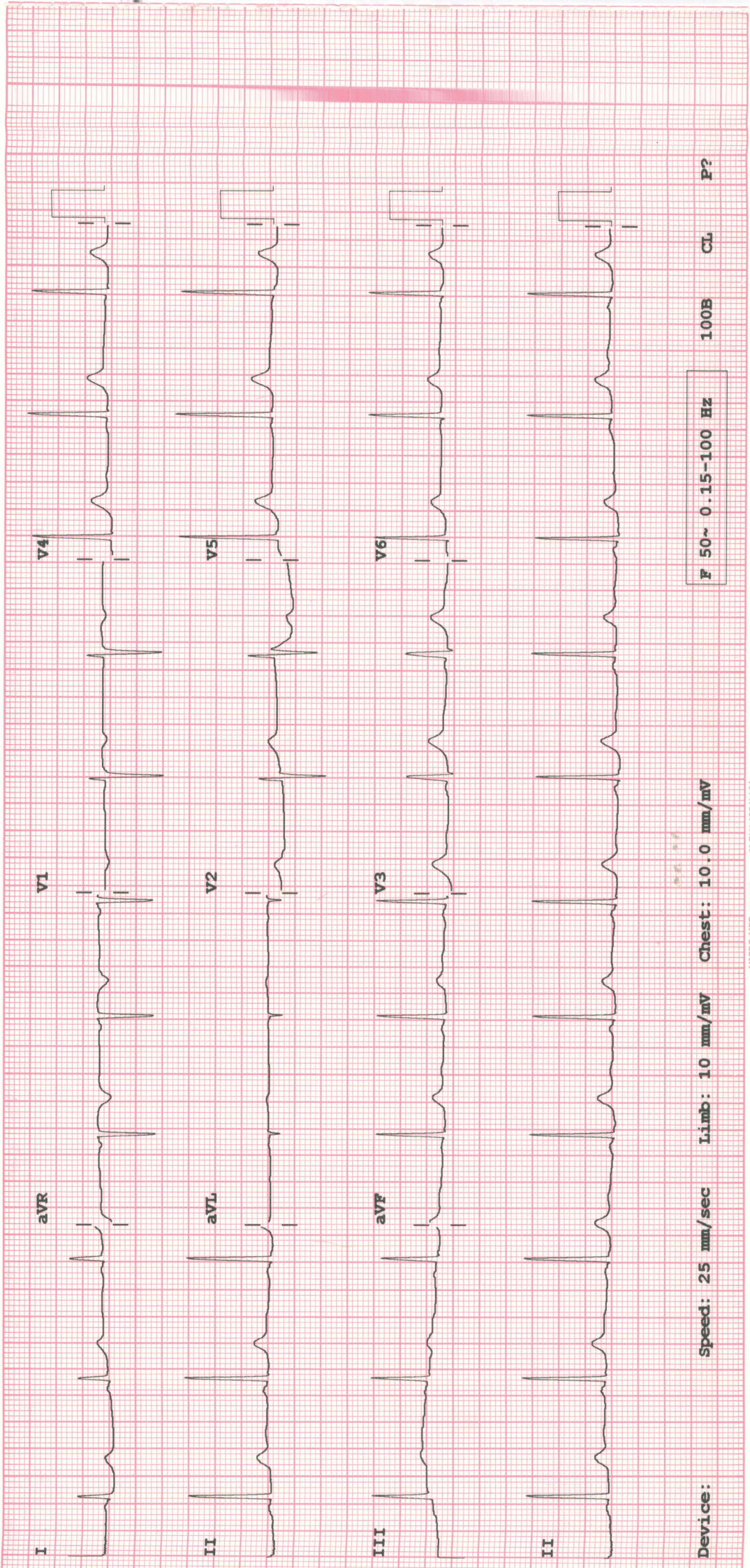
Rate 67

PR 114
QRSD 72
QTc 394
QTc 416

--AXIS--
P 40
QRS 64
T 44

12 Lead; Standard Placement

AHB.0001086019
MS. ASHWINI BHAT
Age: 32Year(s) Year(s)/Female
18 Jul 2022 8:11:25 AM



Device:

Speed: 25 mm/sec

Limb: 10 mm/mV

Chest: 10.0 mm/mV

F 50~ 0.15-100 Hz

100B CL P?