

Name : Mr. DAS SHISIR KUMAR SITANATH

Age: 57 Y

UHID:CKOR.0000248405

Sex: M

Address : kml

Plan : ARCOFEMI MEDIWHEEL MALE AHC CREDIT PAN
 INDIA OP AGREEMENT

OP Number:CKOROPV390063

Bill No :CKOR-OCR-79317

Date : 02.12.2023 09:41

Sno	Service Type/ServiceName	Department
1	ARCOFEMI - MEDIWHEEL - FULL BODY ANNUAL PLUS ABOVE 50Y MALE - 2D ECHO - PAN INDIA - FY2324	
1	URINE GLUCOSE(FASTING)	
2	GAMMA GLUTAMYL TRANSFERASE (GGT) R12	
3	PROSTATIC SPECIFIC ANTIGEN (PSA TOTAL.)	
4	HbA1c, GLYCATED HEMOGLOBIN	
5	2D ECHO R10	
6	LIVER FUNCTION TEST (LFT)	
7	X-RAY CHEST PA R11	
8	GLUCOSE, FASTING	
9	HEMOGRAM + PERIPHERAL SMEAR	
10	ENT CONSULTATION R23 Dr. Vijayrini	
11	FITNESS BY GENERAL PHYSICIAN	
12	DIET CONSULTATION	
13	COMPLETE URINE EXAMINATION	
14	URINE GLUCOSE(POST PRANDIAL)	
15	PERIPHERAL SMEAR	
16	ECG R14	
17	BLOOD GROUP ABO AND RH FACTOR	
18	LIPID PROFILE	
19	BODY MASS INDEX (BMI)	
20	OPHTHAL BY GENERAL PHYSICIAN R20	
21	RENAL PROFILE/RENAL FUNCTION TEST (RFT/KFT)	
22	ULTRASOUND - WHOLE ABDOMEN R17	
23	THYROID PROFILE (TOTAL T3, TOTAL T4, TSH)	
24	DENTAL CONSULTATION R15	
25	GLUCOSE, POST PRANDIAL (PP), 2 HOURS (POST MEAL)	

(28) Physico

11.40

11.30

ht 72.2 in

wt 165 cm

Bp - 150/84

pu - 83 mt

Apollo Clinic

Consent Form

Patient Name: SATISH KUMAR DAS Age: 57
UHID Number: Company Name: BANK OF BARODA

I ~~Mr~~ Mr SATISH KUMAR DAS Employee of BANK OF BARODA

(Company) want to inform you that I am not getting the.....

Test which is a part of health check package.

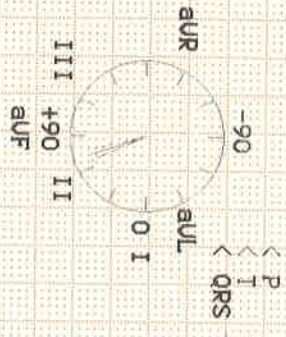
Reason If any: Physician and Dietician

And I claim the above statement in my full consciousness.

Consultancy will be done by meadon

Patient Signature: [Signature] Date: 01/12/2023

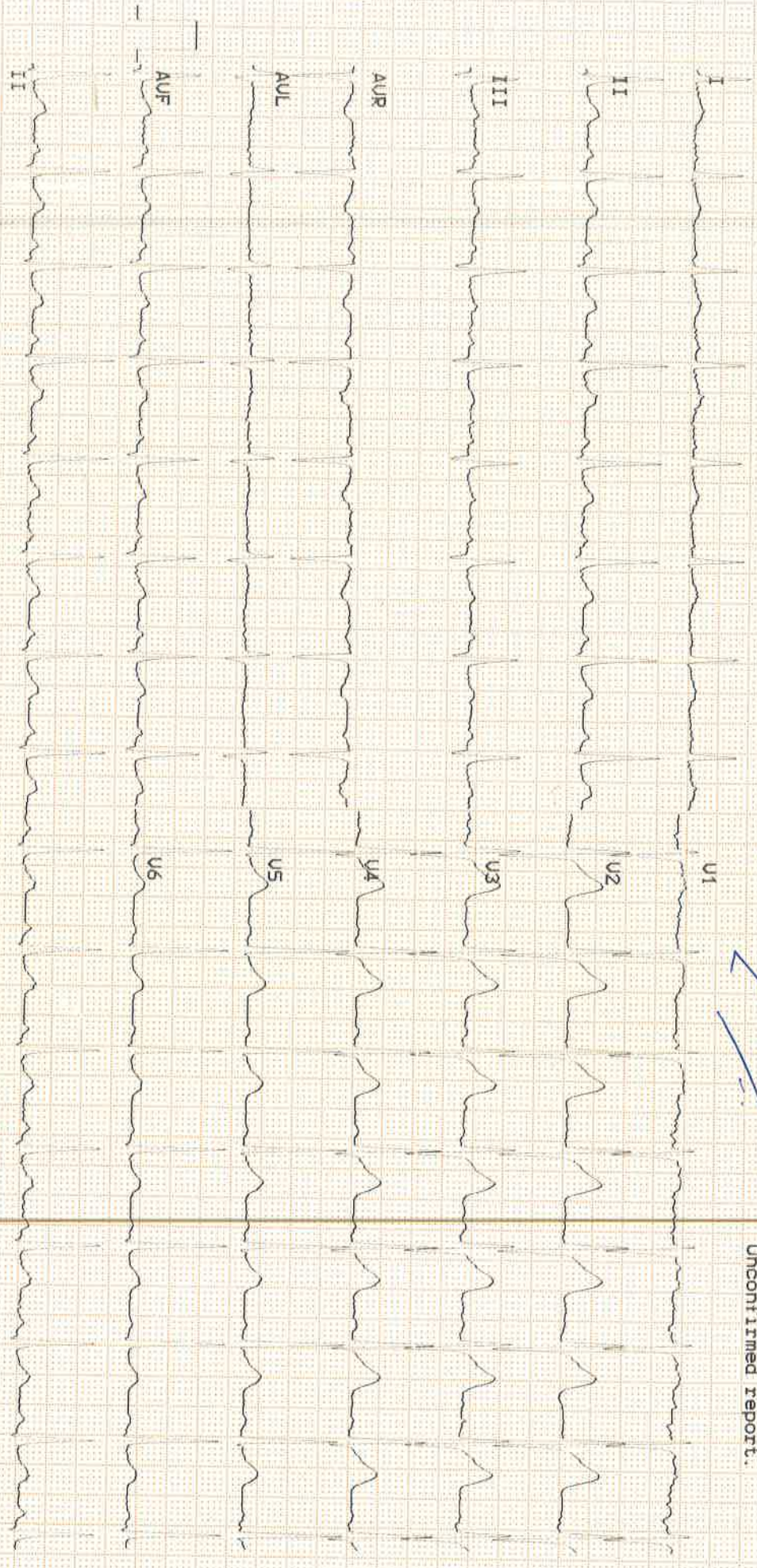AGE: 57
 Measurement Results:
 QRS : 94 ms
 QT/QTcB : 360 / 445 ms
 PR : 134 ms
 P : 94 ms
 RR/PP : 654 / 605 ms
 P/ORS/T : 75 / 70 / 65 degrees
 QTd/QTcBd : 30 / 37 ms
 Sokolow NK : 2.7 mV
 13



Interpretation:

Normal sinus rhythm
 'q' wave III/II/IV
 -low T

Unconfirmed report.



02.10.2023 10:27:20 2023/10/02 10:27:20 5014 0.08 2012 5.71 E A Normalis 06 2 101 443

Patient Name : Mr. DAS SHISIR KUMAR SITANATH Age : 57 Y/M
UHID : CKOR.0000248405 OP Visit No : CKOROPV390063
Reported By : Dr. TOBY ABRAHAM THOMAS Conducted Date : 03-12-2023 10:31
Referred By : SELF

ECG REPORT

Observation :-

1. Normal Sinus Rhythm.
2. Heart rate is 91beats per minutes.
3. No pathological S-T,T changes seen.
4. Normal P,R,S,T waves and axis.Q wave III/aVF ? IHD
5. No evidence of chamber, hypertrophy or enlargement seen.

Impression:

IHD?

Dr. TOBY ABRAHAM THOMAS
CARDIOLOGIST

NOTE : KINDLY TAKE A PHOTOCOPY OF THE GRAPH
FOR FUTURE REFERENCE IF NEEDED.

----- END OF THE REPORT -----



DR VIJAYA LAKSHMI M
M.B.B.S, D.L.O, D.N.B(ENT)
Phone No.9972044580,080-25633823/24/23



Apollo Medical
Centre
Expertise. Closer to you.

HEALTH CHECK- ENT

02/11/23

NAME: *Mr. Das Abdul P Kumar*

AGE: *52*

EAR:

RE:

LE:

EXTERNAL EAR

MIDDLE EAR

INNER EAR (FN)

normal

HEARING ASSESSMENT:

RE:

LE:

RHINNE

WEBER

ABC

normal

NOSE

THROAT

AIRWAY

ORAL CAVITY

SEPTUM

OROPHARYNX

TURBINATES

PHARYNX

OTHERS

LARYNX

normal

normal

NECK

NECK NODES

OTHER

normal

AUDIOMETRY

IMPRESSION

normal

[Signature]

SIGNATURE:

Apollo Health and Lifestyle Limited

(CIN - U85110TG2000PLC046089) Regd. Office: #7-1-617/A, 615 & 616, Imperial Towers, 7th Floor; Ameerpet, Hyderabad, Telangana - 500 038 | Email ID: enquiry@apollohl.com

APOLLO CLINICS NETWORK KARNATAKA

Bangalore (Basavanagudi | Bellandur | Electronics City | HSR Layout | Indira Nagar | JP Nagar | Kundalahalli | Koramangala | Sarjapur Road) **Mysore** (Kalldasa Road)

Online appointments: www.apolloclinic.com

TO BOOK AN APPOINTMENT

1860 500 7788

Patient Name : Mr Das Shisir Kumar Sitanath

Patient ID: 248405

Age : 57Year(s)

Sex : Male

1Referring Doctor : H/C

Date : 02.12.2023

ULTRASOUND ABDOMEN AND PELVIS

FINDINGS:

Liver is enlarged in size (measuring 16.0cms)and shows increased echotexture. No biliary dilatation. No focal lesion

CBD is not dilated. Portal vein is normal in size, course and calibre.

Gall bladder is normal without evidence of calculi, wall thickening or pericholecystic fluid.

Pancreas to the extent visualized, appears normal in size, contour and echogenicity

Spleen is normal in size, shape, contour and echopattern. No evidence of mass or focal lesions.

Right Kidney is normal in size, position, shape and echopattern. Corticomedullary differentiation is maintained. No evidence of calculi or hydronephrosis.

Left Kidney is normal in size, position, shape and echopattern. Corticomedullary differentiation is maintained. No evidence of calculi or hydronephrosis.

Urinary Bladder is well distended. Wall thickness is normal. No evidence of calculi, mass or mural lesion.

Prostate: normal in size and exchotexture.

There is no ascites.

IMPRESSION: HEPATOMEGALY WITH GRADE I FATTY INFILTRATION

**DR VINOD JOSEPH DNB,DMRD
RADIOLOGIST**

DR. MAHABALESHWAR.M
MBBS.(MYS), MD(AIIMS DELHI)FICS
D.O (JIPMER)
REG.NO:KMC:9748

DATE: 2/12/23
OP NO:

THE APOLLO MEDICAL CENTER KORAMANGALA

NAME: Dal Phulke Kemer. Suler
AGE : 57
GENDER: M.

OPHTHALMIC REPORT

Dr. Phulke - eye,

RIGHT EYE

LEFT EYE

GENERAL APPEARANCE

VISION - DISTANCE

WITHOUT GLASS

WITH GLASS

GLASS POWER

EL6 / EL6

NEAR

WITHOUT GLASS

WITH GLASS

GLASS POWER

NG NG

COLOUR

Post by one

ANTERIOR SEGMENT:-

FUNDUS *one*

I.O.P: DIGITAL

DOCTOR SIGNATURE

NAME: MR. DAS SHISIR KUMAR SITANATH

AGE: 57Y

SEX: MALE

DATE: 02/12/2023

ECHOCARDIOGRAPHY REPORT

MEASUREMENT

AO -23(20 – 35)mm	LIVD d – 45(36-52)mm	IVS - 10 (06 - 11)mm
LA -27(19- 40)mm	LVID s – 31(23- 39)mm	PWD – 10(06- 11)mm
EF - 60% (>50%)	RVID-22	

VALVES

Mitral Valve : Normal
Aortic Valve : Normal
Tricuspid Valve : Normal
Pulmonary Valve : Normal

CHAMBERS

Left Atrium : Normal
Right Atrium : Normal
Left Ventricle : Normal
Right Ventricle : Normal

SEPTAE

IVS : Intact
IAS : Intact

GREAT ARTERIES

Aorta : Normal
Pulmonary Artery : Normal

DOPPLER DATA

Mitral : E > A
Aortic : Normal
Tricuspid : Normal
Pulmonary : Normal

WALL MOTION ABNORMALITIES : No RWMA

Pericardium : Normal

FINAL DIAGNOSIS

**NORMAL CHAMBERS AND VALVES
NORMAL BIVENTRICULAR FUNCTION
NO RWMA AT REST, LV EF -60%**



**DR. MOHAN MURALI
CONSULTANT
CARDIOLOGIST**

Patient Name	: Mr. DAS SHISIR KUMAR SITANATH	Age	: 57 Y M
UHID	: CKOR.0000248405	OP Visit No	: CKOROPV390063
Reported on	: 04-12-2023 11:33	Printed on	: 04-12-2023 11:43
Adm/Consult Doctor	:	Ref Doctor	: SELF

DEPARTMENT OF RADIOLOGY

X-RAY CHEST PA

Right upper zone calcification seen.

Rest of the lungs fields appear normal.

Both hila are normal.

Both costophrenic and cardiophrenic angles are normal.

The cardiac and mediastinal shadows appear normal.

Bones and soft tissues appear normal.

IMPRESSION : RIGHT UPPER ZONE CALCIFICATION


Dr. VINOD JOSEPH DNB, DMRD
RADIOLOGIST