

Brodh Kumar Misha

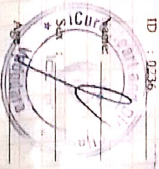
10/2/2024

HR : 66
 RR : 400
 PR : 169
 QRS : 96
 QT/QTc : 378/398
 P/QRS/T : -6/24/31
 R/S/ST : 1.1/90.1/210p
 R/S/ST : 2.4/00

— Undefined Rhythm
 — Mild Left Axis Deviation

Dr. Krish P. Vaidya
 MD, PGCC
 Assoc. Consultant - Cardiology
 Reg. No. G-50510

Unconfirmed report. Verified by:



VI-066/Rev: V1.0/00 2011-01-13 01:37


Heart & General Clinic

Icure Heart & Diet Clinic, 402, Epsilon tower, opp Pasha bhai park, Race course, Vadodar

:: PERSONAL HEALTH REPORT ::

<p align="center"><u>Binod Kumar Mishra</u></p>	<p align="center">N 1012/2024</p>
	<p>SR. NO. SEX. male AGE 46 years HEIGHT 168cm WEIGHT 84kg.</p>

HISTORY

Present History : NO
 Past Illness History : NO Diabetes/Hypertension/Tuberculosis/Asthma/Epilepsy
 Past Occupational History : NO
 Family History : NO
 Personal History : NO
 Addiction : NO Tobacco/Gutkha/Smoking/Alcohol

GENERAL EXAMINATION

T.P.R. : 66 / min B.P. : 124 / 80 mm Hg :
 Pallor/Icterus/Cyanosis/Varicosity/Lymph Nodes/Thyroid/Oedema/NVE/Other :

SYSTEMIC EXAMINATION

R.S. : NAD
 C.V.S : NAD
 C.N.S : NAD
 A.S. : NAD
 Musculo-skelet System : NAD

E.N.T. Ex. <u>NAD</u>	ACUITY OF VISION		RT EYE - <u>0.5</u>	LT EYE - <u>0.5</u>
	Without Glass	DISTANT	6/	6/
		Near	6/	6/
	With Glass	DISTANT	6/	6/
Near		6/	6/	
Dental Ex. <u>NAD</u>		COLOUR BLINDNESS <u>NAD</u>		
Skin Ex. <u>NAD</u>				
Psychic Ex. <u>NAD</u>				

REMARK
ADVICE
 The Worker is FIT / UNFIT for the assigned job.



Dr. Krish P. Vaidya
 MD, PDCC
 Associate Consultant - Cardiology
 Reg. No. G-50510
 DR. KRISH VAIDYA
 MD G-50510, CIM



भारतीय विशिष्ट ओळख प्राधिकरण
भारत सरकार
 Unique Identification Authority of India
 Government of India

नोंदविण्याचा क्रमांक / Enrollment No 1293/60211/03225

To,
 बीनोद कुमार मिश्रा
 Binod Kumar Mishra
 S/O. Bajinath Mishra
 Chandauna
 Chandauna
 Chandauna Jale Darbhanga
 Bihar 847303
 9798655548

Ref: 22361 / 23I / 629334 / 629401 / P



SH331301202FT



आपला आधार क्रमांक / Your Aadhaar No. :

7503 5703 7140

आधार - सामान्य माणसाचा अधिकार



भारत सरकार
 Government of India



बीनोद कुमार मिश्रा
 Binod Kumar Mishra
 जन्म वर्ष / Year of Birth : 1978
 पुरुष / Male



7503 5703 7140

आधार - सामान्य माणसाचा अधिकार

Bank of Baroda
 बैंक ऑफ बरोडा
 नाम
 Name **बिनोद कुमार मिश्रा**
 Binod Kumar Mishra
 कर्मचारी प्लूट नं.
 E.C No **99514**
 अधिकृत अधिकारी
 Issuing Authority
 बिनोद कुमार मिश्रा
 Signature of Member

Binod Kumar



2D Echocardiography & Color Doppler Report

301, Trivia Complex, near Natubhai Circle, Racecourse Road

Patient Name: Mr. BINOD KUMAR MISHRA Date: 10 / 02 / 2024

Age Gender: male, 46Years

Ref. Doctor: DR. KRISH VAIDYA

M. Mode Study:

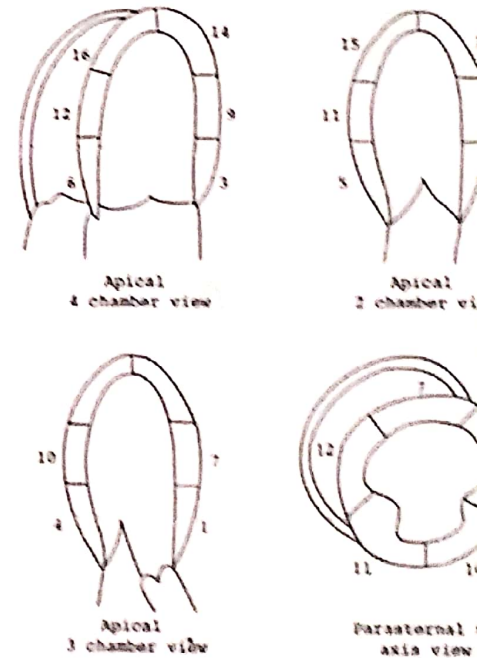
LA	34	IVS	12	PWD	12
AO	25	LVDs	27	LVDd	46

Doppler Study:

Mitral Valve	E: 1.0 A:0.6
Aortic Valve	Normal
Tricuspid Valve	Normal
Pulmonary Valve	Normal

Conclusion:


- Normal LV Systolic function
- LVEF: 60 % , No RWMA at Rest
- Cardiac Chambers: Normal
- Diastolic function: Normal
- TR: Trace PAH: No RVSP: 24mmHg
- No MR , No MS
- No AR , No AS
- ASD/VSD/PDA/Co-A : No
- No Clots or vegetations found
- IVC: 14 mm size with >50 % collapsive



Note:

Normal 2D echo report does not rule out cardiac diseases
this report shall not be used for Medico legal purposes,
Clinical Correlation advisable.

Dr. Krish P Vaidya
MD, PhD
Asso. Consultant-Cardiology
Reg. No. 30510



PARAMOUNT DIAGNOSTIC & RESEARCH CENTRE

(A Unit of Paramount Charity Trust)

Radiology ■ Pathology ■ Histopathology ■ Molecular Biology

NAME : BINODKUMAR MISHRA

AGE : 46 Y/M

DATE : 10/02/2024

ULTRASOUND WHOLE ABDOMEN

Liver is normal in size 15.9cm and shows raised parenchymal reflectivity. No focal lesion is seen. Hepatic veins appear normal. There is no evidence of any dilated intra hepatic biliary radicals.

Portal Vein appears normal in diameter. Common Bile Duct is of normal diameter.

Gallbladder is distended with normal wall thickness. There is no evidence of gallstones. No evidence of peri-cholecystic fluid or probe tenderness.

Pancreas is normal in size and shows homogenous reflectivity. There is no evidence of any calcification or ductal dilatation.

Spleen is normal 12.4cm size and shows a homogenous echotexture. There is no evidence of any focal lesion.

Both Kidneys are normal in position and size. They show normal cortical reflectivity and cortico-medullary distinction. Right kidney measures 106 x 48 mm. Left kidney measures 106x54mm. There is 3.3 mm size calculus noted in lower pole of left kidney

Pre void urine volume is 171 cc
Post void residual urine volume is 15cc.

Bladder is minimally full; wall appears thickened irregular measures 6 mm. No evidence of intra-luminal mass or calculi.

Prostate gland is normal in size. It has smooth outlines and normal reflectivity. Estimated volume is around 28 cc.

There is no evidence of ascites.
No evidence of any gross bowel dilatation seen.
No evidence of any aorto-caval or mesenteric root lymphadenopathy.
Appendix cannot be imaged. No mass or collection in right iliac fossa.

CONCLUSION:

- Mild hepatomegaly with Grade II fatty liver.
- Mildly thickened urinary bladder wall- Urine RM correlation recommended to rule out changes of cystitis.
- A tiny left renal calculus.

Clinical correlation recommended.



Shaily
DR. SHAILY JANI (M.D., DNB)
CONSULTANT RADIOLOGIST

24 hours Emergency Service Available for CT Scan / MRI / Pathology AMBULANCE SERVICE AVAILABLE

Main Branch: Paramount Complex, Gotri Road, Race Course, Vadodra, Ph. : 0265-2395772, 2397438, 6647222, +91 - 6352731483,
Path. Lab : 0265 - 6603900/901/902/903, +91 - 8160225911, +91 - 9099066029

City Branch: Opp. Brahman Sabha Hall, Pratap Road, Dandlabazar, Vadodra. Ph.: 0265 - 2423233, +91 - 6352734810



PARAMOUNT DIAGNOSTIC & RESEARCH CENTRE

(A Unit of Paramount Charity Trust)

Radiology ■ Pathology ■ Histopathology ■ Molecular Biology

NAME : BINODKUMAR MISHRA

AGE : 46 Y/M

DATE : 10/02/2024

X RAY CHEST (PA)

OBSERVATIONS:

Both the lung fields and apices appear clear.

Both the hilar shadow appears normal.

Cardiac silhouette appears normal.

Both the costophrenic sinuses are clear.

Mediastinal and tracheal shadows are normal.

Both the domes of diaphragm are normal.

Visualized rib cage and clavicle are normal.

COMMENTS:

No significant abnormality is seen.

Shaily
DR. SHAILY JANI (M.D., DNB)
CONSULTANT RADIOLOGIST



24 hours Emergency Service Available for CT Scan / MRI / Pathology AMBULANCE SERVICE AVAILABLE

Main Branch : Paramount Complex, Gotri Road, Race Course, Vadodra, Ph. : 0265-2395772, 2397435, 8847222, +91 - 6362731483,

Path. Lab : 0265 - 6603900/901/902/903, +91 - 8160225911, +91 - 6099066029

City Branch : Opp. Brahman Sabha Hall, Pratap Road, Dandlabazar, Vadodra. Ph.: 0265 - 2423233, +91 - 6362734910



301 Trivia complex, near Natubhai circle, Racecourse Road

Name : BINODKUMAR MISHRA
Ref By : ICURE HEART & DIET CLINIC

Age/Sex : 46 Yrs./M
Date : 10/02/2024
Report ID. : 5

HAEMOGRAM PROFILE

<u>TEST</u>	<u>RESULT</u>	<u>UNIT</u>	<u>METHOD</u>	<u>REFERENCE INTERVAL</u>
<u>BLOOD COUNTS & INDICES</u>				
Haemoglobin	: 13.00	gm%		13.5 - 17.0 gm%
Total RBC	: 4.51	mill/cmm		4.6 - 6.2 mill/cmm
PCV	: 30.00	%		40 - 54 %
MCV	: 66.51	fL		80 - 96 fL
MCH	: 28.82	pg		27 - 31 pg
MCHC	: 43.33	%		32 - 36 %
RDW	: 12.00	%		10 - 15 %
Total WBC	: 7,800	/cmm		4,000 - 11,000/cmm
Platelet Count	: 3,08,000	/cmm		1.5 - 4.0 Lac/cmm
<u>DIFFERENTIAL LEUCOCYTES COUNT</u>				
Band Cells	: 00	%		00 - 06 %
Neutrophils	: 66	%		55 - 70 %
Lymphocytes	: 30	%		20 - 40 %
Eosinophils	: 02	%		01 - 06 %
Monocytes	: 02	%		02 - 08 %
Basophils	: 00	%		00 - 01 %
Platelet In Smear	: ADEQUATE			
<u>ERYTHROCYTES SEDIMENTATION RATE</u>				
ESR After 1st Hour	: 8	mm	Westergren	01 - 07 mm
Blood Group	: * O *			
Rh Factor (Anti D.)	: * POSITIVE *			

(By Fully Automated Cell Counter Sysmex KN - 21, Japan)

END OF REPORT



301 Trivia complex, near Natubhai circle, Racecourse Road

Name : BINODKUMAR MISHRA
Ref By : ICURE HEART & DIET CLINIC

Age/Sex : 46 Yrs./M
Date : 10/02/2024
Report ID. : 5

BIOCHEMISTRY

<u>TEST</u>	<u>RESULT</u>	<u>UNIT</u>	<u>REFERENCE INTERVAL</u>
Blood Urea	: 29.00	mg/dL	10 - 50 mg/dL
Blood Urea Nitrogen - BUN	: 13.00	mg/dL	4.5 - 19.0 mg/dL
Serum Creatinine	: 0.90	mg/dL	0.6 - 1.4 mg/dL
Serum Uric Acid	: 4.50	mg/dL	3.4 - 7.0 mg/dL
<u>SERUM PROTEIN</u>			
Serum Protein Total	: 7.00	g/dL	6.6 - 8.3 g/dL
Albumin	: 4.10	g/dL	3.5 - 5.0 g/dL
Globulin	: 2.90	g/dL	2.3 - 3.5 g/dL
A/G Ratio	: 1.4	: 1	1.5 - 2.5 : 1
Billirubin - Total	: 0.5	mg/dL	0.00 - 1.00 mg/dL
Billirubin - Direct	: 0.2	mg/dL	Upto 0.30 mg/dL
Billirubin - Indirect	: 0.3	mg/dL	0.1 - 1.0 mg/dL
SGPT	: 16.0	IU/L	10 - 40 IU/L
SGOT	: 29.0	IU/L	Upto 40 IU/L
Serum Alkaline Phosphatase	: 48.0	U/L	37 - 147 U/L
<u>FASTING (FBS)</u>			
Blood Glucose	: 132.0	mg/dL	70 - 110 mg/dL
<u>POST-PRANDIAL</u>			
Blood Glucose	: 158.0	mg/dL	80 - 140 mg/dL
<u>SPECIAL TESTS</u>			
GGTP	: 11	U/L	05 - 85 U/L
Gamma Glutamyltransferase			

Done By Fully Auto Analyzer MIURA, A-1004

END OF REPORT



301 Trivia complex, near Natubhai circle, Racecourse Road

Name : BINODKUMAR MISHRA
Ref By : ICURE HEART & DIET CLINIC

Age/Sex : 46 Yrs./M
Date : 10/02/2024
Report ID. : 5

LIPID PROFILE

<u>TEST</u>	<u>RESULT</u>	<u>UNIT</u>	<u>REFERENCE INTERVAL</u>
Total Lipid (Calculated)	: 1035	mg/dL	350 - 750 mg/dL
Serum Cholesterol	: 234.0	mg/dL	130 - 200 mg/dL
Serum Triglyceride	: 311.0	mg/dL	60 - 165 mg/dL
HDL Cholesterol	: 46.0	mg/dL	30 - 70 mg/dL
LDL Cholesterol	: 125.8	mg/dL	Upto 150 mg/dL
LDL Cholesterol - Direct	: 118.0	mg/dL	Upto 150 mg/dL
CHOL/HDL Chol. Ratio	: 5.08	:1	Less than 5
LDL Chol/HDL Chol Ratio	: 2.73	:1	Less than 3.5
VLDL (Calculated)	: 62.20	mg/dL	Upto 30 mg/dL

Hb A1C REPORT

Hb A1C - Glycated Hb Glycated Haemoglobin	: 7.2	%	Non Diabetic : 4.3 - 6.3 % Good Control : 6.4 - 7.5 % Moderate Control : 7.5 - 9.0 % Poor Control : 9.0 % & Above
Avg. Blood Glucose Level	: 179	mg/dL	
Estimated Average Glucose eAG	: 160	mg%	

END OF REPORT

301 Trivia complex, near Natubhai circle, Racecourse Road

Name : BINODKUMAR MISHRA
Ref By : ICURE HEART & DIET CLINIC

Age/Sex : 46 Yrs./M
Date : 10/02/2024
Report ID. : 5

PROSTATE SPECIFIC ANTIGEN

<u>TEST</u>	<u>RESULT</u>	<u>UNIT</u>	<u>REFERENCE INTERVAL</u>
P. S. A.	: < 0.81	ng/ml	0.0 - 4.0 ng / ml (i) 04 - 15 ng/ml Possibly Benign Prostate Hyperplasia (ii) > 20 ng/ml Suspected Prostate Carcinoma

END OF REPORT

301 Trivia complex, near Natubhai circle, Racecourse Road

Name : BINODKUMAR MISHRA
Ref By : ICURE HEART & DIET CLINIC

Age/Sex : 46 Yrs./M
Date : 10/02/2024
Report ID. : 5

EXAMINATION OF URINE

<u>TEST</u>	<u>RESULT</u>	<u>UNIT</u>
Sample	: FASTING	
<u>PHYSICAL EXAMINATION</u>		
Quantity	: 10	mL
Colour	: COLOURLESS	
Transperancy	: CLEAR	
Specific Gravity	: 1.003	
Reaction	: ACIDIC	
Deposits	: ABSENT	
<u>CHEMICAL EXAMINATION</u>		
Albumin	: NIL	
Sugar	: NIL	
Acetone	: ABSENT	
Bile Salts	: ABSENT	
Bile Pigments	: ABSENT	
Urobilinogen	: NORMAL : ~ < 1.0 mg/dL	
Occult Blood	: ABSENT	
Nitrate	: ABSENT	
<u>MICROSCOPIC EXAMINATION</u>		
Pus Cells	: 0-1 / hpf	
RBC	: NIL	
Epithelial Cells	: NIL	
Crystals	: NIL	
Amorphous Phosphate	: NIL	
Cast	: NIL	

THYROID FUNCTIONS

Total Triiodothyronine - T3	: 1.31	ng/mL	0.58 -1.59 ng/mL
Total Thyroxine - T4	: 8.90	ng/mL	4.87 - 11.72 microgram%
Thyroid Sti. Hormone -TSH	: 2.09	ng/mL	0.35 - 4.94 IU/mL

END OF REPORT

