

3 March 2023

<wallness@medlwheel.in>  
edckc234@gmail.com  
edckc234@gmail.com

011-41195959

Email: wallness@medlwheel.in

Dear Dr. Charu Kohli Clinic,

City Delhi, Address : A C-234, Block C, Defence Colony.

We have received the confirmation for the following booking.

Name : ~~MS. HALDAR~~ **SACHIN SHARMA**  
 Age : 31  
 Gender : Female  
 Package Name : Medi-Whol Metro Full Body Health Checkup Female Below 40  
 User Location : NEW DELHI, Delhi, 110029  
 Contact Details : 7890245466  
 Booking Date : 03-03-2023  
 Appointment Date : 04-03-2023

*Sachin Sharma*

Member Information

<del>MS. HALDAR</del>	31	Female	Cashless
<b>Total amount to be paid</b>		<b>Cashless</b>	

We will get back to you with confirmation update shortly. Please find the package details as attached for your reference.

Package Name : Medi-Whol Metro Full Body Health Checkup Female Below 40 (37 Tests)

Tests included in this Package :  
 Ecg, TSH, X-ray Chest, Stress Test (mt) / 2d Echo, Blood Sugar Postprandial, A/g Ratio, Blood Group, Total Cholesterol, Triglycerides, Fasting Blood Sugar, Ultrasonnd Whole Abdomen, Glycosylated Haemoglobin (hba1c), HDL, VLDL, Urine Analysis, LDL, Total Protine, General Consultation, HDL/ LDL ratio, GG(T(Gamma-glutamy) Transferase), Eye Check-up, consultation, ALP (ALKALINE PHOSPHATASE), Uric Acid, ACT/ALT Ratio, Serum Protein, U with FSR, Stool Analysis, Urine Sugar Fasting, Urine Sugar PP, T x, Cholesterol Total / HDL Ratio, BUN, BUN/Creatinine Ratio, Bilirubin Total Direct and Indirect, Albumin, Globulin

- USG  
 - PP.  
 - Stool - (SNK)

CHARU HEALTH CHECK UP <insuranceedckc234@gmail.com>  
edckc234@gmail.com <wallness@medlwheel.in>

3 March

ATED



DR. CHARU HEALTH CHECK UP &lt;insurancedckc234@gmail.com&gt;

**Health Check up Booking Confirmed Request(bobS31750),Package Code-PKG10000240, Beneficiary Code-38096**

1 message

7 March 2023 at 15:43

Mediwheel <wellness@mediwheel.in>  
To: insurancedckc234@gmail.com  
Cc: mediwheelwellness@gmail.com



011-41195959

Email:wellness@mediwheel.in

Hi Dr. Charu Kohli Clinic,

Diagnostic/Hospital Location : u C-234, Block C, Defence Colony, .City:Delhi

We have received the confirmation for the following booking .

Beneficiary Name : PKG10000240

Beneficiary Name : SACHIN SHARMA

Member Age : 38

Member Gender : Male

Member Relation : Spouse

Package Name : Medi-Wheel Metro Full Body Health Checkup Male Below 40

Location : NEW DELHI,Delhi-110029

Contact Details : 7890245466

Booking Date : 03-03-2023

Appointment Date : 09-03-2023

**Instructions to undergo Health Check:**

1. Please ensure you are on complete fasting for 10-To-12-Hours prior to check.
2. During fasting time do not take any kind of medication, alcohol, cigarettes, tobacco or any other liquids (except Water) in the morning.
3. Bring urine sample in a container if possible (containers are available at the Health Check centre).
4. Please bring all your medical prescriptions and previous health medical records with you.
5. Kindly inform the health check reception in case if you have a history of diabetes and cardiac problems.

**For Women:**

1. Pregnant Women or those suspecting are advised not to undergo any X-Ray test.
2. It is advisable not to undergo any Health Check during menstrual cycle.

We request you to facilitate the employee on priority.



**BAR COUNCIL OF DELHI**

(Statutory Body Under The Advocates Act, 1961)

H.O.: 2/6, Siri Fort Ind. Area, Khet Geon Marg, N. Delhi-49, Ph.: 254983585/19555196  
Website: www.delhibarcouncil.com, Email: barcouncilofdelhi@gmail.com



S.No. 5857/S/1047 Valid upto 30.11.2018

SACHIN SHARMA

ADVOCATE

Enrolment No. D/2664/2013

Date of Enrolment

07.10.2013

**SURYA PRAKASH KHATRI**  
Chairman

**MURARI TIWARI**  
Hon. Secretary

*Bar of Baroda*

*387A*

*ml*

**DR. CHARU KOHLI**  
**CONSULTANT MBBS**  
**DMC-8388**



NAME : SACHIN SHARMA  
 AGE/SEX : 38 Y/ M  
 DATE : 09.03.2023

Height	Weight	BMI	BP
164 cm	68 kg	25.3	110/ 70mmHg
HABITS	SMOKING : OCC. ALCOHOL : NO. DRUGS : NO		

Family History:

- Asthma : NO
- Diabetes : NO
- TB : NO
- THYROID : NO
- Heart Disease : NO
- BP : NO

Personal History:

- TB : NO
- Rheumatic : NO
- Heart Disease : NO
- Acquired deformity : NO
- Operated for : NO
- Psychosomatic history : NO
- Diabetes : NO
- THYROID : NO
- BP : NO

Eye / Vision	DISTANCE VISION		NEAR VISION		COLOUR VISION	GLASSES
	RT EYE	LT EYE	RT EYE	LT EYE		
	6/6	6/6	N/6	N/6		

Signature of Medical Examiner: *hne*

**DR. CHARU KOHLI**  
 CONSULTANT MBBS  
 DMC-8388

**NAME: SACHIN SHARMA**

**DATE: March 9, 2023**

### WHOLE ABDOMEN SCAN

Liver is normal in size and echotexture is maintained. Normal intrahepatic biliary radicles and normal appearing venous channels noted. No focal lesion in either lobes. Portal vein is normal. No sub-diaphragmatic collection or pleural effusion.

Gall bladder is normal distended and shows echofree lumen.  
CBD: not dilated ; apparently echofree.

Both the kidneys are normal in size, position and echopattern with normal corticomedullary differentiation.

RK: 10.39 x 5.27 cm.

LK: 10.48 x 5.37 cm

Pancreas is of normal size & echopattern. No focal lesion or peri-pancreatic collection.

Spleen is of normal size and echopattern. No focal lesion or calcification. Splenic vein is not dilated.

Aorta and IVC are normal. No retroperitoneal lymphadenopathy.

Urinary bladder shows normal distension and shows normal wall-thickness. No calculus or mass.

Prostate is normal in size measures 2.81 x 3.24 x 2.26 cm ~ vol-10.78. cc, echopattern is homogenous.

Bowel loops are normal.

No free fluid is seen in abdomen.

### IMPRESSION:

**Sonological study is within normal limits .**

*hkh*  
Dr Charu Kohli  
MBBS DMRD  
DMC8388

**DR. CHARU KOHLI**  
CONSULTANT RADIOLOGIST  
DMC - 8388  
DR. CHARU KOHLI'S CLINIC  
C-234, DEFENCE COLONY, NEW DELHI-110024

**IMPORTANT:** Owing to technical limitations ,in case of any error in the study ,the Doctor cannot be held responsible for claim of damages of any nature,and this report is not valid for any Medicolegal aspect.

Every modern technology has its own limitations , in case of discrepancy/difference in opinion advised- repeat scan/ second opinion

**At Your Home: Digital X-Ray, Blood Samples, ECG, PFT, HOLTER, EEG, ABG**

Occupational Health Services ■ Diagnostic & Preventive Health Assessment ■ Periodic Preventive Health Camps ■ Corporate Health Checks  
Test marked with \* are not in NABL Scope. / Tests marked with # are performed at outsourced laboratory.

**Ultrasound | Digital X Ray | DEXA | Mammography | Path Lab | ECHO | TMT | Healthchecks | PFT | Holter | Audiometry**





# DR. CHARU KOHLI'S CLINIC

C-234, DEFENCE COLONY, NEW DELHI

Mr. SACHIN SHARMA  
 Age/Sex : 38/M  
 Recorded : 9-3-2023 12:13  
 Ref. by :  
 Indication : ,

ID : 274  
 Ht/Wt : /

## TREADMILL TEST SUMMARY REPORT

Protocol: BRUCE  
 History:  
 Medication : ,

*Sachin Sharma*

PHASE	PHASE TIME	STAGE TIME	SPEED (Km./Hr.)	GRADE (%)	H.R. (BPM)	B.P. (mmHg)	RPP X100	ST LEVEL (mm)			METS
								II	V2	V5	
SUPINE					64	110/70	70	2.1	5.1	2.5	
HYPERVENT	0:08	0:08			62	110/70	68	2.1	5.1	2.6	
VALSALVA					58	110/70	63	2.0	4.9	2.4	
STANDING					70	110/70	77	2.1	5.2	2.3	
STAGE 1	2:59	2:59	2.70	10.00	93	110/70	102	3.0	5.5	3.7	4.80
STAGE 2	5:59	2:59	4.00	12.00	102	120/74	122	3.1	6.5	4.6	7.10
STAGE 3	8:59	2:59	5.40	14.00	116	128/78	148	3.4	5.9	3.8	10.00
STAGE 4	11:59	2:59	6.70	16.00	151	136/82	206	2.7	4.0	4.0	14.00
STAGE 5	12:44	0:44	8.00	18.00	161	140/84	225	3.5	3.6	3.8	15.47
PEAK EXERCISE	12:58	0:58			133	140/84	186	2.4	3.0	3.4	15.94
RECOVERY	2:59	2:59	0.00	0.00	93	130/78	120	1.9	2.7	1.5	
RECOVERY	5:59	5:59	0.00	0.00	88	126/76	110	0.7	1.8	0.6	

### RESULTS

Exercise Duration : 12:58 Minutes  
 Max Heart Rate : 161 bpm 88% of target heart rate 182 bpm  
 Max Blood Pressure : 140/84 mmHg  
 Max Work Load : 15.94 METS  
 Reason of Termination :

### IMPRESSIONS

*TMT IS Negative for RMI*

Cardiologist



Mr. SACHIN SHARMA  
I.D. : 274  
AGE/SEX : 38/M  
RECORDED : 9-3-2023 12:13

RATE : 64 BPM  
B.P. : 110/70 mmHg

# DR. CHARU KOHLI'S CLINIC

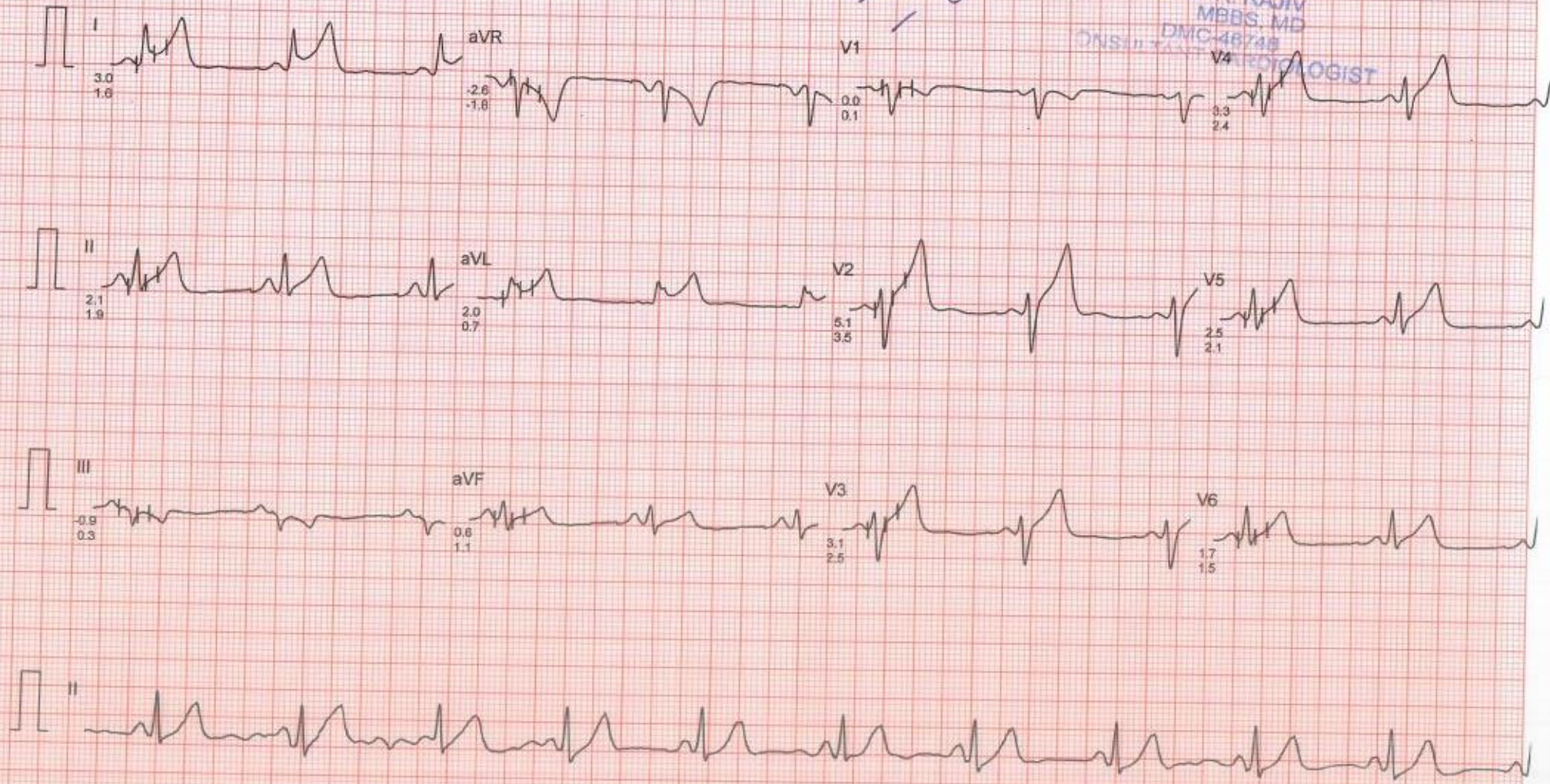
SUPINE  
PRETEST

ST @ 10mm/mV  
80ms PostJ

*ECG in ECG Sharma*  
*60*

LINKED MEDIAN

*Kapil*  
DR. D. R. RAJIV  
MBBS, MD  
DMC-48748  
CARDIOLOGIST





# DR. CHARU KOHLI'S CLINIC

Mr. SACHIN SHARMA  
I.D. : 274  
AGE/SEX : 38/M  
RECORDED : 9-3-2023 12:13

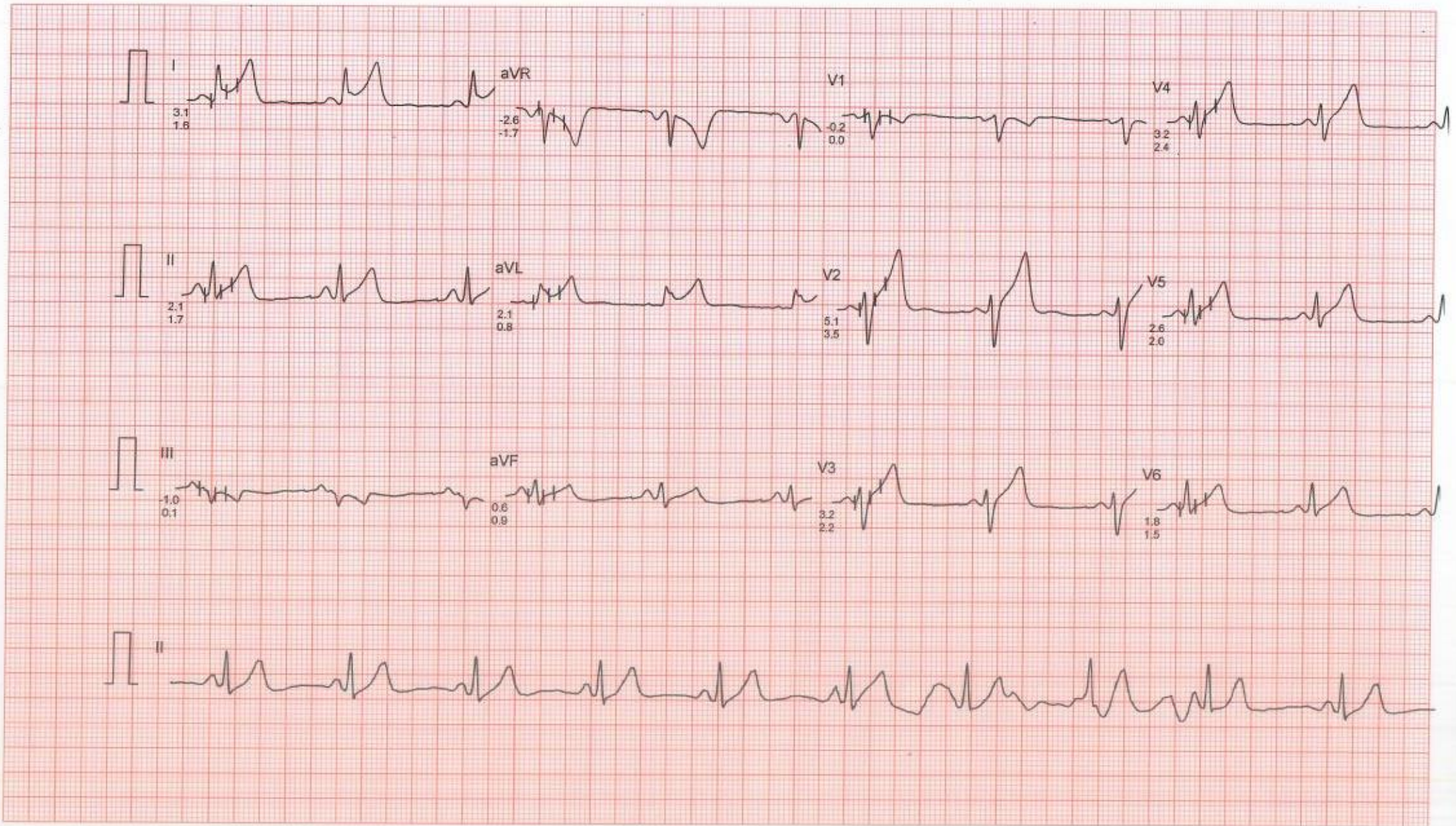
RATE : 62 BPM  
B.P. : 110/70 mmHg

HYPERVENTILATION  
PRETEST

ST @ 10mm/mV  
80ms PostJ

STAGE TIME : 0:08

LINKED MEDIAN



Filtered

Computer Corrected Baseline

25mm/sec 10mm/mV

CardiCom, INDIA Ph.:091-731-2620740, TeleFax:091-731-2431214



Mr. SACHIN SHARMA

I.D. : 274

AGE/SEX : 38/M

RECORDED : 9-3-2023 12:13

# DR. CHARU KOHLI'S CLINIC

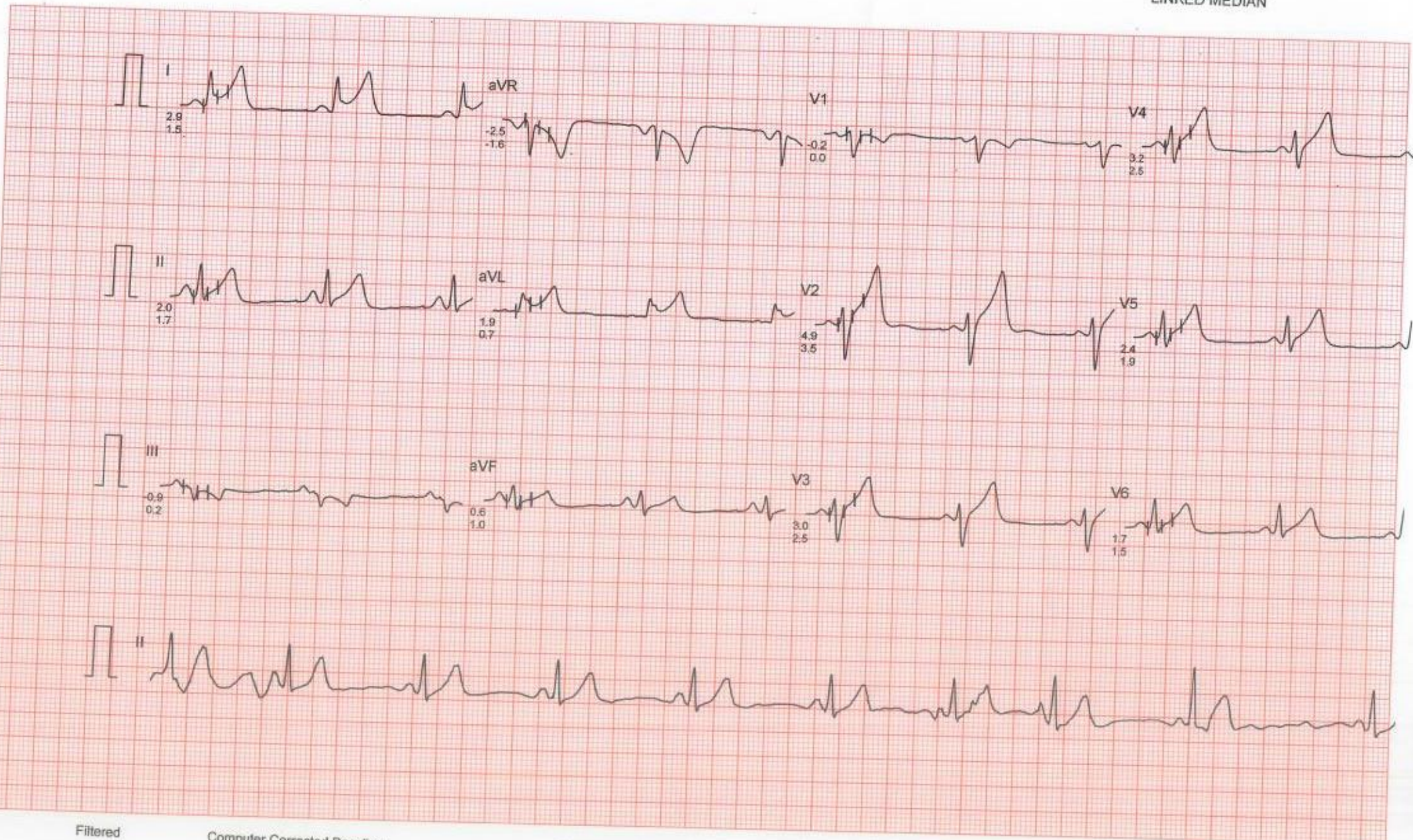
VALSALVA  
PRETEST

RATE : 58 BPM

B.P. : 110/70 mmHg

ST @ 10mm/mV  
80ms PostJ

LINKED MEDIAN



Filtered

Computer Corrected Baseline

25mm/sec 10mm/mV

CardiCom, INDIA Ph.:091-731-2620740,TeleFax:091-731-2431214



# DR. CHARU KOHLI'S CLINIC

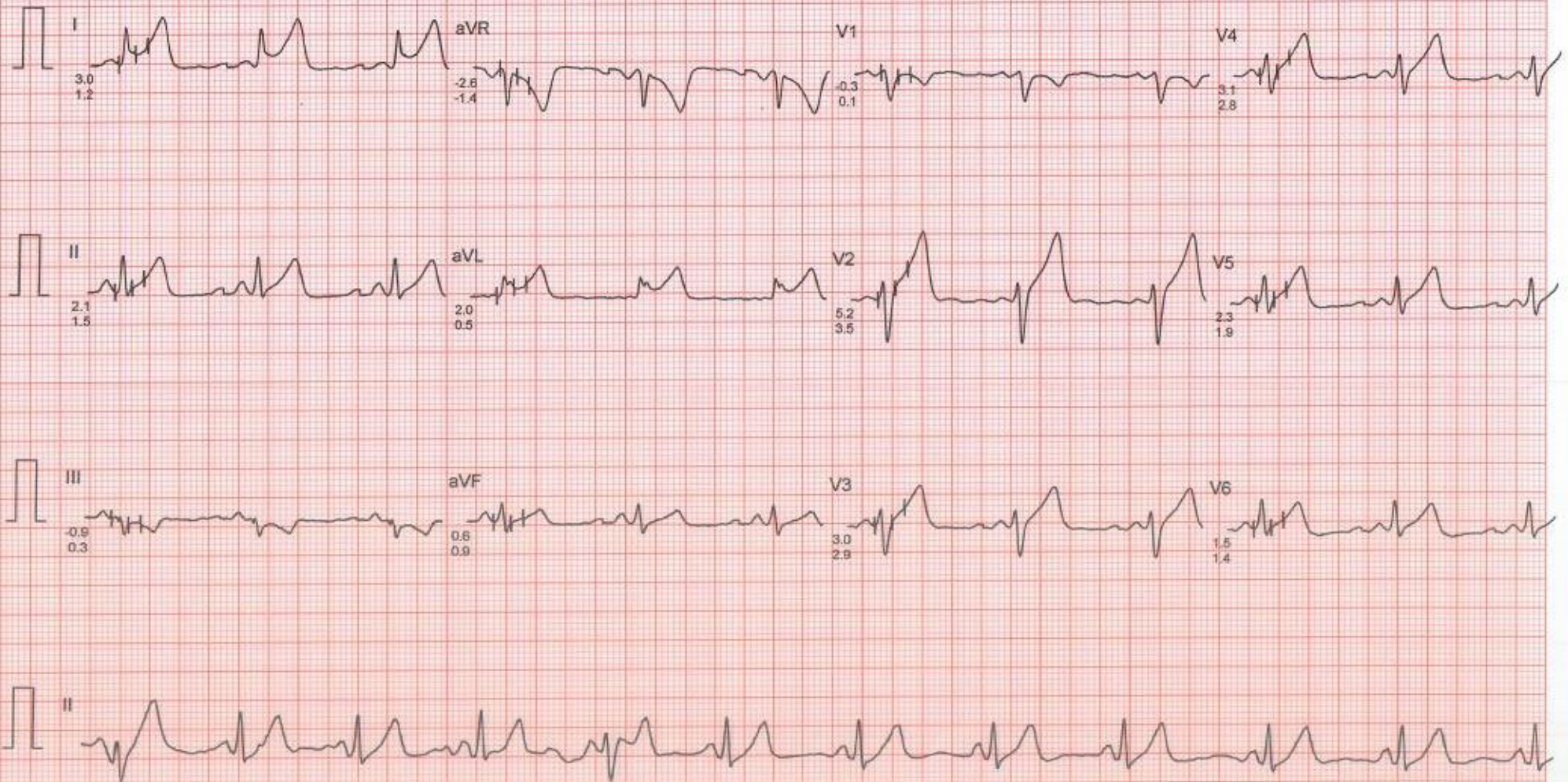
Mr. SACHIN SHARMA  
I.D. : 274  
AGE/SEX : 38/M  
RECORDED : 9-3-2023 12:13

RATE : 70 BPM  
B.P. : 110/70 mmHg

STANDING  
PRETEST

ST @ 10mm/mV  
80ms PostJ

LINKED MEDIAN





# DR. CHARU KOHLI'S CLINIC

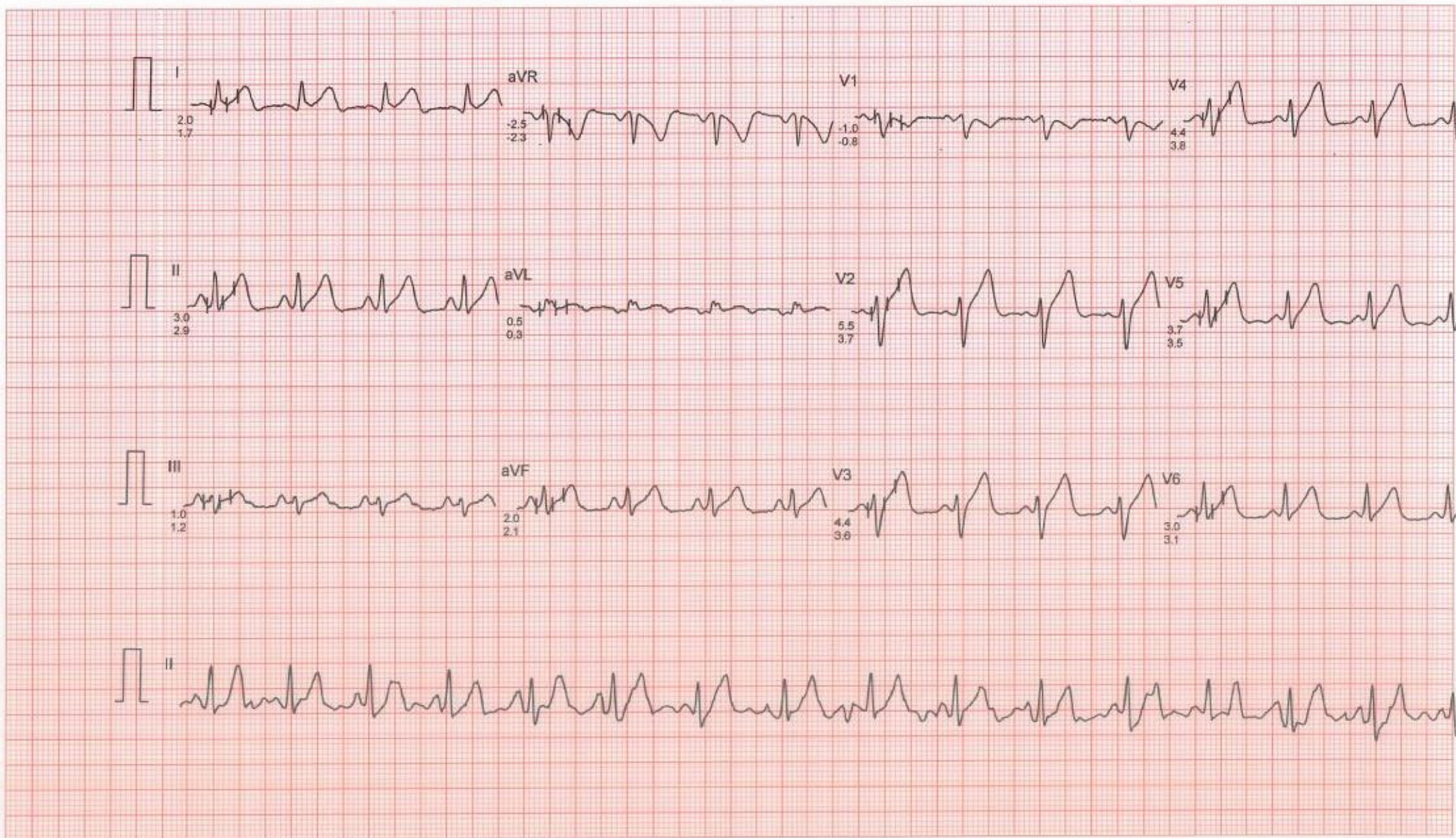
Mr. SACHIN SHARMA  
I.D. : 274  
AGESEX : 38/M  
RECORDED : 9-3-2023 12:13

RATE : 93 BPM  
B.P. : 110/70 mmHg

BRUCE  
EXERCISE 1  
PHASE TIME : 2:59  
STAGE TIME : 2:59

ST @ 10mm/mV  
80ms PostJ  
SPEED : 2.7 Km./Hr.  
GRADE : 10.0 %

LINKED MEDIAN





# DR. CHARU KOHLI'S CLINIC

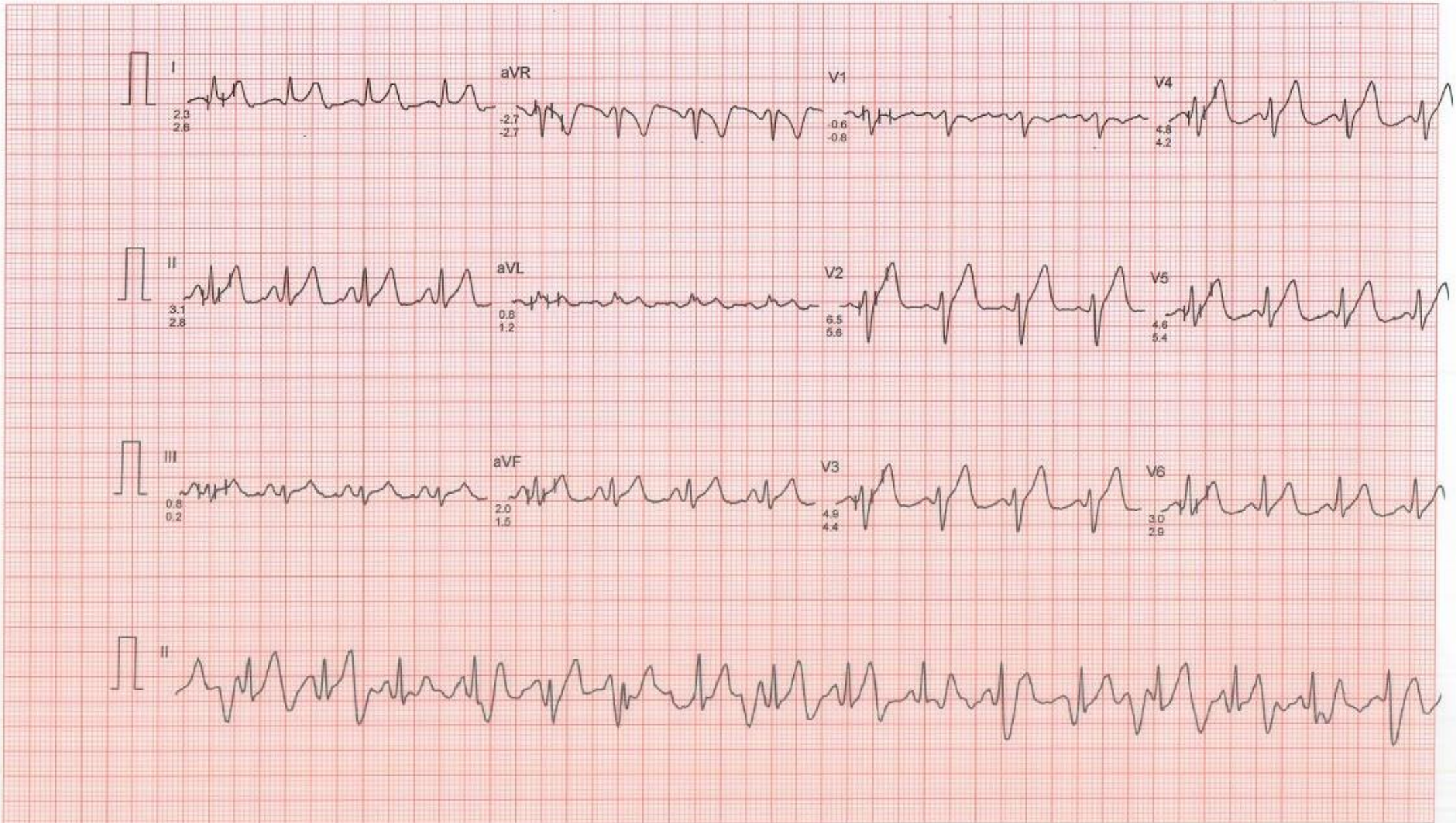
Mr. SACHIN SHARMA  
I.D. : 274  
AGE/SEX : 38/M  
RECORDED : 9- 3-2023 12:13

RATE : 102 BPM  
B.P. : 120/74 mmHg

BRUCE  
EXERCISE 2  
PHASE TIME : 5:59  
STAGE TIME : 2:59

ST @ 10mm/mV  
80ms PostJ  
SPEED : 4.0 Km./Hr.  
GRADE : 12.0 %

LINKED MEDIAN





# DR. CHARU KOHLI'S CLINIC

Mr. SACHIN SHARMA

I.D. : 274

AGE/SEX : 38/M

RECORDED : 9-3-2023 12:13

RATE : 116 BPM

B.P. : 128/78 mmHg

BRUCE

EXERCISE 3

PHASE TIME : 8:59

STAGE TIME : 2:59

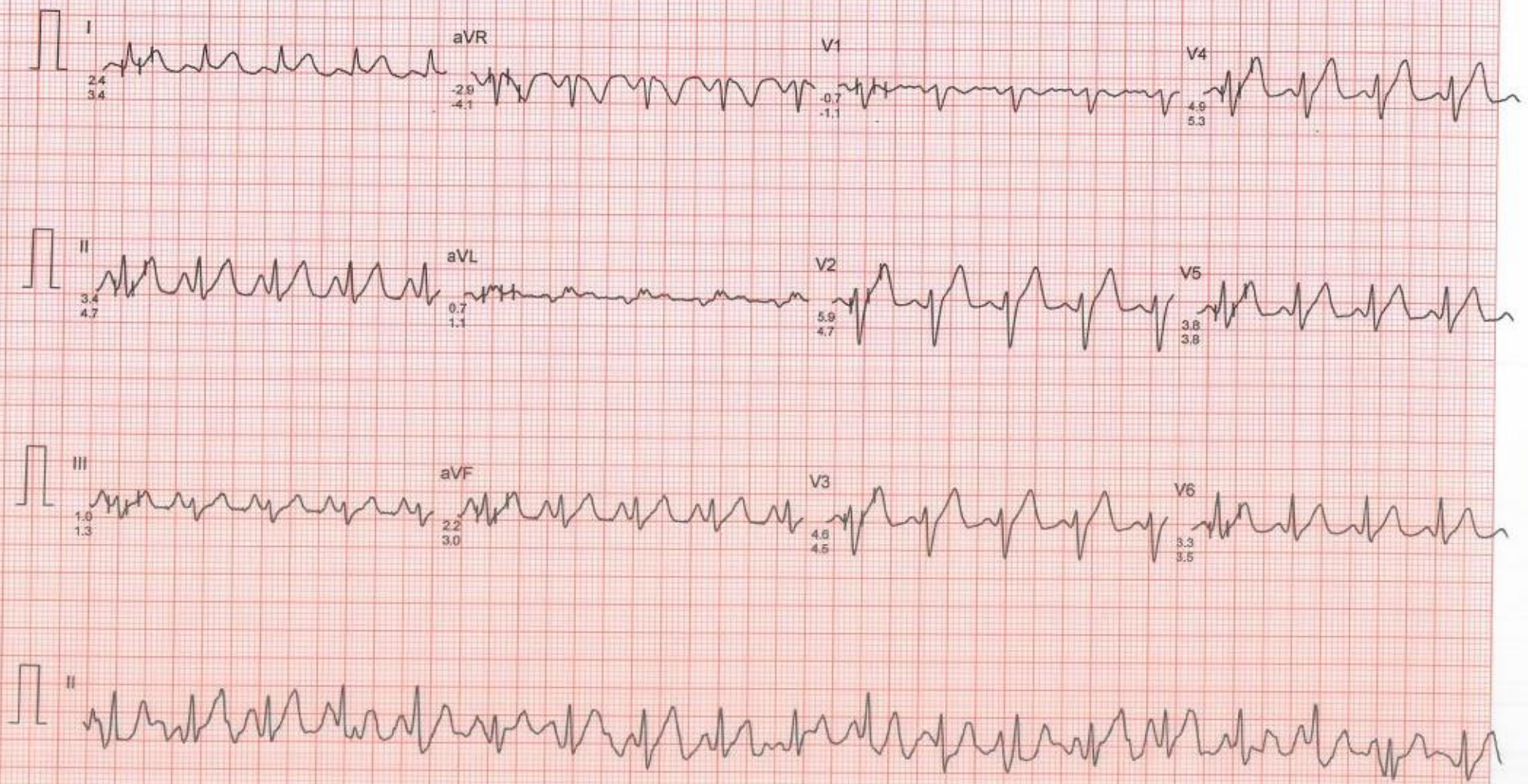
ST @ 10mm/mV

80ms PostJ

SPEED : 5.4 Km./Hr.

GRADE : 14.0 %

LINKED MEDIAN





# DR. CHARU KOHLI'S CLINIC

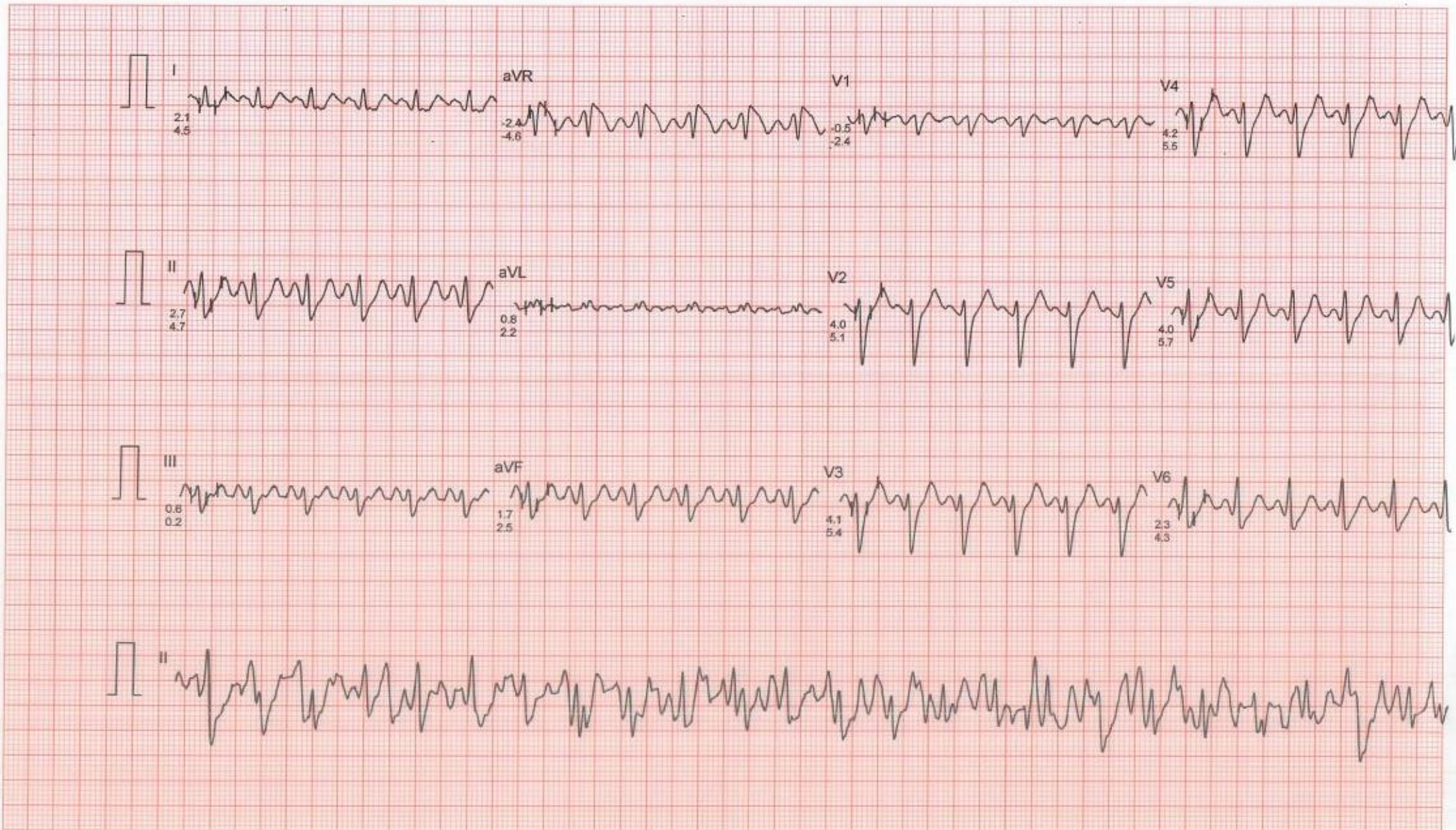
Mr. SACHIN SHARMA  
I.D. : 274  
AGE/SEX : 38/M  
RECORDED : 9-3-2023 12:13

RATE : 151 BPM  
B.P. : 136/82 mmHg

BRUCE  
EXERCISE 4  
PHASE TIME : 11:59  
STAGE TIME : 2:59

ST @ 10mm/mV  
80ms PostJ  
SPEED : 6.7 Km./Hr.  
GRADE : 16.0 %

LINKED MEDIAN





# DR. CHARU KOHLI'S CLINIC

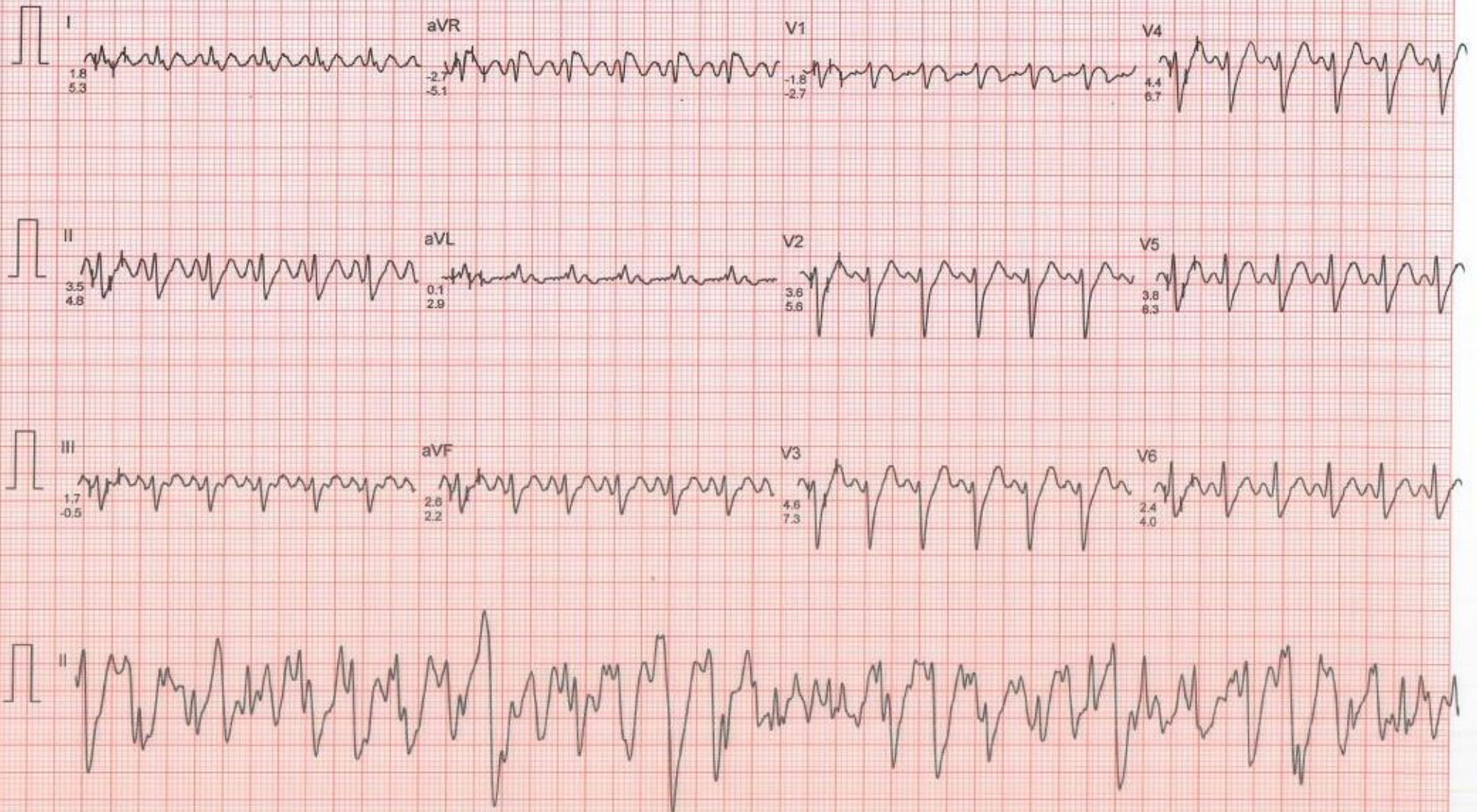Mr. SACHIN SHARMA  
I.D. : 274  
AGE/SEX : 38/M  
RECORDED : 9- 3-2023 12:13

RATE : 161 BPM  
B.P. : 140/84 mmHg

BRUCE  
EXERCISE 5  
PHASE TIME : 12:44  
STAGE TIME : 0:44

ST @ 10mm/mV  
80ms PostJ  
SPEED : 8.0 Km./Hr.  
GRADE : 18.0 %

LINKED MEDIAN





# DR. CHARU KOHLI'S CLINIC

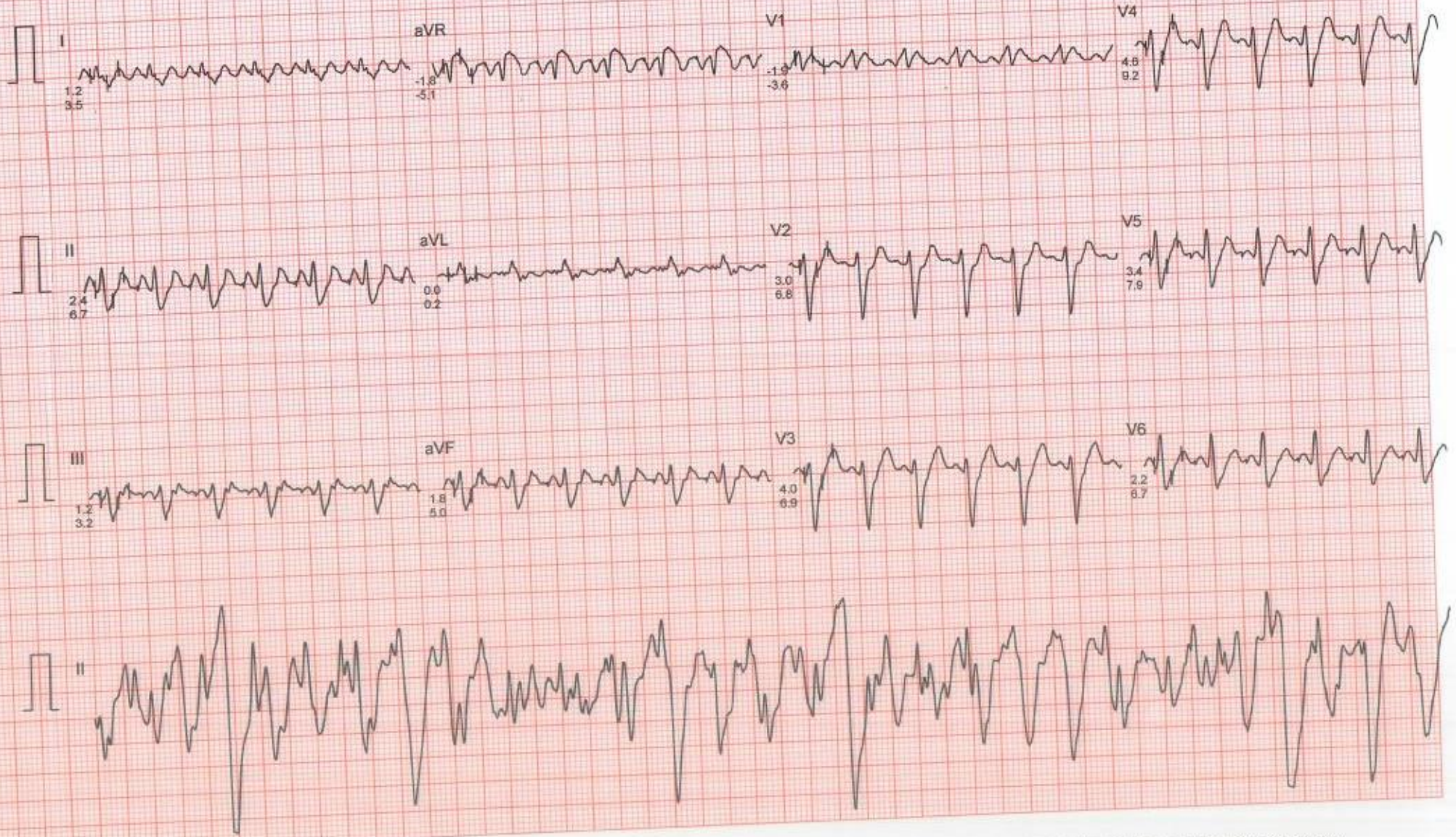Mr. SACHIN SHARMA  
I.D. : 274  
AGE/SEX : 38/M  
RECORDED : 9-3-2023 12:13

RATE : 133 BPM  
B.P. : 140/84 mmHg

BRUCE  
PEAK EXERCISE  
PHASE TIME : 12:58  
STAGE TIME : 0:58

ST @ 10mm/mV  
80ms PostJ  
SPEED : 8.0 Km./Hr.  
GRADE : 18.0 %

LINKED MEDIAN





# DR. CHARU KOHLI'S CLINIC

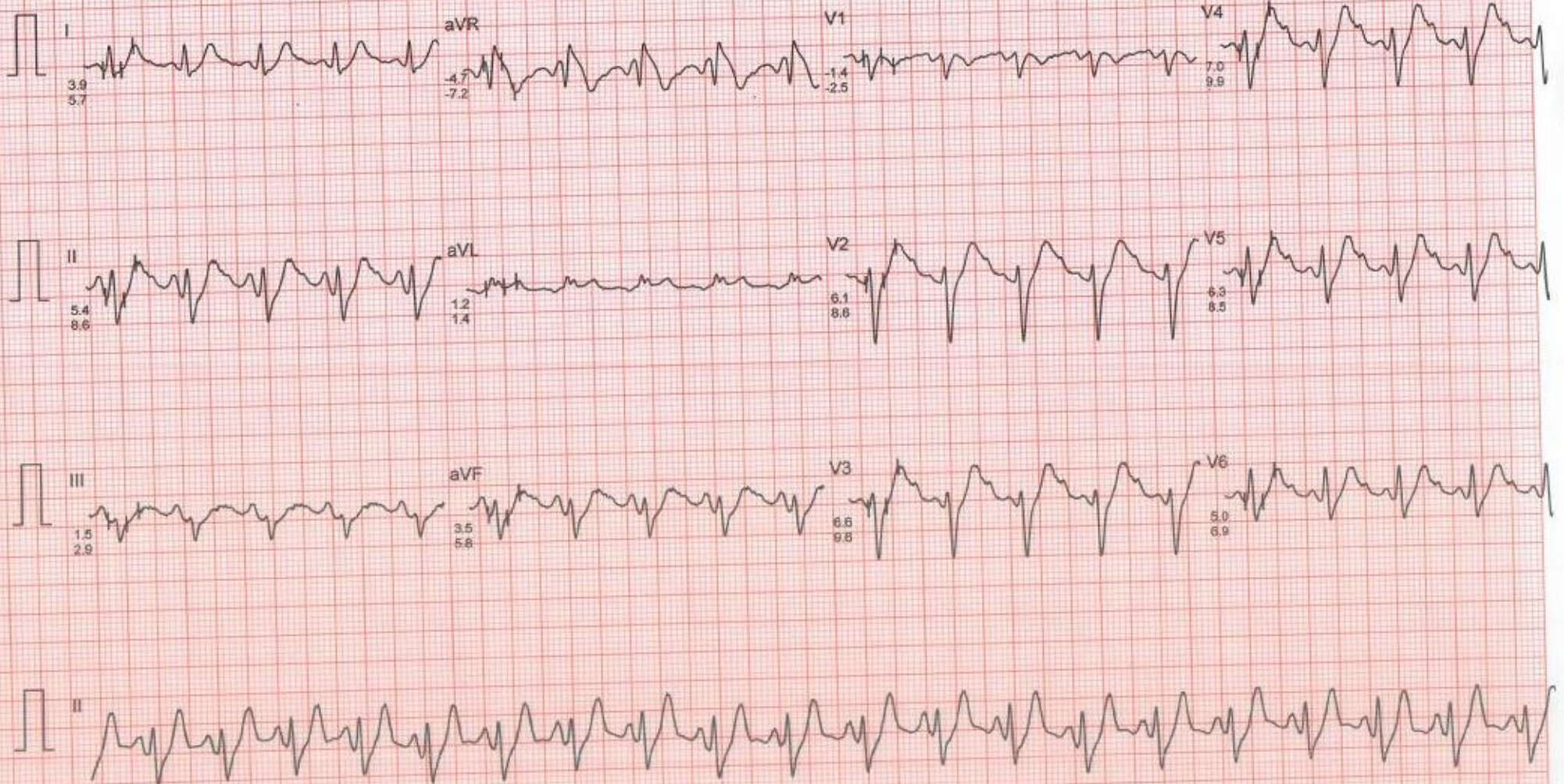
Mr. SACHIN SHARMA  
I.D. : 274  
AGE/SEX : 38/M  
RECORDED : 9- 3-2023 12:13

RATE : 121 BPM  
B.P. : 134/80 mmHg

BRUCE  
RECOVERY  
PHASE TIME : 0:59

ST @ 10mm/mV  
80ms PostJ  
SPEED : 0.0 Km./Hr.  
GRADE : 0.0 %

LINKED MEDIAN





# DR. CHARU KOHLI'S CLINIC

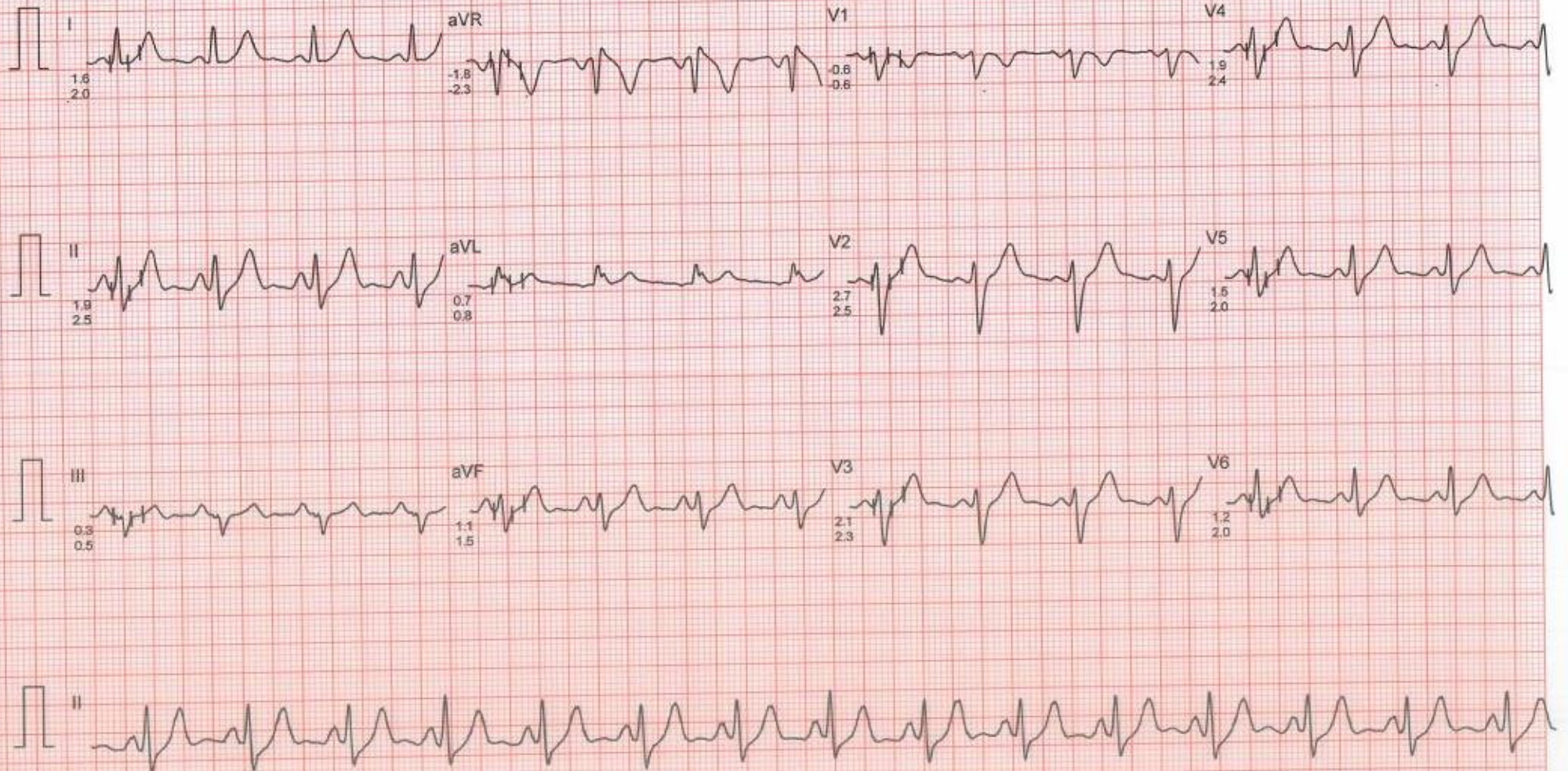
Mr. SACHIN SHARMA  
I.D. : 274  
AGE/SEX : 38/M  
RECORDED : 9-3-2023 12:13

RATE : 93 BPM  
B.P. : 130/78 mmHg

BRUCE  
RECOVERY  
PHASE TIME : 2:59

ST @ 10mm/mV  
80ms PostJ  
SPEED : 0.0 Km./Hr.  
GRADE : 0.0 %

LINKED MEDIAN





# DR. CHARU KOHLI'S CLINIC

Mr. SACHIN SHARMA

I.D. : 274

AGE/SEX : 38/M

RECORDED : 9-3-2023 12:13

RATE : 88 BPM

B.P. : 126/76 mmHg

BRUCE

RECOVERY

PHASE TIME : 5:59

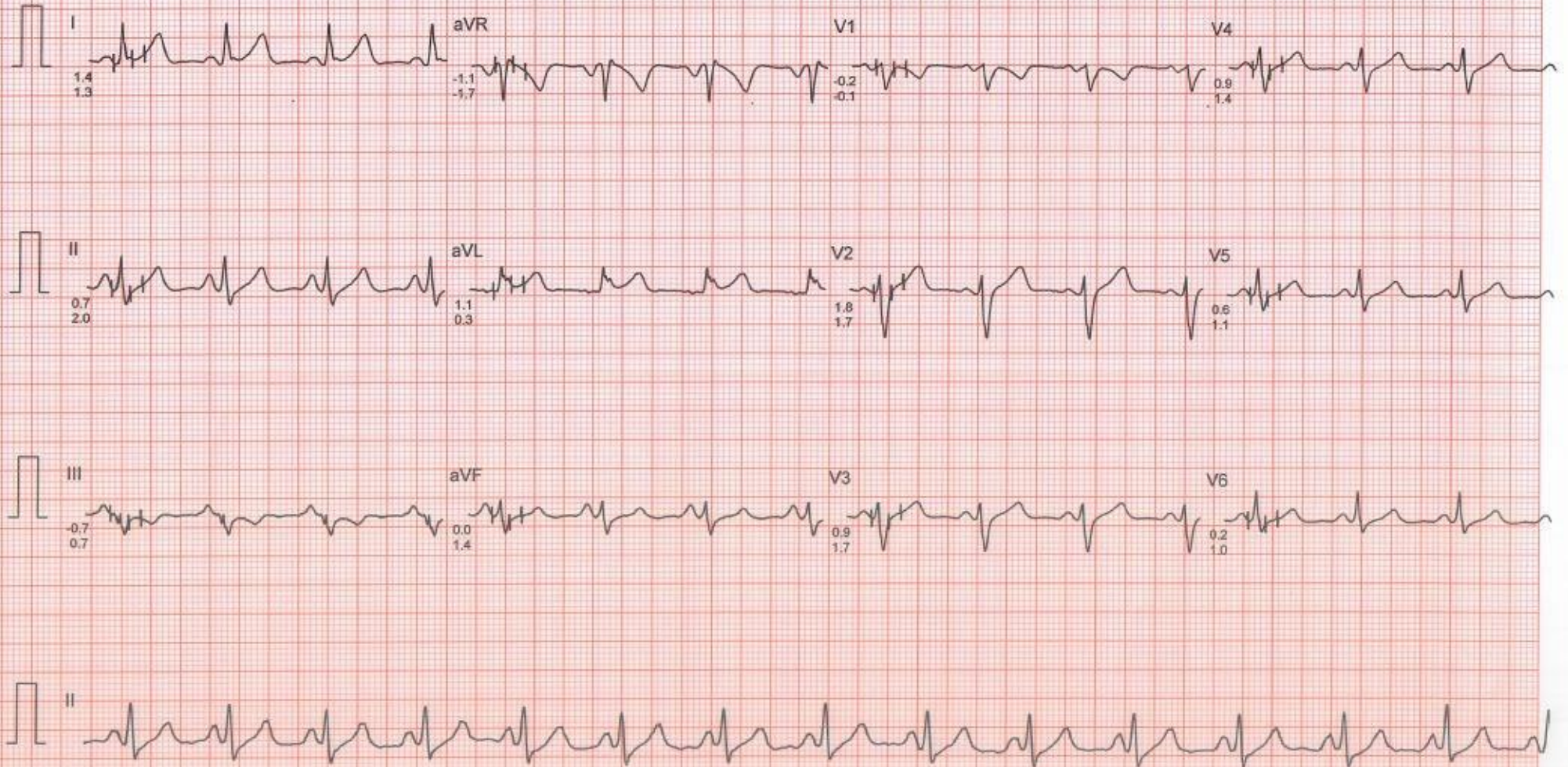
ST @ 10mm/mV

80ms PostJ

SPEED : 0.0 Km./Hr.

GRADE : 0.0 %

LINKED MEDIAN





**SACHIN SHARMA**

**9.3.2023**

## Transthoracic Screening Echo Report

### M - Mode / 2 - D Description :-

- ❖ Left Ventricle : It is normal sized. The wall does not show hypertrophy or thinning. No Regional Wall Motion Abnormality. Global LVEF  $\approx$  55- 60%.
- ❖ Left Atrium : It is normal sized.
- ❖ Right Atrium : It is normal sized.
- ❖ Right Ventricle : It is normal sized. RV systolic function is normal.
- ❖ Aortic Valve : Aortic cusps are normal.
- ❖ Mitral Valve : It opens normally.
- ❖ Tricuspid valve : It appears normal.
- ❖ Pulmonic Valve : It appears normal.
- ❖ Main Pulmonary artery & its branches: Appear normal.
- ❖ Pericardium : There is no pericardial effusion.
- ❖ Inter Atrial Septum : It is intact.
- ❖ Inter ventricular Septum : It is intact.

### Study done at HR of 64/ min.

1. No Regional wall motion abnormality. Global LVEF  $\approx$  55.60%.
2. Normal LV, LA, RA, RV chamber dimensions.
3. Normal RV systolic function present
4. No Intracardiac clot/vegetation/pericardial pathology seen.

*lll*

**IMPORTANT:** Owing to technical limitations ,in case of any error in the study ,the Doctor cannot be held responsible for claim of damages of any nature,and this report is not valid for any Medicolegal aspect.

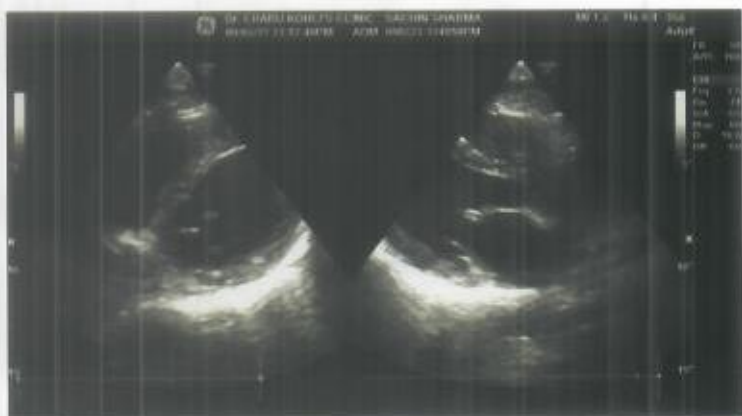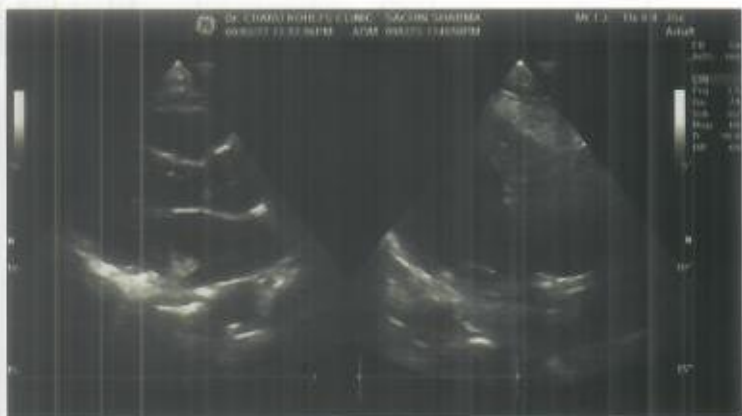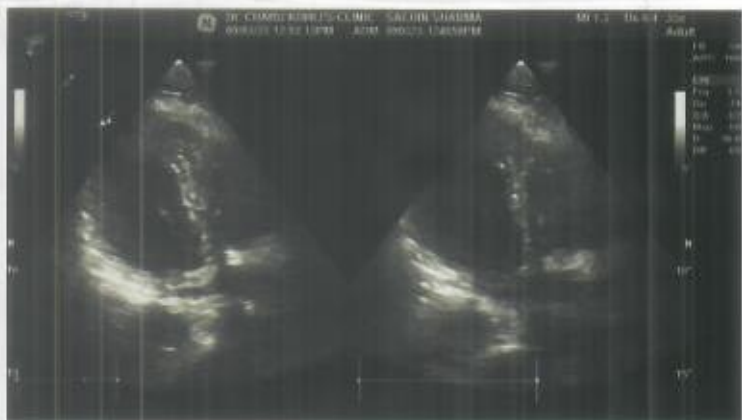Every modern technology has its own limitations , in case of discrepancy/difference in opinion advised-repeat scan/ second opinion

**At Your Home: Digital X-Ray, Blood Samples, ECG, PFT, HOLTER, EEG, ABG**

Occupational Health Services ■ Diagnostic & Preventive Health Assessment ■ Periodic Preventive Health Camps ■ Corporate Health Checks  
Test marked with \* are not in NABL Scope. / Tests marked with # are performed at outsourced laboratory.

**Ultrasound | Digital X Ray | DEXA | Mammography | Path Lab | ECHO | TMT | Healthchecks | PFT | Holter | Audiometry**







**NAME** : SACHIN SHARMA

**AGE/SEX** : 38Y/M

**DATE** : 09.03.2023

**X - RAY CHEST PA VIEW :**

Cardiac shadow is normal.  
Aorta is normal.  
Bilateral lung fields are clear.  
Both costophrenic angles are clear.  
Bilateral domes of diaphragm are normal.  
No bony injury noted.

**IMPRESSION:** Normal chest skiagram.



**DR. CHARU KOHLI**  
CONSULTANT RADIOLOGIST  
DMC - 8388

**DR. CHARU KOHLI'S CLINIC**  
C-234 DEFENCE COLONY, NEW DELHI-110024

**DR. CHARU KOHLI**  
MBBS, DMRD  
Consultant Radiologist

**IMPORTANT:** Owing to technical limitations in case of any error in the study, the Doctor cannot be held responsible for claim of damages of any nature and this report is not valid for any Medico-legal aspect.