



भारत सरकार  
Government of India



किरण रंजन  
Kiran Ranjan  
जन्म तिथि/DOB: 20/04/1976  
लिंग/ FEMALE

Issue Date: 12/07/2013

3622 7749 8835

VID : 9175 9270 6107 9967

मांरो आधार, मांरी ओज्ज्म



To,

The Coordinator,  
Mediwheel (Arcofemi Healthcare Limited)  
Helpline number: 011- 41195959

Dear Sir / Madam,

**Sub: Annual Health Checkup for the employees of Bank of Baroda**

This is to inform you that the following spouse of our employee wishes to avail the facility of Cashless Annual Health Checkup provided by you in terms of our agreement.

PARTICULARS OF HEALTH CHECK UP BENEFICIARY	
NAME	KIRAN RANJAN
DATE OF BIRTH	20-04-1976
PROPOSED DATE OF HEALTH CHECKUP FOR EMPLOYEE SPOUSE	11-02-2023
BOOKING REFERENCE NO.	22M92403100041240S
SPOUSE DETAILS	
EMPLOYEE NAME	MR. RANJAN RAM PUKAR
EMPLOYEE EC NO.	92403
EMPLOYEE DESIGNATION	CREDIT
EMPLOYEE PLACE OF WORK	CHHANI
EMPLOYEE BIRTHDATE	20-02-1972

This letter of approval / recommendation is valid if submitted along with copy of the Bank of Baroda employee id card. This approval is valid from **09-02-2023** till **31-03-2023**. The list of medical tests to be conducted is provided in the annexure to this letter. Please note that the said health checkup is a **cashless facility** as per our tie up arrangement. We request you to attend to the health checkup requirement of our employee's spouse and accord your top priority and best resources in this regard. The EC Number and the booking reference number as given in the above table shall be mentioned in the invoice, invariably.

We solicit your co-operation in this regard.

Yours faithfully,

Sd/-

**Chief General Manager**  
**HRM Department**  
**Bank of Baroda**

(Note: This is a computer generated letter. No Signature required. For any clarification, please contact Mediwheel (Arcofemi Healthcare Limited))



Bill of Supply (Interim Bill)



Patient ID : 20230208256

Age / Sex : 47y / F

Patient Name : KIRAN . RANJAN

Dr. Name : DR SAURABH JAIN

Referred By : self

City/Village : Vadodara

Class : Contract

PAN Card : AAQCS5566G

Visit No. : OPD20230224625(OPD)

Bill No. : OPD20230224625

Bill Date : N/A

Speciality : Internal Medicine

Company Name : Mediwheel Health Check Up

GSTIN : 24AAQCS5566G2ZW

Mobile No. : 9723638464

Expense Details	Qty	Rate	Gross Amount	Waive	Net Amount
<b>Visit Charge</b>					
11/02/2023 Physician First Consultation OPD	1.0	0.0	0.00	0.0	0.00
Ophthalmologist First Consultation OPD	1.0	0.0	0.00	0.0	0.00
Dentist First Consultation OPD	1.0	0.0	0.00	0.0	0.00
Ob & Gy Surgeon First Consultation OPD	1.0	0.0	0.00	0.0	0.00
<b>Visit Charge (Subtotal)</b>			0.0	0.0	0.00
<b>PATHOLOGY</b>					
11/02/2023 CBC, ESR	1.0			0.0	
Urine R/M	1.0			0.0	
STOOL EXAMINATION	1.0			0.0	
Blood Group	1.0			0.0	
HBA1C	1.0			0.0	
FBS & PPBS	1.0			0.0	
TFT (Thyroid Function Test)	1.0			0.0	
Lipid Profile	1.0			0.0	
RENAL FUNCTION TEST	1.0			0.0	
LFT (Liver Function Test)	1.0			0.0	
MediWheel Full Body Health Check-Up(Female Above 40)	1.0	3000.0	3000.00	0.0	3000.00
<b>PATHOLOGY (Subtotal)</b>			3000.0	0.0	3000.00
<b>Radiology</b>					
11/02/2023 X-RAY CHEST PA	1.0			0.0	
USG WHOLE ABDOMEN SCREENING	1.0			0.0	
Memography	1.0	0.0	0.00	0.0	0.00
X-RAY CHEST PA	1.0	0.0	0.00	0.0	0.00
USG WHOLE ABDOMEN SCREENING	1.0	0.0	0.00	0.0	0.00
<b>Radiology (Subtotal)</b>			0.0	0.0	0.00
<b>Non Invasive Cardiology</b>					
11/02/2023 ECHO COLOUR DOPPLER SCREENING	1.0	0.0	0.00	0.0	0.00
ECG Charge(OPD Base)	1.0	0.0	0.00	0.0	0.00
<b>Non Invasive Cardiology (Subtotal)</b>			0.0	0.0	0.00
<b>Total Bill Amount</b>					3000.00
<b>Net payable amount</b>					3000.00
<b>Bill Outstanding</b>					3000.00

Received With Thanks From KIRAN . RANJAN of Rs 0.0 /-  
(Rs Zero Only)

Printed By : (SAYATRI)  
For, Savita Hospital Live



## PHYSICIAN EXAMINATION

<b>Name :</b>	<b>KIRAN RANJAN</b>	<b>Age :</b>	<b>47/FEMALE</b>
<b>Reg.No :</b>	<b>20230208256</b>	<b>DOE :</b>	<b>11/02/2023</b>

### Physical Examination:

<b>Height:</b>	<b>147CM</b>	<b>Weight:</b>	<b>74 KG</b>	<b>PULSE:</b>	<b>100</b>	<b>Temperature:</b>	<b>NORMAL</b>
----------------	--------------	----------------	------------------	---------------	------------	---------------------	---------------

<b>BMI :</b>	<b>34.24</b>	<b>BP :</b>	<b>120/76</b>	<b>SPO2</b>	<b>97%</b>
--------------	--------------	-------------	---------------	-------------	------------

<b>Chief Complaint :</b>	<b>NAD</b>
<b>Past History :</b>	<b>NAD</b>
<b>General Examination :</b>	<b>NAD</b>
<b>Systemic Examination :</b>	<b>NAD</b>
<b>INVESTIGATION :</b>	<b>NAD</b>
<b>ADVICE :</b>	<b>ADD . TAB. SHELCAL HD 1-0-0 FOR 1 MONTH .</b>

**DR. SAURABH JAIN**





### Examination By Ophthalmologist

Name :	KIRAN RANJAN	Age :	47/FEMALE
Reg.No :	20230208256	DOE :	11/02/2023
Present Complaints :	NIL		
Medical History :	NIL		
Examination Of Eye :	NAD		
External Examination :	NAD	NAD	
Ati Seg Examination :	NAD	NAD	
Schiotz Tonometry IOP :	NAD	NAD	
Fundus :	NILL		
Without Glass	Distant Vision :		
	Near Vision :		
With Glass	Distant Vision : 6/6WITH +2.0DSPH	6/18WITH+1.0DSPH 1(NI)	
	Near Vision :		
Colour Vision (With Ishihara Chart) :	WNL		
Advice :	FUNDUS TO R/O ANY POST. SEGMENT PATHOLOGY		

DR CHETAN CHAUHAN





**EXAMINATION BY DENTAL**

<b>Name :</b>	<b>KIRAN RANJAN</b>	<b>Age/Sex:</b>	<b>47/FEMALE</b>									
<b>Reg No :</b>	<b>20230208256</b>	<b>DOE:</b>	<b>11/02/2023</b>									
<b>Presenting Complaint :</b>	NAD											
<b>Medical History :</b>	NAD											
<b>Examination :</b>	<b>ROOT PIECES IRT</b>	<table border="1"><tr><td></td><td>67</td></tr><tr><td></td><td></td></tr></table>		67			<b>FPD</b>	<table border="1"><tr><td></td><td>5678</td></tr><tr><td>765</td><td></td></tr></table>		5678	765	
	67											
	5678											
765												
	<b>MISSING</b>		<b>CALCULUS++</b>									
	<table border="1"><tr><td></td><td></td></tr><tr><td>6</td><td></td></tr></table>			6								
6												
<b>Impression :</b>	NAD											
<b>Advice :</b>	<b>EXTRACTION</b>	<table border="1"><tr><td></td><td>67</td></tr><tr><td></td><td></td></tr></table>		67								
	67											
	<b>FPP</b>	<table border="1"><tr><td></td><td>5678</td></tr><tr><td>765</td><td></td></tr></table>		5678	765							
	5678											
765												
	<b>SCALING</b>											

**DR RUSDA MALEK**





### Examination by GYNAECOLOGIST

Name:	KIRAN RANJAN	Age:	47/FEMALE
Reg.No:	20230208256	DOE:	11/02/2023

Presenting Complaint:	NO COMPLAINTS
-----------------------	---------------


Medical History :	
M/H:	MENOPAUSAL .,1-1/2 YEAR
O/H:	2 FTND -21 YEAR -FTGG (NOTL)1 MISSED ABORTION
OTHER:	K/C/O HYPOTHYROID

EXAMINATION:	
P/A:	SOFT PREVIOUS SURGICAL SCAR +
P/S:	NAD
P/V:	NAD

IMPRESSION:	NILL GYNEC
ADVICE:	MAMMOGRAPHY ,PAP SMEAR EVERY 2-3 YEAR

DR SWARSHAH



<b>Patient Name :</b>	Kiran . Ranjan	<b>Sample No. :</b>	20230214580 
<b>Patient ID :</b>	20230208256	<b>Visit No. :</b>	OPD20230224625
<b>Age / Sex :</b>	47y/Female	<b>Coll. Date :</b>	11/02/2023 08:29
<b>Consultant :</b>	DR SAURABH JAIN	<b>S. Coll. Date :</b>	11/02/2023 10:07
<b>Ward :</b>	-	<b>Report Date :</b>	11/02/2023 13:18

### CBC, ESR

Investigation	Result	Normal Value
Hemoglobin :	11.9 gm/dl [L]	12.5 to 16.0 gm/dl
P.C.V. :	36.6 % [L]	37.0 to 47.0 %
M.C.V. :	90.1 fL	78 to 100 fL
M.C.H. :	29.3 pg	27 to 31 pg
M.C.H.C. :	32.5 g/dl	32 to 36 g/dl
RDW :	12.3 %	11.5 to 14.0 %
RBC Count :	4.06 X 10 <sup>6</sup> / cumm [L]	4.2 to 5.4 X 10 <sup>6</sup> / cumm
Polymorphs :	66 %	38 to 70 %
Lymphocytes :	30 %	15 to 48 %
Eosinophils :	2 %	0 to 6 %
Monocytes :	2 % [L]	3 to 11 %
Basophils :	0 %	0.0 to 1.0 %
Total :	100	< 100 > 100
WBC Count :	7700 /cmm	4000 to 10000 /cmm
Platelets Count :	202000 /cmm	1,50,000 to 4,50,000 /cmm
ESR - After One Hour :	29 mm/hr [H]	1 to 20 mm/hr



**Dr. Mehul Desai**  
**M.B.D.C.P**  
**Reg.No.G-9521**





<b>Patient Name :</b> Kiran . Ranjan	<b>Sample No. :</b> 20230214580
<b>Patient ID :</b> 20230208256	
<b>Age / Sex :</b> 47y/Female	<b>Visit No. :</b> OPD20230224625
<b>Consultant :</b> DR SAURABH JAIN	<b>Coll. Date :</b> 11/02/2023 08:29
<b>Ward :</b> -	<b>S. Coll. Date :</b> 11/02/2023 10:07
	<b>Report Date :</b> 11/02/2023 13:18

### Blood Group

Investigation	Result	Normal Value
<b>BLOOD GROUP :</b>		
<b>ABO</b>	O	
<b>Rh</b>	Negative	

### HBA1C

Investigation	Result	Normal Value
Glycosylated Hb :	<u>6.3</u> % [H]	Near Normal Glycemia : 6 to 7 Excellent Control : 7 to 8 Good Control : 8 to 9 Fair Control : 9 to 10 Poor Control : > 10
Average Plasma Glucose of Last 3 Months :	134.11	

### FBS & PPBS

Investigation	Result	Normal Value
Blood Sugar (FBS) :	105 mg/dl	74 - 100 mg/dl
Urine Sugar ( FUS ) :	Nil	
Blood Sugar (PP2BS) :	102 mg/dl	70 to 120 mg/dl
Urine Sugar ( PP2US ) :	Nil	

**Dr.Mehul Desai**  
**M.B.D.C.P**  
**Reg.No.G-9521**



<b>Patient Name :</b>	Kiran . Ranjan	<b>Sample No. :</b>	20230214580 
<b>Patient ID :</b>	20230208256	<b>Visit No. :</b>	OPD20230224625
<b>Age / Sex :</b>	47y/Female	<b>Coll. Date :</b>	11/02/2023 08:29
<b>Consultant :</b>	DR SAURABH JAIN	<b>S. Coll. Date :</b>	11/02/2023 10:07
<b>Ward :</b>	-	<b>Report Date :</b>	11/02/2023 13:18


### LFT (Liver Function Test)

Investigation	Result	Normal Value
Total Bilirubin :	0.4 mg/dl	0.2 to 1.0 mg/dl
Direct Bilirubin :	0.2 mg/dl	0.0 to 0.2 mg/dl
Indirect Bilirubin :	0.2 mg/dl	0.0 to 0.8 mg/dl
AST (SGOT) :	20 U/L	5 to 34 U/L
ALT (SGPT) :	23 U/L	0 to 55 U/L
Total Protein (TP) :	6.8 g/dL	6.4 to 8.3, g/dl
Albumin (ALB) :	3.8 g/dl	3.5 to 5.2 g/dl
Globulin :	3 g/dl	2.3 to 3.5 g/dl
A/G Ratio :	1.27	
Alkaline Phosphatase (ALP) :	162 U/L [H]	40 to 150 U/L
GAMMA GT. :	16 U/L	7 to 35 U/L



**Dr. Mehul Desai**  
**M.B.D.C.P**  
**Reg.No.G-9521**



<b>Patient Name :</b>	Kiran . Ranjan	<b>Sample No. :</b>	20230214580 
<b>Patient ID :</b>	20230208256	<b>Visit No. :</b>	OPD20230224625
<b>Age / Sex :</b>	47y/Female	<b>Coll. Date :</b>	11/02/2023 08:29
<b>Consultant :</b>	DR SAURABH JAIN	<b>S. Coll. Date :</b>	11/02/2023 10:07
<b>Ward :</b>	-	<b>Report Date :</b>	11/02/2023 13:18

### Lipid Profile

Investigation	Result	Normal Value
Sample :	Fasting	
Sample Type :	Normal	
Cholesterol (Chol) :	185 mg/dl	Low risk : < 200 Moderate risk : 200 - 239 High risk : > or = 240
Triglyceride :	95 mg/dl	Normal : < 200.0 High : 200 - 499 Very High : > or = 500
HDL Cholesterol :	59 mg/dl	Low risk: >or = 60 mg/dL High risk : Up to 35 mg/dL
LDL :	<b>107 mg/dl [L]</b>	131.0 to 159.0(N) < 130.0(L) > 159.0(H)
VLDL :	19 mg/dl	Up to 0 to 34 mg/dl
LDL/HDL Ratio :	1.81	Low risk : 0.5 to 3.0 Moderate risk : 3.0 to 6.0 Elevted level high > 6.0
Total Chol / HDL Ratio :	3.14	Low Risk : 3.3 to 4.4 Average Risk : 4.4 to 7.1 Moderate Risk : 7.1 to 11.0 High Risk : > 11.0
Total Lipids :	639 mg/dl	400 to 700 mg/dl

**Note :-** Lipemic samples give high triglyceride value and falsely low LDL value.



**Dr. Mehul Desai**  
**M.B.D.C.P**  
**Reg.No.G-9521**



**TEST REPORT**

<b>Name</b> : KIRAN RANJAN	<b>Acc. ID</b> : 231002209
<b>Age/Sex</b> : 47 Years / Female	<b>Birthdate</b> :
<b>Refd. By</b> : SAVITA SUPERSPECIALITY HOSPITAL	<b>Status</b> : Final
<b>Sample</b> : Serum (Blood in Plain)	<b>PassportNo.</b> :
<b>Client Details</b> : SAVITA SUPERSPECIALITY HOSPITAL	<b>Mobile</b> :
	<b>Regd. Dt</b> : 11-Feb-2023 01:08 PM
	<b>Coll Dt. TM.</b> : 11-Feb-2023 12:00 PM
	<b>Recd. Dt. Tm.</b> : 11-Feb-2023 01:08 PM
	<b>Report Dt. Tm.</b> : 11-Feb-2023 02:25 PM

**IMMUNOLOGY**

Test Name	Result	Unit	Biological Ref. Interval
-----------	--------	------	--------------------------

**THYROID FUNCTION TEST**

<b>T3 (Triiodothyronine)</b> <small>CHEMILUMINESCENT MICROPARTICLE IMMUNOASSAY</small>	1.23	ng/mL	0.97 - 1.69
<b>T4 (Thyroxine)</b> <small>CHEMILUMINESCENT MICROPARTICLE IMMUNOASSAY</small>	9.36	µg/dL	5.5 - 11.0
<b>TSH</b> <small>CHEMILUMINESCENT MICROPARTICLE IMMUNOASSAY</small>	3.764	µIU/ml	Infants (1-23 months):- 0.5885-6.880 Children (2-12 years):- 0.7291-4.402 Adolescents(13-21 years):- 0.4557-4.160 Adults (>=22 years):- 0.4001-4.049 Pregnant:- (1st trimester):- 0.1298-3.12 (2nd trimester):- 0.2749-2.652 (3rd trimester):- 0.3127-2.947

CHEMILUMINESCENT MICROPARTICLE IMMUNOASSAY

----- End Of Report -----


This is an Electronically Authenticated Report.

*Kinjal*  
**Dr. Kinjal Patel**  
M. D. PATHOLOGY  
GMC No. G-33123

**Verified By**  
**Auto**

**Dr. VIRAL A. PATEL**  
M. D. PATHOLOGY  
GMC No. G-22658



<b>Patient Name :</b> Kiran . Ranjan	<b>Sample No. :</b> 20230214580 
<b>Patient ID :</b> 20230208256	<b>Visit No. :</b> OPD20230224625
<b>Age / Sex :</b> 47y/Female	<b>Coll. Date :</b> 11/02/2023 08:29
<b>Consultant :</b> DR SAURABH JAIN	<b>S. Coll. Date :</b> 11/02/2023 10:07
<b>Ward :</b> -	<b>Report Date :</b> 11/02/2023 15:15

### RENAL FUNCTION TEST

Investigation	Result	Normal Value
Creatinine :	0.7 mg/dl	0.6 - 1.4 mg/dl
Urea :	24 mg/ dl	13 - 45 mg/dl
Uric Acid :	5 mg/dl	3.5 - 7.2 mg/dl
Calcium :	7.3 mg/dl	8.5 - 10.5
Phosphorus :	4.1 mg/dl	1.5 - 6.8



**Dr.Mehul Desai**  
**M.B.D.C.P**  
**Reg.No.G-9521**



**Patient Name :** Kiran . Ranjan

**Sample No. :** 20230214580



**Patient ID :** 20230208256

**Visit No. :** OPD20230224625

**Age / Sex :** 47y/Female

**Coll. Date :** 11/02/2023 08:29

**Consultant :** DR SAURABH JAIN

**S. Coll. Date :** 11/02/2023 10:07

**Ward :** -

**Report Date :** 11/02/2023 13:18

### Urine R/M

Investigation	Result	Normal Value
Quantity - :	20 ml	
Colour - :	Pale Yellow	
Reaction (pH) :	5.0	4.6-8.0
Turbidity :	Clear	
Deposit :	Absent	Absent
Sp.Gravity :	1.025	1.005-1.010
Protein :	Absent	Absent
Glucose :	Absent	Absent
Bile Salts :	Absent	Absent
Bile pigments :	Absent	Absent
Ketones :	Absent	Absent
Urobilinogen :	Absent	
Blood :	<u>Present (+++)</u>	Absent
Pus Cells :	1-2 /hpf	0-5/hpf
Red Blood Cells :	<u>10-14 /hpf</u>	Absent
Epithelial Cells :	1-3 /hpf	

**Dr.Mehul Desai**  
**M.B.D.C.P**  
**Reg.No.G-9521**

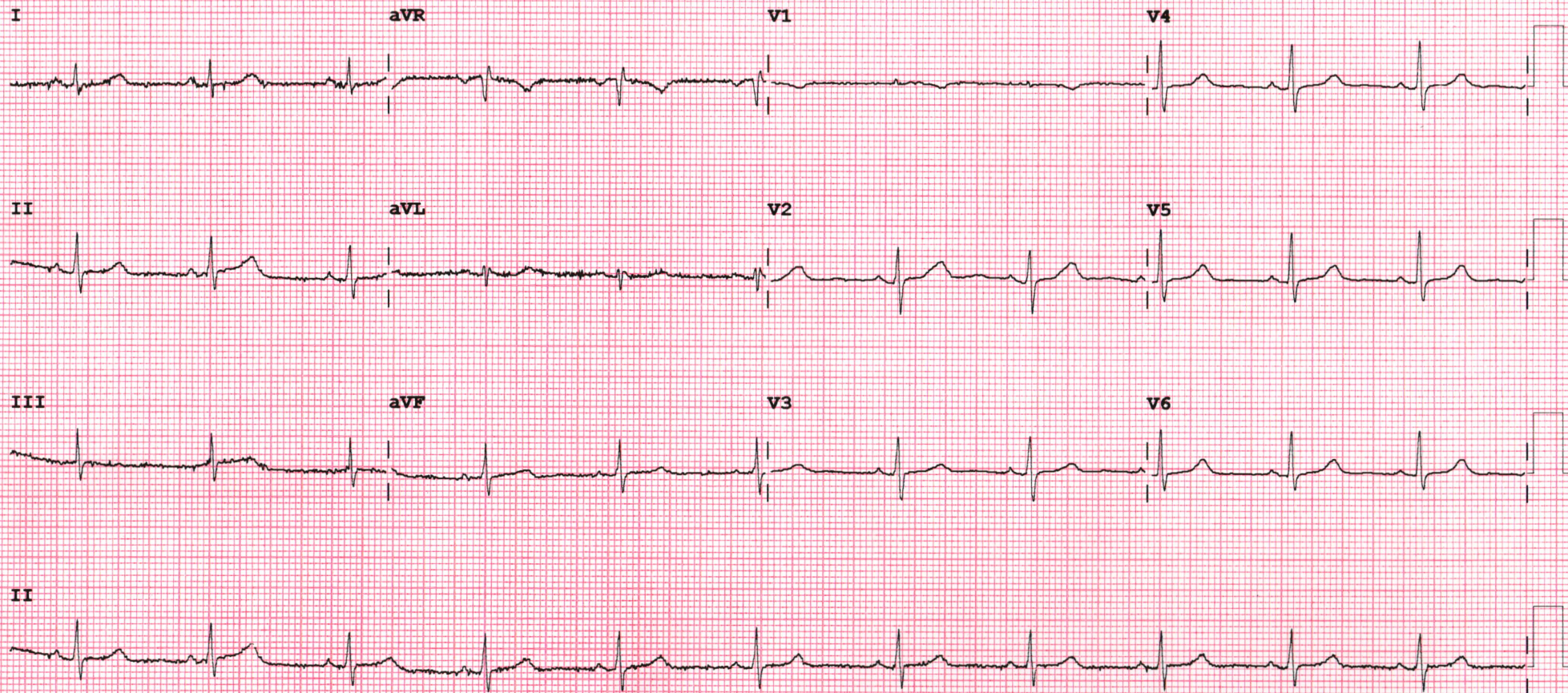
Rate 68

PR 144  
QRSD 76  
QT 392  
QTc 417

--AXIS--

P 6  
QRS 51  
T 25

12 Lead; Standard Placement



Device:

Speed: 25 mm/sec

Limb: 10 mm/mV

Chest: 10.0 mm/mV

F 50~ 0.50-150 Hz W

PH09

P?



**2D-ECHOCARDIOGRAPHY AND COLOR DOPPLER REPORT**

**NAME: KIRAN RANJAN**

**AGE/SEX: 47 YRS/ FEMALE**

**DATE: 11/02/2023**

**REF BY: HCP**

- NORMAL LV SIZE WITH NORMAL LV SYSTOLIC FUNCTION. LVEF = 60%.
- NO RWMA PRESENT AT REST.
- NO LV DIASTOLIC DYSFUNCTION.
- NORMAL MITRAL VALVE, NO MR. NO MS.
- NORMAL TRICUSPID AORTIC VALVE, NO AR. NO AS.
- TRIVIAL TR . NO PAH.
- NORMAL LA,RA, RV SIZE WITH NORMAL RV SYSTOLIC FUNCTION
- NORMAL MPA, RPA & LPA.
- INTACT IAS & IVS.
- NO E/O INTRACARDIAC CLOT/VEGETATION/PE.
- NORMAL SIZE OF IVC. NORMAL PERICARDIUM.

**DIMENSIONS: LA:28mm, AO: 25mm, LV: IVS/PW - 9/9 mm, LV chamber S/D- 38/29mm**

**CONCLUSION:**

- NORMAL LV/RV SIZE AND SYSTOLIC FUNCTION (LVEF = 60%)
- NO LV DIASTOLIC DYSFUNCTION
- TRIVIAL TR, NO PULMONARY HYPERTENSION

**DR.NIRAV BHALANI**  
[CARDIOLOGIST]

**DR.ARVIND SHARMA**  
[CARDIOLOGIST]

**DR. KASHYAP PATEL**  
[CARDIOLOGIST]

**DR PRUTHVIRAJ PUWAR**  
[CARDIOLOGIST]







**Saturday, February 11, 2023**

**KIRAN RANJAN**

**47 YEARS/FEMALE**

**ULTRASONOGRAPHY OF ABDOMEN AND PELVIS**

Liver shows normal in size and echotexture. No mass lesion detected.  
PV, CBD and intrahepatic biliary radicals shows no dilatation.

The gall bladder is contracted and shows a hyperechoic focus of size 14 mm, with posterior acoustic shadowing suggest p/o cholelithiasis.

Spleen appears normal in size and echotexture. No evidence of focal lesion.

Pancreas appears normal in size and echotexture. No evidence of focal lesion.

Both kidneys show normal size, position and cortical echogenicity.

Right kidney measures 8.0 cm and Left kidney measures 10.2 cm.

Corticomedullary differentiation is preserved bilaterally.

**No calculus or hydronephrosis on either side.**

The urinary bladder is distended and appears normal.

No evidence of Lymphadenopathy or ascites seen.

No e/o dilated bowel loops seen.

**CONCLUSION:**

- **CHOLELITHIASIS**



**DR. CHETNA DUHAN, M.D**

**CONSULTANT RADIOLOGIST**



**Saturday, February 11, 2023**

**KIRAN RANJAN**

**47 YEARS/FEMALE**

**ULTRASONOGRAPHY OF ABDOMEN AND PELVIS**

**Liver** shows normal in size and echotexture. No mass lesion detected.  
PV, CBD and intrahepatic biliary radicals shows no dilatation.

**The gall bladder is contracted and shows a hyperechoic focus of size 14 mm, with posterior acoustic shadowing suggest p/o cholelithiasis.**

**Spleen** appears normal in size and echotexture. No evidence of focal lesion.

**Pancreas** appears normal in size and echotexture. No evidence of focal lesion.

Both kidneys show normal size, position and cortical echogenicity.

Right kidney measures 8.0 cm and Left kidney measures 10.2 cm.

Corticomedullary differentiation is preserved bilaterally.

**No calculus or hydronephrosis on either side.**

**The urinary bladder** is distended and appears normal.

No evidence of Lymphadenopathy or ascites seen.

No e/o dilated bowel loops seen.

**CONCLUSION:**

- **CHOLELITHIASIS**



**DR. CHETNA DUHAN, M.D**

**CONSULTANT RADIOLOGIST**



**11/02/2023**

**KIRAN RANJAN**

**47 YEARS/FEMALE**

**CHEST X RAY PA VIEW**

**MILD CARDIOMEGALY IS NOTED.**

Both the lung fields appear normal.

Both costophrenic angles appear clear.

Both hila appears normal.

Mediastinum and aorta appear normal.

Bony thorax appears normal.

No evidence of free gas seen under dome of diaphragm.



**DR. CHETNA DUHAN, M.D**  
**CONSULTANT RADIOLOGIST**