

 भारत सरकार  
GOVERNMENT OF INDIA




चन्दन शर्मा  
Chandan Sharma  
जन्म वर्ष / Year of Birth : 1989  
पुरुष / Male




4846 2107 3682


**आधार — आम आदमी का अधिकार**

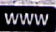
 भारतीय विधिगत पहचान प्राधिकरण  
GOVERNMENT OF INDIA


पता: S/O महावीर प्रसाद शर्मा,  
झाझारपुर भवन, प्रथम फ्लोर चूड़ी मार्केट,  
हिंदू पाडा, अलवर, राजस्थान, 301001

Address: S/O Mahaveer Prasad  
Sharma, Jhajharpur Bhawan, 1st  
Floor Churi Market, Hindu Para,  
Alwar, Alwar, Rajasthan, 301001

 1947  
1800 180 1947

 help@uidai.gov.in

 www.uidai.gov.in

 P.O. Box No.1947,  
Bengaluru-560 001

चन्दन शर्मा



# THAREJA NURSING HOME



DIGITAL X-RAY, OPG, COMPUTERISED ECG & EEG, DIAGNOSTIC  
LABORATORY EQUIPPED WITH COMPUTERISED AUTO ANALYZER & CBC

1, Ram Kuteer, Company Bagh Road, ALWAR - 301001 (Raj.) Ph: 0144-2700184, 2331842

PROPOSAL NO. PKG1000227

Patient Name MR CHANDAN SHARMA

Ref. By Dr. M. N. THAREJA

Date 23/04/2022

Age 32 Yrs.

Sex M

Details of packages		Patients report	Units	Normal value
HB		12.7	gm%	M-13.5-18, F-11.5-16.5
TRBC		4.34	million /cu mm	M-4.0-5.5, F-3.9-5.6
TWBC		5200	cu mm	4000-11000
DLC	Polymorphs	65	%	42-75
	Lymphocytes	30	%	20-50
	Eosinophil	05	%	1-6
ESR		03	mm 1 <sup>st</sup> Hr.	M-0-9, F-0-20
Platelets		168000	Lack / cu mm	1.5-4
PCV		35.8	%	37-54
MCV		82.5	Cubicmicrons	86-98
MCH		29.3	Picograms	26-34
MCHC		35.5	%	32-36
Blood Grouping & Rh Factor		" B "Rh+(POSITIVE)		
BUN		14.0	mg %	M-7-20
S. Creatinine		0.91	Mg/100ml	0.9-1.4 mg /100 ml
HBsAg		-		
HIV I & II		-	Elisa Method	
HbA1C		4.6	%	4-6%
VDRL		-		

Details of packages		Patients report	Units	Normal value	
LFT	GGTP	29.0	U/L	5-60	
	SGOT	17.0	Units / ml	Upto 40	
	SGPT	25.0	Units / ml	Upto 40	
	S. Bilirubin	Total Bilirubin	0.66	mg%	Upto 1.2
		Direct Bilirubin	0.25	mg%	0-0.25
		Indirec Bilirubin	0.41	mg%	
		T. Protein	6.91	Gm%	6.2-8.3
	S. Albumin	4.29	Gm%	3.2-5.3	
	Globulin	2.62	Gm%		
	Alkaline phosphate	110.0	IU/L	60 - 170	
S. Calcium	-	Gm%	8.5-10.5		
Uric Acid	3.54	Mg%	2.5-7 mg%		
Blood Sugar Fasting		70.0	Mg%	60-110 mg %	
Blood Sugar PP		112.0	Mg%	Upto 160	
Lipid Profile	S. Cholesterol	186.0	mg%	120-220	
	S. Triglycerides	108.7	mg/ml	Upto 170	
	HDL Cholesterol	58.0	IU/L		
	LDL cholesterol	98.82	IU/L	450 at 37 <sup>o</sup> C	
VLDL	29.18	mg %	Upto 35		

### Routine Urine Analysis

Physical/ Chemical	Microscopic:	
Appearance	Clear	RBCs Nil
Specific Gravity	1010	WBCs 2-3/HPF
Ph	ACIDIC	Epith. Cells 2-3/HPF
Albumin	Nil	Casts Nil
Glucose F	NIL	Crystals Nil
Ketones	----	Bacteria Nil
Blood	Nil	Glucose P.P. NIL

Signature of Technician

Signature of Doctor

This Report is not Valid for Medical Legal Purpose

Pat-Name: Chandan Sharma

HR 70/min

Axis:

SINUS RHYTHM

UNCONFIRMED REPORT

Age: 32 M / F

Intervals:

P 64°

5.70

RR 850 ms

QRS 87°

P 100 ms

T 31°

PR 160 ms

P (II) 0.12 mV

QRS 86 ms

S (V1) - mV

QT 342 ms

R (V5) 1.06 mV

QTc 372 ms

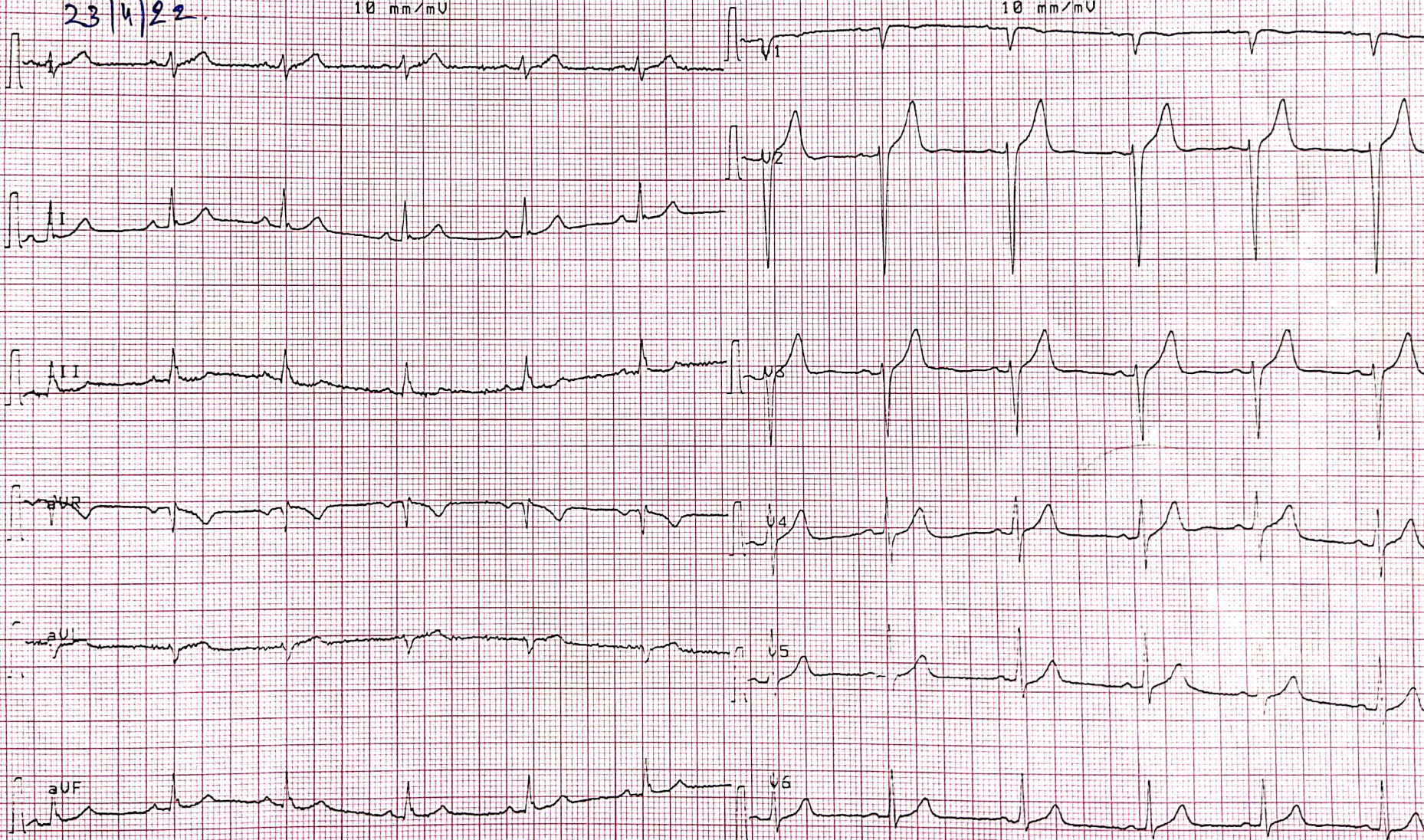
Sokol. 3.37 mV

*Chandan Sharma*

23/4/22

10 mm/mV

10 mm/mV



25 mm/s

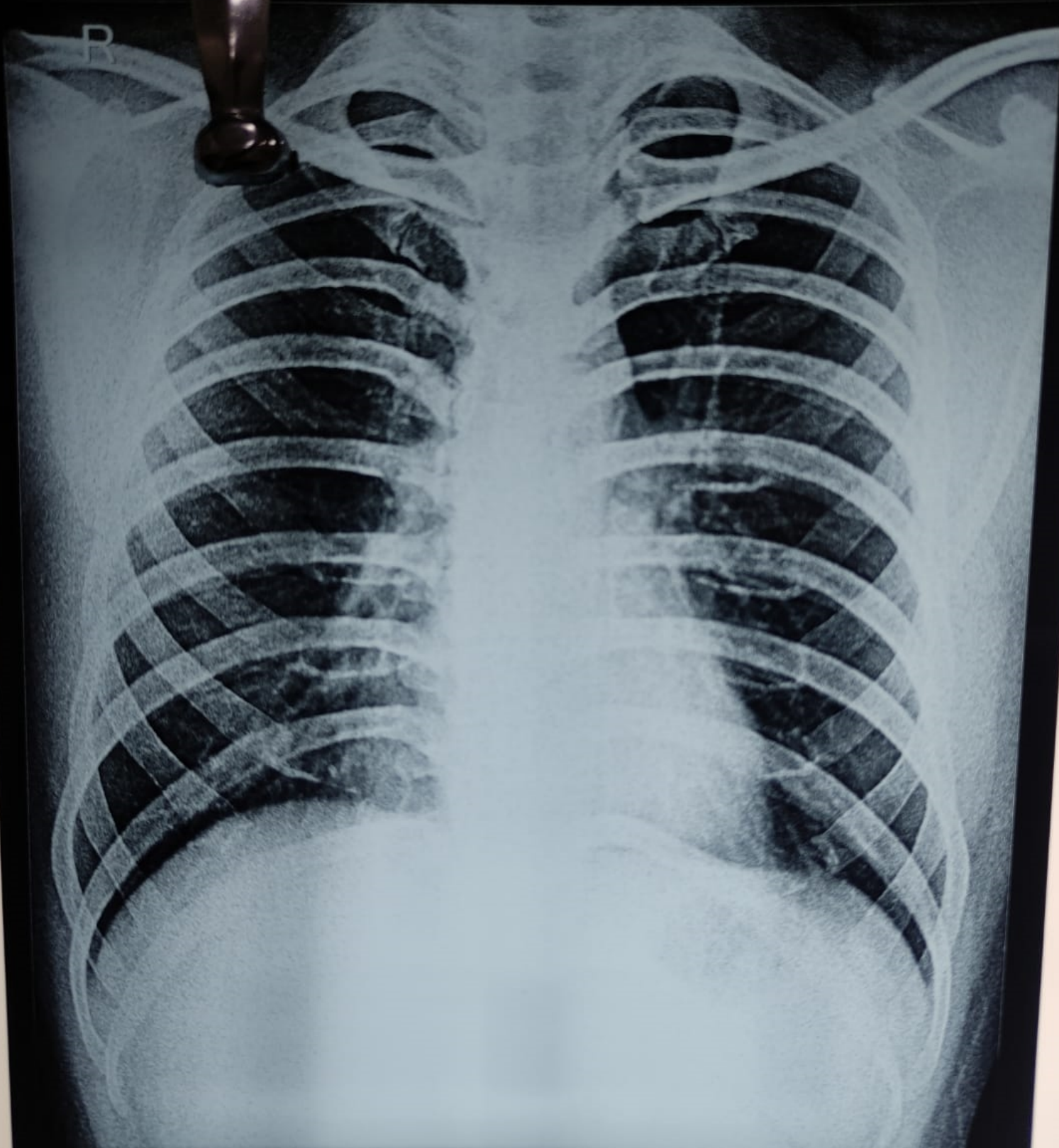
0.05-35 Hz F50 5a 23-APR-22 10:10:01

AT-2 0 3.03

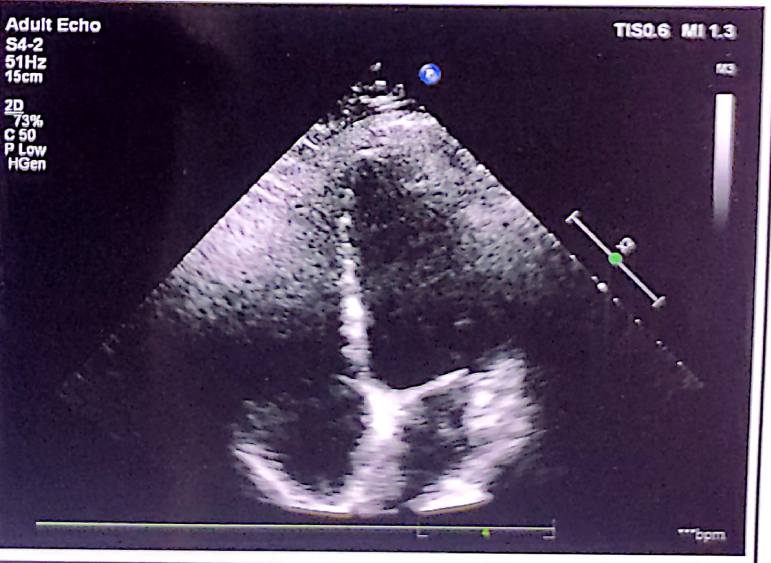
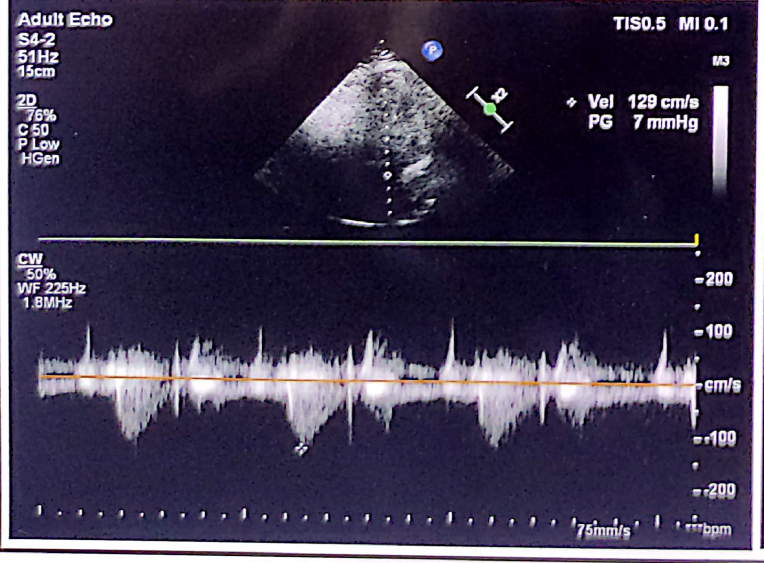
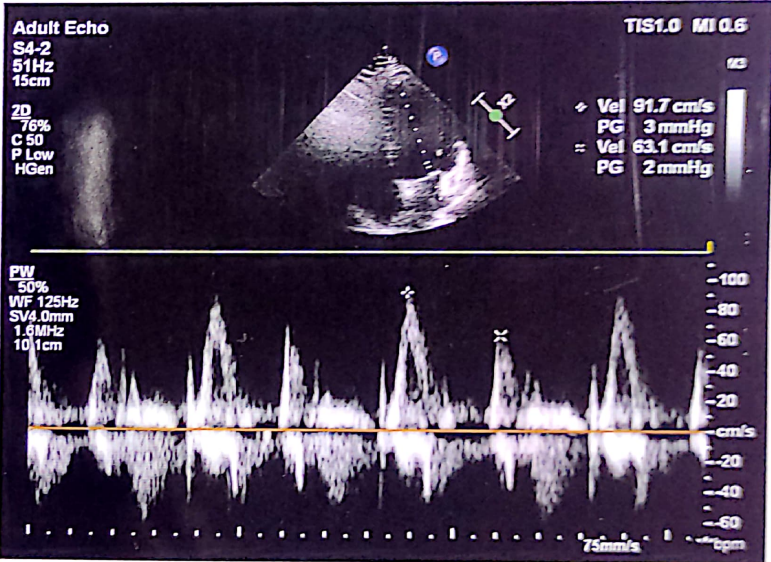
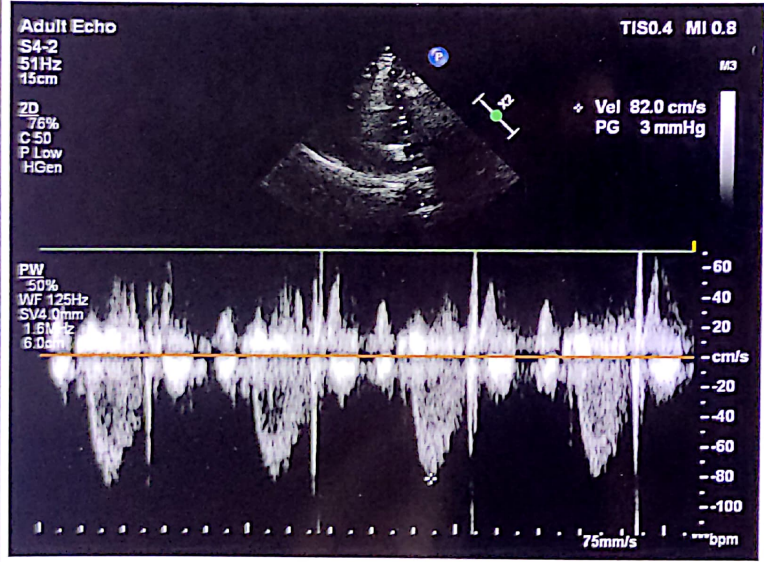
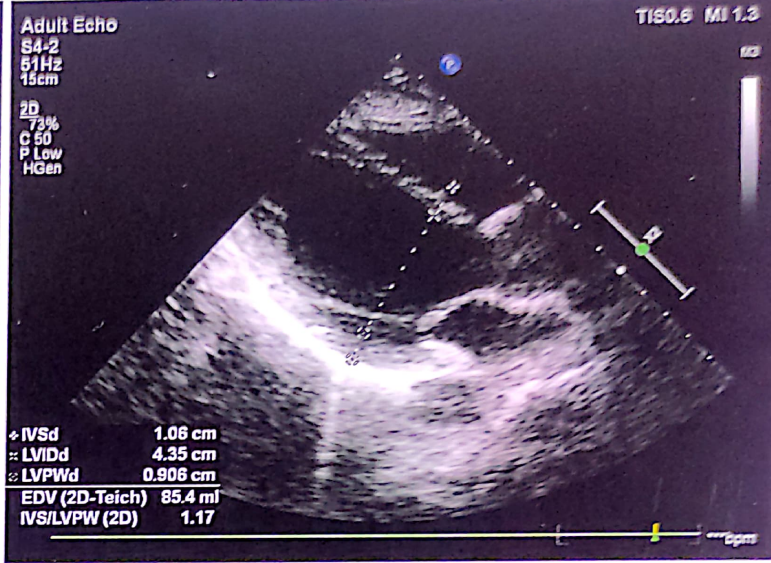
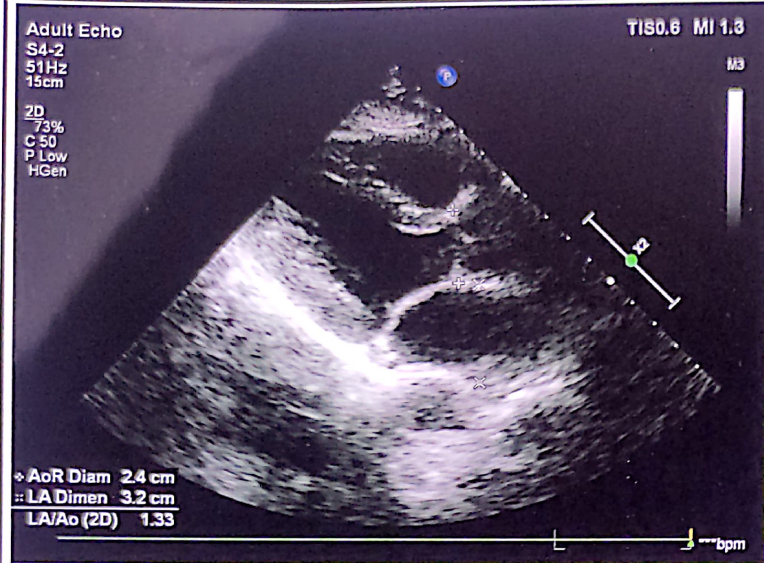
SCHILLER

Part No.2.157017M CE 0123

Q.88



MR. CHANDAN SHARMA AGE 32Y. 06 32 M CHEST, P->A  
THAREJA NURSING HOME ALWAR





# GUPTA ENT AND HEART CENTRE

Dayanand Marg, Nangli Circle, Alwar (Raj.) Ph. 0144-3591336 | M. 7378184427

## Echocardiography Report

Name : Mr. Chandan Sharma Refd by: Dr. M. N. Thareja  
Age / Sex : 32yrs./male Date : 23 April 2022

Clinical Diagnosis : For Cardiac Evaluation  
2D Echocardiography Findings  
Mitral Valve : Normal  
Aortic Valve : Normal  
Tricuspid Valve : Normal  
Pulmonary Valve : Normal  
Left Atrium : 3.2cm: Normal  
Left Ventricle : Normal LV size with normal LV systolic function. No RWMA

LVIDd	4.3cm.	IVSd	1.0cm.	EF	60%	Visual
LVIDs	2.4cm.	PWd	0.9cm.	EF	%	F.S.

Right Atrium : Normal  
Right Ventricle : Normal  
Aorta : 2.4cm: Normal  
Pulmonary Artery : Normal  
Pulmonary Veins : Normal  
Superior Venacava : Normal  
Inferior Venacava : Normal  
Pericardium : Normal  
Intracardiac Masses : No Intracardiac masses seen  
IAS/IVS : Intact

### Doppler Findings:

Valve	Peak Velocity (cm/s)	Peak Gradient (mmHg)	Mean Gradient (mmHg)	Regurgitation Grade	others/comments
Mitral Valve	E-/A-91/63			No MR	
Aortic Valve	129				
Tricuspid Valve				No TR, No PAH.	
Pulmonary Valve	82				

Diagnosis : Transthoracic echo done in supine position at resting heart rate of 70bpm, shows Normal LV size with normal LV systolic function. LVEF~60% (Visual). No RWMA.  
Other cardiac chambers are normal in size.  
No MR, No TR, No PAH.  
Normal MIP.  
No pericardial effusion /Vegetation /Clot Intracardiac masses seen.  
Normal left sided arch of aorta, No Coarctation.

Dr. Prachi Gupta  
MBBS, FCGI  
(Non-Invasive Cardiology) Invasive  
Gupta ENT and Heart Centre  
Nangli Circle, Alwar

Please correlate clinically



# THAREJA NURSING HOME

1, Ram Kuteer Company Bagh Road, ALWAR - 301001 (Raj.)  
Mob. 9982111801, Ph. 0144-2700184, 2331842, Telefax: 0144-2342339  
E-mail: drmnthareja@yahoo.com



Name Chandana Sharma Age 32 Yr OPD/UHID..... Date 23/04/2022

Address..... Mobile No.....

VITALS	B.P.	Pulse	Temp.	Wt.	Ht.	Allergies
--------	------	-------	-------	-----	-----	-----------

Complaints

*Routine eye check up*

*Right eye vision 19/6/6 with 6/6 glasses*

Findings

*color vision WNL*

Investigation

*NA - 6/6 with glasses*  
*L 6/6 with glasses*

Treatment

**DR. M.N. THAREJA**

7233 (RMC)  
Male Infertility Specialist

**DR. SAVITA THAREJA**

7600 (RMC)  
Female Infertility Specialist

**DR. JAYANT THAREJA**

A-0824 (RSDC)  
M.D.S.

Oral & Maxillo - Facial Surgery  
Ex Resident Trauma Centre,  
AIIMS, Delhi

**DR. SHIVANI THAREJA**

10807 / 31220 (RMC)  
Ophthalmologist  
Cornea Specialist

**DR. PRERNA THAREJA**

A-3574  
MDS (Endodontics)  
Root Canal Specialist  
Ex Resident  
AIIMS, Jodhpur

**DR. H.R. GUPTA**

1744 (RMC)  
Senior Consultant  
M.S. Gen Surgeon

**DR. VARUN SAPRA**

Reg. No. 70990 (DMC)  
MBBS DNB ORTHO, D.ORTHO  
Joint Replacement &  
Arthroscopy Surgeon

**Dr. M. N. THAREJA**

MBBS  
Thareja Nursing Home  
Alwar-301001, (Raj.)

**Pain Scale**

0



No Pain

2



Mild Pain

4



Distressing

6



Distressing

8

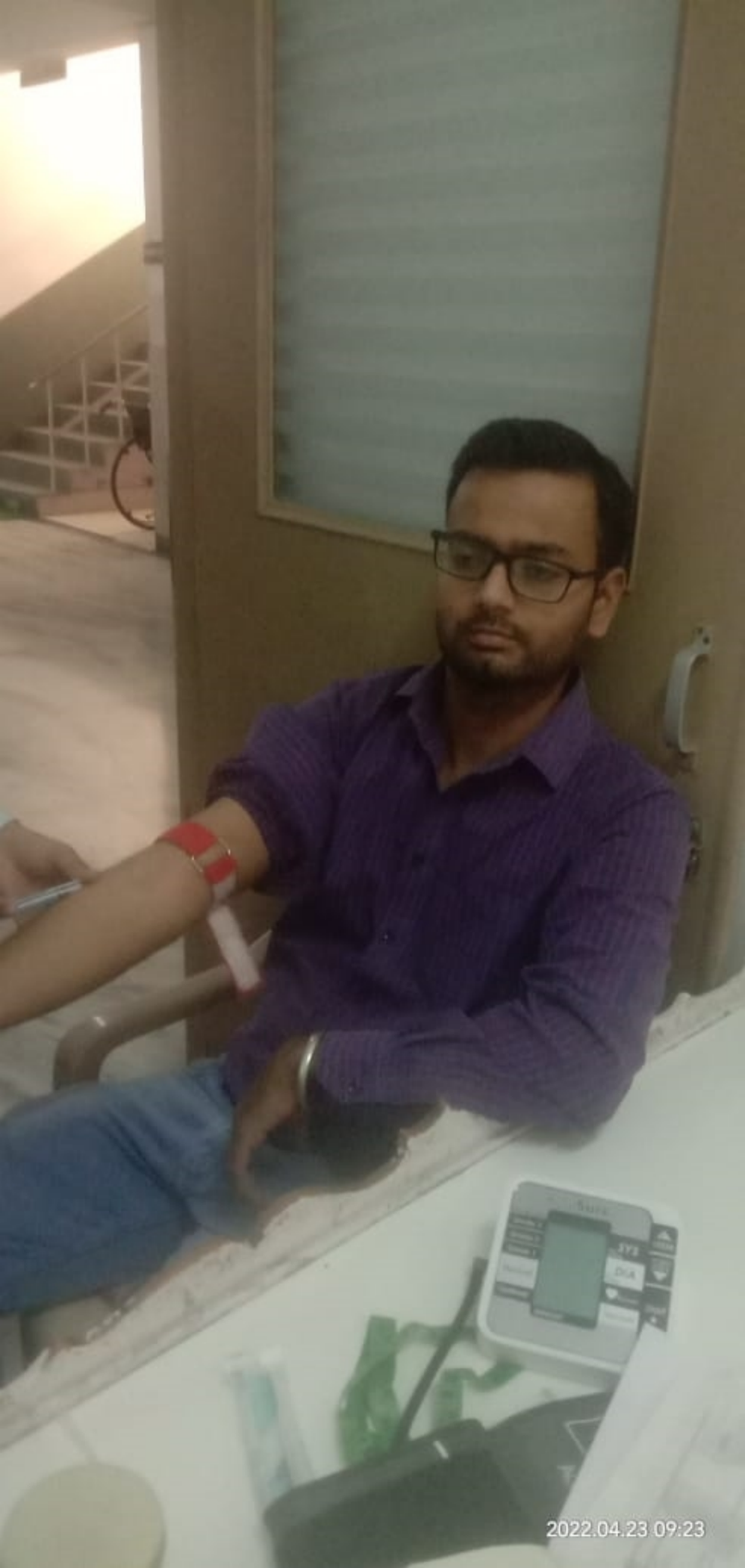

Intense

10

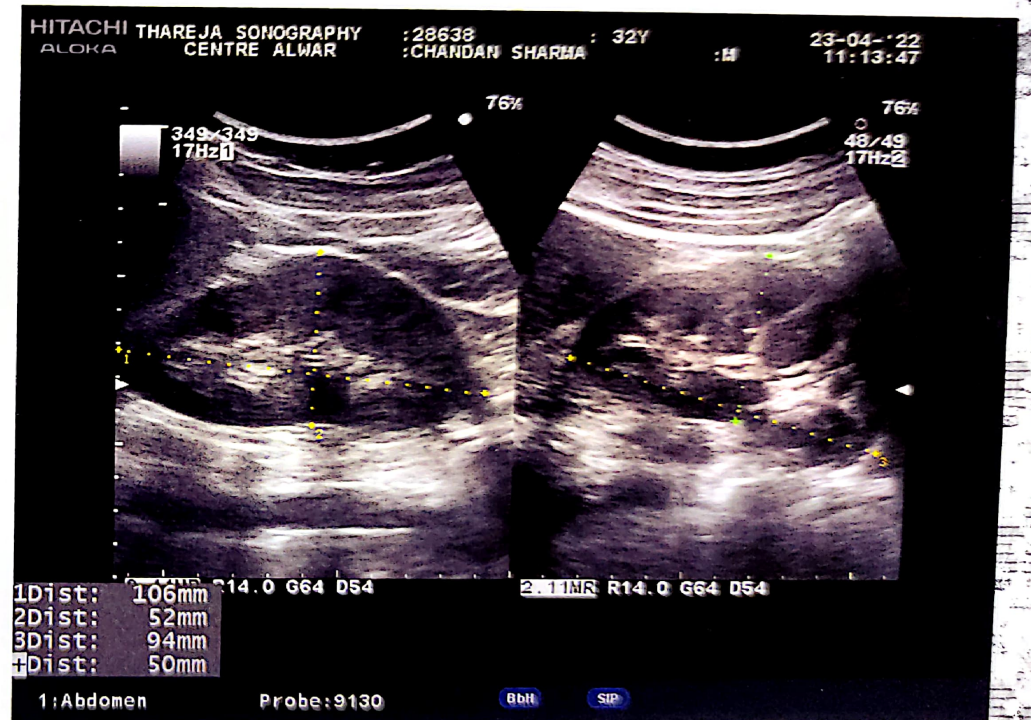
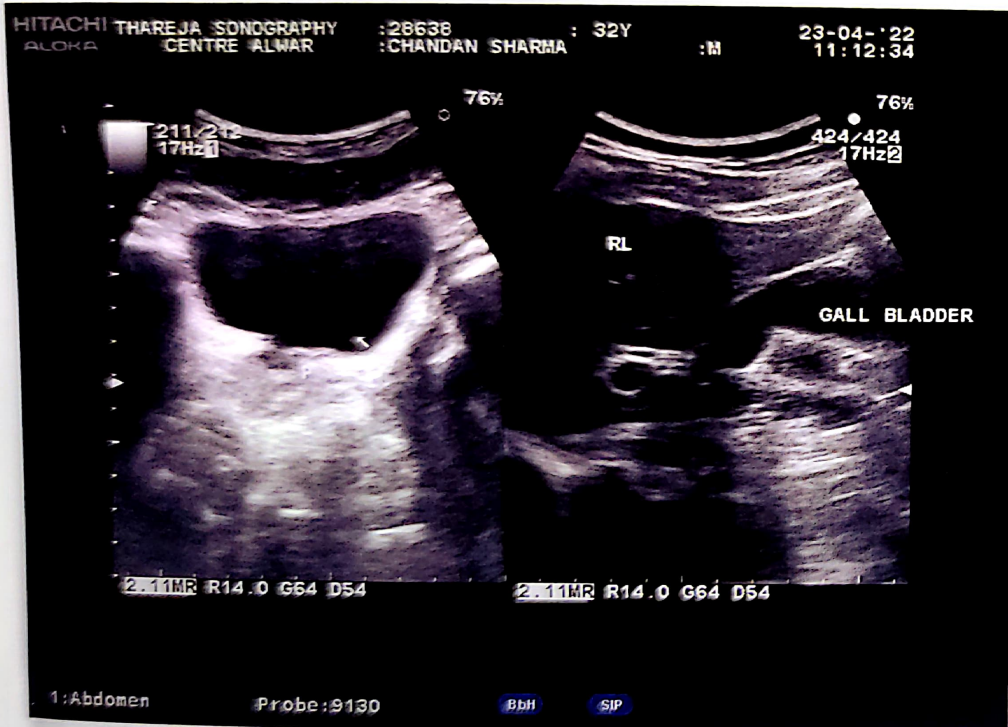


Excruciating



2022.04.23 09:23







# THAREJA SONOGRAPHY CENTRE

1, Ram Kuteer, Company Bagh Road, ALWAR - (0144) 2700184



This report is not valid for MLC Purpose

Ref. No.

Date.....  
23/04/2022

Name of Patient: MR. CHANDAN Age : 32 Yrs. Sex: M  
Ref.by : DR. M. N. THAREJA

## Sonography Report – abdomen

LIVER: Size: RL: 13.4 cm L. L.:4.9 cm.  
Margins: Regular I.H.B.R: ND  
Parenchyma : Echo  
C. B. D. Size: 3.2 mm LUMEN: Clear  
P.V. Size: mm LUMEN: Clear  
GALL BLADDER : Size 3.8 X 1.6cm  
Wall thickness N Lumen : Clear  
PANCREAS: N  
SPLEEN: 7.8 cc  
KIDNEYS: Right: 9.4 X 5.0 cm Left: 10.3 X 5.2 cm

PELVICALYCAL SYSTEM: |  
CORTICO – MEDU. DIFF: | N

RETROPERITONEUM : |  
LYMPH – NODES : | Not Seen  
PLEURAL EFFUSION : |  
ASCITES : |

URINARY BLADDER:  
Prevoiding Volume 106 cc  
Wall Thickness: N  
PROSTATE: N

Residual Urine C.C.  
Lumen: Clear


Size: N  
Parenchyma: Echo

Capsule: Intact

SEMINAL – VASICLES: Normal

**Conclusion:- Normal Study**

Thanks,

  
Dr. Savita Thareja  
Reg. No. 7600  
Rajasthan Medical Council

Enclosed: Photo - 2

PLEASE NOTE: INTESTINAL PATHOLOGY CAN NOT BE RULE OUT

This is only an opinion, not a diagnosis, which should be clinically co-related. No procedure/surgery should be undertaken simply on the basis of this opinion because Ultrasound accuracy is only 96%.

\* Subject to Alwar jurisdiction. \* Not valid for medico-legal purpose.



# THAREJA NURSING HOME



DIGITAL X-RAY, OPG, COMPUTERISED ECG & EEG, DIAGNOSTIC  
LABORATORY EQUIPED WITH COMPUTERISED AUTO ANALYZER & CBC

1, Ram Kuteer, Company Bagh Road, ALWAR - 301001 (Raj.) Ph: 0144-2700184, 2331842

Name : **CHANDAN SHARMA** age **32** Sex : **MALE**  
Ref. By : **M.N. THAREJA** Lab No. : Date : **April 23, 2022**

## HORMONES & MARKERS

<u>Test</u>	<u>Value</u>	<u>Units</u>	<u>Biological Ref. Values</u>
T3 (Total Triiodothyronine)	1.48	ng/dL	0.60-1.81 ng/dL Adults
T4 (Total Thyroxine)	5.51	µg/dL	3.2-12.60 µg/dL : Adults
TSH (Thyroid Stimulating Hormone)	3.16	µIU/mL	Adults : 0.35-5.50 µIU/mL

### Interpretation of TSH :-

#### Children

0 Days : 1.0-39.0 uIU/mL  
5 days : 1.7-9.1 uIU/mL  
1 year : 0.4-8.6 uIU/mL  
2 years : 0.4-7.6 uIU/mL  
3 years : 0.3-6.7 uIU/mL  
4-19 years : 0.4-6.2 uIU/mL

### Interpretation of TSH :-

#### Children

3.20 - 34.6 µIU/mL 1- 2 Days  
0.70 - 15.4 µIU/mL 3 - 4 Days  
0.70 - 9.10 µIU/mL 15 Days - 5 Months  
0.70 - 6.40 µIU/mL 5 Months - 20 Years

#### Adults

20-54 years : 0.35-5.50 uIU/mL  
55-87 years : 0.5-8.9 uIU/mL

#### Pregnancy

1st Trimester : 0.30 - 4.50 µIU/mL  
2nd Trimester : 0.50 - 4.60 µIU/mL  
3rd Trimester : 0.80 - 5.20 µIU/mL

#### Pregnancy

0.30 - 4.50 µIU/mL 1st Trimester  
0.50 - 4.60 µIU/mL 2nd Trimester  
0.80 - 5.20 µIU/mL 3rd Trimester

Method : **Fluorescence Immunoassay Technology**


Sample Type : **Free Blood Serum**


### Remarks :

Primary malfunction of the Thyroid gland may result in excessive (hyper) or Low (hypo) release of T3 or T4. In addition, as TSH directly affect thyroid function, malfunction of the pituitary or the hypothalamus influences the thyroid gland activity.

Disease in any portion of the thyroid-pituitary-hypothalamus system may influence the level of T3 and T4 in the blood, in Primary Hypothyroidism,

TSH levels are significantly elevated, while in secondary and tertiary hypothyroidism, TSH levels may be low. In addition, in Euthyroid sick syndrome, multiple alterations in serum thyroid function test findings have been recognized.

  
Signature of Technician

  
Signature of Doctor



# THAREJA NURSING HOME



DIGITAL X-RAY, OPG, COMPUTERISED ECG & EEG, DIAGNOSTIC  
LABORATORY EQUIPED WITH COMPUTERISED AUTO ANALYZER & CBC

1, Ram Kuteer, Company Bagh Road, ALWAR - 301001 (Raj.) Ph: 0144-2700184, 2331842

PROPOSAL NO.PKG10000227

Patient Name MR CHANDAN SHARMA

Ref. By Dr. M. N. THAREJA


Date 23/04/2022


Age 32 Yrs.

Sex M

**PART - X-RAYED :** X-RAY CHEST PA VIEW  
**REPORT :** X-RAY CHEST P.A. VIEW  
:- Chest is bilaterally symmetrical.  
:- C.P. Angles are clear.

**CONCLUSSION: Normal Study**

  
Signature of Technician

  
Signature of Doctor