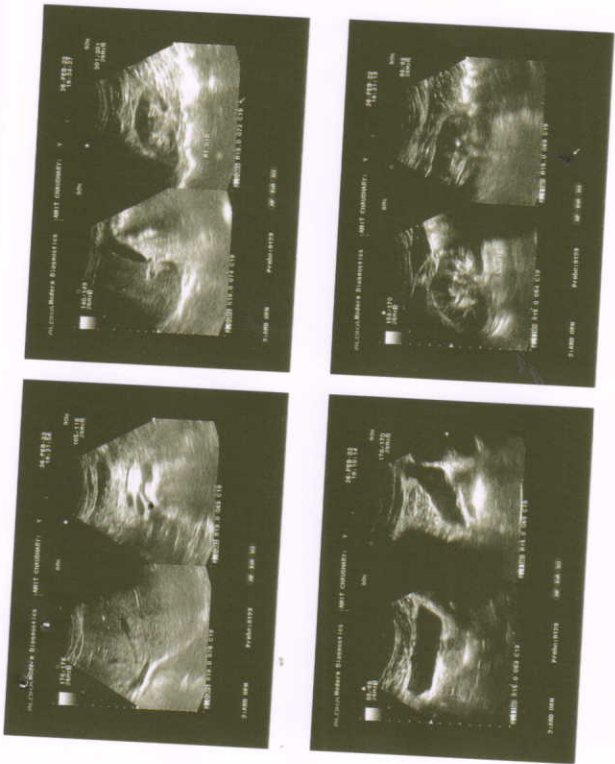




Patient's Name Mr Amit Chaudhary  
Ref By Dr V M Nadkarni  
Date 26/02/2022

### USG ABDOMEN & PELVIS

Liver normal in size, shape & outline & reveals normal echo-texture.  
No focal lesion seen. Intra hepatic biliary and portal vein radicles normal.  
Gall bladder physiologically distended & shows clear contents. No calculi. No e/o cholecystitis.  
Portal vein & CBD normal. No calculus in CBD.  
Spleen & visualized pancreas show normal size & echoanatomy. Tail of pancreas not visualized due to unavoidable bowel gas.  
Both kidneys normal in size, shape, outline & position.  
Right kidney :- 114mm x 45mm.  
Left kidney :- 104mm x 50 mm.  
No hydronephrosis, hydroureter on either side. No calculus seen in right kidney or in visualized ureters.  
Left kidney shows a Nonobstructing calculus 4mm in midcalyx.  
Cortico-medullary differentiation normal.  
Urinary bladder is well filled. No mural or luminal pathology seen. Prostate normal in size, echotexture; measures 28mmx34mmx 26mm; volume 13cc.  
Aorta & IVC normal. No lymphadenopathy. No loculated or free fluid collection seen in abdomen or pelvis. No abnormally dilated bowel loops seen.

### IMPRESSION

**Nonobstructing small left renal calculus**  
**No other abnormality appreciated in this USG study of Abdomen & Pelvis**

  
**Dr. Prashant Naik MD (Radiology)**  
Thanks for referral