

Customer Name	MR.SANKARA NARAYANAN	Customer ID	MED120925854
Age & Gender	46Y/MALE	Visit Date	28/03/2022
Ref Doctor	MediWheel		

DEPARTMENT OF CARDIOLOGY

TRANSTHORACIC RESTING ECHO CARDIOGRAPHY REPORT

**ECHO INDICATION: Assessment
M MODE & 2-D PARAMETERS:**

ACOUSTIC WINDOW : GOOD

LV STUDY

DOPPLER PARAMETERS

IVS(d)	cm	0.5
IVS(s)	cm	1.1
LPW(d)	cm	0.5
LPW(s)	cm	1.3
LVID(d)	cm	5.9
LVID(s)	cm	4.1
EDV ml		209
ESV ml		72
SV ml		137
EF %		65
FS %		29

Parameters		Patient Value
LA	cm	3.0
AO	cm	2.1

Valves	Velocity max(m/sec mm/Hg)
AV	0.6/2 m/s
PV	0.7/3 m/s
MV (E)	0.5 m/s
(A)	0.7 m/s
TV (E)	1.0/4 m/s
(A)	m/s

FINDINGS:

- ❖ No regional wall motion abnormality.
- ❖ Normal left ventricle systolic function. (EF: 65%).
- ❖ Grade – I LV diastolic dysfunction.
- ❖ Normal chambers dimension.
- ❖ Normal valves.
- ❖ Normal pericardium/Intact septae.
- ❖ No clot/aneurysm.

IMPRESSION:

- ▼ **NO REGIONAL WALL MOTION ABNORMALITY.**
- ▼ **NORMAL LEFT VENTRICLE SYSTOLIC FUNCTION.**


S. VIGNESH M.Sc.
ECHO TECHNICIAN



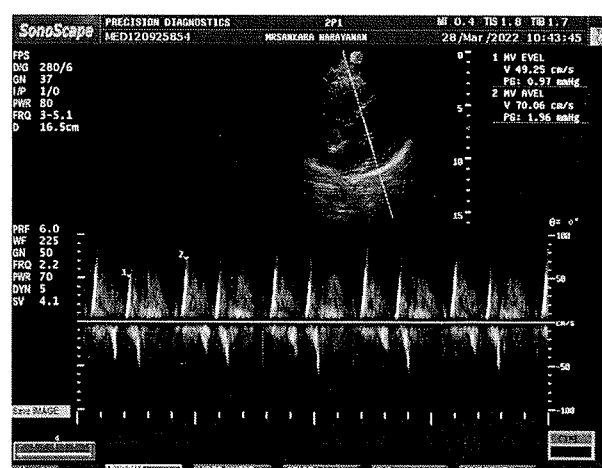
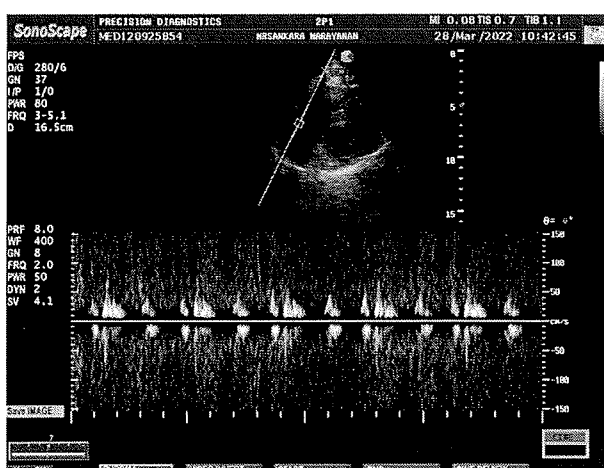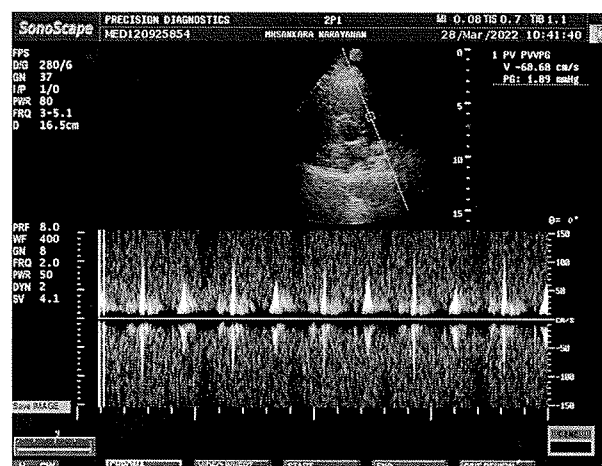
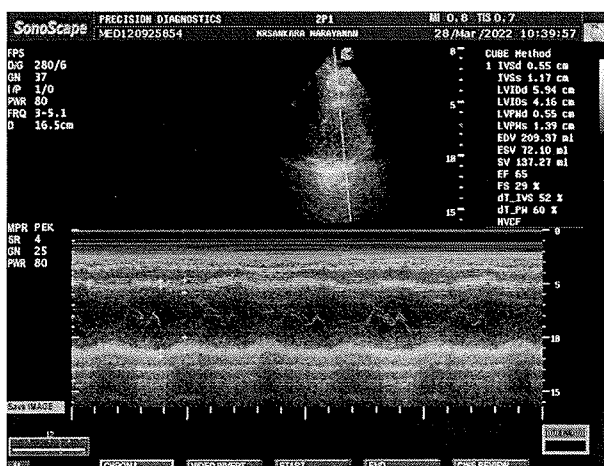
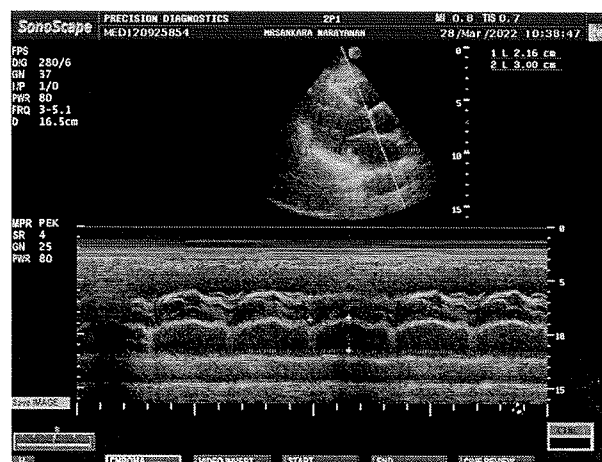
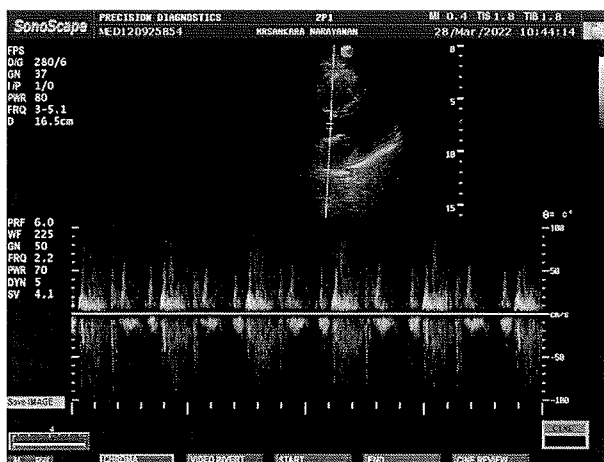


MEDALL

Precision Diagnostics-vadapalani

58/6, Revathy street, Jawarlal nehru road, 100 feet Road, (Former State Election Commission Office),

Customer Name	MR.SANKARA NARAYANAN	Customer ID	MED120925854
Age & Gender	46Y/MALE	Visit Date	28/03/2022
Ref Doctor	MediWheel		



You can also conveniently view the reports and trends through our App. Scan QR code to download the App.



Please produce bill copy at the time of collecting the reports. Request you to provide your mobile number or customer id during your subsequent visits.

Customer Name	MR.SANKARA NARAYANAN	Customer ID	MED120925854
Age & Gender	46Y/MALE	Visit Date	28/03/2022
Ref Doctor	MediWheel		

SONOGRAM REPORT

WHOLE ABDOMEN

The liver is normal in size and shows uniform echotexture with no focal abnormality.

The gall bladder is normal sized. A calculus measuring 1 cm seen in the lumen of gall bladder.

There is no intra or extra hepatic biliary ductal dilatation.

The pancreas shows a normal configuration and echotexture. The pancreatic duct is normal.

The portal vein and IVC are normal.

The spleen is normal.

There is no free or loculated peritoneal fluid.

No para aortic lymphadenopathy is seen.

No abnormality is seen in the region of the adrenal glands.

The right kidney measures 11.0 x 4.8 cm.

The left kidney measures 11.4 x 5.0 cm.

Both kidneys are normal in size, shape and position. Cortical echoes are normal bilaterally.

There is no calculus or calyceal dilatation.

The ureters are not dilated.

The bladder is smooth walled and uniformly transonic. There is no intravesical mass or calculus.

The prostate measures 3.1 x 3.6 x 3.4 cm (20 cc) and is normal sized.

The echotexture is homogeneous.



Customer Name	MR.SANKARA NARAYANAN	Customer ID	MED120925854
Age & Gender	46Y/MALE	Visit Date	28/03/2022
Ref Doctor	MediWheel		

The seminal vesicles are normal.

Iliac fossae are normal.

IMPRESSION:

- Gall bladder calculus.



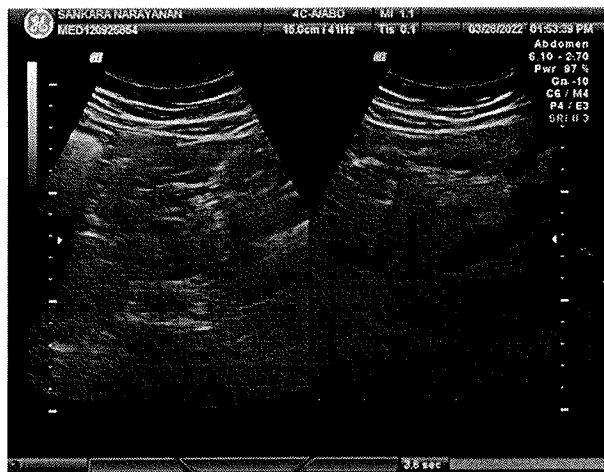
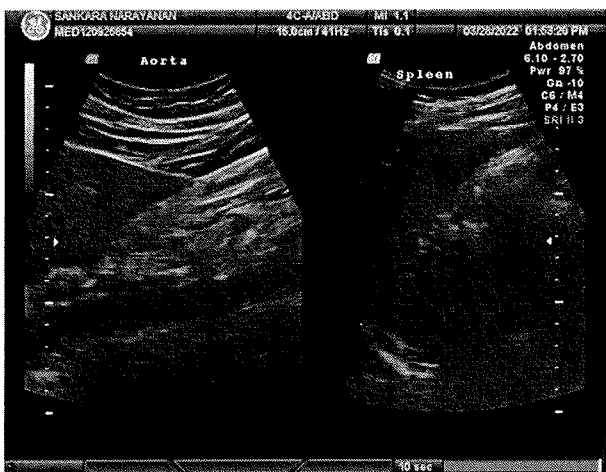
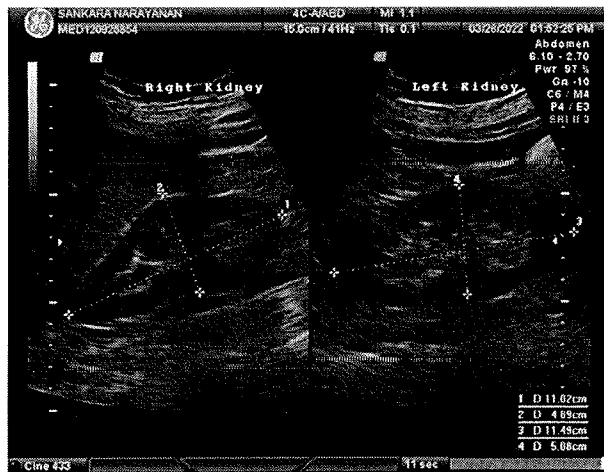
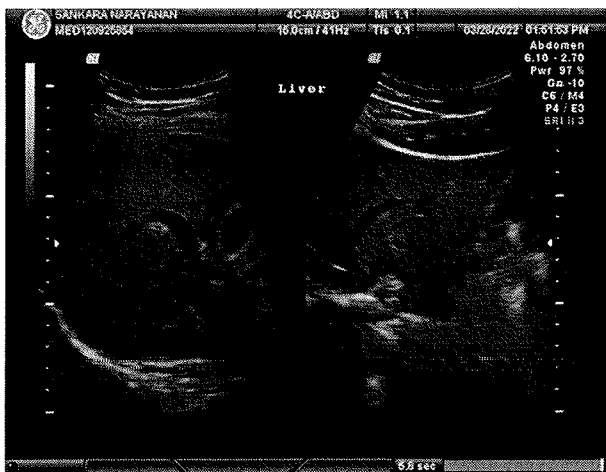
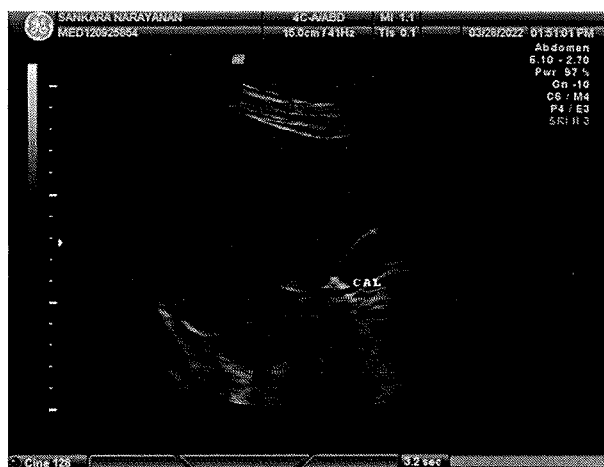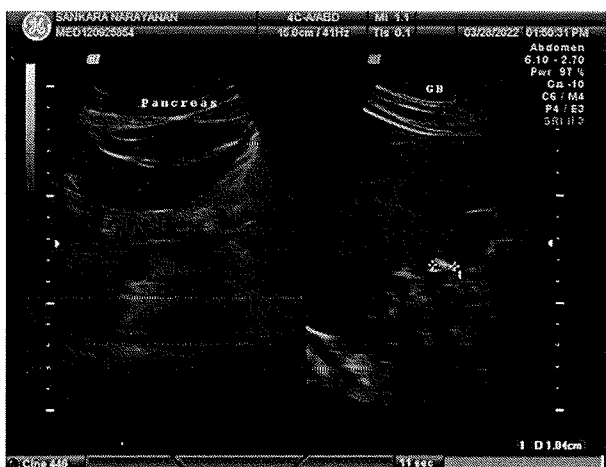
Dr.Vanmathi.F.USG (OBGYN)
Consultant Sonologist



Precision Diagnostics-vadapalani

58/6, Revathy street, Jawarlal nehru road, 100 feet Road, (Former State Election Commission Office),

Customer Name	MR.SANKARA NARAYANAN	Customer ID	MED120925854
Age & Gender	46Y/MALE	Visit Date	28/03/2022
Ref Doctor	MediWheel		



Precision Diagnostics-vadapalani

58/6, Revathy street, Jawarlal nehru road, 100 feet Road, (Former State Election Commission Office),

Customer Name	MR.SANKARA NARAYANAN	Customer ID	MED120925854
Age & Gender	46Y/MALE	Visit Date	28/03/2022
Ref Doctor	MediWheel		

