

mediwheel.

1800 180 1947
www.uidai.gov.in
help@uidai.gov.in
R.O. Box No. 1947, Bengaluru-560 001

www

Address: S/O: Vinod Kumar
Chawla, house no-203 ward
no-19, khanna khurd road,
near springdel school,
khanna, khanna, Ludhiana,
khanna, Punjab, 141401

ਭਾਰਤ ਸਰਕਾਰ
ਏ ਏ ਏ ਏ 19 ਖਾ ਖਾ ਏ
ਏ ਏ ਏ ਏ 141401

ਏ ਏ ਏ ਏ ਏ ਏ ਏ ਏ ਏ ਏ
UNIQUE IDENTIFICATION AUTHORITY OF INDIA

26/02/82
39/11

ਭਾਰਤ ਸਰਕਾਰ
GOVERNMENT OF INDIA

ਸਨੀ ਚਾਵਲਾ
Sunny Chawla

ਸਾਲ ਦਾ ਜਨਮ / Year of Birth: 1982
ਲਿੰਗ / Male

5909 8175 2553

ਆਧਾਰ - ਆਮ ਆਦਮੀ ਦਾ ਅਧਿਕਾਰ

M.B.B.S, F.C.C.P. (RESP. MEDICINE) PGDHIM, PGDIMS
FELLOW INTENSIVE CARE
MMC REG. NO. - 91702
NATHANI HEIGHTS, B-W-13,
42, MUMBAI CENTRAL (EAST)



Dr. Hari Chhablani

Cardiometabolic Physician & Intensivist
M.B.B.S., F.C.C.P. (RESP. MED.), PGDHMM,
PGDMLS, FELLOW INTENSIVE CARE MED.

ATTACHED TO: Wockhardt Hospital • Saifee Hospital • Apollo Spectra Hospital

NATHANI HEIGHTS, B-Wing, Shop No. 42, Ground Floor, Opp. Mumbai Central Station (East),
Mumbai - 400 008. • Cell : 98206 46163 • E : drharichhablani@gmail.com

PHYSICIAN REPORT

28/08/2021

NAME : SUNNY CHAWLA

AGE/SEX: 39/M

PRESENTING COMPLAINS: NIL

PAST HISTORY: NIL

FAMILY HISTORY: NOT SIGNIFICANT

ADDICTION: NIL

P: 60

BP: 110/70

RS: CLEAR

CVS: S1,S2 REGULAR

PA: SOFT

CNS: CLINICALLY NAD

ECG: WNL

CXR: WNL

LABS: ATTACHED

USG ABDO-PELVIS: WNL

EYE EXAMINATION B/E : NEAR VISION - BL N12 DISTANT VISION - 6/12 COLOUR VISION - NORMAL

IMPRESSION : FIT ON CLINICAL MEDICAL EXAMINATION.

DR. HARI CHHABLANI

DR. HARI CHHABLANI
M.B.B.S., F.C.C.P. (RESP. MEDICINE) PGDHMM, PGDMLS
FELLOW INTENSIVE CARE
MMC REG. NO. - 91702



NAME : SUNNY CHAWLA

39/M

DATE:28/08/2021

REF BY : DR. PURVI CHHABLANI

2D-ECHO. AND COLOR DOPPLER REPORT

- NORMAL CARDIAC VALVES WITH TRIVIAL TR.
- NORMAL CARDIAC CHAMBERS
- NO E/O REGIONAL WALL MOTION ABNORMALITY. WITH NORMAL LVEF OF 64 %.
- NO E/O PULMONARY HYPERTENSION. PASP 32 mmHg by TR jet.
- NO E/O LEFT VENTRICULAR HYPERTROPHY.
- NO E/O DIASTOLIC DYSFUNCTION.
- NO E/O PERICARDIAL EFFUSION.
- NO E/O INTRACARDIAC CLOT OR VEGETATIONS.
- INTACT IAS/IVS
- CONVENTIONL DOPPLER :

E TO A RATIO IS MORE THAN ONE IN LV INFLOW.


THERE IS NO GRADIENT ACROSS AV, LVOT OR RVOT

PASP FROM TR JET IS .32 mm OF Hg.

- COLOUR DOPPLER:

TRIVIAL TR

EF Slope	113	mm/sec		
Opening Amplitude	17			
Posterior leaflet				
E.P.S.S	02	mm		
Mitral valve prolapse				
Vegetations				
TRICUSPID VALVE	OBSERVED	NORMAL VALUES		
PULMONARY VALVE	OBSERVED	NORMAL VALUES		
EF Slope				
'A' Wave				
Midsystolic notch				
Flutter				
Other Findings				
AORTIC VALVE	OBSERVED	NORMAL VALUES		
Cuspal opening	17	mm		
Closure line	Central			
Eccentricity index	1			
Other Findings				
DIMENSIONS	OBSERVED	NORMAL VALUES		
1. Lvd (Diastolic)	45	26-52		
2. Lvd (Systolic)	29	24-42mm		
3. RVD (Diastolic)	18	7-23mm		
4. IVST (Diastolic)	09	6-11mm		
5. IVST (Systolic)	15			
6. LVPWT (Diastolic)	09	6-11mm		
7. LVPWT (Systolic)	17			
8. Aortic root	28	22-37mm		
9. left Atrium	33	19-40mm		
	STRUCTURE	REGURG GRADING	VELOCITY m/sec	STENOSIS GRADIENT mm/Hg
			Max mean	Peak mean
MITRAL VALVE	NORMAL	0/3	/	/
TRICUSPID VELVE	NORMAL	TRIVIAL	/	/
PULMONARY VELVE	NORMAL	0/4	/	/
AORTIV VALVE	NORMAL	0/4	/	/


DR.P.H.CHHABLANI
 M.B.B.S, DNB.(MEDICINE)
 CONSULTANT PHYSICIAN AND CARDIOLOGIST.

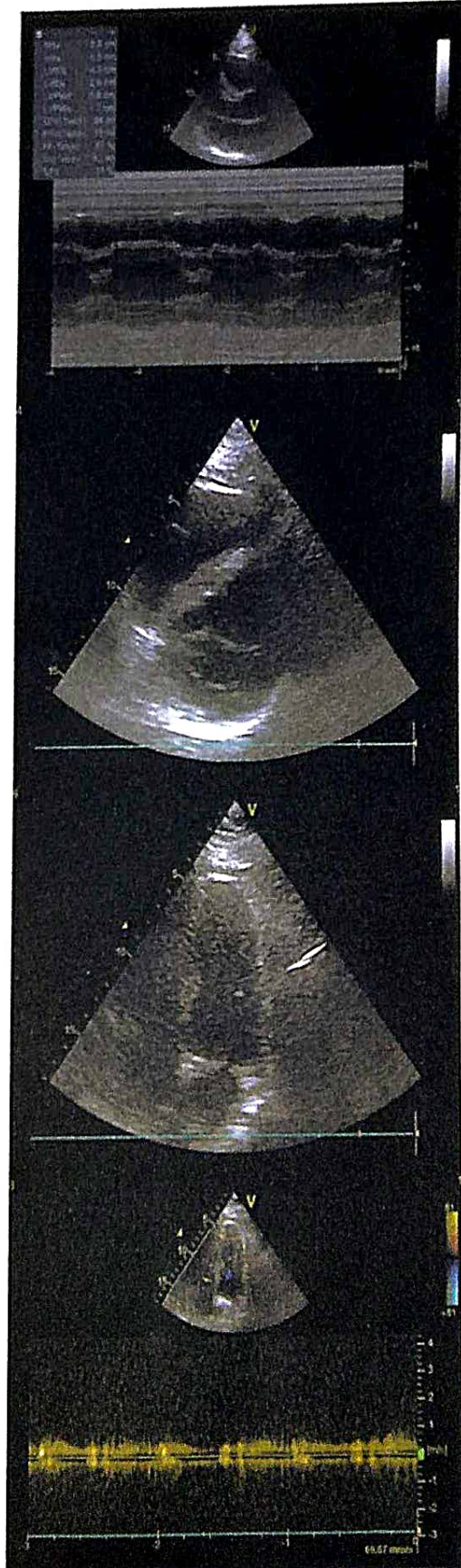
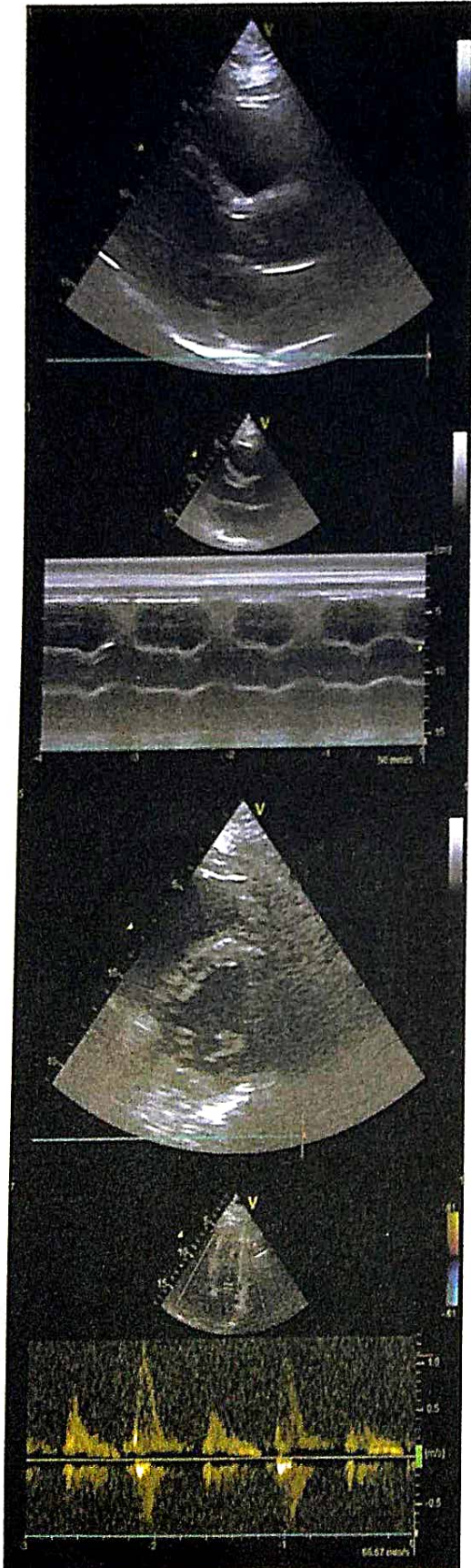
DR. PURVI CHHABLANI
 MBBS, DNB (Medicine),
 Consultant Physician And Intensivist
 Reg No 77696

Name **SUNNY CHAWLA**

Sex **Male**

Age **39**

Date **28/08/2021**



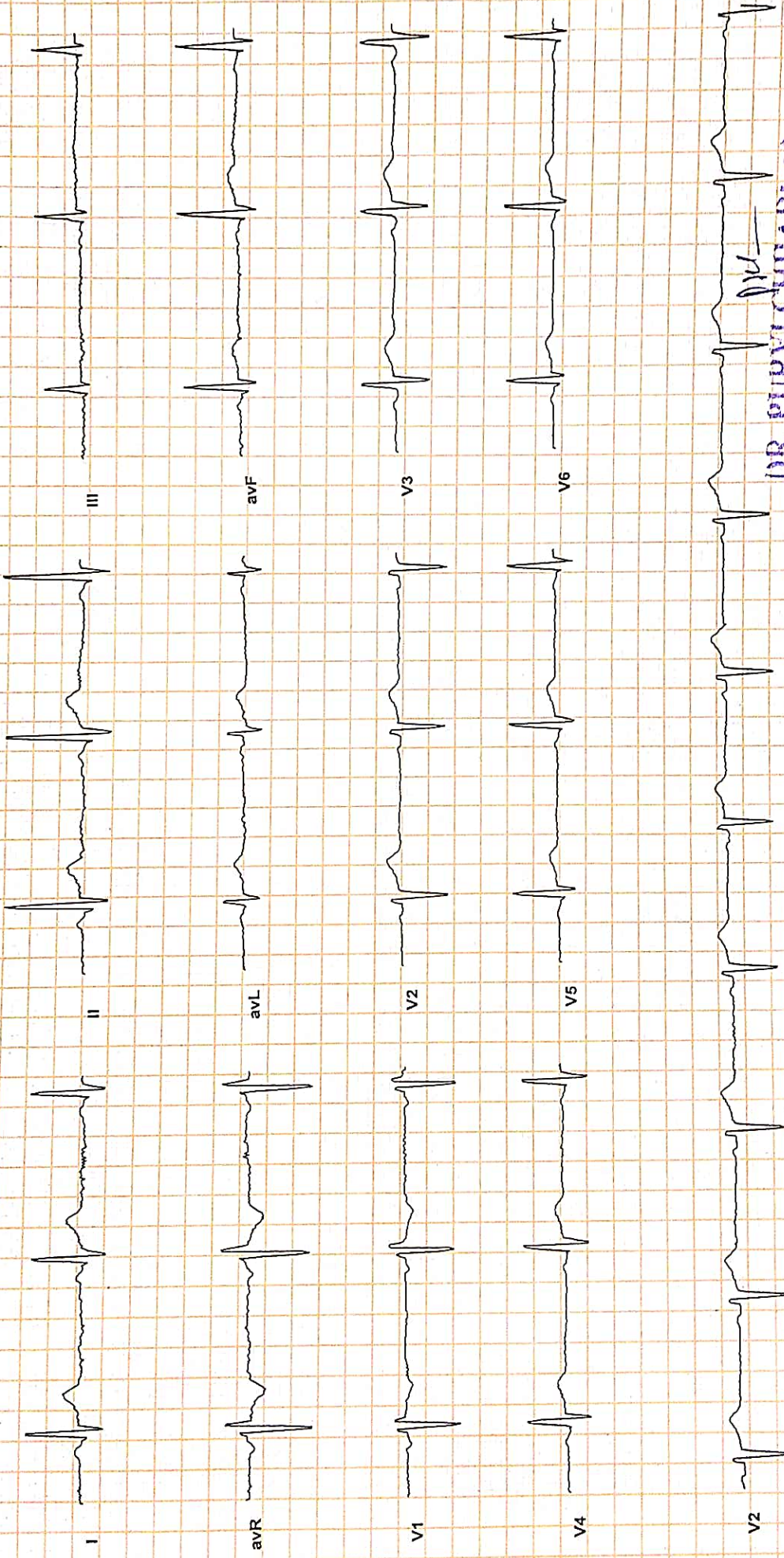
DR PLUS HEALTHCARE CENTRE- MUMBAI CENTRAL

1027 / SUNNY CHAWLA / 39 Yrs / M

Heart Rate : 56 bpm / Tested On : 28-Aug-21 / HF 0.05 Hz - LF 100 Hz / Notch 50 Hz / Sn. 1.00 Cm/mV / Sw 25 mm/s

ECG

mm/s



Normal

DR. PURVI CHHABLANI

MBS DNB (Medicine)
Consultant Physician
Reported By: DR. PURVI CHHABLANI
Reg. No. 77699



Dr-Plus Healthcare Centre

NATHANI HEIGHTS, B-Wing, Shop No. 42, Ground Floor, Opp. Mumbai Central Station (East), Mumbai - 400 008.

Patient Name	:	SUNNY CHAWLA	Sex:	Male
Doctor's Name	:	SELF	Age:	39 Years
Date	:	28/08/2021		

ULTRASONOGRAPHY OF THE ABDOMEN AND THE PELVIS:

The relevant sonographic findings include the following:

HEPATOBIILIARY APPARATUS

The liver is normal in size and echogenicity. No obvious focal parenchymal lesion is seen. Extrahepatic biliary radicals are not dilated.

The portal vein (1.0 mm) and the common bile duct are normal.

GALL BLADDER

The gall bladder is adequately distended. The wall thickness is normal.

No echogenic contents are noted in its lumen. There is no pericholecystic collection noted.

PANCREAS

The pancreas shows normal echogenicity and size. No focal or diffuse lesions are noted.

No evidence of calcification is noted.

SPLEEN

The spleen appears normal in size and echogenicity. No focal or diffuse lesions are noted.

No evidence of calcification is noted.

KIDNEYS

Right Kidney measure: 9.45 x 3.90 cm, Left kidney measure: 10.88 x 3.43cm

Both the kidneys appear normal in size, shape and echogenicity. Both the pelvicalyceal system is normal and both corticomedullary differentiations are well maintained. There is no obvious focal or diffuse lesion noted.

No evidence of any calculus seen in either kidney.

URINARY BLADDER

The urinary bladder shows anechoic contents. Its wall thickness appears normal.

Pre void volume = 412cc. No significant post void residue.

PROSTATE


Prostate measures: 4.73 x 3.01 x 3.98 cm. Volume = 43cc

The Prostate appears normal and shows a normal echogenicity.

No evidence of calcification is seen.

There is no obvious evidence of abdominal or pelvic lymphadenopathy or ascites noted.

IMPRESSION: No significant abnormality is detected.

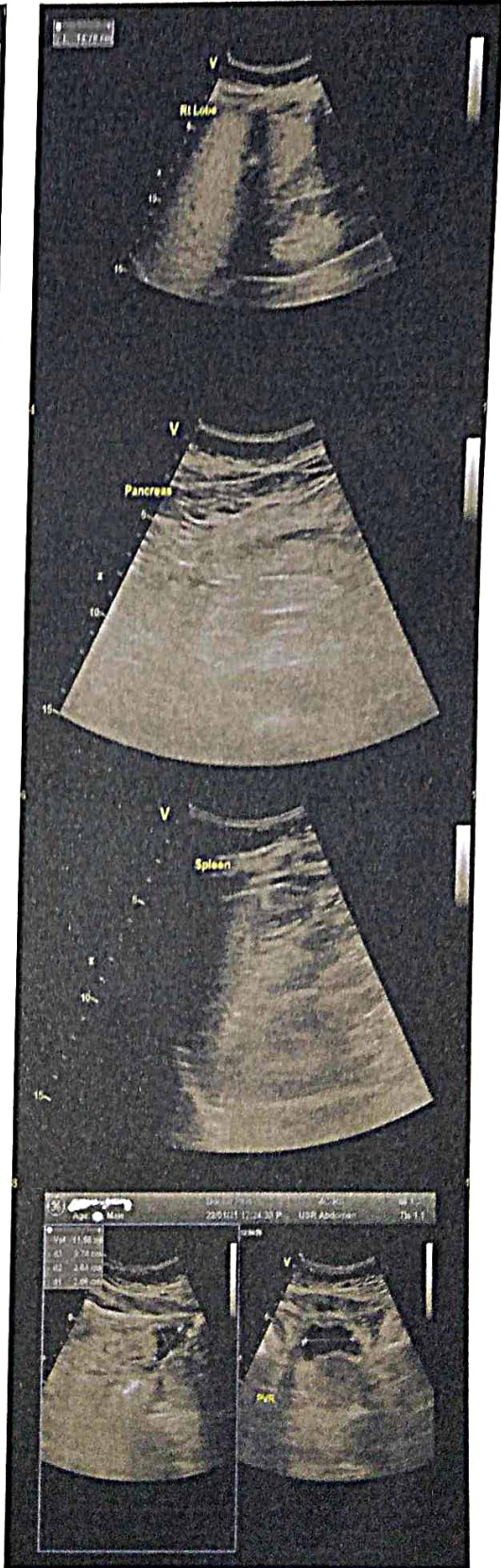
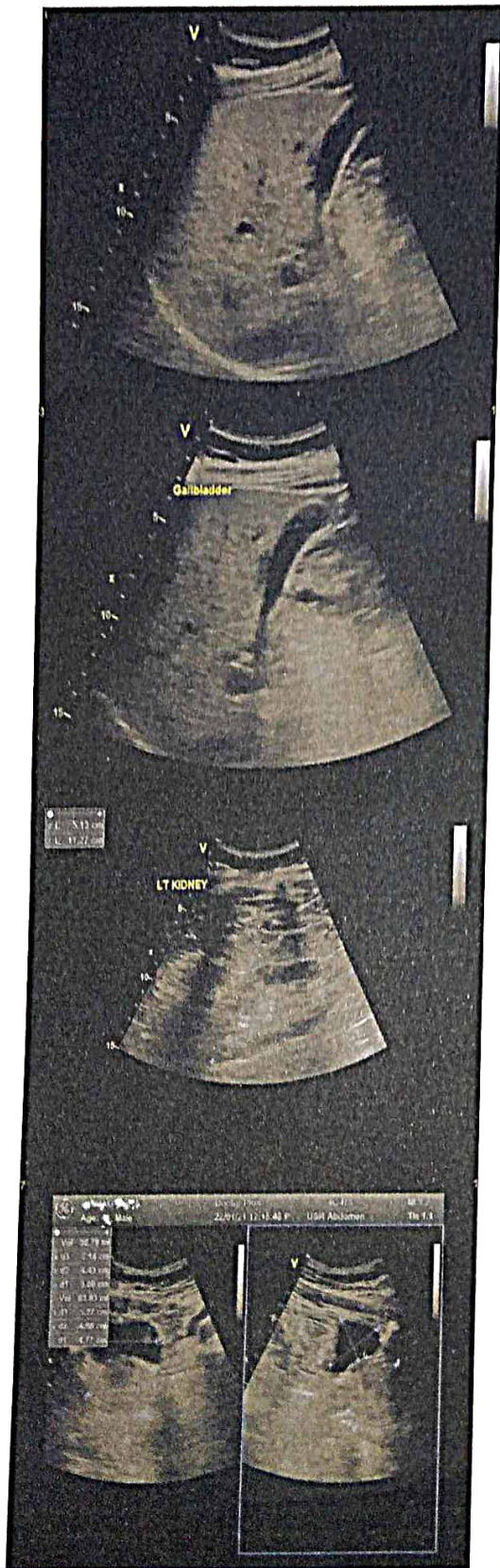
Dr. Parag Jhaveri
MBBS (BOM), DMRE(BOM)
Radio-Sonologist

DR. PLUS HEALTHCARE CENTRE
NATHANI HEIGHTS', B-WING
42, MUMBAI CENTRAL (EAST)

Name **SUNNY CHAWLA**

Sex **Male**

Age **39**





Dr-Plus Healthcare Centre

NATHANI HEIGHTS, B-Wing, Shop No. 42, Ground Floor, Opp. Mumbai Central Station (East), Mumbai - 400 008.

Patient's Name : SUNNY CHAWLA

Report Date : 28/08/2021

Referred By Dr. : SELF

Age : 39 Years

Sex : MALE

X- RAY CHEST

THE HILAR SHADOWS APPEAR NORMAL.

THE COSTO -PHRENIC ANGLES ARE CLEAR.

THE CARDIAC SHADOWS APPEAR NORMAL.

THE TRACHIA IS CENTRAL IN POSITION.

THE BONY CAGE APPEARS NORMAL.


Radiologist

DR. A. J. MAZUMDAR

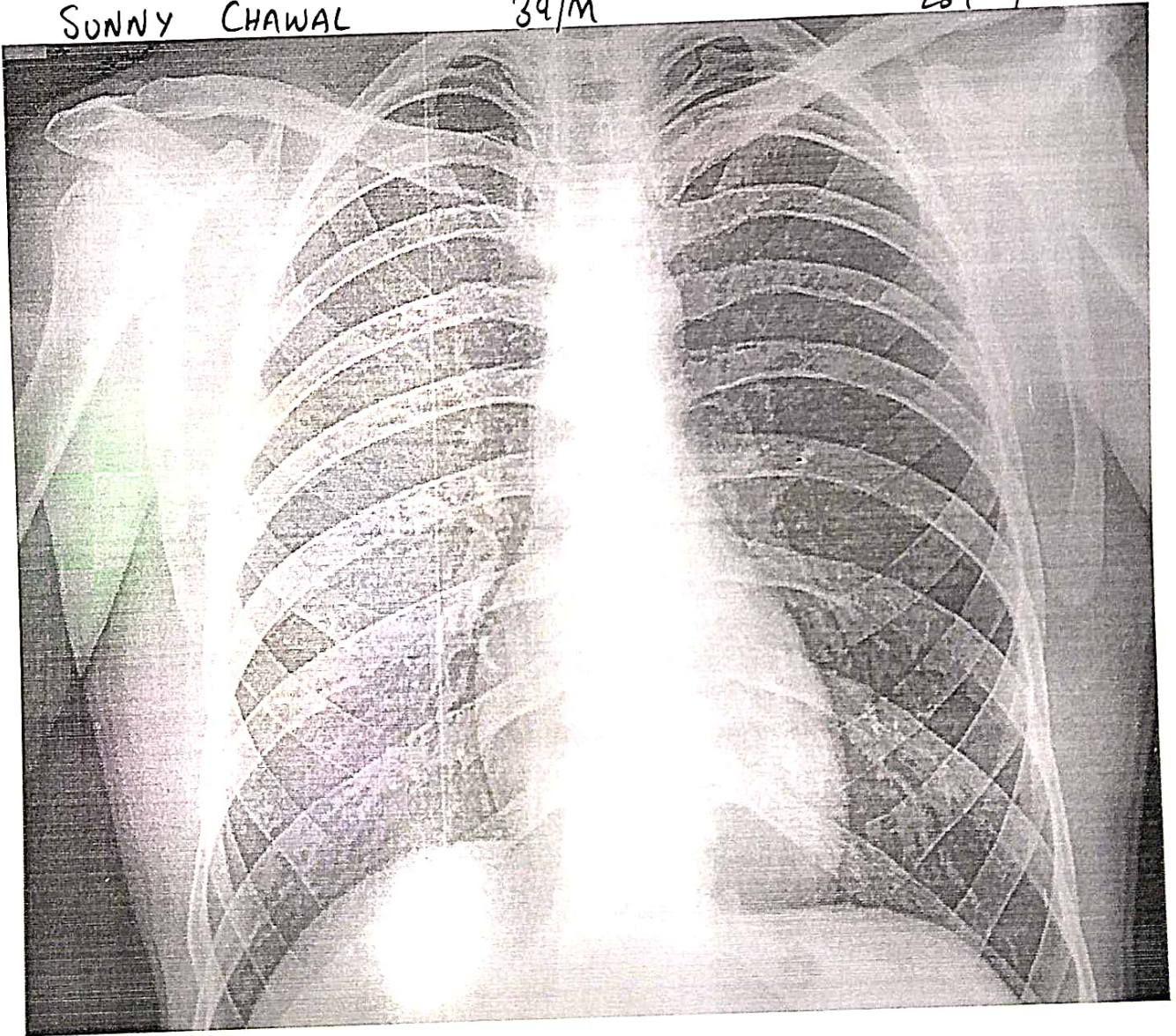
MD. DMRE, MDRD

"DR. PLUS HEALTHCARE CENTRE"
NATHANI HEIGHTS', B-WING,
42, MUMBAI CENTRAL (EAST)

SUNNY CHAWAL

39/M

28/08/24





Dr-Plus Healthcare Centre

NATHANI HEIGHTS, B-Wing, Shop No. 42, Ground Floor, Opp. Mumbai Central Station (East), Mumbai - 400 008.

Full Name of life to be assured:

SUNNY CHAWLA

39/M

DATE:28/08/2021

HAEMOGRAM

Normal Range

1.	Red Blood Cell Count	4.8	[M : 4.5 - 5.6 / F : 3.5 - 5.5/cu.mm]
2.	Hb%	17.1	[M: 14-18 / F : 11-16 gm%]
3.	Hematocrit	48	[M : 40-53 / F : 30-47 %]
4.	Indices:		
(a)	MCV(Mean Corpuscular Volume)	91	[79-101 cu.mi.]
(b)	MCH(Mean Corpuscular Hb)	31	[27-32 pg]
(c)	MCHC(Mean Corpuscular Hb Concentration)	37	[32-38%]
5.	Morphology		
	Macrocytes :	--	Microcytes: -- Hypochromia: --
	Poikilocytosis:	--	Anisocytosis: --
6.	Target cells:	--	
	Spherocytes:	--	Elliptocytes: --
7.	TOTALW.B.C.Count	8,700	{4000-11000/cu.mm}
Differential Count0			
a)	Neutrophils :	64	[45 -70%] c) Eosinophils: 04 [01 - 06%]
b)	Lymphocytes :	28	[20 - 45%] d) Monocytes: 03 [00 - 08%]
e)	Basophils :	01	[00 - 01%]
8.	Platelets :4.2	1.5-4.5 Lacks/cu.mm	
9.	Erythrocyte Sedimentation Rate:14	20 mm at end of 1 hour	Method : Westergrens

ROUTINE URINE EXAMINATION (RUA)

1. Physical Examination:

(i)	Colour:	PLAN YELLOW	(ii)	Sediment:	CLEAR
(iii)	Transparency:	ABSENT	(iv)	Reaction:	ACIDIC
(v)	Specific gravity	1.015			

2. Chemical Examination:

(i)	Protein :	ABSENT	(ii)	Sugar:	ABSENT
(iii)	Bile salt:	ABSENT	(iv)	Bile pigment:	ABSENT

3. Microscopic Examination:

(i)	Red Blood Cells:	ABSENT	(ii)	Epithelial Cells:	ABSENT
(iii)	Crystals:	ABSENT	(iv)	Pus Cells:	02 TO 03/HPF
(v)	Casts:	ABSENT	(vi)	Deposits:	ABSENT
(vii)	Bacteria's :	ABSENT			

DR. RAJESH PATKAR
M.D., D.N.B. (Pathology)
Reg. No. 2013/05/1669



Dr-Plus Healthcare Centre

NATHANI HEIGHTS, B-Wing, Shop No. 42, Ground Floor, Opp. Mumbai Central Station (East), Mumbai - 400 008.

Full Name: SUNNY CHAWLA 39/M 28/08/2021
Life to be assured:

	Type of Test	Actual Reading	Normal Range
1	Fasting Blood Sugar	92	70-100 mg%
2	PPBS	135	110 TO 140 mg%
3	Total Cholesterol	189	120-200 mg%
4	VERY LOW DENSINTY LEVEL(VLDL)	26	10-30 mg/dl
5	High Density Lipid (HDL)	47	40-60 mg%
6	Low Density Lipid (LDL)	143	Upto 150
7	S. Triglycerides	129	50-150 mg%
8	CHOL/HDL	4.0	Upto 5
9	HDL/LDL	0.3	
10	S. Creatinine	0.8	0.5-1.2 mg%
11	Blood Urea Nitrogen (BUN)	16	7-21 mg%
12	BUN/CREAT RATIO	20	
13	S. Proteins	7.5	6.0-7.9 mg%
14	(a) Albumin	4.2	3.5-5.5 mg%
15	(b) Globulin	3.3	2.0-3.5 mg%
16	A/G RATIO	1.2	
17	S. Bilirubin	0.8	0.3-1.3mg%
18	(a) Direct	0.5	0.0-0.8 mg%
19	(b) Indirect	0.3	0.0-0.5 mg%
20	SGOT (AST)	28	05-34 IU
21	SGPT (ALT)	34	05-40 IU
22	GGTP (GGT)	43	05-50 IU
23	SGOT/SGPT	0.8	
24	HBA1C	5.1	UPTO 6.5
25	S. Alkaline Phosphatase	93	30-115 IU
26	T3	116	80-180ng/dl
27	T4	11.3	4.6-12 ug/dl
28	TSH	3.7	0.4-4.0 mIU/L
29	SERUM URIC ACID	5.0	2.5-7.2mg/dl
30	URINE SUGAR PP	ABSENT	
31	URINE SUGAR FASTING	ABSENT	
32	BLOOD GROUP	"A"POSITIVE"	

DR. RAKESH PATKAR
M.D., D.N.B. (Pathology)
Reg. No. 2013/05/1660

