



Mittal Hospital

ਮਿੱਤਲ ਹਸਪਤਾਲ

For Appointment PH: 01679-237777
For Emergency M: 99142-16070
mittal_parshant@yahoo.com

ਡਾ. ਪ੍ਰਸ਼ਾਂਤ ਮਿੱਤਲ

ਐਮ.ਡੀ. ਮੈਡੀਸਨ (ਡੀ.ਐਮ.ਸੀ. ਲੁਧਿਆਣਾ)
ਐਕਸ ਮੈਡੀਕਲ ਅਫਸਰ, ਸਿਵਲ ਹਸਪਤਾਲ, ਬਰਨਾਲਾ
ਐਕਸ ਸੀਨੀਅਰ ਰਜਿਸਟਰਾਰ, ਫੋਰਟੀਜ਼ ਹਸਪਤਾਲ, ਮੁਹਾਲੀ
ਐਕਸ ਸਪੈਸ਼ਲਿਸਟ, ਰਾਧਾ ਸੁਆਮੀ ਹਸਪਤਾਲ, ਬਿਆਸ
(ਦਿਲ, ਪੇਟ, ਫਾਤੀ, ਸ਼ੂਗਰ ਅਤੇ ਕਾਲੇ ਪੀਲੀਏ ਦੇ ਮਾਹਿਰ)
PMC Regd. No. 37514

ਨੇੜੇ ਪਨਸਪ ਗੈਸ ਏਜੰਸੀ, ਨੇੜੇ ਆਰੀਆ ਮਹਿਲਾ ਕਾਲਜ, ਰਾਮ ਬਾਗ ਰੋਡ, ਬਰਨਾਲਾ

Near Pansup Gas Agency, Near LBS College,
Ram Bagh Road, BARNALA-148101 (Pb.)

ਡਾ: ਪ੍ਰੀਆ ਗਰਗ

ਐਮ.ਡੀ. ਐਨਸਥੀਜ਼ੀਆ (ਡੀ.ਐਮ.ਸੀ. ਲੁਧਿਆਣਾ)
ਐਕਸ ਸੀਨੀਅਰ ਰਜਿਸਟਰਾਰ ਡੀ ਐਮ ਸੀ, ਲੁਧਿਆਣਾ
ਐਕਸ ਸੀਨੀਅਰ ਰਜਿਸਟਰਾਰ ਪੀ ਜੀ ਆਈ, ਚੰਡੀਗੜ੍ਹ
ਐਕਸ ਕਨਸਲਟੈਂਟ ਰਾਧਾ ਸੁਆਮੀ ਹਸਪਤਾਲ, ਬਿਆਸ
(ਆਈ.ਸੀ.ਯੂ. ਅਤੇ ਕਰੀਟੀਕਲ ਕੇਅਰ ਸਪੈਸ਼ਲਿਸਟ)
PMC Regd. No. 36677

Name..... Age..... Sex..... Dated.....

Name- AYINA

Age/sex - 30/F

Ref by: Dr. PARSHANT MITTAL

Date-February 11, 2023

USG WHOLE ABDOMEN

Liver- is normal in size (12.3 cm), shape, position and echotexture. No obvious focal lesion is seen. Intrahepatic biliary radicals are not dilated. Portal vein is normal in course and caliber.

Gall Bladder is normally distended. Wall thickness is normal. No evidence of calculus.

Common bile duct is normal in course and caliber.

Pancreas is normal in size and echotexture. Main pancreatic duct is not dilated.

Right Kidney is normal in size, position and echotexture. Corticomedullary differentiation maintained. No evidence of calculus/ hydronephrosis.

Left Kidney is normal in size, position and echotexture. Corticomedullary differentiation maintained. No evidence of calculus/ hydronephrosis.

Spleen is normal in size, shape and echotexture. Splenic vein is normal in caliber.

Urinary bladder is distended. Wall thickness is normal. No evidence of calculus.

No e/o free fluid in peritoneal cavity.

IMPRESSION- USG abdomen reveals- Normal study

Kindly correlate clinically/Lab parameters (CBC, Urine C/E).

DR. PARSHANT MITTAL

M. D. MEDICINE

Dr. Parshant Mittal
M.D. Medicine
PMC Regd. No. 37514
Mittal Hospital, Barnala



Mittal Hospital

For Appointment PH: 01679-237777
For Emergency M: 99142-16070
mittal_parshant@yahoo.com

ਮਿੱਤਲ ਹਸਪਤਾਲ

ਡਾ. ਪ੍ਰਸ਼ਾਂਤ ਮਿੱਤਲ

ਨੇੜੇ ਪਨਸਪ ਗੈਸ ਏਜੰਸੀ, ਨੇੜੇ ਆਰੀਆ ਮਹਿਲਾ ਕਾਲਜ, ਰਾਮ ਬਾਗ ਰੋਡ, ਬਰਨਾਲਾ

Near Pansup Gas Agency, Near LBS College,
Ram Bagh Road, BARNALA-148101 (Pb.)

ਐਮ.ਡੀ. ਸੇਡੀਸਨ (ਡੀ.ਐਮ.ਸੀ. ਲੁਧਿਆਣਾ)
ਐਕਸ ਮੈਡੀਕਲ ਅਫਸਰ, ਸਿਵਲ ਹਸਪਤਾਲ, ਬਰਨਾਲਾ
ਐਕਸ ਸੀਨੀਅਰ ਰਜਿਸਟਰਾਰ, ਫੋਰਟੀਜ਼ ਹਸਪਤਾਲ, ਮੁਹਾਲੀ
ਐਕਸ ਸਪੈਸ਼ਲਿਸਟ, ਰਾਧਾ ਸੁਆਮੀ ਹਸਪਤਾਲ, ਬਿਆਸ
(ਦਿਲ, ਪੇਟ, ਛਾਤੀ, ਸ਼ੂਗਰ ਅਤੇ ਕਾਲੇ ਪੀਲੀਏ ਦੇ ਮਾਹਿਰ)
PMC Regd. No. 37514

ਡਾ: ਪ੍ਰੀਆ ਗਰਗ

ਐਮ.ਡੀ. ਐਨਸਥੀਜ਼ੀਆ (ਡੀ.ਐਮ.ਸੀ. ਲੁਧਿਆਣਾ)
ਐਕਸ ਸੀਨੀਅਰ ਰਜਿਸਟਰਾਰ ਡੀ ਐਮ ਸੀ, ਲੁਧਿਆਣਾ
ਐਕਸ ਸੀਨੀਅਰ ਰਜਿਸਟਰਾਰ ਪੀ ਜੀ ਆਈ, ਚੰਡੀਗੜ੍ਹ
ਐਕਸ ਕਨਸਲਟੈਂਟ ਰਾਧਾ ਸੁਆਮੀ ਹਸਪਤਾਲ, ਬਿਆਸ
(ਆਈ.ਸੀ.ਯੂ. ਅਤੇ ਕਰੀਟੀਕਲ ਕੇਅਰ ਸਪੈਸ਼ਲਿਸਟ)
PMC Regd. No. 36677

Name.....Age.....Sex.....Dated.....

X-RAY REPORT

Name: AYINA

30/F

Date: 11/02/23

Dr.: PARSHANT MITTAL

X- Ray Report: Chest pa view:

Both CP angles are clear.

Bony cage and ribs are unremarkable.

Trachea is central.

Cardiac silhouette and size are normal.

Lungs show normal parenchyma with no other active lesion.

No scar mark present.

No other abnormality seen.

DR. PARSHANT MITTAL
M. D. MEDICINE

Dr. Parshant Mittal
M.D. Medicine
PMC Regd. No. 37514
Mittal Hospital, Baraala



MITTAL HOSPITAL

Near Pansup Gas Agency, Near LBS College, Ram Bagh Road, BARNALA-148101 (Pb.)

For Appointment
Ft 01679-237777

For Emergency
Mt 99142-16070

Dr. Parshant Mittal

mittal_parshant@yahoo.com

Dr. Priya Garg

M.D. Medicine (D.M.C. Ludhiana)
Ex. Medical Officer, Civil Hospital, Barnala
Ex. Sen. Registrar, Fortis Hospital, Mohali
Ex. Specialist, Radha Soami Hospital, Beas
PMC Regd. No. 37514

M.D. Anaesthesiology
Consultant Anaesthesiology
Ex. Registrar DMC, Ludhiana
Ex. Sr. Registrar PGI, Chandigarh
Ex. Consultant Radha Soami Hospital, Beas
PMC Regd. No. 36677

ECHOCARDIOGRAPHY REPORT

Name: AYINA

Date: 11.02.2023

AGE: 30 YEARS

Sex: FEMALE

Done by: Dr. Parshant Mittal

	<u>MEASUREMENT</u>	<u>NORMAL ADULT VALUES</u>
	AORTIC ROOT : 23.6	(22 – 37 mm)
	LEFT ATRIUM : 32.1	(20 – 40 mm)
	RVID (D) : 07.9	(10 – 20 mm)
	IVST (D) : 07.1	(07 – 11 mm)
	IVST (S) : 09.3	(07 – 11 mm)
	LVID (D) : 39.3	(35 – 55 mm)
	LVID (S) : 24.3	(25 – 42 mm)
	LVPW (D) : 08.6	(07 – 11 mm)
	LVPW (S) : 10.0	(07 – 11 mm)
	<u>L.V. FUNCTION</u>	
EJECTION FRACTION	: 72.30%	(50 – 80%) (mod. simpson)
FRACTIONAL SHORTENING	: 38.18%	(28 – 40%)

Mitral Valve : Thin, opens normally. No regurgitation present.
MVA=3.78cm², EPSS=0.50, MAPSE=11mm. "E" wave more than "A".
E/A ratio=1.58

Aortic Valve : Thin, tricuspid, opens normally.
No aortic regurgitation present.

Tricuspid Valve : Thin, opens normally.
No tricuspid regurgitation present.

Pulmonary Valve : Thin, opens normally.

Pericardium : No pericardial effusion present.

Wall Motion Abnormalities: No regional wall motion abnormalities present.

Cardiac Chambers : All the cardiac chambers are normal in size.

DOPPLER EVALUATION

VELOCITY (GRADIENT)		(GRADE)
MV : E=83 A=53	cm/sec.	MR : NIL
AV : 140	cm/sec.	AR : NIL
TV :	cm/sec.	TR : NIL
PV :	cm/sec	PR : NIL

> **NO REGIONAL WALL MOTION ABNORMALITIES PRESENT WITH NORMAL LV SYSTOLIC FUNCTION (EF=72.30%).**

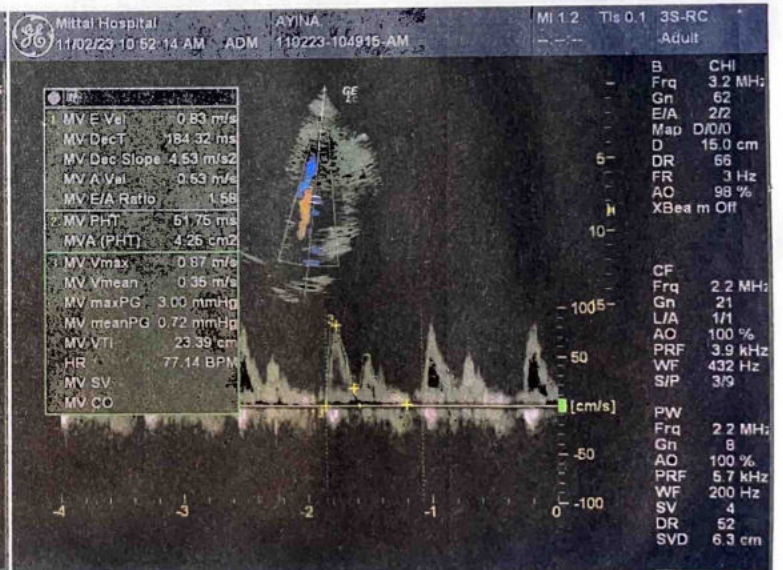
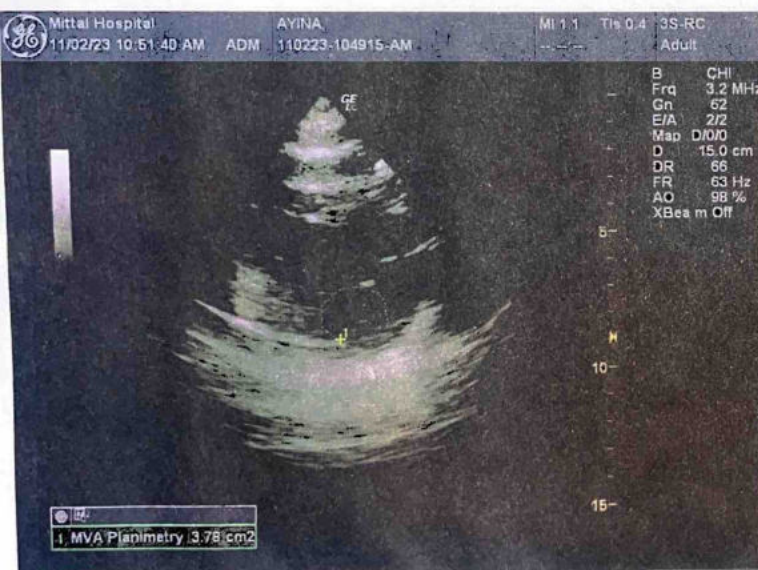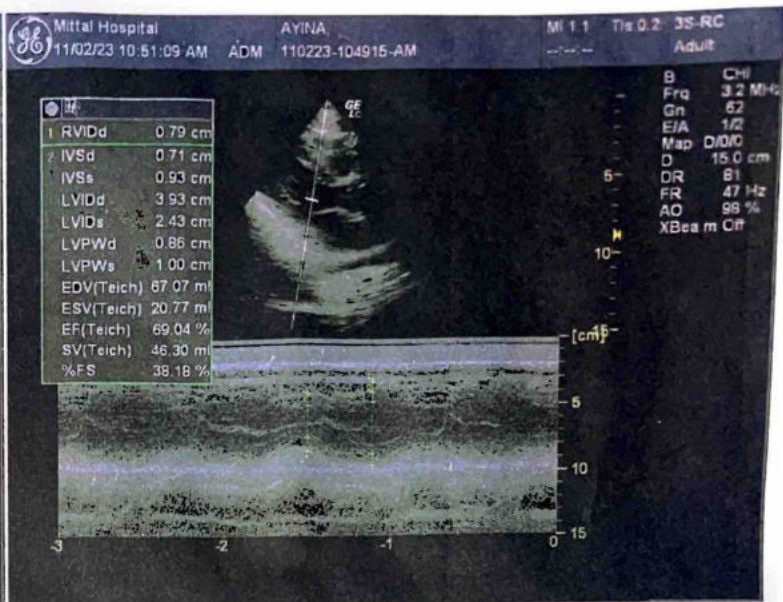
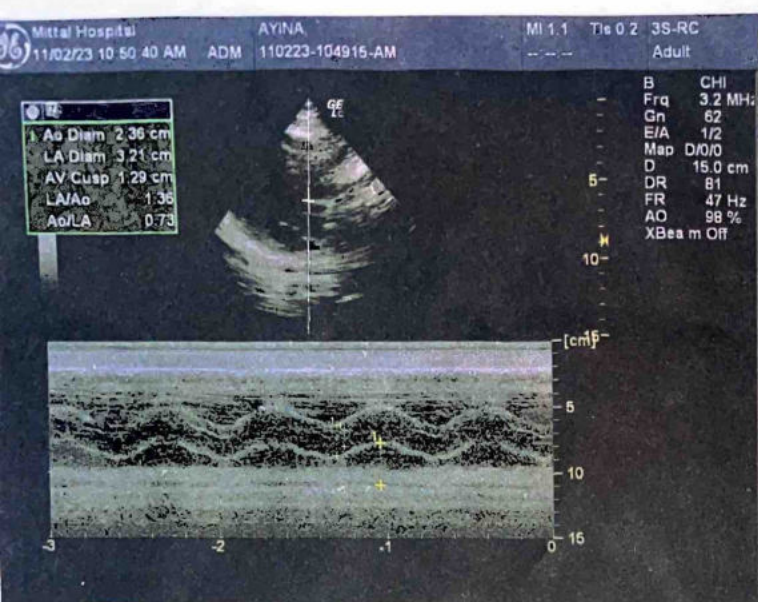


DR. PARSHANT MITTAL

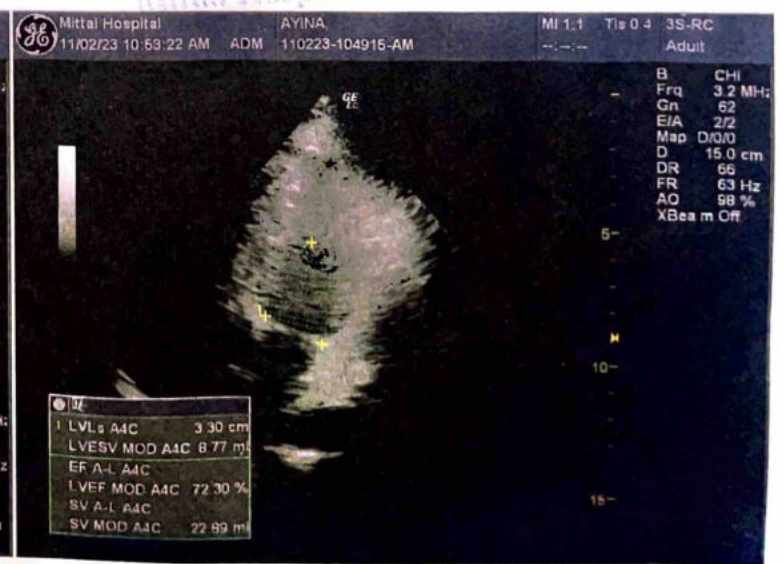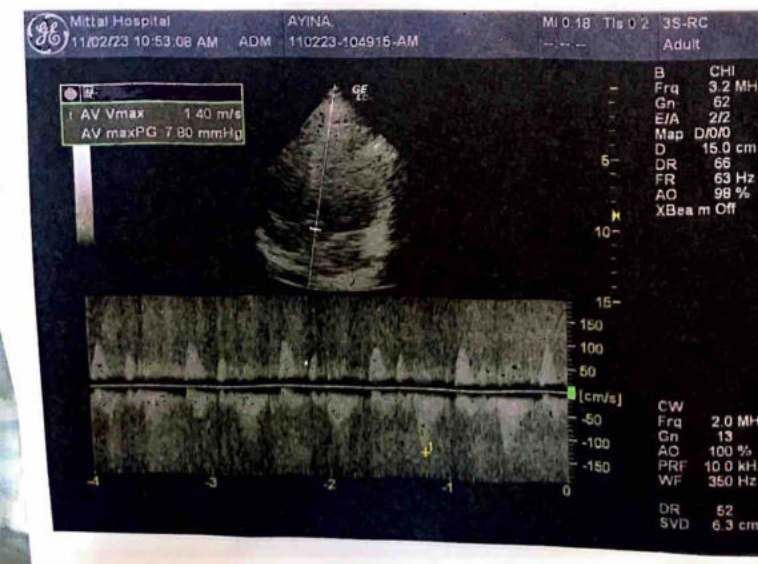
MITTAL HOSPITAL, BARNALA
MD (MEDICINE)

Not valid for Medico Legal Purpose

Dr. Parshant Mittal
M.D. Medicine
PMC Regd. No. 37514
Mittal Hospital, Barnala



Dr. Parshant Mittal
M.D. Medicine
PMC Regd. No. 12345
Mittal Hospital, Barwala





Mittal Hospital

ਮਿੱਤਲ ਹਸਪਤਾਲ

For Appointment PH: 01679-237777
For Emergency M: 99142-16070
mittal_parshant@yahoo.com

ਨੇੜੇ ਪਨਸਪ ਗੈਸ ਏਜੰਸੀ, ਨੇੜੇ ਆਰੀਆ ਮਹਿਲਾ ਕਾਲਜ, ਰਾਮ ਬਾਗ ਰੋਡ, ਬਰਨਾਲਾ

ਡਾ. ਪ੍ਰਸ਼ਾਂਤ ਮਿੱਤਲ

Near Pansup Gas Agency, Near LBS College,
Ram Bagh Road, BARNALA-148101 (Pb.)

ਐਮ.ਡੀ. ਮੈਡੀਸਨ (ਡੀ.ਐਮ.ਸੀ. ਲੁਧਿਆਣਾ)
ਐਕਸ ਮੈਡੀਕਲ ਅਫਸਰ, ਸਿਵਲ ਹਸਪਤਾਲ, ਬਰਨਾਲਾ
ਐਕਸ ਸੀਨੀਅਰ ਰਜਿਸਟਰਾਰ, ਫੋਰਟੀਜ਼ ਹਸਪਤਾਲ, ਮੁਹਾਲੀ
ਐਕਸ ਸਪੈਸ਼ਲਿਸਟ, ਰਾਧਾ ਸੁਆਮੀ ਹਸਪਤਾਲ, ਬਿਆਸ
(ਦਿਲ, ਪੇਟ, ਛਾਤੀ, ਸ਼ੂਗਰ ਅਤੇ ਕਾਲੇ ਪੀਲੀਏ ਦੇ ਮਾਹਿਰ)
PMC Regd. No. 37514

ਡਾ: ਪ੍ਰੀਆ ਗਰਗ

ਐਮ.ਡੀ. ਐਨਸਥੀਜ਼ੀਆ (ਡੀ.ਐਮ.ਸੀ. ਲੁਧਿਆਣਾ)
ਐਕਸ ਸੀਨੀਅਰ ਰਜਿਸਟਰਾਰ ਡੀ ਐਮ ਸੀ, ਲੁਧਿਆਣਾ
ਐਕਸ ਸੀਨੀਅਰ ਰਜਿਸਟਰਾਰ ਪੀ ਜੀ ਆਈ, ਚੰਡੀਗੜ੍ਹ
ਐਕਸ ਕਨਸਲਟੈਂਟ ਰਾਧਾ ਸੁਆਮੀ ਹਸਪਤਾਲ, ਬਿਆਸ
(ਆਈ.ਸੀ.ਯੂ. ਅਤੇ ਕਰੀਟੀਕਲ ਕੇਅਰ ਸਪੈਸ਼ਲਿਸਟ)
PMC Regd. No. 36677

Name..... Age..... Sex..... Dated.....

PAP SMEAR

NAME : AIYNA 30/F

DATE : 11 - 02 - 2023

REF.BY.: DR. PARSHANT MITTAL

CYTOLOGY:

Cells present: Satisfactory

Hormonal evaluation: Normal

Inflammation: None

Smear characteristics: Negative for malignant cells; cells appear normal

Sawan

DR. SAWAN KUMAR
M. D. PATHOLOGY

Dr. Sawan Kumar
M.D. Pathology
Reg. No. 45679

MITTAL COMPUTERISED LAB.

Inside Mittal Hospital, BARNALA-148101

Patient's Name AYINA 30/F Ref. By Dr. PARSHANT MITTAL Dated 11-02-2023

HEMATOLOGY

TEST	RESULT	NORMAL RANGE
Haemoglobin	12.1 gm/dl	Male 12.0-15.5 gm/dl Female 10-13.5 gm/dl
T.L.C.	5300 /cumm	4000-11000/cumm
D.L.C. (Different Leucocyte Count)		
Neutrophils	49 %	40-75%
Lymphocytes	41 %	20-45%
Eosinophils	03 %	1-6%
Monocytes	07 %	2-10%
Basophils	00 %	0-1%
MCV	86	80-99 fL
MCH	27	26-32 pg
MCHC	33	32-36 gm/dl
RDW	39	37-54 fL
Hematocrit	44	37-52
ESR (Westergreen)	05 mm. 1st Hr.	Male upto 10mm. 1st Hour. Female upto 20mm. 1st Hour.
Platelet Count	239000 /cumm.	1,50000-4,00000/cu.mm.
T Eosinophil Count	/Cumm	40-440 Cell/cumm
Total RBC COUNT	5.3	4.7-6.2 to 10 ⁶ /µl

SEROLOGY

Widal Test	1:20	1:40	1:80	1:160	1:320	1:640
S. Typhi O	-	-	-	-	-	-
S. Typhi H	-	-	-	-	-	-
S. Paratyphi AH	-	-	-	-	-	-
S. Paratyphi BH	-	-	-	-	-	-
Dengue NS1						
Dengue IgM/IgG						
TSH:	4.62	(0.550-4.780 uIU/ml)				
S. T4 LEVEL:	94.4	(77-155 nmol/l)				
S. T3 LEVEL:	2.61	(0.3-4 mU/l)				
S. Vitamin D LEVEL:		(30-100 ng/mL)				

URINE EXAMINATION

ROUTINE EXAMINATION	
Appearance :	CLEAR
Colour :	STRAW
Sp. Gravity :	1.005
Reaction :	ACIDIC
Albumin :	NIL
Sugar :	NIL
Bile Salts:	NIL
Bile Pigments :	NIL
MICROSCOPIC EXAMINATION	
RBC	NIL
Pus Cells	0-1/hpf
Epithelial Cells	0-2/hpf
Calcium Oxalate	NIL
Spermatozoa	
URINE FOR MICROALBUMIN :	(0.00-25.0 mg/l)
URINE FOR NICOTINE:	(<5ng/ml)

BIO-CHEMISTRY

TEST	RESULT	NORMAL RANGE
Blood Sugar Fasting	83 mg/dl.	80-120 mg/dl.
Blood Sugar PP/Random	92 Mg/dl.	Upto 140 mg/dl.
Blood Urea Nitrogen	12 Mg/dl.	10-20 mg/dl.
S. Creatinine	0.6 mg/dl.	0.8-1.4 gm/dl.
S. Uric Acid	mg/dl.	Male 2-5 mg/dl. Female 2-4.5 mg/dl.
Blood Group	A	

LIVER FUNCTION TEST

S. Bilirubin (Total)	0.51 mg/dl.	0.2-1.0 mg/dl.
Conjugated	0.24	0.1-0.4 mg/dl
Unconjugated	0.27	0.1-0.6 mg/dl
S. Alkaline Phosphatase	69 U/L	37-147U/L
S.G.O.T.	16 U/L	10-40 Units/ml
S.G.P.T.	19 U/L	10-35 Units/ml
G.G.T.P	15	0-40 U/L
AUSTRALIA ANTIGEN		(HbsAg) Test
HBeAg		
Total Serum Proteins	7.3 gm/dl.	6.0-8.0 gm/dl.
Albumin	4.2 Gm/dl.	3.5-5.0 gm/dl.
Globulin	3.1 gm/dl.	2.0-3.5 gm/dl
S. Lipase	U/L	20-85 U/L
S. Amylase	U/L	25-80 U/L

LIPIDOGRAM

S. Cholesterol	129 mg/dl.	130-240 mg/dl.
S. Triglycerides	86 mg/dl.	60-170 mg/dl.
S. HDL Cholesterol	47 mg/dl.	30-60 mg/dl.
S. LDL Cholesterol	79 Mg/dl.	Upto 150 mg/dl
S. VLDL Cholesterol	28 Mg/dl.	Upto 45 mg/dl.

ELECTROLYTES TEST

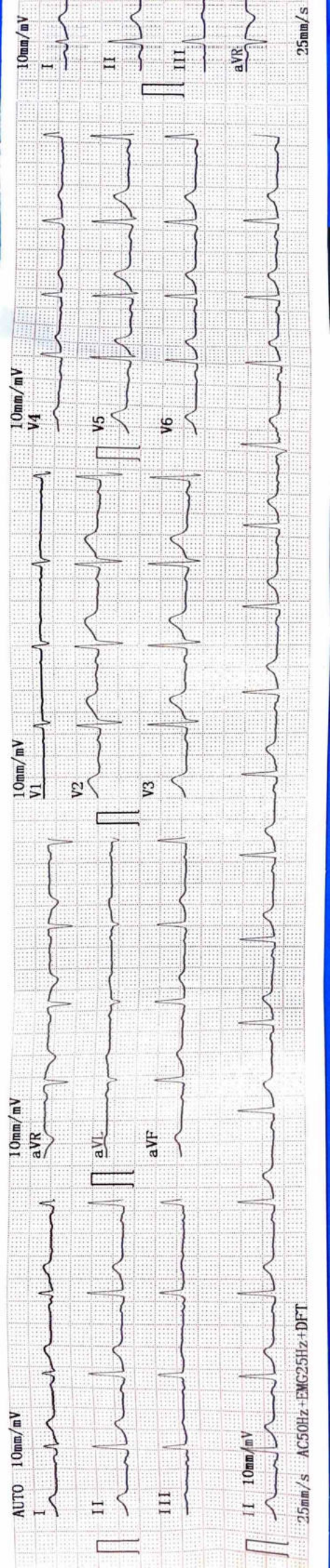
S. Chloride	mmol/L.	96-106 mmol/L.
S. Sodium	Mmol/L	135-155 mmol/L
S. Potassium	mmol/L	3.5-5.5 mmol/L

GLYCOSYLATED HEMOGLOBIN (HbA1c)

Reference Range	4.0 - 6.0 %	5.1 %
Good Diabetic Control	6.0 - 7.0 %	
Fair Control	7.0 - 8.0 %	
Poor Control	Above 8.0 %	
HbA1C test Value in %	Mean Plasma Glucose Level	
12.0	345	
11.0	310	
10.0	275	
9.0	240	
8.0	205	
7.0	170	
6.0	135	
5.0	100	

Medical Technologist

Dr. Sawan Kumar
M.D. Pathology
Reg. No. 45679



<< Conclusions >>

Normal Sinus Rhythm
Normal Cardiac Electric
V4 Abnormal T wave

**Report need physician co

Normal ECG

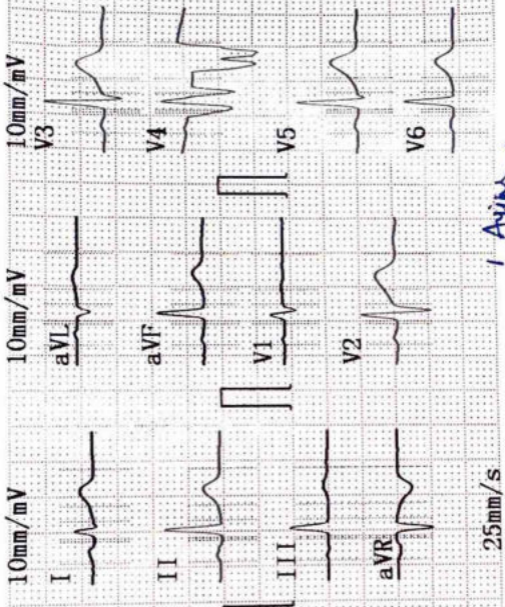
DR. PAUL JAYAL M.D.
FAMILY MEDICINE
No. 357
MITTAL Hospital, Barnala

PHYSICIAN

MITTAL HOSPITAL
1970-06-18 18:32

ID: _____
Name: AYINA
Sex: F Age: 30 kg
Height: _____ cm
Weight: _____ kg
SYS: _____ mmHg
DIA: _____ mmHg

HR [bpm] : 87
PR Interval [ms] : 140
P Duration [ms] : 122
QRS Duration [ms] : 100
T Duration [ms] : 210
QT/QTc [ms] : 395/478
P/QRS/T Axis [deg] : 32.3/73.1/42.7
R(V5)/S(V1) [mV] : 0.89/0.16
R(V5)+S(V1) [mV] : 1.05



1 Ayina

25mm/s

