



PRE – EMPLOYMENT HEALTH CHECK UP REPORT

DATE - 22/8/22

PATIENT NAME - Mr KumbhKaram AGE - 55Yr GENDER - M

WEIGHT(KG)- HEIGHT - 170 cm

PHYSICAL EXAMINATION

PULSE

BP 130/90

BLOOD SUGAR(RANDOM)

FINDINGS

INVESTIGATIONS : Investigation reports are attached

FITNESS CERTIFICATE

Ad.

HBALC



SIGNATURE

[Handwritten Signature]
24/8/2022

(This is only professional opinion and not the diagnosis, Please correlate clinically)

Q Block South City 11, Sohna Road, Main Sector-47, Gurgaon, Haryana
Ph.: 0124-4900000 (100 Lines) Fax : 0124-2218733 E-mail : parkmedicenters@gmail.com

PARK GROUP OF HOSPITALS : West Delhi • South Delhi • Gurgaon • Karnal • Panipat • Hodal • Ambala • Behror

the **health** care providers

the **health** care providers





DEPARTMENT OF PATHOLOGY

Patient Name : Mr. KUMBHKARAN
MR No : 659230
Age/Sex : 58 Years / Male
Type : OPD
TPA/Corporate : MEDIWHEEL PVT LTD

Bill Date : 22/08/2022
Reporting Date : 22/08/2022
Sample ID : 31776
Bill/Req. No. : 22946054
Ref Doctor : Dr.RMO

Test	Result	Bio. Ref. Interval	Units
KFT (RENAL PROFILE)			
KFT			
SERUM UREA	27	10 - 45	mg/dL
SERUM CREATININE	1.3	0.4 - 1.4	mg/dL
SERUM URIC ACID	2.9	2.5 - 7.0	mg/dL
SERUM SODIUM	137	136 - 145	meq/l
SERUM POTASSIUM	4.7	3.5 - 5.5	meq/l
SERUM CALCIUM	9.1	8.5 - 10.5	mg/dL
SERUM PHOSPHORUS	2.7	2.5 - 4.5	mg/dL

***** END OF THE REPORT *****



Sample no.

Dr.NALANDA BUKTARE
MD (Pathology)

Dr.PRADIP KUMAR
Consultant (Microbiology)

Dr.BHAVANA CHAUHAN
MBBS, MD (Microbiology)

USER NM : AMIT

(This is only professional opinion and not the diagnosis, Please correlate clinically)

Q Block South City 11, Sohna Road, Main Sector-47, Gurgaon, Haryana
Ph.: 0124-4900000 (100 Lines) Fax : 0124-2218733 E-mail : parkmedicenters@gmail.com

PARK GROUP OF HOSPITALS : West Delhi • South Delhi • Gurgaon • Karnal • Panipat • Hodal • Ambala • Behror

the **health** care providers

the **health** care providers





DEPARTMENT OF PATHOLOGY

Patient Name : Mr. KUMBHKARAN
MR No : 659230
Age/Sex : 58 Years / Male
Type : OPD
TPA/Corporate : MEDIWHEEL PVT LTD

Bill Date : 22/08/2022
Reporting Date : 22/08/2022
Sample ID : 31776
Bill/Req. No. : 22946054
Ref Doctor : Dr.RMO

Test	Result	Bio. Ref. Interval	Units
LIPID PROFILE			
LIPID PROFILE			
TOTAL CHOLESTEROL	133	0 - 250	mg/dL
SERUM TRIGLYCERIDES	130	60 - 165	mg/dl
HDL-CHOLESTEROL	51	30 - 70	mg/dl
VLDL CHOLESTEROL	26	6 - 32	mg/dL
LDL	56	50 - 135	mg/dl
LDL CHOLESTEROL/HDL RATIO	1.0	1.0 - 3.0	mg/dL
TOTAL CHOLESTEROL/HDL RATIO	2.6	2.0 - 5.0	mg/dl

***** END OF THE REPORT *****



Sample no.

Dr.NALANDA BUKTARE
MD (Pathology)

Dr.PRADIP KUMAR
Consultant (Microbiology)

Dr.BHAVANA CHAUHAN
MBBS, MD (Microbiology)

USER NM : AMIT

(This is only professional opinion and not the diagnosis, Please correlate clinically)

Q Block South City 11, Sohna Road, Main Sector-47, Gurgaon, Haryana

Ph.: 0124-4900000 (100 Lines) Fax : 0124-2218733 E-mail : parkmedicenters@gmail.com

PARK GROUP OF HOSPITALS : West Delhi • South Delhi • Gurgaon • Karnal • Panipat • Hodal • Ambala • Behror





DEPARTMENT OF PATHOLOGY

Patient Name : Mr. KUMBHKARAN
 MR No : 659230
 Age/Sex : 58 Years / Male
 Type : OPD
 TPA/Corporate : MED/WHEEL PVT LTD

Bill Date : 22/08/2022
 Reporting Date : 22/08/2022
 Sample ID : 31776
 Bill/Req. No. : 22946054
 Ref Doctor : Dr.RMO

Test	Result	Bio. Ref. Interval	Units
URINE ROUTINE AND MICROSCOPY			
PHYSICAL CHARACTERSTICS			
QUANTITY	30ml		
COLOUR	Pale Yellow	5 - 100	
TURBIDITY	Slightly Turbid	Pale Yellow	
SPECIFIC GRAVITY	1.020		
PH	6.0		
CHEMICAL EXAMINATION-1			
UROBILINOGEN	NIL	NIL	
URINE PROTEIN	NIL		mg/dl
BLOOD	NIL		
TOTAL BILIRUBIN	NIL	0.1 - 1.2	mg/dL
GLUCOSE	NIL		mg/dL
URINE KETONE	Negative	Negative	
MICRO.EXAMINATION			
PUS CELLS	2-3/hpf	NIL	
RED BLOOD CELLS	NIL	NIL	
EPITHELIAL CELLS	1-2/hpf	4-5/HPF	
CASTS	NIL	NIL	
CRYSTALS	NIL	NIL	
OTHER	NIL		

***** END OF THE REPORT *****



Sample no.

Dr.NALANDA BUKTARE
 MD (Pathology)

Dr.PRADIP KUMAR
 Consultant (Microbiology)

Dr.BHAVANA CHAUHAN
 MBBS, MD (Microbiology)

USER NM SAVITA

(This is only professional opinion and not the diagnosis, Please correlate clinically)

Q Block South City 11, Sohna Road, Main Sector-47, Gurgaon, Haryana
 Ph.: 0124-4900000 (100 Lines) Fax : 0124-2218733 E-mail : parkmedicenters@gmail.com

PARK GROUP OF HOSPITALS : West Delhi • South Delhi • Gurgaon • Karnal • Panipat • Hodal • Ambala • Behror

the health care providers

the health care providers





DEPARTMENT OF PATHOLOGY

Patient Name : Mr. KUMBHKARAN
MR No : 659230
Age/Sex : 58 Years / Male
Type : OPD
TPA/Corporate : MEDIWHEEL PVT LTD

Bill Date : 22/08/2022
Reporting Date : 22/08/2022
Sample ID : 31776
Bill/Req. No. : 22946054
Ref Doctor : Dr.RMO

Test	Result	Bio. Ref. Interval	Units
ESR (WESTERGREN)			
E.S.R.	25 H	0 - 15	mm at the end of 1st hr

***** END OF THE REPORT *****



Sample no.

Dr.NALANDA BUKTARE
MD (Pathology)

Dr.PRADIP KUMAR
Consultant (Microbiology)

Dr.NISHA TIWARI
MBBS, MD (Microbiology)

USER NM. AMIT

(This is only professional opinion and not the diagnosis, Please correlate clinically)

Q Block South City 11, Sohna Road, Main Sector-47, Gurgaon, Haryana
Ph.: 0124-4900000 (100 Lines) Fax : 0124-2218733 E-mail : parkmedicenters@gmail.com

PARK GROUP OF HOSPITALS : West Delhi • South Delhi • Gurgaon • Karnal • Panipat • Hodal • Ambala • Behror

the **health** care providers

the **health** care providers





DEPARTMENT OF PATHOLOGY

Patient Name : Mr. KUMBHKARAN
MR No : 659230
Age/Sex : 58 Years / Male
Type : OPD
TPA/Corporate : MEDIWHEEL PVT LTD

Bill Date : 22/08/2022
Reporting Date : 22/08/2022
Sample ID : 31776
Bill/Req. No. : 22946054
Ref Doctor : Dr.RMO

Test	Result	Bio. Ref. Interval	Units
CBC			
HAEMOGLOBIN	12.6	12 - 16	gms/dL
TOTAL LEUCOCYTE COUNT	6200	4000 - 10000	/ μ L
DIFFERENTIAL COUNT			
NEUTROPHILS	65	40.0 - 80.0	%
LYMPHOCYTES	25	20.0 - 40.0	%
MONOCYTES	07	2.0 - 10.0	%
EOSINOPHILS	03	0.0 - 5.0	%
BASOPHILS	00	0.0 - 2.0	%
RED BLOOD CELL COUNT	4.8	3.5 - 5.5	millions/ μ L
PACKED CELL VOLUME	38.3	35.0 - 50.0	%
MEAN CORPUSCULAR VOLUME	78.8	83 - 101	fL
MEAN CORPUSCULAR HAEMOGLOBIN	25.9	27 - 31	Picogrames
MEAN CORPUSCULAR HB CONC	32.9	33 - 37	g/dl
PLATELET COUNT	164	150 - 450	lakhs
RDW	16.3	11.6 - 13.7	%

***** END OF THE REPORT *****



Sample no.

Dr.NALANDA BUKTARE
MD (Pathology)

Dr.PRADIP KUMAR
Consultant (Microbiology)

Dr.BHAVANA CHAUHAN
MBBS, MD (Microbiology)

USER NM AMIT

(This is only professional opinion and not the diagnosis, Please correlate clinically)

Q Block South City 11, Sohna Road, Main Sector-47, Gurgaon, Haryana

Ph.: 0124-4900000 (100 Lines) Fax : 0124-2218733 E-mail : parkmedicenters@gmail.com

PARK GROUP OF HOSPITALS : West Delhi • South Delhi • Gurgaon • Karnal • Panipat • Hodal • Ambala • Behror

the health care providers

the health care providers





DEPARTMENT OF PATHOLOGY

Patient Name : Mr. KUMBHKARAN
MR No : 659230
Age/Sex : 58 Years / Male
Type : OPD
TPA/Corporate : MEDIWHEEL PVT LTD

Bill Date : 22/08/2022
Reporting Date : 22/08/2022
Sample ID : 31776
Bill/Req. No. : 22946054
Ref Doctor : Dr.RMO

Test	Result	Bio. Ref. Interval	Units
LFT (LIVER FUNCTION TEST)			
LFT			
TOTAL BILIRUBIN	1.6 H	0.1 - 1.2	mg/dL
DIRECT BILIRUBIN	0.7 H	0 - 0.4	mg/dL
INDIRECT BILIRUBIN	0.9 H	0.10 - 0.6	mg/dL
SGOT (AST)	24	0 - 45	U/L
SGPT (ALT)	20	0 - 45	U/L
ALKALINE PHOSPHATASE	64	30 - 170	IU/L
TOTAL PROTEINS	7.7	6.4 - 8.0	g/dL
ALBUMIN	4.2	3.3 - 5.5	g/dL
GLOBULIN	3.5	2.3 - 4.5	g/dL
A/G RATIO	1.2	1.1 - 2.2	

***** END OF THE REPORT *****



Sample no.

Dr.NALANDA BUKTARE
MD (Pathology)

Dr.PRADIP KUMAR
Consultant (Microbiology)

Dr.BHAVANA CHAUHAN
MBBS, MD (Microbiology)

USER NM AMIT

(This is only professional opinion and not the diagnosis, Please correlate clinically)

Q Block South City 11, Sohna Road, Main Sector-47, Gurgaon, Haryana
Ph.: 0124-4900000 (100 Lines) Fax : 0124-2218733 E-mail : parkmedicenters@gmail.com

PARK GROUP OF HOSPITALS : West Delhi • South Delhi • Gurgaon • Karnal • Panipat • Hodal • Ambala • Behror

the **health** care providers

the **health** care providers





Cert. No. MC - 4830



Cert. No. H 2016 Q169

DEPARTMENT OF PATHOLOGY

Patient Name : Mr. KUMBHKARAN
MR No : 059230
Age/Sex : 58 Years / Male
Type : OPD
TPA/Corporate : MEDIWHEEL PVT LTD

Bill Date : 22/08/2022
Reporting Date : 22/08/2022
Sample ID : 31776
Bill/Req. No. : 22946054
Ref Doctor : Dr.RMO

Test	Result	Blo. Ref. Interval	Units
BLOOD SUGAR FASTING			
PLASMA GLUCOSE FASTING	102 H	60 - 100	mg/dl

***** END OF THE REPORT *****



Sample no.

Dr.NALANDA BUKTARE
MD (Pathology)

Dr.PRADIP KUMAR
Consultant (Microbiology)

Dr.BHAVANA CHAUHAN
MBBS, MD (Microbiology)

USER NM AMIT

(This is only professional opinion and not the diagnosis, Please correlate clinically)

Q Block South City 11, Sohna Road, Main Sector-47, Gurgaon, Haryana.

Ph.: 0124-4900000 (100 Lines) Fax : 0124-2218733 E-mail : parkmedicenters@gmail.com

PARK GROUP OF HOSPITALS : West Delhi • South Delhi • Gurgaon • Karnal • Panipat • Hodal • Ambala • Behror

the **health** care providers

the **health** care providers



DEPARTMENT OF PATHOLOGY

Patient Name : Mr. KUMBHKARAN
MR No : 659230
Age/Sex : 58 Years / Male
Type : OPD
TPA/Corporate : MEDIWHEEL PVT LTD

Bill Date : 22/08/2022
Reporting Date : 22/08/2022
Sample ID : 31776
Bill/Req. No. : 22946054
Ref Doctor : Dr RMO

Test	Result	Bio. Ref. Interval	Units
BLOOD SUGAR 2 HR. PP			
BLOOD SUGAR P.P.	233	H 80 - 150	mg/dl

***** END OF THE REPORT *****



Dr. NALANDA BUKTARE
MD (Pathology)

Dr. PRADIP KUMAR
Consultant (Microbiology)

Dr. NISHA TIWARI
MBBS, MD (Microbiology)
USER NM SONU

(This is only professional opinion and not the diagnosis, Please correlate clinically) Page 1 of 1
O Block South City 11, Sohna Road, Main Sector-47, Gurgaon, Haryana

Ph.: 0124-4900000 (100 Lines) Fax : 0124-2218733 E-mail : parkmedicenters@gmail.com

PARK GROUP OF HOSPITALS : West Delhi • South Delhi • Gurgaon • Karnal • Panipat • Hodal • Ambala • Behror



DEPARTMENT OF PATHOLOGY

Patient Name : Mr. KUMBHKARAN
MR No : 659230
Age/Sex : 58 Years / Male
Type : OPD
TPA/Corporate : MEDIWHEEL PVT LTD

Bill Date : 22/08/2022
Reporting Date : 22/08/2022
Sample ID : 31778
Bill/Req. No. : 22946054
Ref Doctor : Dr.RMO
Bio. Ref. Interval

Units

Test

Result

BLOOD GROUPING AND RH FACTOR

BLOOD GROUP

" B " RH POSITIVE

***** END OF THE REPORT *****



Sample no.

Dr.NALANDA BUKTARE
MD (Pathology)

Dr.PRADIP KUMAR
Consultant (Microbiology)

Dr.NISHA TIWARI
MBBS, MD (Microbiology)
USER NM SONU

(This is only professional opinion and not the diagnosis, Please correlate clinically)

Q Block South City 11, Sohna Road, Main Sector-47, Gurgaon, Haryana
Ph.: 0124-4900000 (100 Lines) Fax : 0124-2218733 E-mail : parkmedicenters@gmail.com

PARK GROUP OF HOSPITALS : West Delhi • South Delhi • Gurgaon • Karnal • Panipat • Hodal • Ambala • Behror

the **health** care providers

the **health** care providers





DEPARTMENT OF PATHOLOGY

Patient Name : Mr. KUMBHKARAN
MR No : 659230
Age/Sex : 58 Years / Male
Type : OPD
TPA/Corporate : MEDIWHEEL PVT LTD

Bill Date : 22/08/2022
Reporting Date : 22/08/2022
Sample ID : 31776
Bill/Req. No. : 22946054
Ref Doctor : Dr.RMO

Test	Result	Bio. Ref. Interval	Units
	PSA TOTAL		
PROSTATE SPECIFIC ANTIGEN(PSA)	0.74	0.57 - 4.0	ng/ml

***** END OF THE REPORT *****



Sample no.

Dr. NALANDA BUKTARE
MD (Pathology)

Dr. PRADIP KUMAR
Consultant (Microbiology)

Dr. BHAVANA CHAUHAN
MBBS, MD (Microbiology)
USER NM DINESH

(This is only professional opinion and not the diagnosis, Please correlate clinically)

O Block South City 11, Sohna Road, Main Sector-47, Gurgaon, Haryana
Ph.: 0124-4900000 (100 Lines) Fax : 0124-2218733 E-mail : parkmedicenters@gmail.com

PARK GROUP OF HOSPITALS : West Delhi • South Delhi • Gurgaon • Karnal • Panipat • Hodal • Ambala • Behror

the **health** care providers

the **health** care providers





DEPARTMENT OF PATHOLOGY

Patient Name : Mr. KUMBHKARAN
 MR No : 659230
 Age/Sex : 58 Years / Male
 Type : OPD
 TPA/Corporate : MEDIWHEEL PVT LTD

Bill Date : 22/08/2022
 Reporting Date : 22/08/2022
 Sample ID : 31776
 Bill/Req. No. : 22946054
 Ref Doctor : Dr.RMO

Test	Result	Bio. Ref. Interval	Units
THYROID PROFILE			
TRI-IODOETHYRONINE (T3)	0.97	0.60 - 1.81	ng/ml
THYROXINE (T4)	7.0	5.01 - 12.45	µg/dL
THYROID STIMULATING HORMONE (TSH)	3.29	0.5-5.50	µIU/ml

***** END OF THE REPORT *****



Sample no.

Dr.NALANDA BUKTARE
MD (Pathology)

Dr.PRADIP KUMAR
Consultant (Microbiology)

Dr.NISHA TIWARI
MBBS, MD (Microbiology)
USER NM DINESH

(This is only professional opinion and not the diagnosis, Please correlate clinically)

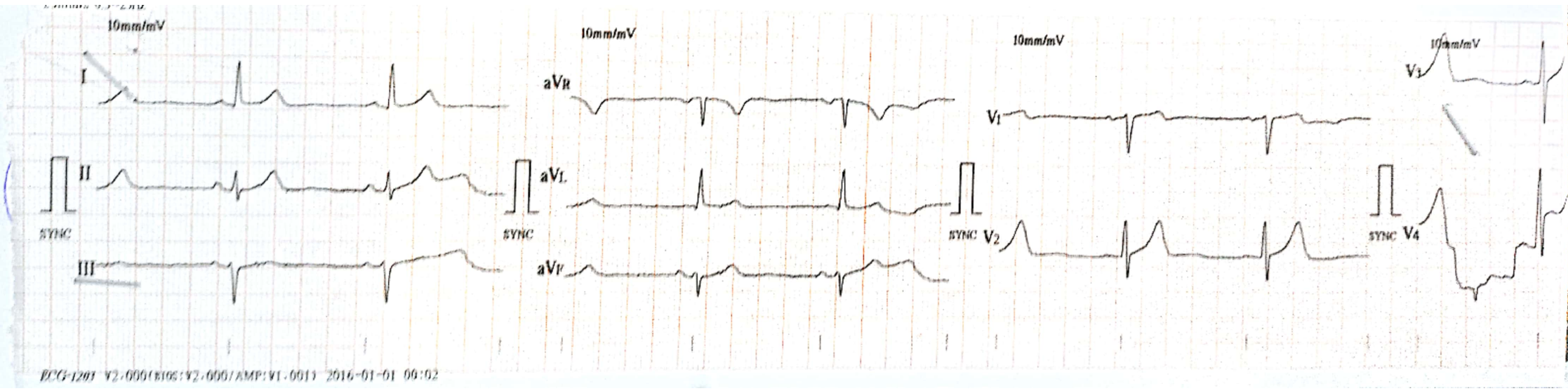
Q Block South City 11, Sohna Road, Main Sector-47, Gurgaon, Haryana
Ph.: 0124-4900000 (100 Lines) Fax : 0124-2218733 E-mail : parkmedicenters@gmail.com

PARK GROUP OF HOSPITALS : West Delhi • South Delhi • Gurgaon • Karnal • Panipat • Hodal • Ambala • Behror

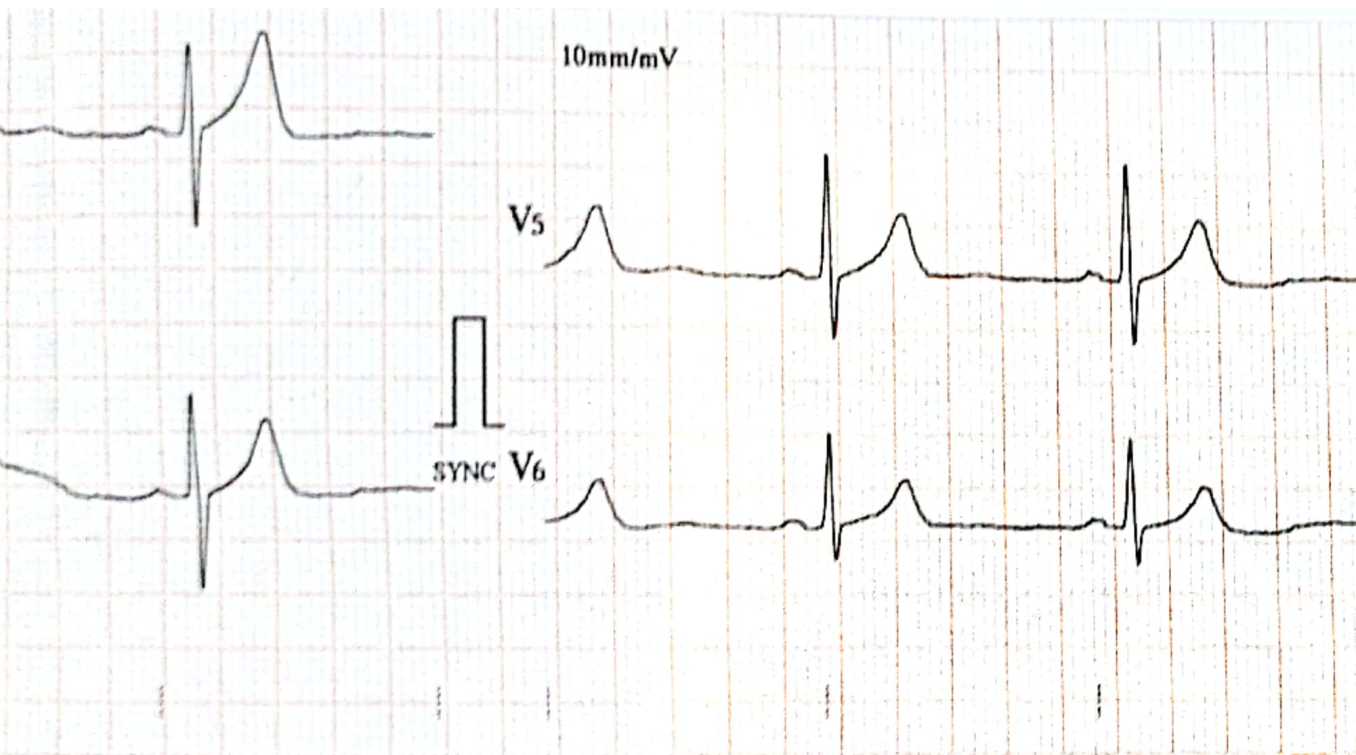
the health care providers

the health care providers





ECG-1203 V2-000(R10S)V2-000/AMP:V1-0013 2016-01-01 00:02



ID : 0004 HR : 54 bpm
 R R : 1094 ms
 Name: Mr /-vrm/8.22.18/153 ms
 QRS : 89 ms
 Sex : m QT/QTc : 402/384 ms
 Age : 50 P/QRS/T : 47/-18/36
 RV5/SV1 : 1.190/0.720 mV
 RV5+SV1 : 1.910 mV

----- Sinus BradyCardia
 ----- Left Axis Deviation

22/18

Unconfirmed report Verified by: _____



NAME	: MR. KUMBHKARAN SINGH	DATE	: 22 / 8 / 2022
Age Sex	: 58 Years / Male	Inpatient No	:
PERFORMED BY	: Dr. ELA MADAAN	UHID	: 22946054

TRANS THORACIC ECHO CARDIOGRAPHY REPORT

MITRAL VALVE

Morphology AML: Normal / Thickening / Calcification / Flutter / Vegetation / Non significant Prolapse / SAM
PML: Normal / Thickening / Calcification / Prolapse / Paradoxical Motion / Fixed.
Subvalvular deformity: Present / Absent

Doppler Normal / Abnormal
Mitral Stenosis Present / Absent
Mitral Regurgitation; Absent / Normal / Mild / Trace / Moderate / Severe.

TRICUSPID VALVE

Morphology Normal / Atresia / Thickening / Calcification / Prolapse / Vegetation / Doming.
Doppler Normal / Abnormal
Tricuspid Stenosis : Present / Absent.
Tricuspid Regurgitation; Absent / Normal / Mild / Trace / Moderate / Severe.

PULMONARY VALVE

Morphology Normal / Atresia / Thickening / Calcified / Doming / Vegetation.
Doppler Normal / Abnormal.
Pulmonary stenosis : Present / Absent
Pulmonary regurgitation : Present / Absent

AORTIC VALVE

Morphology Normal / Thickened / Mildly / Calcified / Flutter / Vegetation / Restricted / Opening
No. of Cusps 1 / 2 / 3 / 4
Doppler Normal / Abnormal
Aortic Stenosis : Present / Absent
Aortic regurgitation : Present / Absent / Mild / Trace



(This is only professional opinion and not the diagnosis, Please correlate clinically)

Q Block South City 11, Sohna Road, Main Sector-47, Gurgaon, Haryana
Ph.: 0124-4900000 (100 Lines) Fax : 0124-2218733 E-mail : parkmedicenters@gmail.com

PARK GROUP OF HOSPITALS : West Delhi • South Delhi • Gurgaon • Karnal • Panipat • Hodal • Ambala • Behror

the **health** care providers

the **health** care providers



Measurements	Normal Values	Measurements	Normal Value
IVSD : 1.3cm	(0.6-1.1cm)	LA : 4.0cm	(1.9-4.0cm)
LVID : 4.3cm	(3.7-5.6cm)	LVOT : 1.4cm	
LVPW : 1.2cm	(0.6-1.1cm)	AORTA : 2.7cm	(2.0-3.7cm)
EF : 60%	(55% - 80%)	IVSmotion :	Normal / Flat / Paradoxical

Any Other

CHAMBERS:-

- LV **Normal** / Enlarged / **Clear** / Thrombus /
 Contraction Normal LV shows concentric LVH, no gradient across LVOT / Inetic / Intra capillary
 Regional wall motion abnormality: **Absent** / Present
- LA **Normal** / Enlarged / Clear / Thrombus / Myxoma; **LAA: Clear** / Thrombus
- RA **Normal** / **Clear** / Thrombus, Dilated.
- RV **Normal** / Enlarged / **Clear** / Thrombus / Hypertrophied/ Dilated.
- PERICARDIUM **Normal** / Thickening / Calcification / Effusion.

COMMENTS & SUMMARY:- SUBOPTIMAL WINDOW

- All cardiac chambers dimensions are with in normal limits.
- Global LVEF 60%
- No RWMA
- MILD CONCENTRIC LVH
- NORMAL LV FUNCTION
- LVDD GRADE – I (E<A)
- TRACE MR
- TRACE AR
- TRACE TR
- GOOD RV FUNCTION
- IAS/IVS. No Flow seen across IAS/IVS.
- No Thrombus/Mass in any chamber.
- No Pericardial Effusion.



Please correlate clinically

Dr. Eta Madaan
 MBBS, PGDCC
 Fellowship in Non Invasive
 Cardiology

Dr. NAVJEET SINGH
 M.D.(Medicine) D.M (Cardiology).
 HOD & Director Interventional cardiology.

(This is only professional opinion and not the diagnosis, Please correlate clinically)

Q Block South City 11, Sohna Road, Main Sector-47, Gurgaon, Haryana
 Ph.: 0124-4900000 (100 Lines) Fax : 0124-2218733 E-mail : parkmedicenters@gmail.com

PARK GROUP OF HOSPITALS : West Delhi • South Delhi • Gurgaon • Karnal • Panipat • Hodal • Ambala • Behror

the **health** care providers

the **health** care providers





Dental Department

Kumbhkarani
58/M

22/08/22

Vitals :

Chief Complaints :

e/o- routine dental checkup.

HO Present Illness :

o/e Stains ++, Calculi ++.

Past History :

Investigation :

Drug Allergies : (if any)

Adv. Scaling & Polishing

Treatment :



Gurgaon

Q Block South City 11, Sohna Road, Main Sector-47, Gurgaon, Haryana Ph : 0124-4800000 Fax : 0124-2218733
E-mail : parkmedicenters@gmail.com

• West Delhi • South Delhi • Faridabad • Panipat • Karnal

the health care providers

the health care providers





For medical examination

no ENT complaints

Vitals :

Chief Complaints :



H/O Present Illness :

Past History :

Investigation :

Drug Allergies : (if any)

Oral } - NAD .
Nose }

Treatment :

Also
Pure Tone audiometry
[Signature]
22/8/22





DEPARTMENT OF RADIOLOGY

Patient Name	Mr KUMBHKARAN	Billed Date	: 22/08/2022	8.43 AM
Reg No	659230	Reported Date	: 22/08/2022	
Age/Sex	58 Years / Male	Req. No.	: 22946054	
Type	OPD	Consultant Doctor	: Dr. RMO	

USG WHOLE ABDOMEN

The real time, B mode, gray scale sonography of the abdominal organs was performed.

LIVER : The liver is normal in size 12.6cm with fatty infiltration. No evidence of any focal lesion. IHBR is not dilated.

GALL BLADDER : The gall bladder is well distended . No evidence any calculus or mass seen.

GB wall thickness with in normal limits.No evidence of pericholecystic fluid is seen.

BILE DUCT :The common bile duct is normal in caliber.Its measures 4.2 mm at porta hepatis.No evidence of calculus is noted in common bile duct.

SPLEEN :The spleen is normal in size 10.1cm and shape.Its echotexture is homogeneous.No evidence of focal lesion is noted.

PANCREAS :The pancreas is normal in size, shape, contours and echotexture.No evidence of solid or cystic mass lesion is noted.MPD is not dilated. No evidence of peripancreatic collection.

KIDNEYS : The bilateral kidneys are normal in size and echotexture. Cortico-medullary differentiation is maintained.There is no evidence of obvious calculus or hydronephrosis.

URINARY BLADDER :The urinary bladder is well distended.It shows uniformly thin walls and sharp mucosa.No evidence of calculus is seen. No evidence of mass or diverticulum is noted.

PROSTATE: Prostate is mild enlarged in size 23CC.

No evidence of ascites or interbowel free fluid is seen.

No evidence of obvious retroperitoneal or mesantric lymphadenopathy is seen.



IMPRESSION:- Fatty liver grade-I

Mild prostatomegaly

Dr ANSHU K SHARMA
MBBS,MD

CONSULTANT RADIOLOGIST

To be correlated clinically.

Dr.SAKET ROY CHAMKA
MBBS,MD

CONSULTANT RADIOLOGIST

Dr.MANJEET SEHRAWAT
MBBS,MD,PDCC

CONSULTANT RADIOLOGIST

Dr. NEENA SIKKA
MBBS,DNB

CONSULTANT RADIOLOGIST



