


भारत सरकार
Government of India



पुनीत कुमार
Puneet Kumar
जन्म तिथि/DOB: 03/12/1988
पुरुष/ MALE




4881 8803 0997

VID : 9185 9264 9138 5824

मेरा आधार, मेरी पहचान


(Handwritten signature)


Dr. NITIN AGARWAL
 MBBS, MD
 Regn. No. DMC-R-1436

VID : 9185 9264 9138 5824

4881 8803 0997

QR Code with Photograph



पता: S/O शम्भूगान, एन.डी.पी.ए. ऑफिस, 172, फ्लॉर, बारा, नॉर्थ वेस्ट डेल्ही, 110039

Address: S/O Shubhagan, N.D.P.L. OFFICE, 172, North West Delhi, ISHWAR COLONY, BAWANA, Bawana, Delhi - 110039

Unique Identification Authority of India
 भारत सरकार का विशेष अधिकारी

ONEPLUS ULTRASOUND LAB
 47, Harsh Vihar, Pitam Pura,
 Delhi-110034
 Ph. 011-42480101, 9599913051
 E-mail: oneplusul@gmail.com



Nitin

Nitin

Dr. NITIN AGARWAL
 MBBS, MD
 Regn. No. DMC-R-1436

ONEPLUS ULTRASOUND LAB
 47, Harsh Vihar, Pitam Pura,
 Delhi-110034
 Ph. 011-42480101, 9599913051
 E-mail: oneplusul@gmail.com

*** End Of Report ***

Dr. Nitin Agarwal

Pathologist & Director

Ex. Sr. Res. MAMC

& Lok Nayak Hospital

Ex. Chief of Lab Dr. Lal Path Labs.

Dr. Pooja (Garg) Agarwal

Radiologist & Director

MAMC & Lok Nayak Hospital



OnePLUS
Ultrasound Lab
— QUALITY FIRST... ALWAYS! —

To whomsoever it may concern:-

Respected sir/Ma'am,

This is to inform you that my ~~wife~~
named Jyoti Gupta and ~~my~~ ⁰ (Puneet Kumar),
~~are~~ not interested for stool test as well
as postprandial sugar test.

With Regards,

()
(Puneet Kumar)

Bank of Baroda



Dr. NITIN AGARWAL

MBBS, MD

Regn. No. DMC-R-1436

ci.

• Clinical cor.
• This report.

ONEPLUS ULTRASOUND LAB

47, HARSH VIHAR, PITAMPURA, DELHI- 110034

Mr. PUNEET KUMAR
 Age : 34M
 Ref. by : MEDIWHEEL
 Indication 1 :
 Indication 2 :
 Indication 3 :
 COMMENTS : Normal ECG

ID : 2161
 Ht/Wt : 165/70
 Recorded : 25-3-2023 8:34
 Medication 1 :
 Medication 2 :
 Medication 3 :

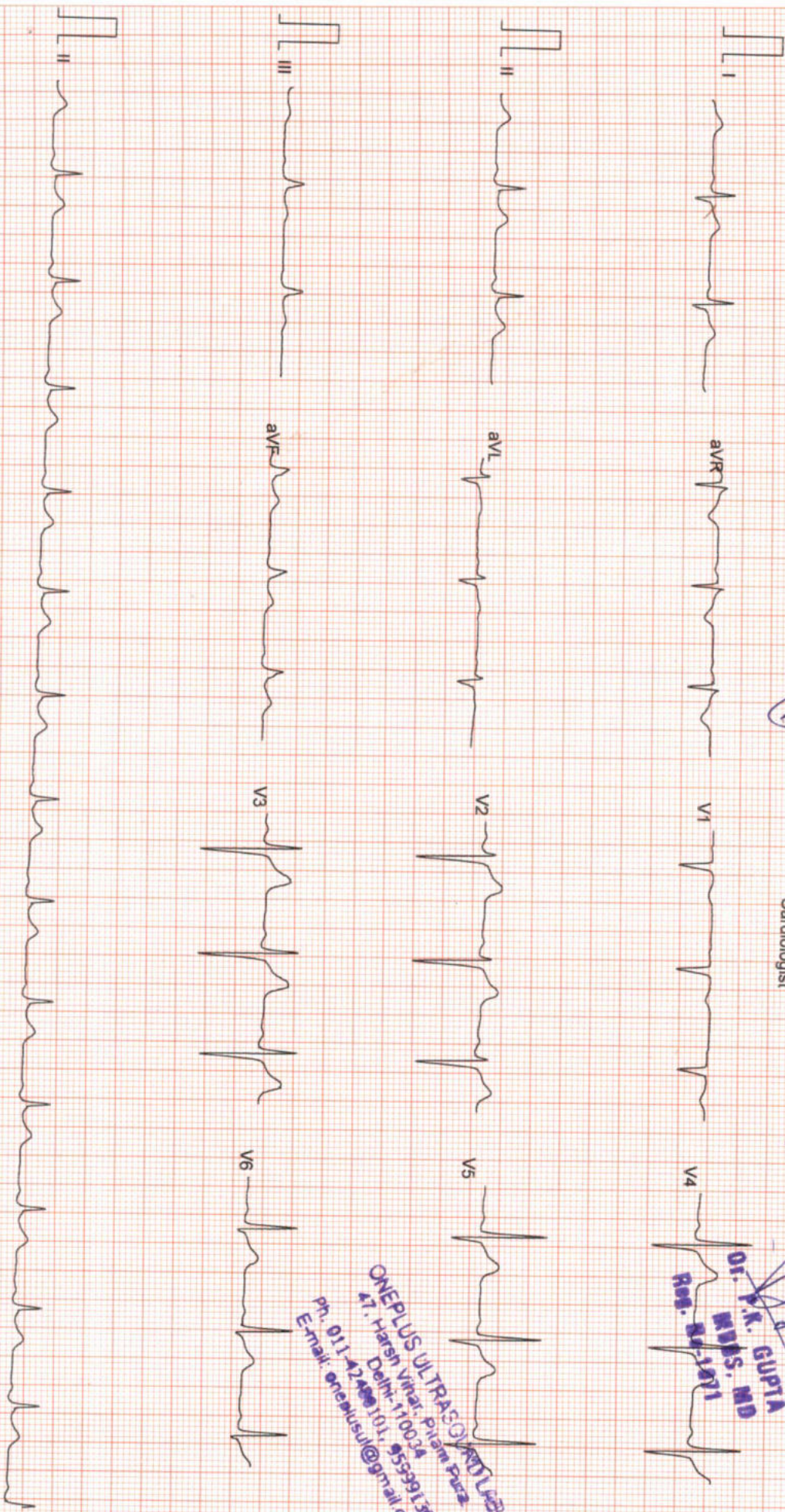
BP : 86
 P Axis : 126/88 deg
 QRS Axis : 37 deg
 T Axis : 69 deg
 T Axis : 48 deg

P duration : 86 msec
 PR duration : 140 msec
 QRS duration : 100 msec
 QT Interval : 306 msec
 QTc Interval : 351 msec

Raw E.C.G. (Sec)

Unconfirmed Report Reviewed By:
 Cardiologist

Dr. P.K. GUPTA
M.D.S. MD
Reg. No. 17071



ONEPLUS ULTRASOUND LAB
 47, Harsh Vihar, Pitampura
 Delhi-110034
 Ph. 011-42488101, 9599913051
 E-mail: oneplusul@gmail.com

Filtered
 25mm/sec 10mm/mV
 CardCom, INDIA

ONEPLUS ULTRASOUND LAB

47, HARSH VIHAR PITAMPURA DELHI 110034

ID : 999

HWM : 165/70

Recorded : 25-3-2023 8:36

TREADMILL TEST SUMMARY REPORT

Protocol: BRUCE

History:

Medication 1:

Medication 2:

Medication 3:

Mr. PUNEET KUMAR
Age/Sex : 34/M
Ref. by : MEDIWHEEL
Indication 1:
Indication 2:
Indication 3:

PHASE	PHASE TIME	STAGE TIME	SPEED (Km./Hr.)	GRADE (%)	H.R. (BPM)	B.P. (mmHg)	RPP X100	II	ST LEVEL (mm) V2	V5	METS
SUPINE											
STANDING											
STAGE 1	2:59	2:59	2.70	10.00	85	126/88	107	0.8	1.5	1.3	4.80
STAGE 2	5:59	2:59	4.00	12.00	85	126/88	107	0.8	1.6	1.4	7.10
STAGE 3	8:59	2:59	5.40	14.00	102	126/88	142	0.7	1.7	1.3	10.00
STAGE 4	10:29	1:29	6.70	16.00	120	150/92	180	0.1	1.5	1.5	11.99
PEAK EXER	10:30	1:30			167	160/94	267	0.1	2.5	2.7	
RECOVERY	2:59	2:59	0.00	0.00	101	128/88	129	0.5	0.9	0.9	12.01

RESULTS

Exercise Duration

Max Heart Rate

Max Blood Pressure

Max Work Load

Reason of Termination

10:30 Minutes
167 bpm 89 % of target heart rate 166 bpm
160/94 mmHg
12.01 METS

Negative for ischemia

ONEPLUS ULTRASOUND LAB
47, Harsh Vihar, Pitam Pura
Delhi-110034
Ph. 011-4246101, 9599913051
E-mail: oneplusul@gmail.com

Dr. D.K. GUPTA
M.B.B.S., MD
Cardiologist 071

ONEPLUS ULTRASOUND LAB

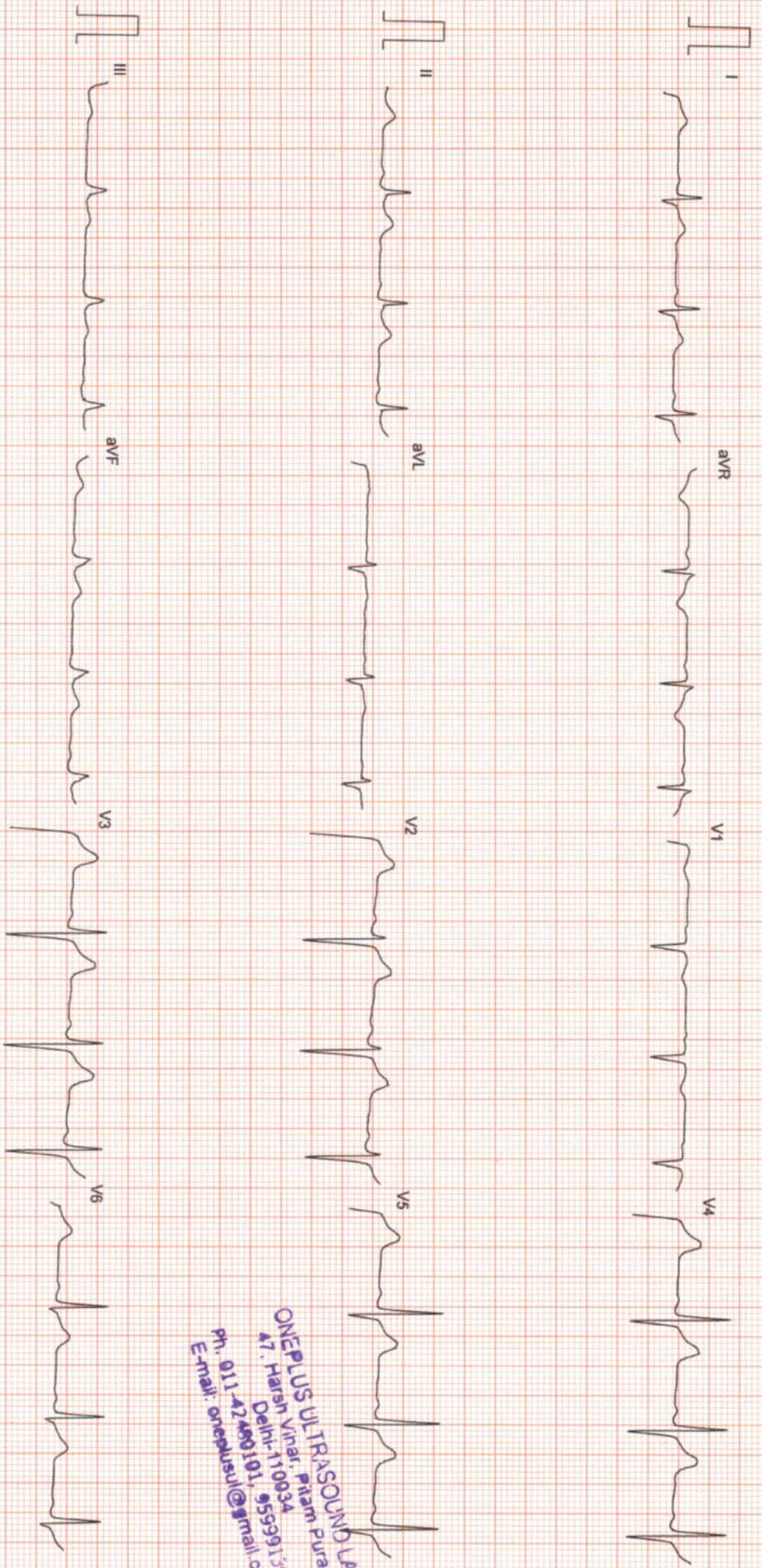
SUPINE
PRETEST

ST @ 10mm/mV
80ms PostJ

Mr. PUNEET KUMAR
I.D. : 999
AGE/SEX : 34/M

RATE : 85 BPM
B.P. : 126/88 mmHg

RAW E.C.G.



ONEPLUS ULTRASOUND LAB
A7, Harsn Vihar, Pitampura,
Delhi-110034
Ph. 011-42469101, 9559913051
Email: onepusul@gmail.com

Filtered

25mm/sec 10mm/mV

CardiCom, INDIA Ph.:091-731-2620740, TeleFax:091-731-2431214

ONEPLUS ULTRASOUND LAB

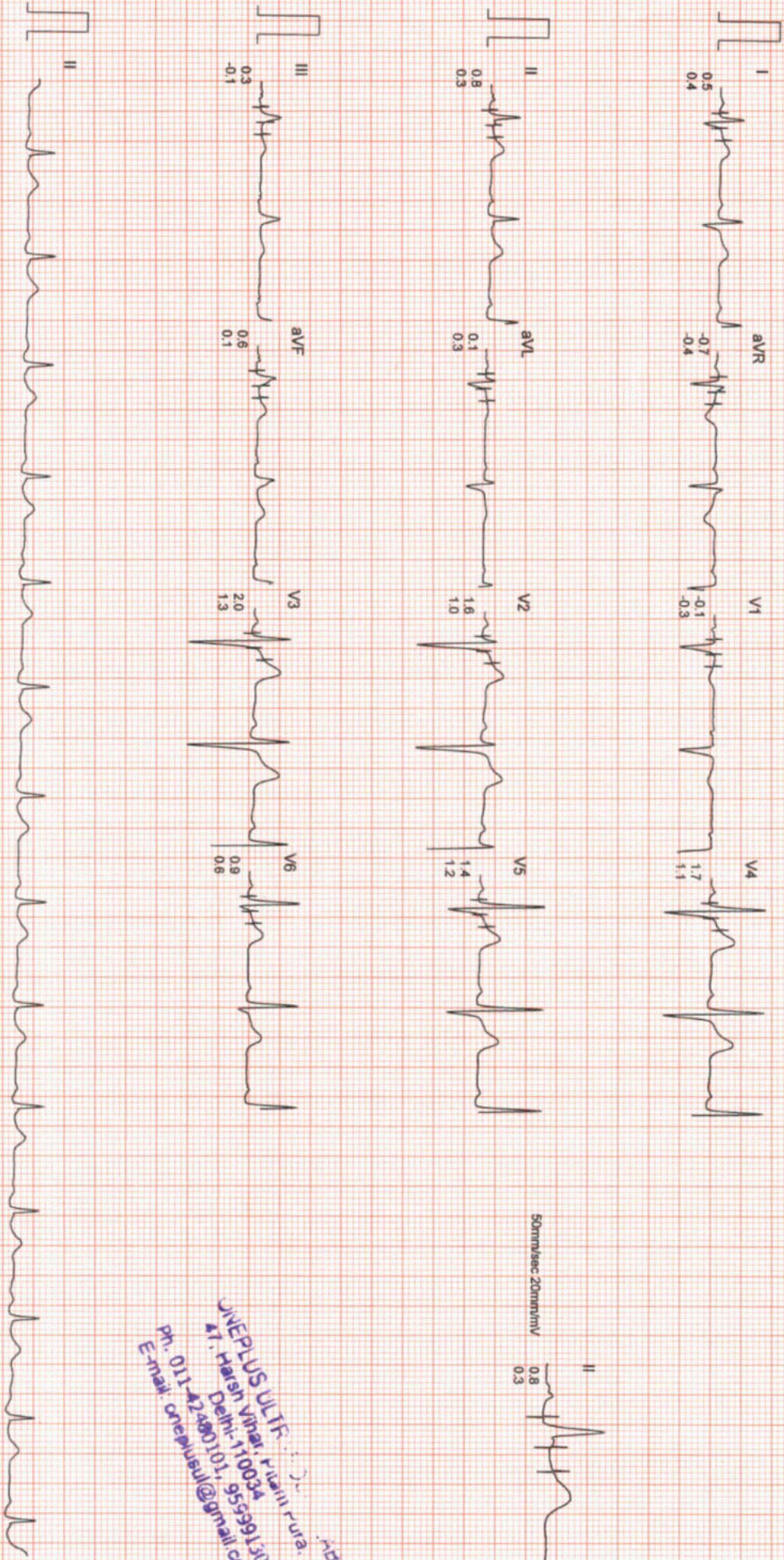
STANDING
PRETEST

ST @ 10mm/mV
80ms PostJ

Mr. PUNEET KUMAR
I.D. : 999
AGE/SEX : 34/M
RECORDED : 25-3-2023 8:36

RATE : 85 BPM
B.P. : 126/88 mmHg

LINKED MEDIUM



ONEPLUS ULTRASONIC LAB
47, Harish Vihar, R. Kheri R. u. a. - 20
Delhi-110034
Ph. 011-2460101, 9559913051
E-mail: oneplusultra@gmail.com

Filtered Computer Corrected Baseline

25mm/sec 10mm/mV

CardiCom, INDIA Ph. :091-731-2620740, Telefax:091-731-2431214

ONEPLUS ULTRASOUND LAB

Mr. PUNEET KUMAR

I.D. : 999

AGE/SEX : 34/M

RECORDED : 25-3-2023 8:36

RATE : 94 BPM

B.P. : 126/88 mmHg

BRUCE

EXERCISE 1

PHASE TIME : 2:59

STAGE TIME : 2:59

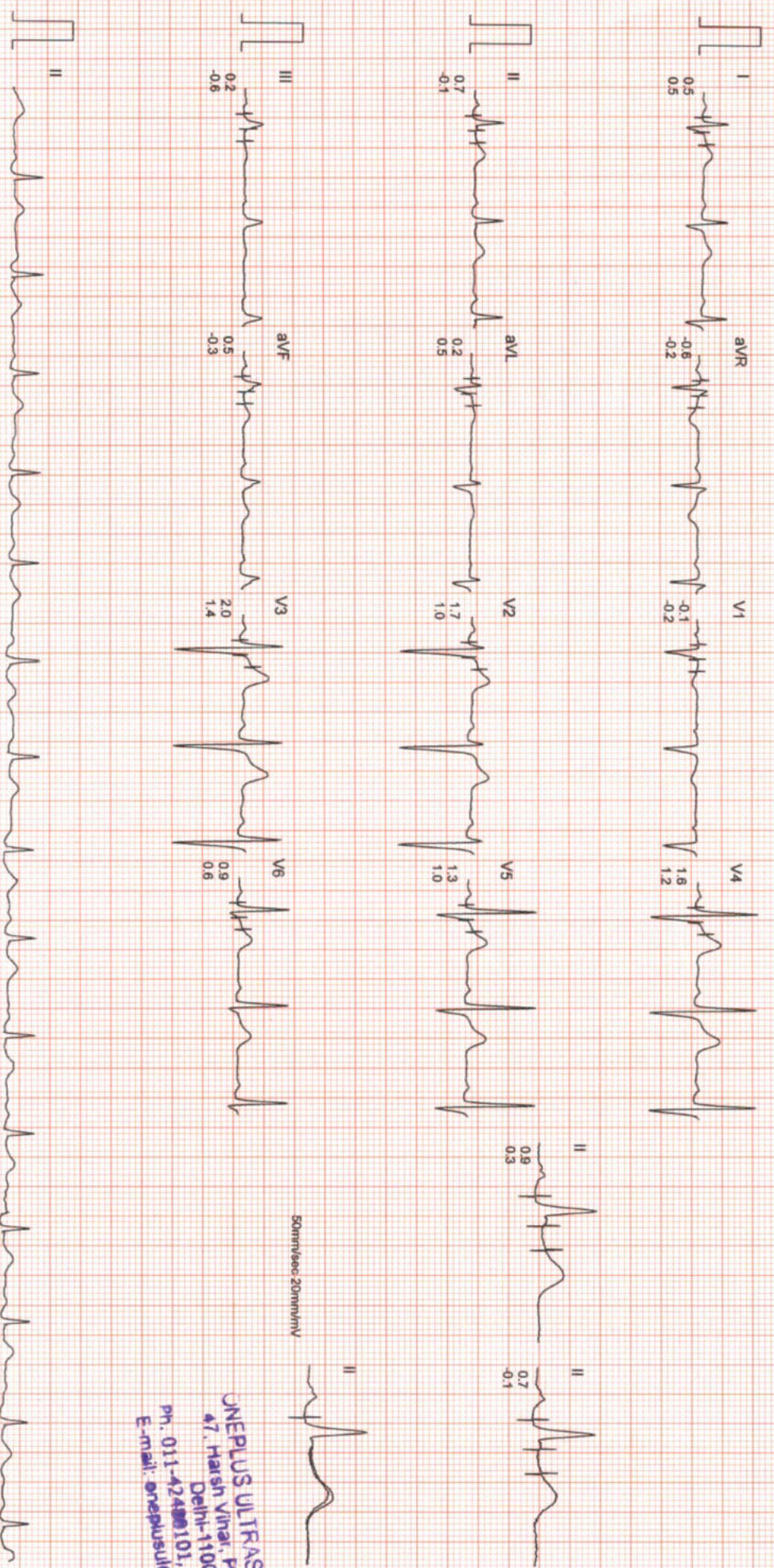
ST @ 10mm/mV

80ms PostJ

SPEED : 2.7 Km./HR.

GRADE : 10.0 %

LINKED MEDIAN



Filtered

Computer Corrected Baseline

25mm/sec 10mm/mV

CardiCom, INDIA Ph. 091-731-2620740, TeleFax 091-731-2431214

ONEPLUS ULTRASOUND LAB
47, Harish Vihar, Pitam Pura,
Delhi-110034
Ph. 011-42488101, 9599913051
E-mail: oneplusul@gmail.com

ONEPLUS ULTRASOUND LAB

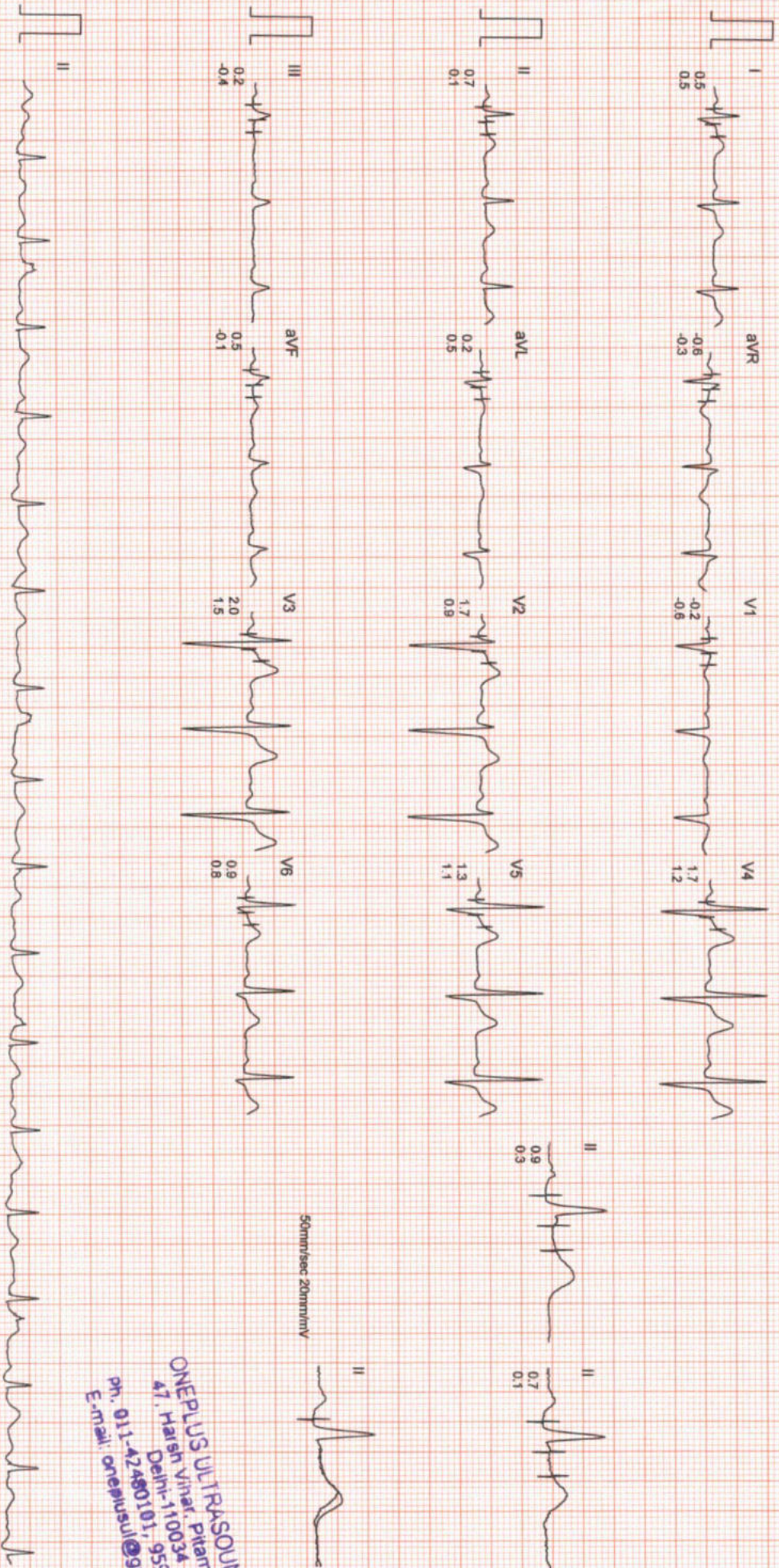
Mr. PUNEET KUMAR
 I.D. : 999
 AGE/SEX : 34/M
 RECORDED : 25-3-2023 8:36

RATE : 102 BPM
 B.P. : 140/90 mmHg

BRUCE
 EXERCISE 2
 PHASE TIME : 5:59
 STAGE TIME : 2:59

ST @ 10mm/mv
 80ms PostJ
 SPEED : 4.0 Km./Hr.
 GRADE : 12.0%

LINKED MEDIAN



50mm/sec 20mm/mv

ONEPLUS ULTRASOUND LAB
 47, Hareh Vihar, Pitam Pura,
 Delhi-110034
 Ph. 011-42480101, 9599913051
 Email: oneplusul@gmail.com

Filtered Computer Corrected Baseline

25mm/sec 10mm/mv

CardiCom, INDIA Ph. 091-731-2620740, TeleFax: 091-731-2431214

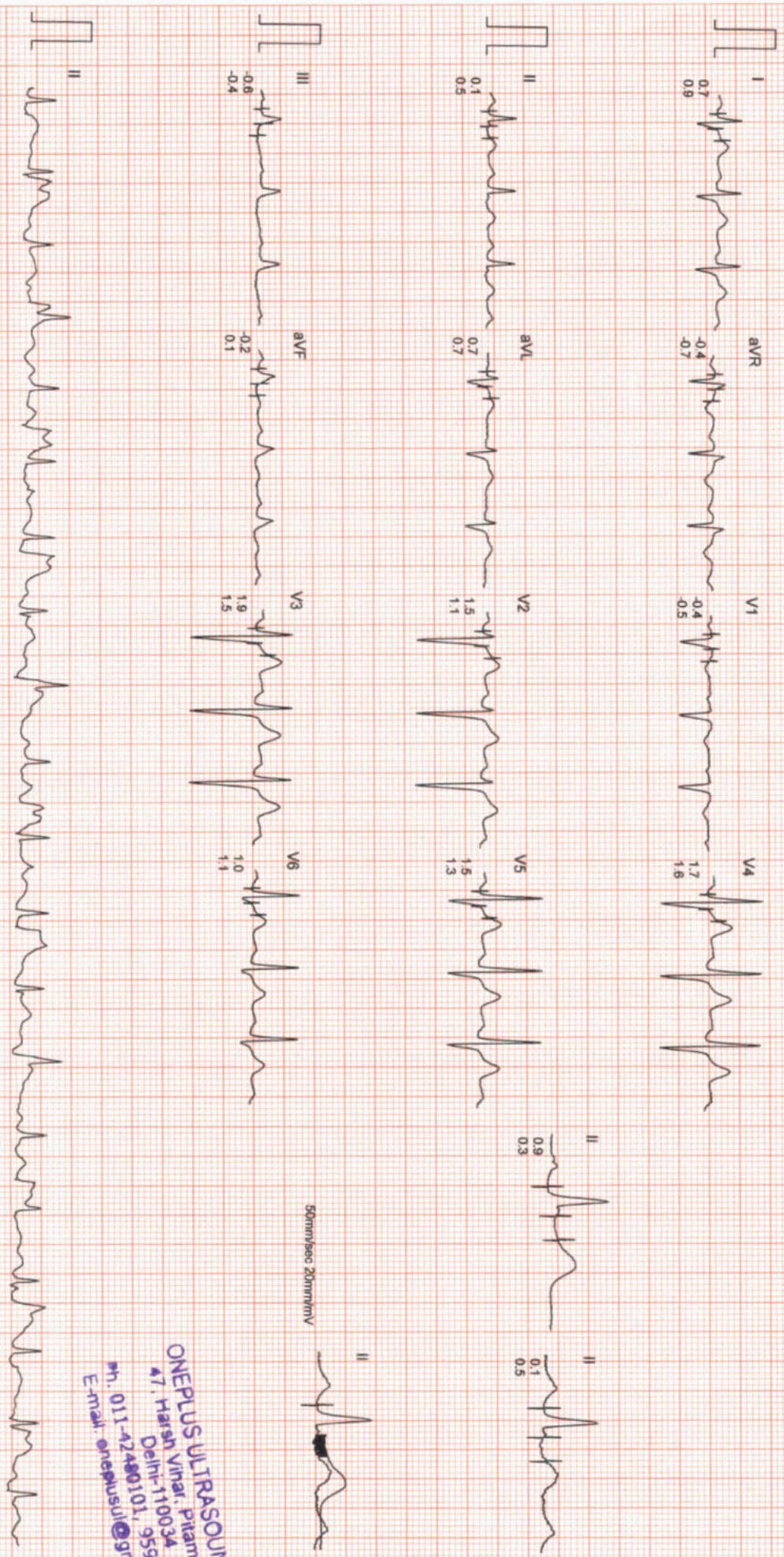
ONEPLUS ULTRASOUND LAB

Mr. PUNEET KUMAR
I.D. : 999
AGE/SEX : 34/M
RECORDED : 25-3-2023 8:36

BRUCE
EXERCISE 3
PHASE TIME : 8:59
STAGE TIME : 2:59

ST @ 10mm/mV
80ms PostJ
SPEED : 5.4 Km./Hr.
GRADE : 14.0 %

LINKED-MEDIAN



ONEPLUS ULTRASOUND LAB
47, Harsh Vihar, Pitam Pura.
Delhi-110034
Ph. 011-42480101, 9559913051
E-mail: onepusul@gmail.com

ONEPLUS ULTRASOUND LAB

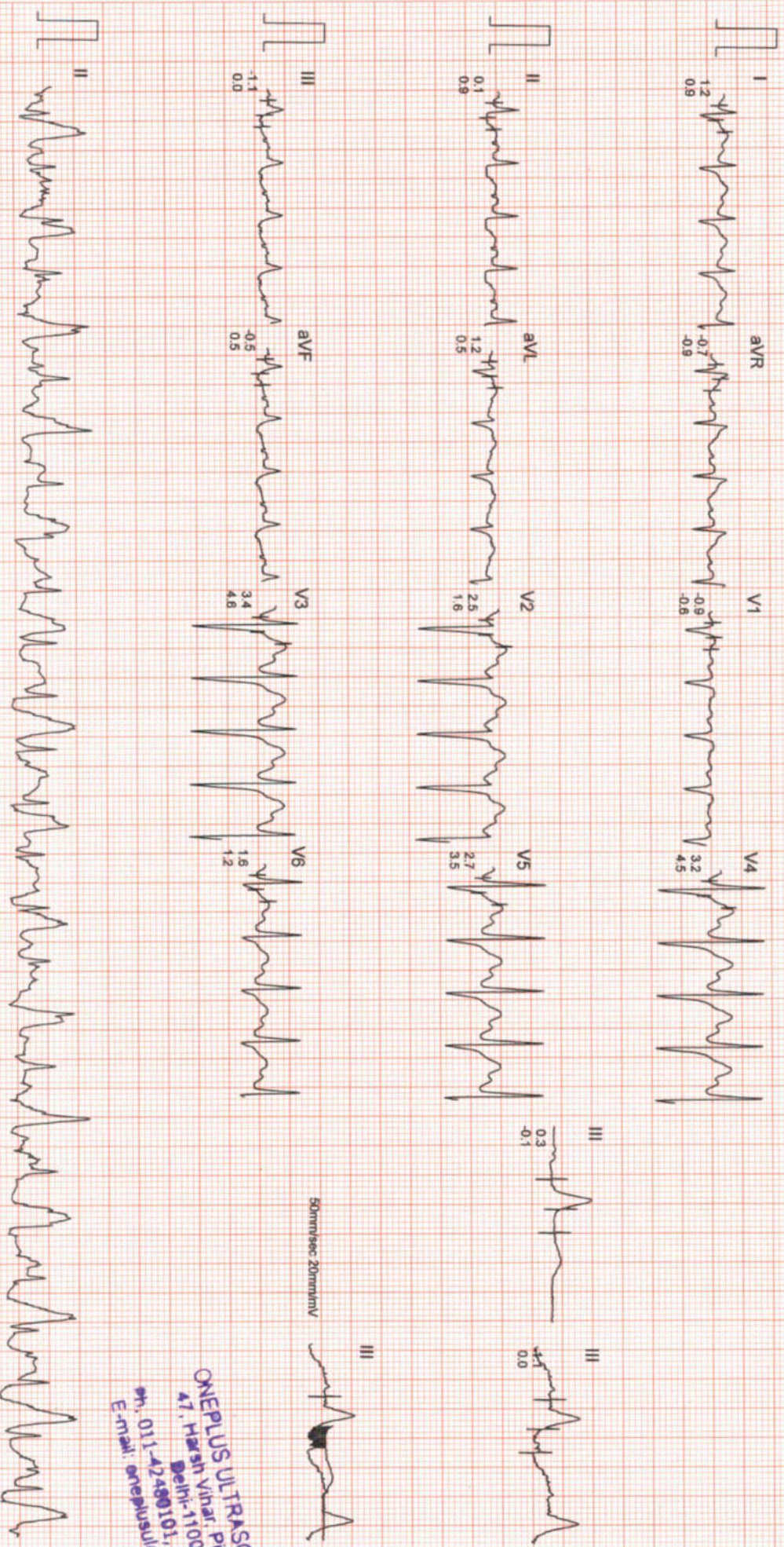
Mr. PUNEET KUMAR
 I.D. : 999
 AGE/SEX : 34/M
 RECORDED : 25-3-2023 8:36

RATE : 167 BPM
 B.P. : 160/94 mmHg

BRUCE
 EXERCISE 4
 PHASE TIME : 10:29
 STAGE TIME : 1:29

ST @ 10mm/mV
 80ms PostJ
 SPEED : 6.7 Km./Hr.
 GRADE : 16.0 %

LINKED MEDIUM



50mm/sec 20mm/mV

ONEPLUS ULTRASOUND LAB
 47, Harsh Vihar, Pitam Pura,
 Delhi-110034
 Ph: 011-42480101, 9599913051
 E-mail: oneplusul@gmail.com

Filtered Computer Corrected Baseline

25mm/sec 10mm/mV

CardiCom, INDIA Ph.:091-731-2620740, TeleFax:091-731-2431214

ONEPLUS ULTRASOUND LAB

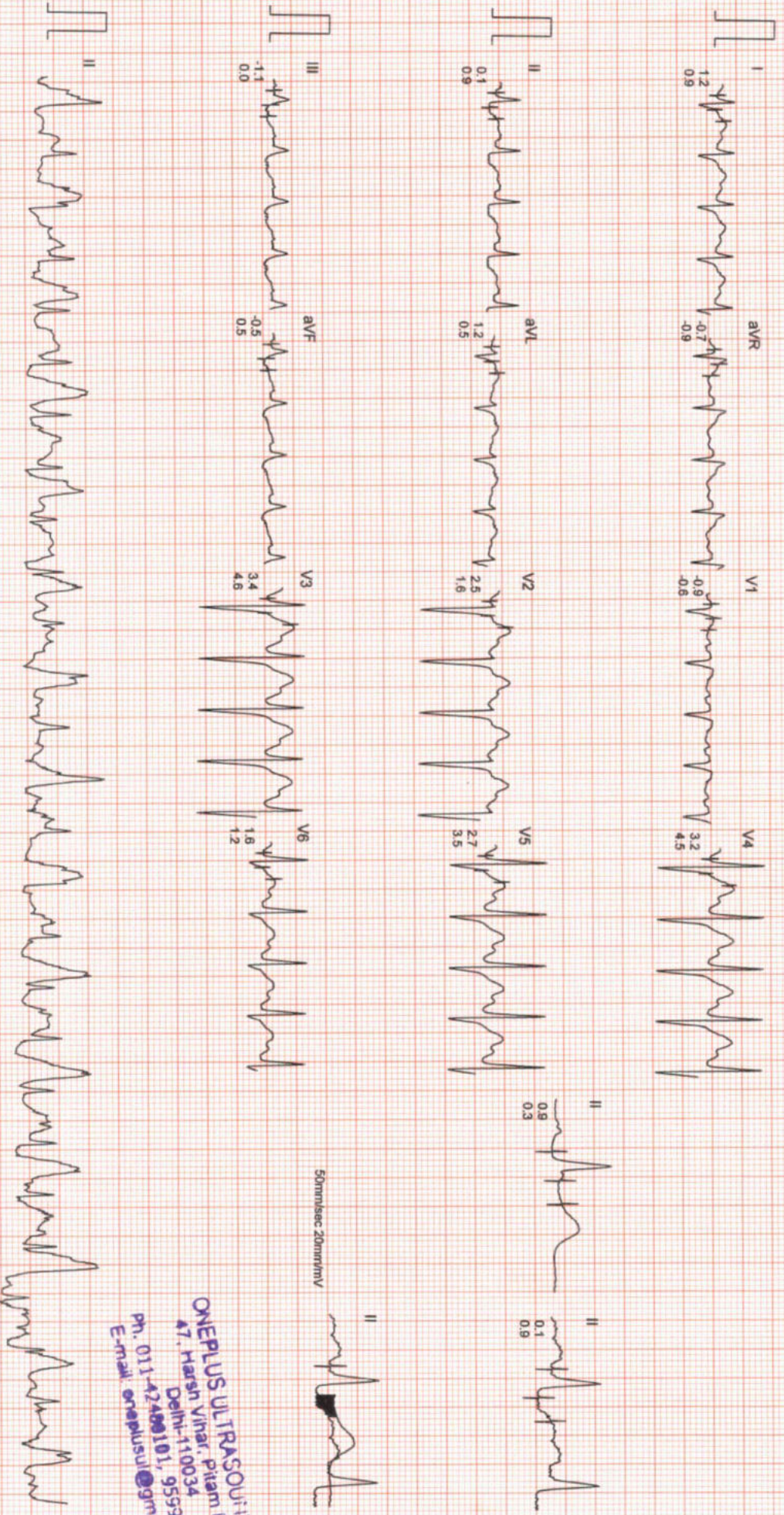
MR. PUNEET KUMAR
 ID. : 999
 AGE/SEX : 34/M
 RECORDED : 25-3-2023 8:36

RATE : 167 BPM
 B.P. : 160/94 mmHg

BRUCE
 PEAK EXER
 PHASE TIME : 10:30
 STAGE TIME : 1:30

ST @ 10mm/mV
 80ms PostJ
 SPEED : 6.7 Km./hr.
 GRADE : 16.0 %

LINKED MEDIAN



50mm/sec 20mm/mV

ONEPLUS ULTRASOUND LAB
 47, Harsh Vihar, Pitam Pura,
 Delhi-110034
 Ph. 011-42480101, 9559913051
 E-mail: oneplusul@gmail.com

Handwritten text, possibly a signature or initials, located in the upper left quadrant of the page.

ONEPLUS ULTRASOUND LAB

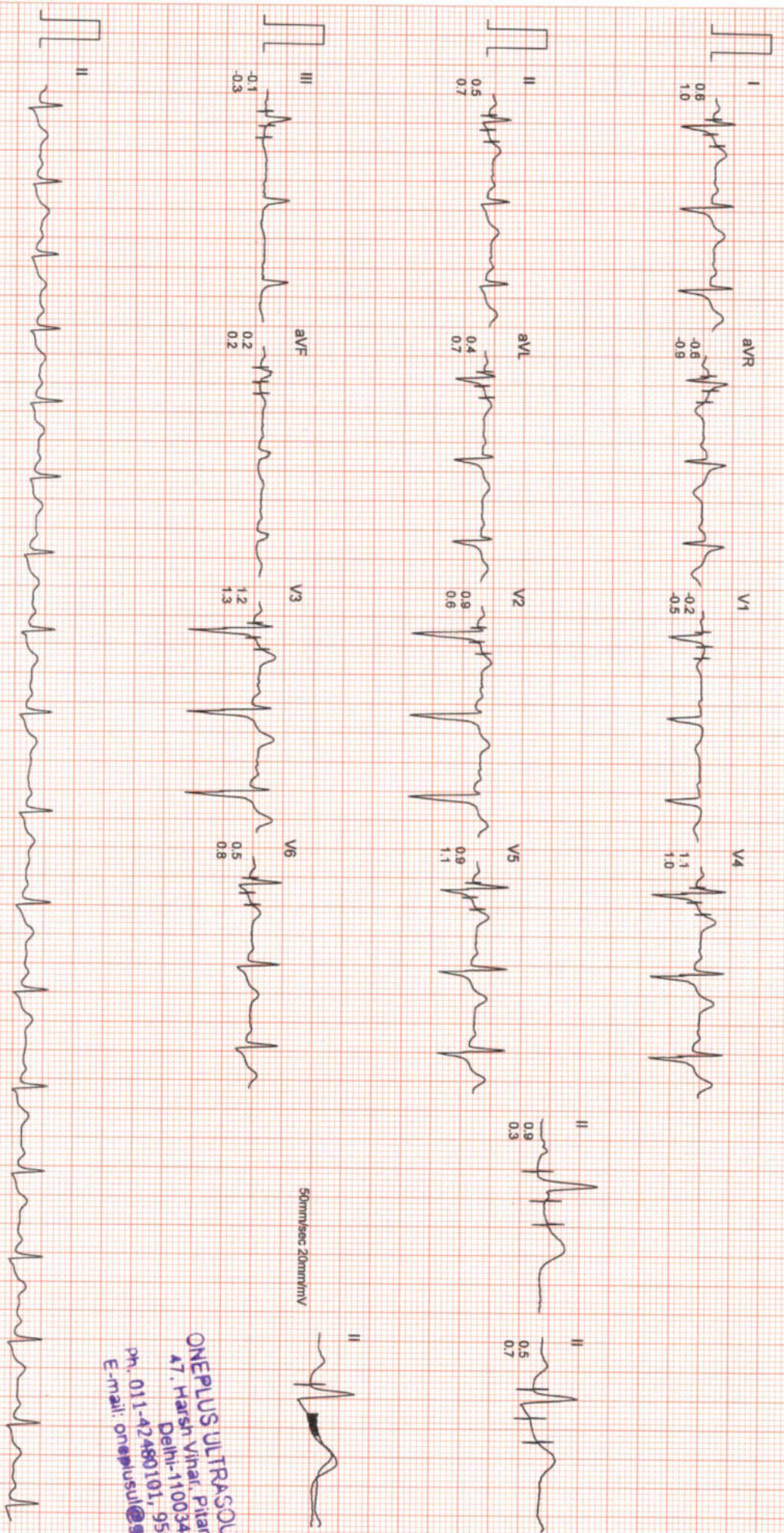
Mr. PUNEET KUMAR
ID. : 999
AGE/SEX : 34/M
RECORDED : 25-3-2023 8:36

RATE : 101 BPM
B.P. : 128/88 mmHg

BRUCE
RECOVERY
PHASE TIME : 2:59

ST @ 10mm/mV
80ms PostJ
SPEED : 0.0 Km./Hr.
GRADE : 0.0 %


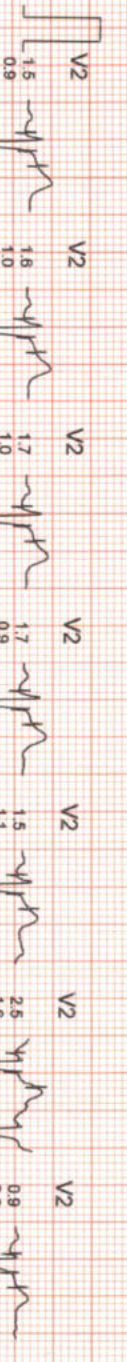
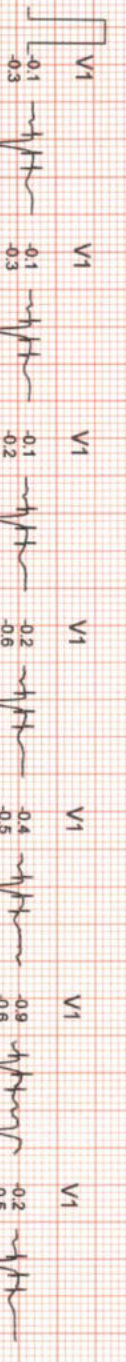
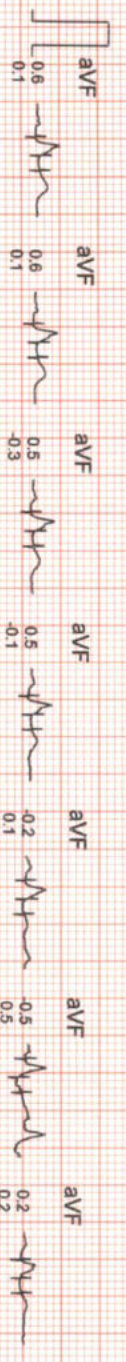
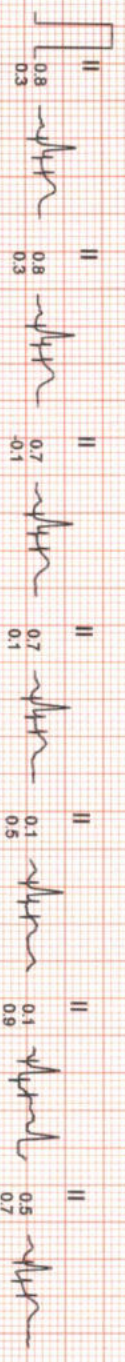
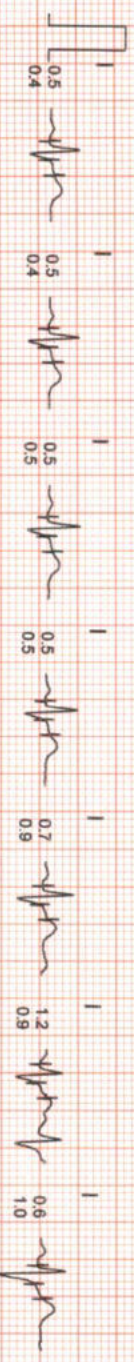
LINKED MEDIAN



50mm/sec 20mm/mV

ONEPLUS ULTRASOUND LAB
47, Harsh Vihar, Pitam Pura,
Delhi-110034
Ph. 011-42480101, 9599913051
E-mail: oneplusul@gmail.com

STAGE	HR	BP	SpO2
SUPINE	85 bpm	128/88	98ms Postu
STANDING	85 bpm	128/88	80ms Postu
STAGE 1	94 bpm	128/88	80ms Postu
STAGE 2	102 bpm	140/90	80ms Postu
STAGE 3	120 bpm	150/92	80ms Postu
PEAK EXERCISE	167 bpm	160/94	80ms Postu
RECOVERY	101 bpm	128/88	80ms Postu



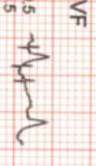

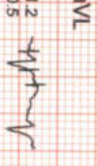


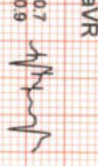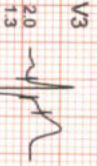

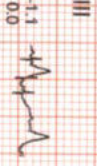
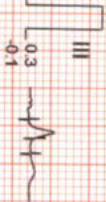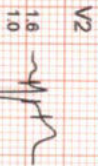
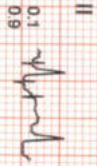
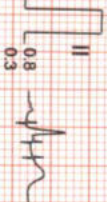

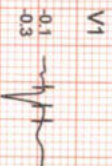

ONEPLUS ULTRASOUND LAB
 47, Harsih Vihar, Pitam Pura,
 Delhi-110034
 Ph. 011-42480101, 9599913051
 E-mail: onepulsul@gmail.com

STANDING
0.0Kmph
0.0%
85 bpm
B.P. 128/88
80ms PostU

PEAK EXERCISE
10:30
1:30
6.7Kmph
16.0%
167 bpm
B.P. 160/94
80ms PostU

STANDING
0.0Kmph
0.0%
85 bpm
B.P. 128/88
80ms PostU

PEAK EXERCISE
10:30
1:30
6.7Kmph
16.0%
167 bpm
B.P. 160/94
80ms PostU



ONEPLUS ULTRASOUND LAB
47, Hrish Vihar, Pitam Pura,
Delhi-110034
Ph. 011-42480101, 9559913051
E-mail: onepplusul@gmail.com



OnePLUS Ultrasound Lab

— QUALITY FIRST... ALWAYS! —

Dr. Nitin Agarwal
Pathologist & Director
Ex. Sr. Res. MAMC
& Lok Nayak Hospital
Ex. Chief of Lab Dr. Lal Path Labs.

Dr. Pooja (Garg) Agarwal
Radiologist & Director
MAMC & Lok Nayak Hospital



NAME	:Mr. PUNEET KUMAR	Barcode No	:10140818
AGE/GENDER	:34 YRS/Male	SPECIMEN DATE	:25/Mar/2023 08:09AM
PATIENT ID	:111309	SPECIMEN RECEIVED	:25/Mar/2023 08:19AM
REFERRED BY	:Dr. MEDIWHEEL	REPORT DATE	:25/Mar/2023 01:15PM
CENTRE NAME	:ONEPLUS ULTRASOUND LAB	LAB NO.	:012303250001

Test Name	Result	Unit	Ref. Range
-----------	--------	------	------------

HAEMATOLOGY

Medi Wheel Health checkup < 40 Male

Glycosylated Hemoglobin (HbA1c)	5.2	%	Non Diabetic adults <5.7 Prediabetic (at risk) 5.7-6.4 Diabetes >6.4
--	-----	---	--

Estimated average blood glucose (eag)	103
--	-----

Reference range (mg/dl):

90 - 120:Excellent control, 121 - 150:Good Control, 151 - 180:Average Control, 181 - 210:Action Suggested

>211:Panic value

BLOOD GROUP (ABO)	B
Rh typing	POSITIVE

NOTE :

- * Apart from major A,B,H antigens which are used for ABO grouping and Rh typing, many minor blood group antigens exist. Agglutination may also vary according to titre of antigen and antibody.
- * So before transfusion, reconfirmation of blood group as well as cross-matching is needed.
- * Presence of maternal antibodies in newborns, may interfere with blood grouping.
- * Auto agglutination (due to cold antibody, falciparum malaria, sepsis, internal malignancy etc.) may also cause erroneous result.

CBC

Haemoglobin	15.0	g/dl	13.0-17.0
Total Leucocyte Count	7500	/cumm	4000-10000
Differential leucocyte count			
Neutrophils	63.5	%	40-80
Lymphocyte	31.80	%	20-40
Monocytes	2.70	%	2-10
Eosinophils	1.6	%	1-6
Basophils	0.4	%	0-2
RBC Count	5.20	million/cumm	4.5 - 5.5

Checked By.

Dr NITIN AGARWAL
M B B S , MD (Path)
DMC/R/01436

DR. NITIN AGARWAL
MBBS,MD(PATHOLOGIST)

47, Harsh Vihar, Pitampura, New Delhi-110034 | Ph.: 011-42480101, 9599913051
E-mail: oneplusul@gmail.com | Web.: www.oneplusul.in

Page 1 of 5



OnePLUS Ultrasound Lab

QUALITY FIRST... ALWAYS!

Dr. Nitin Agarwal
Pathologist & Director
Ex. Sr. Res. MAMC
& Lok Nayak Hospital
Ex. Chief of Lab Dr. Lal Path Labs.

Dr. Pooja (Garg) Agarwal
Radiologist & Director
MAMC & Lok Nayak Hospital



NAME	:Mr. PUNEET KUMAR	Barcode No	:10140818
AGE/GENDER	:34 YRS/Male	SPECIMEN DATE	:25/Mar/2023 08:09AM
PATIENT ID	:111309	SPECIMEN RECEIVED	:25/Mar/2023 08:19AM
REFERRED BY	:Dr. MEDIWHEEL	REPORT DATE	:25/Mar/2023 01:15PM
CENTRE NAME	:ONEPLUS ULTRASOUND LAB	LAB NO.	:012303250001

Test Name	Result	Unit	Ref. Range
PCV(Hematocrit)	49.5	%	40-50
MCV	96.1	fL	83-101
MCH	29.2	Pg	27-32
MCHC	30.4	G/dL	32-35
Platelet count	253000	/cumm	150000-450000
RDW-CV	13.5	%	11.4-14.0
ESR(WESTGRENs METHOD)	10	mm in 1st hr	0-20

BIOCHEMISTRY

<u>Blood sugar fasting</u>	94	mg/dL	70-110
<u>Bun (blood urea nitrogen)</u>	12.60	mg/dl	8.9-21.6
<u>Uric acid, serum</u>	4.6	mg/dl	3.5-7.2
<u>Creatinine, serum</u>	0.6	mg/dl	0.60-1.2

LFT(LIVER FUNCTION TEST)

Bilirubin Total	0.65	mg/dl	0.1-1.2
Bilirubin Conjugated	0.32	mg/dl	0-0.4
Bilirubin Unconjugated	0.33	mg/dl	up to 0.7
SGOT (AST)	27	U/L	0-46
SGPT (ALT)	41	U/L	0-49
Alkaline phosphatase	105	U/L	40-129
Gamma glutamyl transpeptidase	28	U/L	10-45
Total Protein	6.9	gm/dl	6.60 - 8.70
Albumin serum	3.8	g/dL	3.0-5.2
Globulin	3.10	gm/dl	1.8-3.4
Albumin/Globulin Ratio	1.23		1.10 - 2.50

LIPID PROFILE

Cholesterol	226	mg/dl	50-200
Triglycerides	254	mg/dL	25-150
HDL Cholesterol	45	mg/dL	40 - 60

Checked By.

Dr. NITIN AGARWAL
M B B S , MD (Path)
DMC/R/01436

DR. NITIN AGARWAL
MBBS,MD(PATHOLOGIST)

47, Harsh Vihar, Pitampura, New Delhi-110034 | Ph.: 011-42480101, 9599913051
E-mail: oneplusul@gmail.com | Web.: www.oneplusul.in

Page 2 of 5



OnePLUS Ultrasound Lab

QUALITY FIRST... ALWAYS!

Dr. Nitin Agarwal
Pathologist & Director
Ex. Sr. Res. MAMC
& Lok Nayak Hospital
Ex. Chief of Lab Dr. Lal Path Labs.

Dr. Pooja (Garg) Agarwal
Radiologist & Director
MAMC & Lok Nayak Hospital



NAME	:Mr. PUNEET KUMAR	Barcode No	:10140818
AGE/GENDER	:34 YRS/Male	SPECIMEN DATE	:25/Mar/2023 08:09AM
PATIENT ID	:111309	SPECIMEN RECEIVED	:25/Mar/2023 08:19AM
REFERRED BY	:Dr. MEDIWHEEL	REPORT DATE	:25/Mar/2023 01:15PM
CENTRE NAME	:ONEPLUS ULTRASOUND LAB	LAB NO.	:012303250001

Test Name	Result	Unit	Ref. Range
LDL cholesterol	130	mg/dL	<130
VLDL cholesterol	50.8	mg/dL	5-40
Cholesterol/HDL Ratio	5.0		Low Risk 3.3-4.97 Average Risk 4.4-7.1 Moderate Risk 7.1-11.0 High Risk >11.0
LDL/HDL Ratio	2.9		0 - 3.55

According to ATP III and NCEP guidelines

Parameter	Normal	Desirable	Borderline	High
Total cholesterol	<200		200-239	240
Triglycerides	<150	150-199	200-499	500
LDL	Optimal <100 Near Optimal 100-129	130-159	160-180	190
HDL	<40 : LOW 60 : HIGH			

BUN/Creatinine ratio

Bun (blood urea nitrogen)	12.60	mg/dl	8.9-21.6
CREATININE	0.60	mg/dl	0.30-1.10
BUN/Creatinine ratio	21.00		10.0 - 20.0

ENDOCRINOLOGY

THYROID PROFILE(T3,T4,TSH)

Triiodothyronine total [t3]	0.86	ng/dl	0.52-1.9
Thyroxine total [t4]	7.40	µg/dl	4.4 - 10.8
TSH (Thyroid Stimulating Hormone)	2.80	µIU/ml	0.25-5.0

AGE WISE VARIATION IN TSH

AGE	TSH(µIU/ml)	AGE	TSH(µIU/ml)
-----	-------------	-----	-------------

Checked By.

Dr. NITIN AGARWAL
M B B S , MD (Pathology)
DMC/R/01436
MBBS, MD (PATHOLOGIST)

47, Harsh Vihar, Pitampura, New Delhi-110034 | Ph.: 011-42480101, 9599913051
E-mail: oneplusul@gmail.com | Web.: www.oneplusul.in



OnePLUS Ultrasound Lab

QUALITY FIRST... ALWAYS!

Dr. Nitin Agarwal
Pathologist & Director
Ex. Sr. Res. MAMC
& Lok Nayak Hospital
Ex. Chief of Lab Dr. Lal Path Labs.

Dr. Pooja (Garg) Agarwal
Radiologist & Director
MAMC & Lok Nayak Hospital



NAME	:Mr. PUNEET KUMAR	Barcode No	:10140818
AGE/GENDER	:34 YRS/Male	SPECIMEN DATE	:25/Mar/2023 08:09AM
PATIENT ID	:111309	SPECIMEN RECEIVED	:25/Mar/2023 08:19AM
REFERRED BY	:Dr. MEDIWHEEL	REPORT DATE	:25/Mar/2023 01:15PM
CENTRE NAME	:ONEPLUS ULTRASOUND LAB	LAB NO.	:012303250001

Test Name	Result	Unit	Ref. Range
1-4 weeks	1.00 - 19.0	16-20 yrs	0.25 - 5.0
1-12 mths	1.70 - 9.1	21 - 80 yrs	0.25 - 5.0
1-5 yrs	0.80 - 8.2	I st trimester	0.25 - 5.0
6-10 yrs	0.25 - 5.0	II nd trimester	0.50 - 5.0
11-15 yrs	0.25 - 5.0	II rd trimester	0.4 - 6.0

Reference ranges - Interpretation of Diagnostic tests - (Jacques Wallach)

1. Primary hypothyroidism is accompanied by depressed serum T3 and T4 values and elevated serum TSH level.
2. Primary hyperthyroidism is accompanied by elevated serum T3 and T4 levels along with depressed TSH values.
3. Significantly elevated T3 levels may be found in pregnancy and estrogen therapy, while depressed levels may be encountered in severe illness, renal failure and during therapy with drugs like propranolol and propyl thiouracil.
4. Although elevated TSH levels are nearly always indicative of primary hypothyroidism, and may be seen in secondary thyrotoxicosis

CLINICAL PATHOLOGY

URINE ROUTINE

Physical examination

Quantity	30	ML
Colour	PALE YELLOW	
Transparency	CLEAR	CLEAR
Sp.gravity	1.015	1.010-1.030
pH	6.00	
Reaction	ACIDIC	ACIDIC

Chemical examination

Urine protein	NIL	NIL
Urine sugar	NIL	NIL
Bilirubin, urine	NEGATIVE	NEGATIVE
Urobilinogen	NORMAL	NORMAL
Ketones	NEGATIVE	NEGATIVE

Microscopic examination

Pus cells.	1-2	/HPF	0-2
------------	-----	------	-----

Checked By.

Dr. NITIN AGARWAL
M B B S , MD (Pathology) DR. NITIN AGARWAL
DMC/R/01436 MBBS,MD(PATHOLOGIST)

47, Harsh Vihar, Pitampura, New Delhi-110034 | Ph.: 011-42480101, 9599913051
E-mail: oneplusul@gmail.com | Web.: www.oneplusul.in

Page 4 of 5



OnePLUS Ultrasound Lab

QUALITY FIRST... ALWAYS!

Dr. Nitin Agarwal
Pathologist & Director
Ex. Sr. Res. MAMC
& Lok Nayak Hospital
Ex. Chief of Lab Dr. Lal Path Labs.

Dr. Pooja (Garg) Agarwal
Radiologist & Director
MAMC & Lok Nayak Hospital



NAME	:Mr. PUNEET KUMAR	Barcode No	:10140818
AGE/CENDER	:34 YRS/Male	SPECIMEN DATE	:25/Mar/2023 08:09AM
PATIENT ID	:111309	SPECIMEN RECEIVED	:25/Mar/2023 08:19AM
REFERRED BY	:Dr. MEDIWHEEL	REPORT DATE	:25/Mar/2023 01:15PM
CENTRE NAME	:ONEPLUS ULTRASOUND LAB	LAB NO.	:012303250001

Test Name	Result	Unit	Ref. Range
Epithelial cells	1-2	/HPF	NIL
R.B.C.	NIL	/HPF	NIL
Casts	NIL	/HPF	NIL
Crystals	NIL	/HPF	NIL
Bacteria	NIL	/HPF	NIL
Others	NIL	NIL	NIL

*** End Of Report ***

Checked By.

Dr NITIN AGARWAL
M B B S , MD (Path)
DMC/R/01436
DR. NITIN AGARWAL
MBBS,MD(PATHOLOGIST)

47, Harsh Vihar, Pitampura, New Delhi-110034 | Ph.: 011-42480101, 9599913051
E-mail: oneplusul@gmail.com | Web.: www.oneplusul.in

Page 5 of 5

Clinical correlation is essential for final diagnosis. • If test results are unsatisfactory please contact personally or on phone. • This report is for perusal of doctors only.
• All disputes Subject to Delhi Jurisdiction only. • Not for medicolegal purposes. • All congenital anomalies in a foetus may not be diagnosed in routine obstetric ultrasound.

Name	: Mr. PUNEET KUMAR	Age/Sex	: 34 YRS/Male
Ref. By	: Dr. MEDIWHEEL	Lab No	: 012303250001
Date	: 25-Mar-2023	Patient ID	: LSHHI111309

ULTRASOUND EXAMINATION----WHOLE ABDOMEN

Liver is normal in size and normal in outline with **altered echopattern. Diffuse increase in echogenicity of liver parenchyma is noted, suggestive of fatty infiltration (grade II).** Intrahepatic biliary radicles are not dilated. No abscess or mass lesion seen. Hepatic veins, portal vein, IVC and aorta are normal. CBD is normal in caliber.

Gall bladder is well distended with anechoic lumen. Wall thickness is normal.

Both kidneys are normal in size, shape, position, outline and echopattern. Corticomedullary differentiation is maintained. No pelvicalyceal dilation or mass lesion is seen.

Spleen is normal in size and echotexture. No mass lesion seen.

Pancreas is normal in size, outline and echotexture.

Urinary bladder is normal in shape and position. No evidence of intravesical stone or mass seen.

Prostate is **borderline in size**, normal in shape and echopattern.

Prostate measures 4.5 x 3.5 x 3.2 cm. **Weight of prostate is 26.9 grams.**

No abnormal bowel wall thickening seen in right iliac fossa.
No free fluid seen anywhere in abdomen.

IMPRESSION:

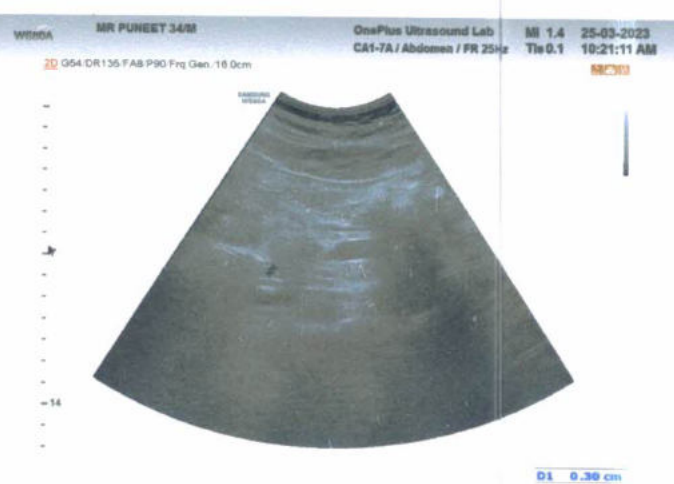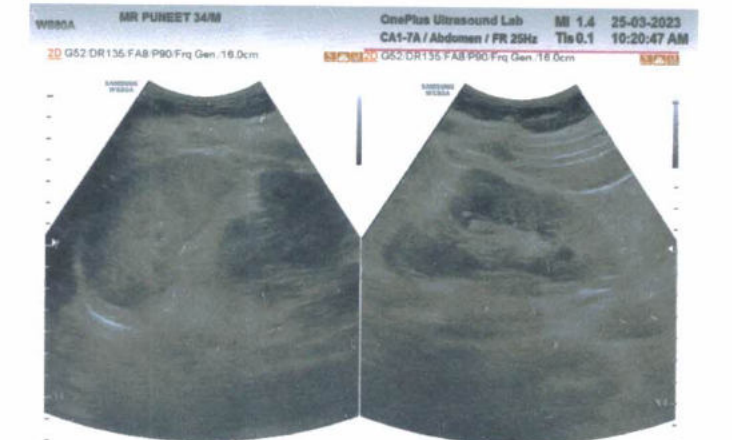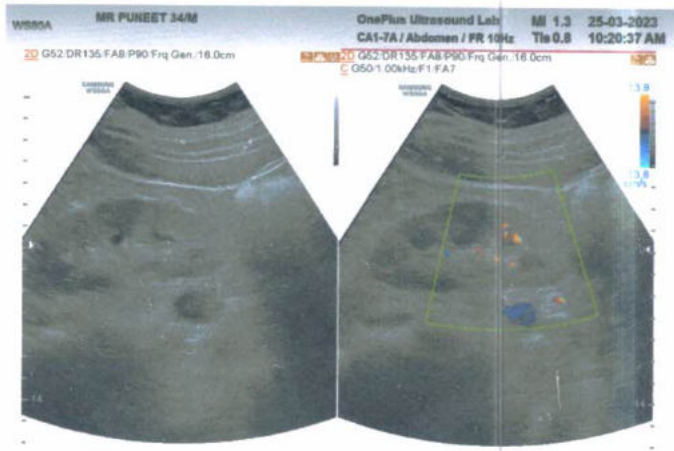
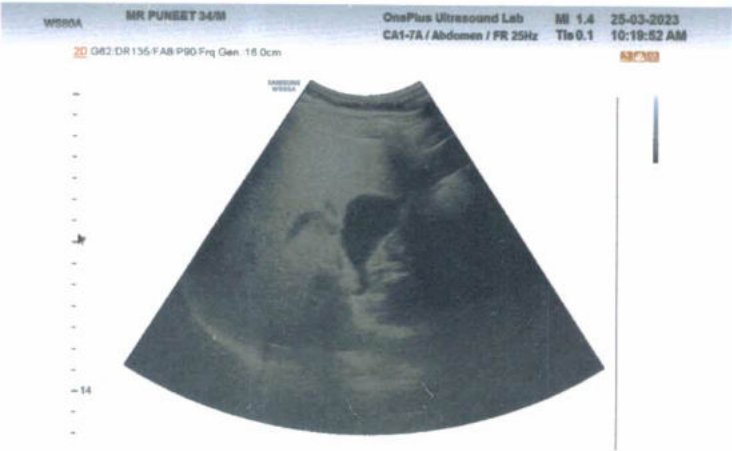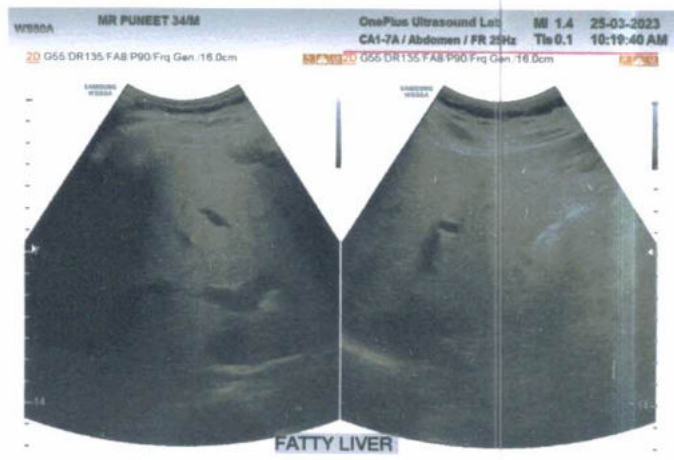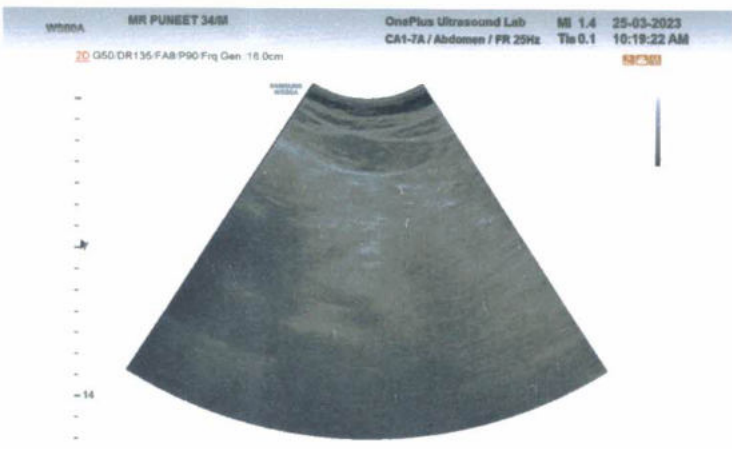
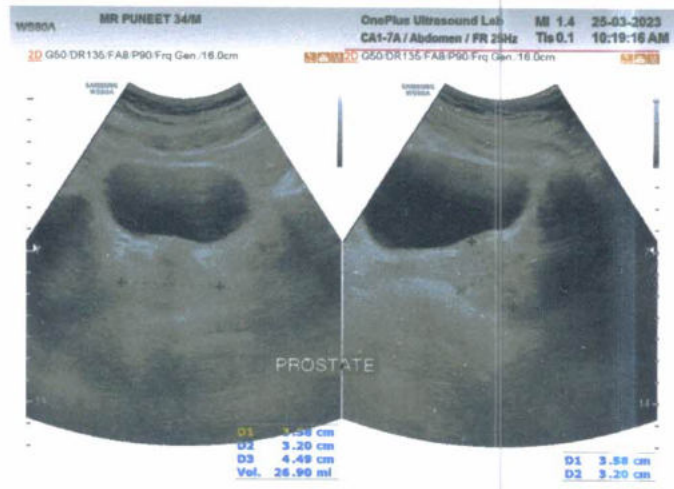
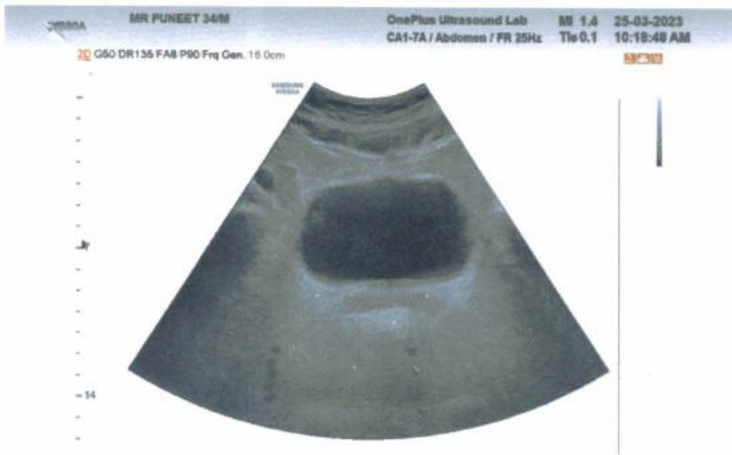- **Fatty infiltration of liver (grade II) with no hepatomegaly.**

DR. POOJA GARG
RADIOLOGIST
REG NO- DMC/R/03398
Dr. POOJA GARG
M.B.B.S., D.M.R.D
Reg No. DMC/R/03398
Radiologist

Type By : darshita

47, Harsh Vihar, Pitampura, New Delhi-110034 | Ph.: 011-42480101, 9599913051

E-mail: oneplusul@gmail.com | Web.: www.oneplusul.in





OnePLUS
Ultrasound Lab

— QUALITY FIRST... ALWAYS! —

Dr. Nitin Agarwal

Pathologist & Director

Ex. Sr. Res. MAMC

& Lok Nayak Hospital

Ex. Chief of Lab Dr. Lal Path Labs.

Dr. Pooja (Garg) Agarwal

Radiologist & Director

MAMC & Lok Nayak Hospital

Name	: Mr. PUNEET KUMAR	Age/Sex	: 34 YRS/Male
Ref. By	: Dr. MEDIWHEEL	Lab No	: 012303250001
Date	: 25-Mar-2023	Patient ID	: LSHH111309

X-ray-Chest PA view

Bony cage and soft tissues are normal.

Cardiothoracic ratio is normal.

Mediastinum is normal.

Both hila are normal.

Both costophrenic angles are clear.

Both domes of diaphragm are normal.

Lung fields are clear. No parenchymal lesion seen.

IMPRESSION: Normal Study.

DR. POOJA GARG
Dr. POOJA GARG
RADIOLOGIST
M.B.B.S. D.M.R.D.
Reg No. DMC/R/03398
Radiologist

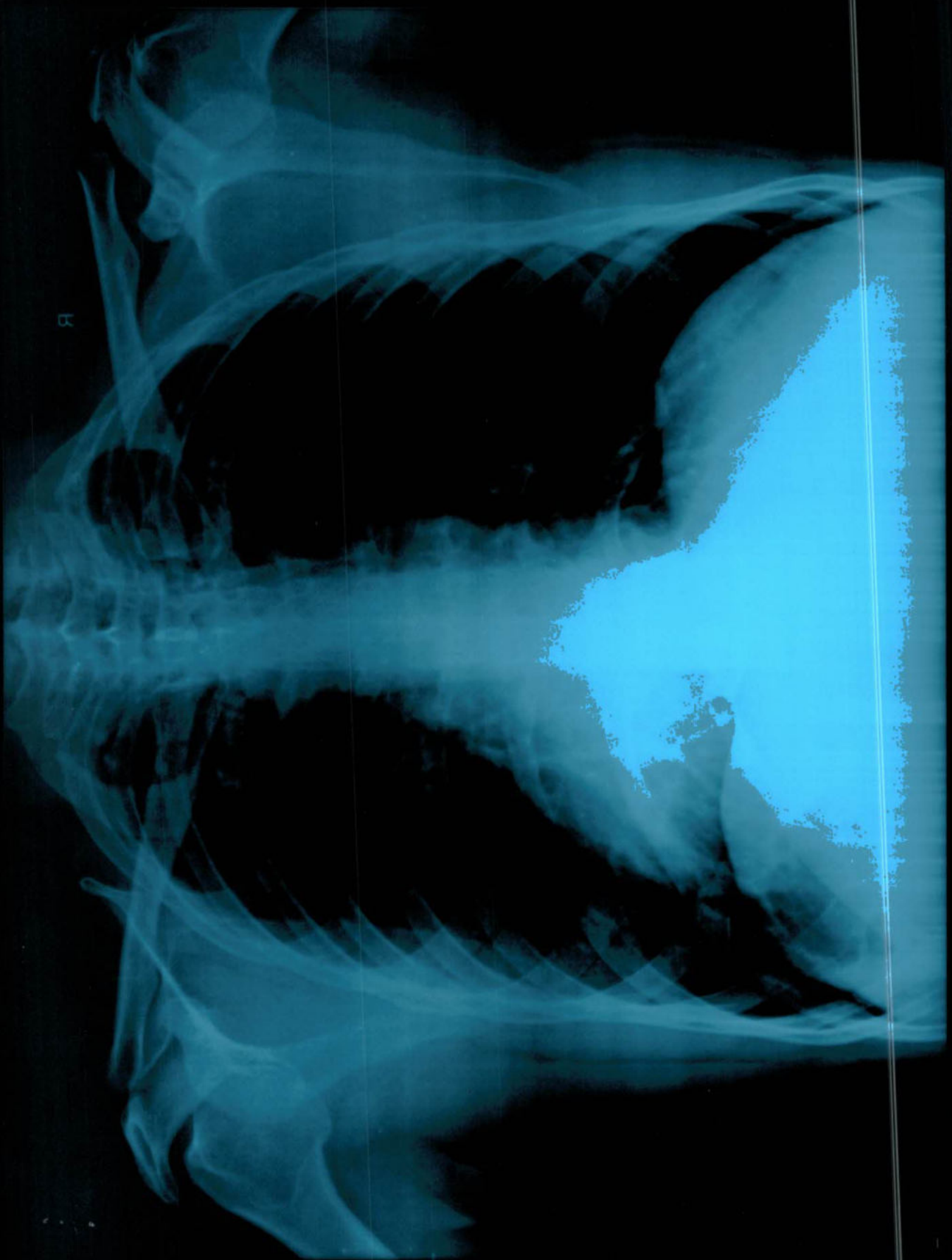
Type By : darshita

47, Harsh Vihar, Pitampura, New Delhi-110034 | Ph.: 011-42480101, 9599913051

E-mail: oneplusul@gmail.com | Web.: www.oneplusul.in

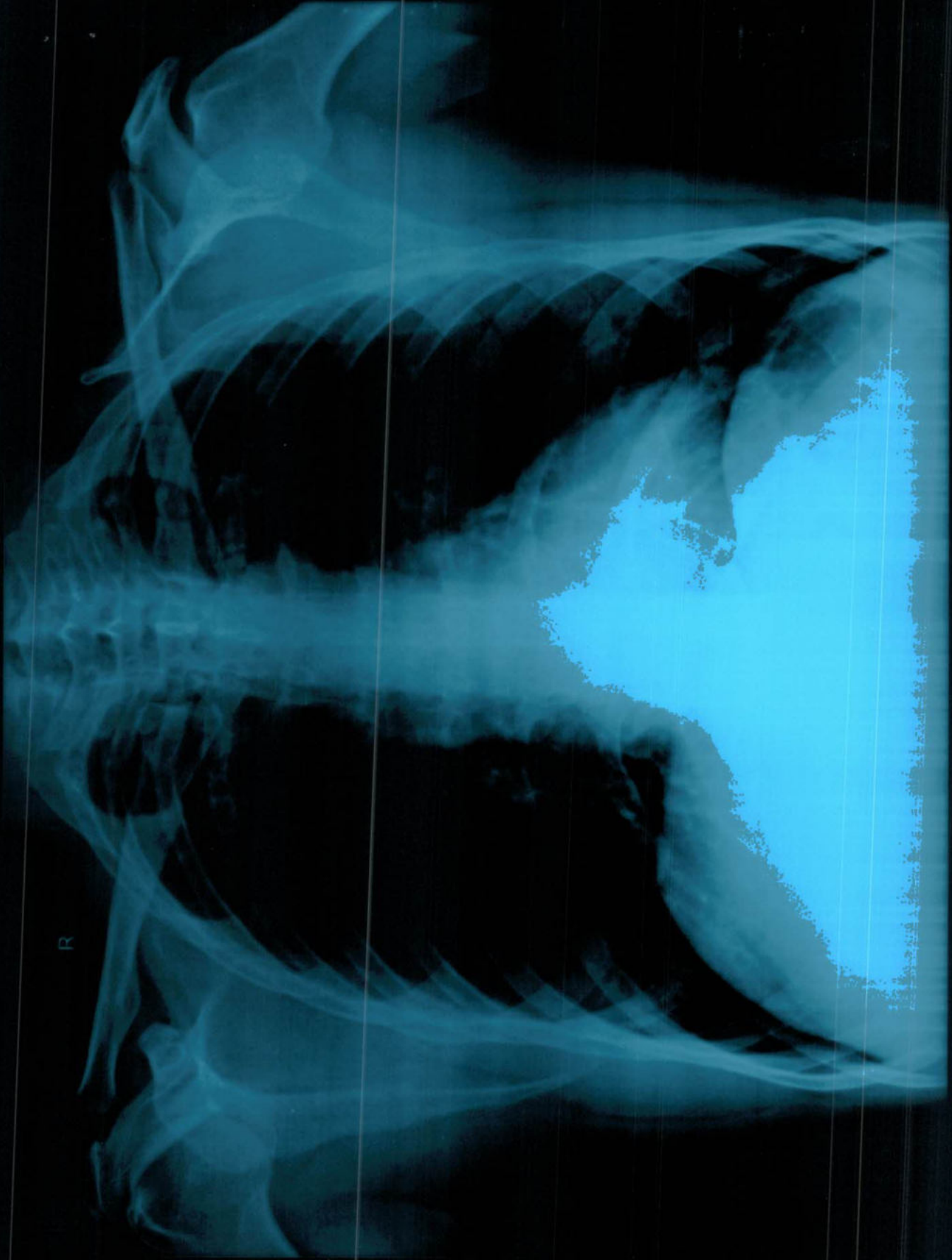
Clinical correlation is essential for final diagnosis. * If test results are unsatisfactory please contact personally or on phone. * This report is for perusal of doctors only.
* All disputes Subject to Delhi Jurisdiction only. * Not for medicolegal purposes. * All congenital anomalies in a foetus may not be diagnosed in routine obstetric ultrasound.

ONE PLUS ULTRASOUND I AB 43 HARSH VIHAR PITAMPURA
MR PUNEET KUMAR 34 YRS S210315053 W CHEST PA VIEW 3/52/5053



R

R



MR PUNEET KUMAR 34 YRS 25/03/2023 M CHEST PA VIEW 3/25/2023
ONEPI US ULTRASOUND LAB 47 HARSH VIHAR PITAMPURA