

**Health Check up Booking Request(bobE24442), Beneficiary Code-45062**

1 message

*37 Years Female*

**Mediwheel** <wellness@mediwheel.in>  
 To: vidhidiagnostics@gmail.com  
 Cc: mediwheelwellness@gmail.com

4 January 2023 at 14:27

**011-41195959**
**Email:wellness@mediwheel.in**

 Dear **VIDHI DIAGNOSTICS**,

City : Ahmedabad . Location : Gujarat,

We have received the confirmation for the following booking .

**Name** : MRS. VAGHELA RESHMABEN CHIRAG  
**Age** : 35  
**Gender** : Female  
**Package Name** : Medi-Wheel Metro Full Body Health Checkup Female Below 40  
**User Location** : ,AHMEDABAD,Gujarat,380009  
**Contact Details** : 9924063513  
**Booking Date** : 04-01-2023  
**Appointment Date** : 07-01-2023

Member Information			
Booked Member Name	Age	Gender	Cost(In INR)
MRS. VAGHELA RESHMABEN CHIRAG	35	Female	Cashless
<b>Total amount to be paid</b>			<b>Cashless</b>

We will get back to you with confirmation update shortly. Please find the package details as attached for your reference.

**Package Name** : Medi-Wheel Metro Full Body Health Checkup Female Below 40 - Includes (37 )Tests

**Tests included in this Package** : Ecg, TSH, X-ray Chest, Stress Test (tmt)/ 2d Echo, Blood Sugar Postprandial, A:g Ratio, Blood Group, Total Cholesterol, Triglycerides, Fasting Blood Sugar, Ultrasound Whole Abdomen , Glycosylated Haemoglobin (hba1c), Hdl, Vldl, Urine Analysis, LDL, Total Protine, General Consultation, HDL/ LDL ratio, GGT(Gamma-glutamyl Transferase), Eye Check-up consultation, ALP (ALKALINE PHOSPHATASE), Uric Acid, AST/ALT Ratio, Serum Protein, CBC with ESR, Stool Analysis, Urine Sugar Fasting, Urine Sugar PP, T3, T4, Cholesterol Total / HDL Ratio, BUN, BUN/Creatinine Ratio, Bilirubin Total & Direct and Indirect, Albumin, Globulin



## Dr. Dinesh S. Modh

M.D., D.M.R.E. (Radiodiagnosis)

Consultant Radiologist & Sonologist

Ex. Junior Lecturer, B.J. Medical College, Civil Hospital, A'bad.

Panel Doctor of L.I.C.

Creating life in Images  
**VIDHI**  
DIAGNOSTICS

28/02/2023

Rehmat Chitsey Nagheer  
37 yr female

Height ! - 160 cm

Weight ! - 69 kg

BP :- 110/76 mmHg

Pulse ! - 58 per min

SpO<sub>2</sub> ! - 98

T ! - (N)

Res (N)  
CNS (N)

Asymptomatic

H/O. Thyroid since 2018  
No H/O DM, HTN or TB

Dr. Vidhi D. Modh  
Reg. No. C-74540  
MIBBS

Vidhi Diagnostics  
L-86, Swatantra-Senani Nagar,  
Opp. Akhbarnagar Bus Terminal,  
Nr. Akhbarnagar Circle,  
New Wadaj, Ahmedabad-13.

ISO 9001:2015 Certified Diagnostics Center

Vidhi Imaging Center

L-86, Swatantra Senani Nagar, Opp. Akhbarnagar Petrol Pump, Nr. Akhbarnagar Circle, Nava-Vadaj, Ahmedabad - 380 013.

Phone : 079-2762 1406, Mobile : 98799 29406, 98250 09406, E-mail : vidhidiagnostics@gmail.com, Website : www.vidhidiagnostics.com

Time : Mon. to Sat. 9.00 am to 2.00 pm, 5.00 pm to 9.00 pm, Sunday 9.00 am to 12.00 Noon

FACILITIES : Live 3D-4D Sonography | Colour Doppler | Echo Cardiography | Interventional Radiology | Fetal Medicine | Digital X-Ray  
Digital Mammography | Digital OPG / TMJ | ECG / TMT / PFT / EEG / EMG | Pathology Laboratory | Health Check Up Plans | Pre Employment Check Up

# Dr. Dinesh S. Modh

M.D., D.M.R.E. (Radiodiagnosis)  
Consultant Radiologist & Sonologist  
Ex. Junior Lecturer, B.J. Medical College, Civil Hospital, A'bad.



28/05/2023

Reshma chiberg vaghela  
37 yr / female

→ Physical examination:-

neck swelling since 5-7 yr (child thyroid swelling)

→ Eye

NO Night blindness & Colour blindness  
G/G normal vision in both eye  
N/G normal vision in both eye

→ Ear:-

Impaired hearing in left ear since 2 yr.  
no pus discharge or whistling. no trauma

Dr. Vidhi D. Modh  
Reg. No. 577540

Vidhi Diagnostics  
Swatantra-Senani Nagar,  
Akhbarnagar Bus Terminals,  
New Wadaj, Ahmedabad-13.

ISO 9001:2015 Certified Diagnostics Center

Vidhi Imaging Center

L-86, Swatantra Senani Nagar, Opp. Indian Oil Petrol Pump, Akhbarnagar Circle, Nava Vadaj, Ahmedabad - 380 013.

Phone : (Radiology) 079-2762 1406 | M. 98799 29406, 98250 09406 | Time (Radiology) : Mon. to Sat. 9 am to 2 pm, 5 to 9 pm, Sunday 9 am to 12 Noon

E-mail : vidhidiagnostics@gmail.com, Website : www.vidhidiagnostics.com

Multislice CT Scan | CBCT-Dental Scan | Live 3D-4D Sonography | Colour Doppler | Echo Cardiography | Interventional Radiology | Maxillofacial Radiology | Fetal Medicine  
Digital X-Ray | Digital Mammography | Digital OPG/TMJ | ECG/TMT/PFT/EEG/EMG | Audiometry | Pathology Laboratory | Health Check Up Plans | Pre Employment Check Up

**CT SCAN & CBCT FACILITY NOW AVAILABLE**

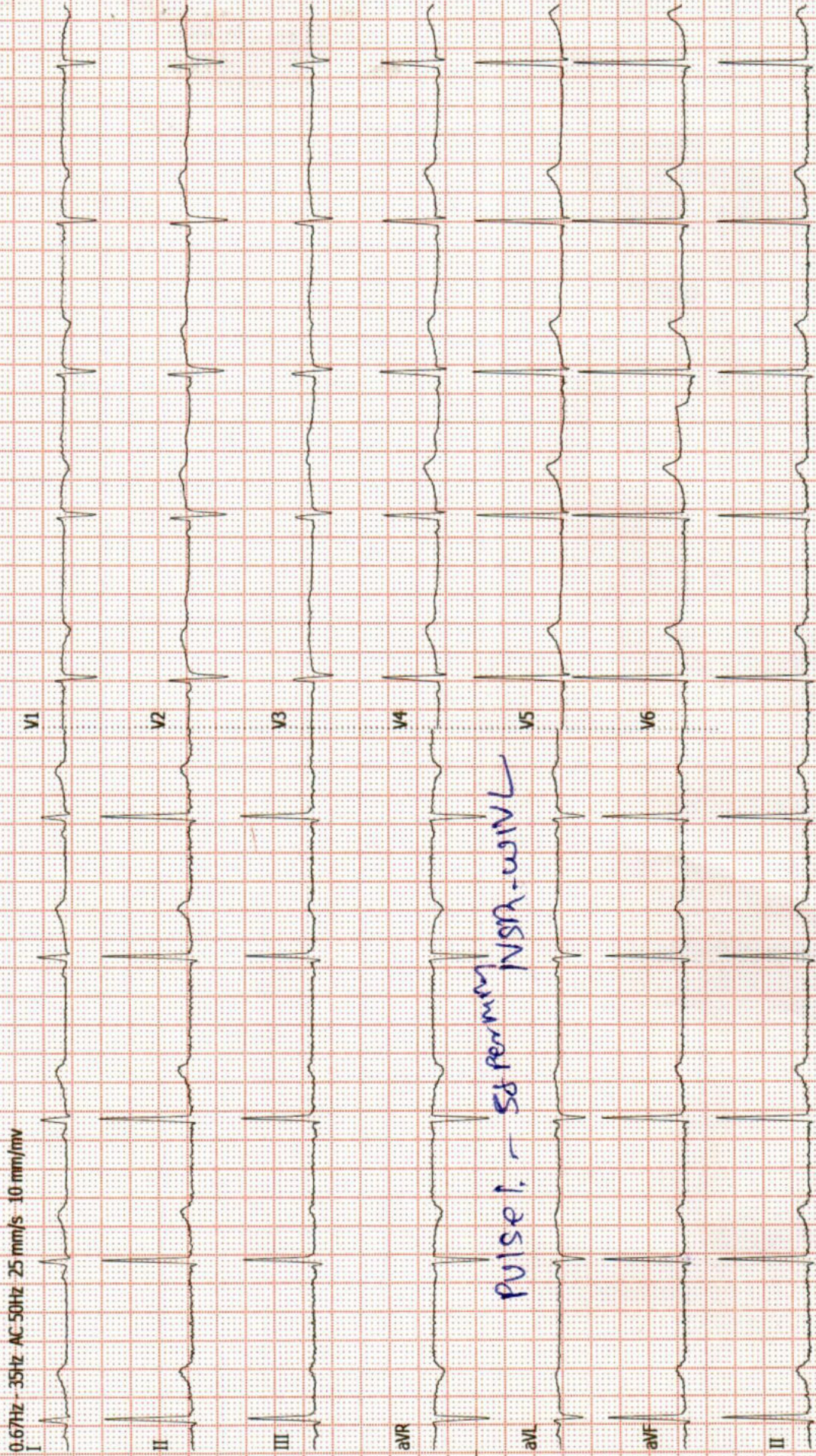


HR : 58 bpm  
 PR : 188 ms  
 QRS : 80 ms  
 QT/QTc : 454/446 ms  
 P/QRS/T : 17/75/31 deg  
 RV5/SVI : 1.513/-0.572 mv  
 RV5+SVI : 2.085 mv

ID: 7562  
 Name: reshmaben c vaghela  
 Age: 37yrs  
 Sex: Female  
 Hospital: **Dr. Avinash Chavan**  
**Dr. Avinash Chavan**  
**Dr. Avinash Chavan**  
**Dr. Avinash Chavan**

### Vidhi Diagnostics

I-80, Swatantra-Senani Nagar,  
 Chhatrapati Sambhaji Maharaj Terminus,  
 Mr. Akhbarnagar Circle,  
 N. West to be confirmed by doctor, Doctor Name:





## Dr. Dinesh S. Modh

M.D., D.M.R.E. (Radiodiagnosis)

Consultant Radiologist & Sonologist

Ex. Junior Lecturer, B.J. Medical College, Civil Hospital, A'bad.

Panel Doctor of L.I.C.



Patient's name : RESHMABEN C VAGHELA  
Reg. ID : R-12206-22  
Referred by : Dr. MEDIWHEEL

Age/Sex : 37 Years/Female  
Accession : 30388  
Date : 28/01/2023

### X-RAY CHEST (PA VIEW)

Both lung fields appear normal.  
No e/o consolidation or cavitations is seen.  
Both costo-phrenic angles appear clear.  
Cardiac size is within normal limits.  
Both domes of diaphragm appear normal.  
Bony thoracic cage appears normal.

Thanks for reference.

Dr. Dinesh S. Modh  
DR. DINESH S. MODH  
MD. D.M.R.E. (Radiodiagnosis)  
M.D. (RADIOLOGIST)  
28/01/2023

ISO 9001:2015 Certified Diagnostics Center

Vidhi Imaging Center

L-86, Swatantra Senani Nagar, Opp. Akharnagar Petrol Pump, Nr. Akharnagar Circle, Nava-Vadaj, Ahmedabad - 380 013.

Phone : 079-2762 1406, Mobile : 98799 29406, 98250 09406, E-mail : vidhidiagnostics@gmail.com, Website : www.vidhidiagnostics.com

Time : Mon. to Sat. 9.00 am to 2.00 pm, 5.00 pm to 9.00 pm, Sunday 9.00 am to 12.00 Noon

FACILITIES : Live 3D-4D Sonography | Colour Doppler | Echo Cardiography | Interventional Radiology | Fetal Medicine | Digital X-Ray  
Digital Mammography | Digital OPG / TMJ | ECG / TMT / PFT / EEG / EMG | Pathology Laboratory | Health Check Up Plans | Pre Employment Check Up



## Dr. Dinesh S. Modh

M.D., D.M.R.E. (Radiodiagnosis)

Consultant Radiologist & Sonologist

Ex. Junior Lecturer, B.J. Medical College, Civil Hospital, A'bad.

**VIDHI**  
DIAGNOSTICS



Patient's name: RESHMABEN C VAGHELA  
Reg. ID : R-12206-22  
Referred by : Dr. MEDIWHEEL

Age/Sex : 37 Years/Female  
Accession : 30388  
Date : 28/01/2023

### **USG ABDOMEN**

**LIVER:** - Liver appears normal in size & show normal echotexture. No evidence of diffuse or focal lesion is seen. Intrahepatic biliary radicals appear normal. Portal vein and CBD appear normal. No e/o calculus is seen in bile duct.

**GALL BLADDER:** - Gall bladder is distended & appears normal. No evidence of calculus or cholecystitis is seen. No evidence of pericholecystic fluid is seen.

**SPLEEN:** - Spleen appears normal in size & shows normal echotexture. No evidence of diffuse or focal lesion is seen.

**PANCREAS:** - Pancreas appears normal size and echopattern. No e/o diffuse or focal lesion is seen. Main pancreatic duct appears normal.

**KIDNEY:-**Both Kidneys appear normal in size & echotexture.

No e/o calculus or hydronephrosis or hydroureter is seen in either side.

Cortico-medullary differentiation is maintained on either side.

Both suprarenal regions appear normal.

**RIF & BOWEL LOOPS (By high frequency probe):-**Normal.

No evidence of pre & para aortic lymphadenopathy is seen.

No evidence of free fluid is seen in abdomen.

No evidence of dilated or thickened bowel loops is seen.

**Urinary bladder:** - appears normal. No e/o calculus or mass lesion is seen in bladder.

Uterus appears normal in size and echopattern.

No evidence of diffuse or focal lesion is seen.

Cervical region appears normal.

Endometrial thickness is 6.4mm. Cu-T is seen in situ.

Both ovaries and adnexal regions appear normal.

No e/o free fluid is seen in pouch of Douglas.

Thanks for reference.

**Dr. Dinesh S. Modh**  
MD DMRE (Radiodiagnosis)  
DR DINESH S. MODH  
M.D. DMRE(RADIODIAGNOSIS)

ISO 9001:2015 Certified Diagnostics Center

Vidhi Imaging Center

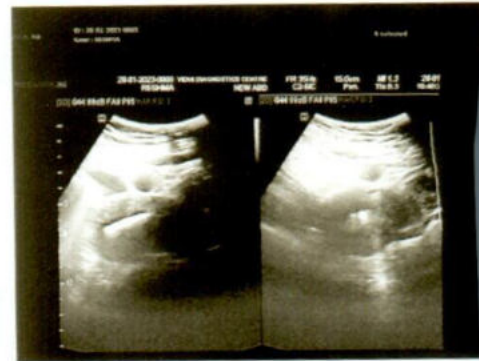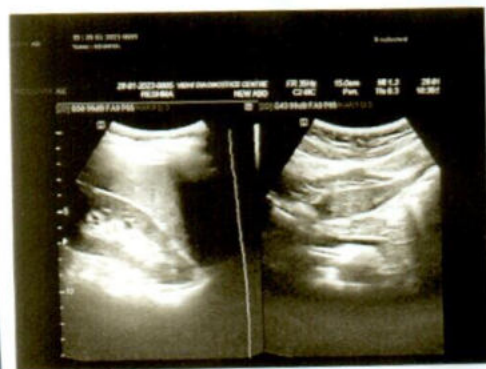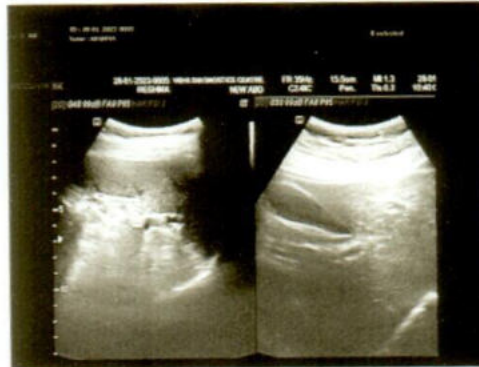
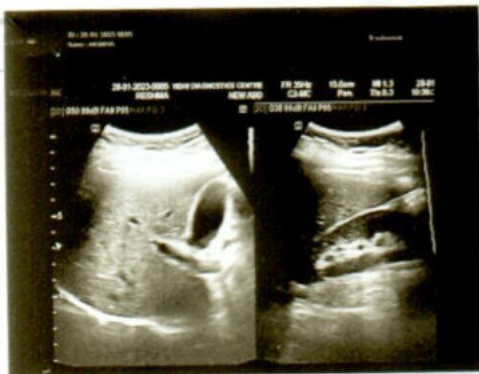L-86, Swatantra Senani Nagar, Opp. Indian Oil Petrol Pump, Akhbarnagar Circle, Nava Vadaj, Ahmedabad - 380 013.

Phone : (Radiology) 079-2762 1406 | M. 98799 29406, 98250 09406 | Time (Radiology) : Mon. to Sat. 9 am to 2 pm, 5 to 9 pm, Sunday 9 am to 12 Noon

E-mail : vidhidiagnostics@gmail.com, Website : www.vidhidiagnostics.com

Multislice CT Scan | CBCT-Dental Scan | Live 3D-4D Sonography | Colour Doppler | Echo Cardiography | Interventional Radiology | Maxillofacial Radiology | Fetal Medicine  
Digital X-Ray | Digital Mammography | Digital OPG/TMJ | ECG/TMT/PFT/EEG/EMG | Audiometry | Pathology Laboratory | Health Check Up Plans | Pre Employment Check Up

**CT SCAN & CBCT FACILITY NOW AVAILABLE**





## Dr. Dinesh S. Modh

M.D., D.M.R.E. (Radiodiagnosis)  
Consultant Radiologist & Sonologist  
Ex. Junior Lecturer, B.J. Medical College, Civil Hospital, A'bad.  
Panel Doctor of L.I.C.



Patient's name : RESHMABEN C VAGHELA  
Reg. ID : R-12206-22  
Referred by : Dr. MEDIWHEEL

Age/Sex : 37 Years/Female  
Accession : 30388  
Date : 28/01/2023

### 2D- ECHO REPORT

#### FINAL CONCLUSION:

LV IS NORMAL SIZE. GOOD LV SYSTOLIC FUNCTION NO RWMA.  
LVEF - 60%. NO CONCENTRIC LVH.  
NORMAL LV COMPLIANCE.  
LA IS NORMAL SIZE. NO LA CLOT.  
RV IS NORMAL SIZE. GOOD RV SYSTOLIC FUNCTION.  
RA IS NORMAL SIZE.  
MITRAL VALVE IS NORMAL. NO MS. TRIVIAL MR. NO MVP.  
AORTIC VALVE IS NORMAL. NO AS. NO AR.  
TRICUSPID VALVE IS NORMAL. NO TR. RVSP-26 mmHg. NO PAH.

NO CLOT, NO VEGETATION, NO PERICARDIAL EFFUSION.

#### DIMENSIONS:

AORTA	2.6 C.M
LEFT ATRIUM	2.7 C.M
LVDD	4.1 C.M.
IVSD	1.0 C.M
PWD	1.0 C.M
LVDS	2.6 C.M.

#### COLOUR DOPPLER FINDING:

STRUCTURE	VELOCITY m/sec
	Max
PULMONARY VALVE	0.7
MITRAL VALVE	E : 0.7 A: 0.4
AORTIC VALVE	1.0

Dr. Avinash Bhaskar  
MBBS, D Cardio  
Reg. No. 12206

DR AVINASH BHASKAR  
CLINICAL CARDIOLOGIST

### Vidhi Diagnostics

L-86, Swatantra-Senani Nagar,  
Opp. Akhbarnagar Bus Terminals,  
Nr. Akhbarnagar Circle,  
New Wadaj, Ahmedabad-13.

ISO 9001:2015 Certified Diagnostics Center

Vidhi Imaging Center

L-86, Swatantra Senani Nagar, Opp. Akhbarnagar Petrol Pump, Nr. Akhbarnagar Circle, Nava-Vadaj, Ahmedabad - 380 013.

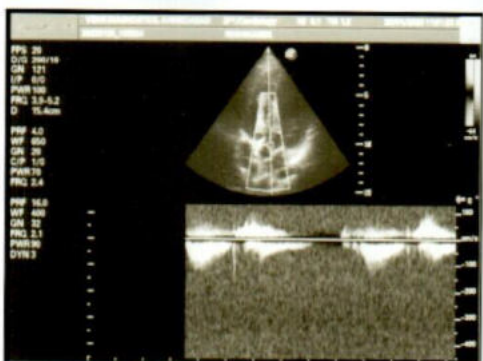
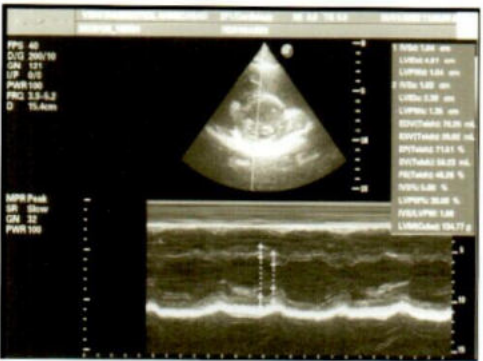
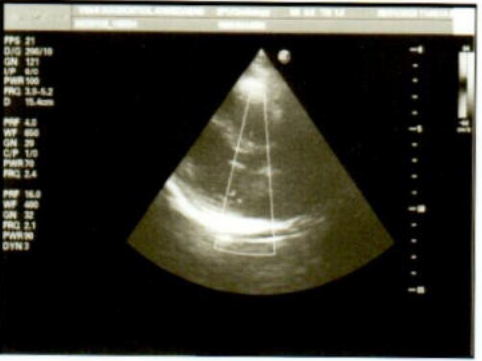
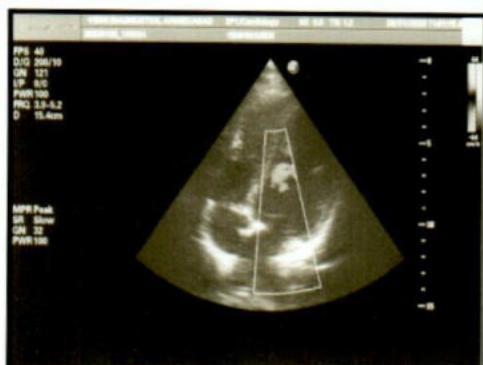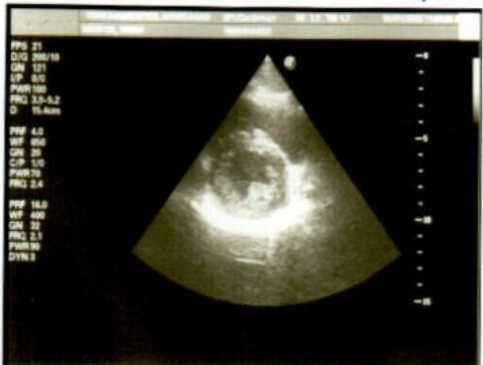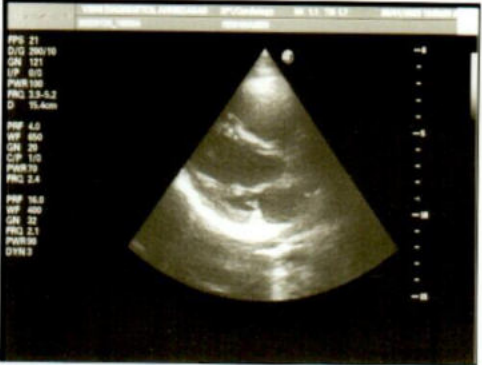Phone : 079-2762 1406, Mobile : 98799 29406, 98250 09406, E-mail : vidhidiagnostics@gmail.com, Website : www.vidhidiagnostics.com

Time : Mon. to Sat. 9.00 am to 2.00 pm, 5.00 pm to 9.00 pm, Sunday 9.00 am to 12.00 Noon

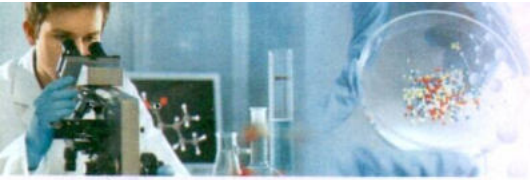FACILITIES : Live 3D-4D Sonography | Colour Doppler | Echo Cardiography | Interventional Radiology | Fetal Medicine | Digital X-Ray  
Digital Mammography | Digital OPG / TMJ | ECG / TMT / PFT / EEG / EMG | Pathology Laboratory | Health Check Up Plans | Pre Employment Check Up



Reel 1 mel







Pathology Department

**VIDHI**  
DIAGNOSTICS

Creating Life in Progress

Patient's name : RESHMABEN C VAGHELA  
Age/Sex : 37 Years/Female  
Referred by : Dr. MEDIWHEEL  
Collection Time : 09:54

Reg. ID : P-6907-22  
Accession : 30380  
Order Dt/time : 28/01/2023 09:54

**Complete Blood Count**

Sample Type: EDTA

Test Name	Result	Units	Biological Reference Interval
<b><u>Blood Counts</u></b>			
Haemoglobin :	<b>12.3</b>	Gms%	12.5 - 16.0
Total R.B.C. :	<b>3.96</b>	mill/c.mm	4.2 - 5.4
Total W. B. C. :	7,750	/cu mm	4000 - 10500
Platelet Count :	2,87,000	/cu.mm	1,50,000 - 4,50,000
<b><u>Differential Count</u></b>			
Neutrophils :	70	%	40 - 70
Lymphocytes :	26	%	20 - 40
Eosinophils :	02	%	1 - 4
Monocytes :	02	%	2 - 6
Basophils :	00	%	0 - 01
<b><u>Blood Indices</u></b>			
P. C. V :	<b>36.2</b>	%	37 - 47
M. C. V. :	91.4	fl	78 - 100
M.C.H :	31.0	pg	27 - 31
M. C. H. C :	33.9	%	32 - 36
R.D.W :	13.2	%	11.5 - 14.0
<b><u>E.S.R.( Westergren Method )</u></b>			
After one hour :	10	mm/hr	3 - 12

TESTS DONE ON FULLY AUTOMATED HEMATOLOGY ANALYZER.

*Dr. Gayatri M. Mehta*  
M. D. (Patho)

DR GAYATRI MEHTA  
MD(PATHOLOGY)

DR. ANAND D. PARIKH  
MD(PATHOLOGY)

LAB USE ONLY (Entered by :GM Enter Date/Time:28/01/2023 11:27:00 AM) (Verify by :GM Verify Date/Time:28/01/2023 11:27:00 AM)

ISO 9001:2015 Certified Diagnostics Center

Vidhi Imaging Center | Pathology Department

L-86, Swatantra Senani Nagar, Opp. Akhbarnagar Petrol Pump, Nr. Akhbarnagar Circle, Nava-Vadaj, Ahmedabad - 380 013.

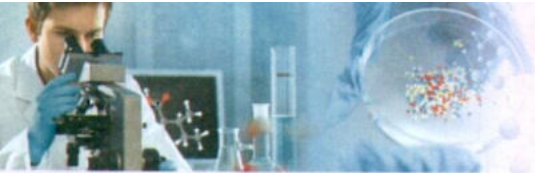Ph. (Pathology) : 079-2762 1406, 8849893954 M. 98799 29406, 98250 09406, E-mail : vidhidiagnostics@gmail.com, Web. : www.vidhidiagnostics.com

Time (Pathology) : Mon. to Sat. 8.30 am to 8.00 pm, Sunday 9 am to 12 Noon

*Pathology means science behind medicine*

**CT SCAN & CBCT FACILITY NOW AVAILABLE**





Pathology Department



Patient's name : RESHMABEN C VAGHELA  
Age/Sex : 37 Years/Female  
Referred by : Dr. MEDIWHEEL  
Collection Time : 09:54

Reg. ID : P-6907-22  
Accession : 30380  
Order Dt/time : 28/01/2023 09:54

### Blood Group

Sample Type: EDTA sample.

Test Name	Result
BG :	" O "
RH :	POSITIVE
Remarks	Done by forward grouping method.

### Blood Glucose

Sample Type: Serum

Test Name	Result	Units	Biological Reference Interval
Fasting Blood Glucose : <i>GOD-POD Method.</i>	86.5	mg/dl	70 - 110

### Blood Glucose

Sample Type: Serum

Test Name	Result	Units	Biological Reference Interval
Post Prandial Blood Glucose After 2hr. : <i>GOD-POD Method.</i>	95.5	mg/dl	80 - 140

*Dr. Gayatri M. Mehta*  
M. D. (Patho)  
DR GAYATRI MEHTA  
MD(PATHOLOGY)  
Reg. No. G-32215

DR. ANAND D. PARIKH  
MD(PATHOLOGY)

LAB USE ONLY (Entered by :GM Enter Date/Time:28/01/2023 2:49:00 PM) (Verify by :GM Verify Date/Time:28/01/2023 2:49:00 PM)

ISO 9001:2015 Certified Diagnostics Center

Vidhi Imaging Center | Pathology Department

L-86, Swatantra Senani Nagar, Opp. Akhbarnagar Petrol Pump, Nr. Akhbarnagar Circle, Nava-Vadaj, Ahmedabad - 380 013.

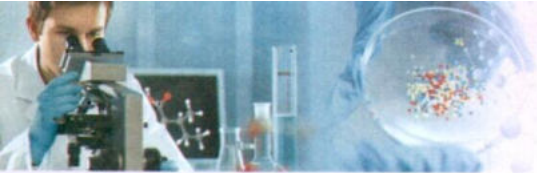Ph. (Pathology) : 079-2762 1406, 8849893954 M. 98799 29406, 98250 09406, E-mail : vidhidiagnostics@gmail.com, Web. : www.vidhidiagnostics.com

Time (Pathology) : Mon. to Sat. 8.30 am to 8.00 pm, Sunday 9 am to 12 Noon

*Pathology means science behind medicine*

**CT SCAN & CBCT FACILITY NOW AVAILABLE**





Pathology Department



Patient's name : RESHMABEN C VAGHELA  
 Age/Sex : 37 Years/Female  
 Referred by : Dr. MEDIWHEEL  
 Collection Time : 09:54

Reg. ID : P-6907-22  
 Accession : 30380  
 Order Dt/time : 28/01/2023 09:54

**HbA1C**

Sample Type: Serum

Test Name	Result	Units	Biological Reference Interval
HbA1C :	5.0	%	Non-diabetic: 4.2-6.2 Pre-diabetic : 6.3-7.2 Diabetic : 7.3-8.2
Mean Blood Glucose of Last 03 months.	96.8	mg/dl	

**Comment**

\*As per the new 2009 update of American Diabetes Association regarding HbA1C & Mean Blood Glucose relationship.

**NOTE:**

This test is used to monitor diabetic patients compliance with the therapeutic regimen and logo It's level is proportional to both the average blood glucose concentration and the life span of the red blood cells (RBC) in circulation. HbA1c values are free of day to day glucose fluctuations and are unaffected by exercise or recent food intake.

*Dr. Gayatri M. Mehta*

M. D. (Patho)

Reg. No. G-32215

DR GAYATRI MEHTA  
 MD(PATHOLOGY)

DR. ANAND D. PARIKH  
 MD(PATHOLOGY)

LAB USE ONLY (Entered by :GM Enter Date/Time:28/01/2023 1:18:00 PM) (Verify by :GM Verify Date/Time:28/01/2023 1:18:00 PM)

ISO 9001:2015 Certified Diagnostics Center

Vidhi Imaging Center | Pathology Department

L-86, Swatantra Senani Nagar, Opp. Akhbarnagar Petrol Pump, Nr. Akhbarnagar Circle, Nava-Vadaj, Ahmedabad - 380 013.

Ph. (Pathology) : 079-2762 1406, 8849893954 M. 98799 29406, 98250 09406, E-mail : vidhidiagnostics@gmail.com, Web. : www.vidhidiagnostics.com

Time (Pathology) : Mon. to Sat. 8.30 am to 8.00 pm, Sunday 9 am to 12 Noon

*Pathology means science behind medicine*

**CT SCAN & CBCT FACILITY NOW AVAILABLE**





Pathology Department



Patient's name : RESHMABEN C VAGHELA  
Age/Sex : 37 Years/Female  
Referred by : Dr. MEDIWHEEL  
Collection Time : 09:54

Reg. ID : P-6907-22  
Accession : 30380  
Order Dt/time : 28/01/2023 09:54

### Lipid Profile

Sample Type: Serum

Test Name	Result	Units	Biological Reference Interval
<b>S. Cholesterol :</b> Oxidase-esterase method.	177.0	mg/dl	0 - 200
<b>S. Triglyceride :</b> Enzymatic Colorimetry method	67.5	mg/dL	0 - 200
<b>S. HDL - Cholesterol :</b> Serum by Enzymatic method.	51.6	mg/dL	35 - 65
<b>S. LDL - Cholesterol :</b> Serum by Enzymatic method	111.9	mg/dL	0 - 130
<b>S. VLDL - Cholesterol :</b>	13.5	mg/dL	0 - 30
<b>S. Chole/HDL.Ratio :</b>	3.43		1 - 6
<b>S. LDL / HDL Cholesterol Ratio :</b>	2.17		0 - 3.5

*Dr. Gayatri M. Mehta*  
M. D. (Patho)  
Reg. No. G-32215  
DR GAYATRI MEHTA  
MD(PATHOLOGY)

DR. ANAND D. PARIKH  
MD(PATHOLOGY)

LAB USE ONLY (Entered by :GM Enter Date/Time:28/01/2023 1:18:00 PM) (Verify by :GM Verify Date/Time:28/01/2023 1:18:00 PM)

ISO 9001:2015 Certified Diagnostics Center

Vidhi Imaging Center | Pathology Department

L-86, Swatantra Senani Nagar, Opp. Akhbarnagar Petrol Pump, Nr. Akhbarnagar Circle, Nava-Vadaj, Ahmedabad - 380 013.

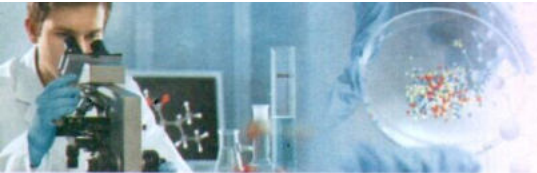Ph. (Pathology) : 079-2762 1406, 8849893954 M. 98799 29406, 98250 09406, E-mail : vidhidiagnostics@gmail.com, Web. : www.vidhidiagnostics.com

Time (Pathology) : Mon. to Sat. 8.30 am to 8.00 pm, Sunday 9 am to 12 Noon

*Pathology means science behind medicine*

**CT SCAN & CBCT FACILITY NOW AVAILABLE**





Pathology Department



Patient's name : RESHMABEN C VAGHELA  
Age/Sex : 37 Years/Female  
Referred by : Dr. MEDIWHEEL  
Collection Time : 09:54

Reg. ID : P-6907-22  
Accession : 30380  
Order Dt/time : 28/01/2023 09:54

**BIOCHEMISTRY**

Sample type :Serum

Test Name	Result	Units	Biological Reference Interval
<b>Urea</b> , (Serum by GLDH method) :	19.9	mg/dl	10 - 50
<b>S.Uric acid</b> , (Serum by Uricase method) :	4.2	mg/dl	2.6-6.0
<b>Bun</b> :	9.3	mg/dl	6-20
<b>Creatinine</b> , (Serum by Enzymatic reaction) :	0.63	mg/dl	0.5-1.2
<b>S.G.P.T (ALT)</b> : (Serum by IFCC method )	18.6	U/L	0 - 40
<b>S.G.O.T (AST)</b> : (Serum by IFCC method )	20.0	U/L	0 - 37
<b>ALK.PHOSPHATASE</b> : (Serum by PNP method )	73.0	U/L	35-104
<b>G.G.T</b> :	12.8	U/L	8 - 78
<b>BILIRUBIN</b>			
<b>Total</b> :	0.84	mg/dl	Up to 1.2
<b>Direct</b> :	0.36	mg/dl	0-0.7
<b>Indirect</b> :	0.48	mg/dl	0 - 0.5
<b>SERUM PROTEINS</b>			
<b>Total Protein</b> (Serum by Biuret method) :	7.41	gms/dl	6.4 - 8.5
<b>Albumin</b> (Serum by BCG method) :	4.03	gms/dl	3.97-4.94
<b>Globulins</b> :	3.38	gms/dl	2.3 - 3.5
<b>A/G Ratio</b> :	1.192		0.9 - 2.9

*Dr. Gayatri M. Mehta*  
M. D. (Patho)

Reg. No. G-32215  
DR GAYATRI MEHTA  
MD(PATHOLOGY)

DR. ANAND D. PARIKH  
MD(PATHOLOGY)

LAB USE ONLY (Entered by :GM Enter Date/Time:28/01/2023 1:18:00 PM) (Verify by :GM Verify Date/Time:28/01/2023 1:18:00 PM)

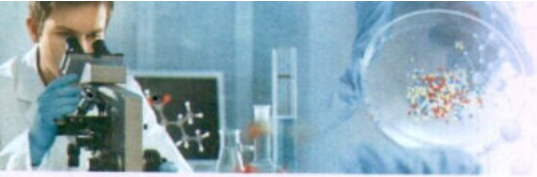ISO 9001:2015 Certified Diagnostics Center  
Vidhi Imaging Center | Pathology Department

L-86, Swatantra Senani Nagar, Opp. Akhbaragar Petrol Pump, Nr. Akhbaragar Circle, Nava-Vadaj, Ahmedabad - 380 013.  
Ph. (Pathology) : 079-2762 1406, 8849893954 M. 98799 29406, 98250 09406, E-mail : vidhidiagnostics@gmail.com, Web. : www.vidhidiagnostics.com  
Time (Pathology) : Mon. to Sat. 8.30 am to 8.00 pm, Sunday 9 am to 12 Noon

*Pathology means science behind medicine*

**CT SCAN & CBCT FACILITY NOW AVAILABLE**





Pathology Department



Patient's name : RESHMABEN C VAGHELA  
Age/Sex : 37 Years/Female  
Referred by : Dr. MEDIWHEEL  
Collection Time : 09:54

Reg. ID : P-6907-22  
Accession : 30380  
Order Dt/time : 28/01/2023 09:54

### Thyroid Function Test

Sample Type: Serum

Test Name	Result	Units	Biological Reference Interval
TOTAL T3 :	1.48	ng/ml	0.84 - 2.0
TOTAL T4 :	8.4	ug/dl	5.1 - 14.0
TSH(Ultra sensitive) :	3.890	mIU/L	0.27 - 4.2

*Dr. Gayatri M. Mehta*  
M. D. (Patho)  
Reg. No. G-32215

DR GAYATRI MEHTA  
MD(PATHOLOGY)

DR. ANAND D. PARIKH  
MD(PATHOLOGY)

LAB USE ONLY (Entered by :GM Enter Date/Time:28/01/2023 1:18:00 PM) (Verify by :GM Verify Date/Time:28/01/2023 1:18:00 PM)

ISO 9001:2015 Certified Diagnostics Center

Vidhi Imaging Center | Pathology Department

L-86, Swatantra Senani Nagar, Opp. Akhbaragar Petrol Pump, Nr. Akhbaragar Circle, Nava-Vadaj, Ahmedabad - 380 013.

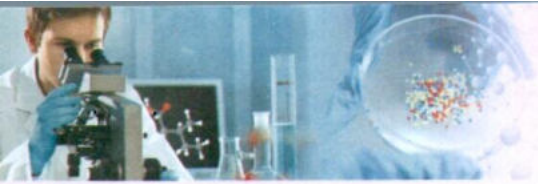Ph. (Pathology) : 079-2762 1406, 8849893954 M. 98799 29406, 98250 09406, E-mail : vidhidiagnostics@gmail.com, Web. : www.vidhidiagnostics.com

Time (Pathology) : Mon. to Sat. 8.30 am to 8.00 pm, Sunday 9 am to 12 Noon

*Pathology means science behind medicine*

**CT SCAN & CBCT FACILITY NOW AVAILABLE**





Pathology Department



Patient's name : RESHMABEN C VAGHELA  
Age/Sex : 37 Years/Female  
Referred by : Dr. MEDIWHEEL  
Collection Time : 09:54

Reg. ID : P-6907-22  
Accession : 30380  
Order Dt/time : 28/01/2023 09:54

**Urine Analysis**

Sample Type: Urine

Test Name	Result	Units	Biological Reference Interval
<b><u>Physical Examination</u></b>			
Quantity :	20	ml	0 - 500 ml
Colour :	Pale Yellow		Pale Yellow
Transparency :	Slight Turbid.		Clear
Reaction :	Acidic		4.6 - 8.0
Specific Gravity :	1.030		1.016 - 1.022
Sediment :	Present		
<b><u>Chemical Examination</u></b>			
Albumin :	Present (Faint Trace)		Absent
Sugar :	NIL		Absent
Acetone :	Absent		Absent
Bile Salts :	Absent		Absent
Bile Pigments :	Absent		Absent
Urobilogen :	Absent		Absent
Nitrites :	Absent		Absent
<b><u>Microscopic Examination</u></b>			
Red blood Cells :	1-2	/h.p.f	Absent
Pus Cells :	2-3	/h.p.f	Absent
Epithelial Cells :	1-2	/h.p.f	< 10.0
Amorphous :	Absent	/h.p.f	Absent
Bacteria :	Absent	/h.p.f	Absent
Crystals :	Absent	/h.p.f	Absent
Casts :	Absent	/h.p.f	Absent
Fungus :	Not seen	/h.p.f	Absent

*Dr. Gayatri M. Mehta*

M. D. (Patho)

Reg. No. G-32215

DR GAYATRI MEHTA  
MD(PATHOLOGY)

DR. ANAND D. PARIKH  
MD(PATHOLOGY)

ISO 9001:2015 Certified Diagnostics Center

LAB USE ONLY (Entered by : GM Enter Date/Time: 28/01/2023 11:18:00 AM Pathology Department Verify by : GSM Verify Date/Time: 28/01/2023 11:18:00 PM)

L-86, Swatantra Senani Nagar, Opp. Akhbarnagar Petrol Pump, Nr. Akhbarnagar Circle, Nava-Vadaj, Ahmedabad - 380 013.

Ph. (Pathology) : 079-2762 1406, 8849893954 M. 98799 29406, 98250 09406, E-mail : vidhidiagnostics@gmail.com, Web : www.vidhidiagnostics.com

Time (Pathology) : Mon. to Sat. 8.30 am to 8.00 pm, Sunday 9 am to 12 Noon

*Pathology means science behind medicine*

**CT SCAN & CBCT FACILITY NOW AVAILABLE**



## Dr. Dinesh S. Modh

M.D., D.M.R.E. (Radiodiagnosis)

Consultant Radiologist & Sonologist

Ex. Junior Lecturer, B.J. Medical College, Civil Hospital, A'bad.

Panel Doctor of L.I.C.



મારી શબ્દ વા ઉપર કોઈપણ માર  
સંભળો

28/1/23

રૂઝા સિદ્ધી

ISO 9001:2015 Certified Diagnostics Center

Vidhi Imaging Center, L-86, Swatantra Senani Nagar, Opp. Akhbarnagar Petrol Pump, Nr. Akhbarnagar Circle, Nava-Vadaj, Ahmedabad - 380 013.

Phone : 079-2762 1406, Mobile : 98799 29406, 98250 09406, E-mail : vidhidiagnostics@gmail.com, Website : www.vidhidiagnostics.com

FACILITIES : Live 3D-4D Sonography | Colour Doppler | Echo Cardiography | Interventional Radiology | Fetal Medicine | Digital X-Ray  
Digital Mammography | Digital OPG / TMJ | ECG / TMT / PFT / EEG / EMG | Pathology Laboratory | Health Check Up Plans | Pre Employment Check Up



UNION OF INDIA **Driving Licence** (GJ) (NT)

GUJARAT STATE

GJ01-2016004023

Date of First Issue: 26-12-2016

Validity: 17-09-2035

CDOK: 08-10-2018

Date of Birth: 18-09-1985

Blood Group: O+ VE

Name: RESHMABEN C VAGHELA

Relationship: Son/Daughter/Wife of

CHIRAG VAGHELA

*Chirag Vaghela*


**Vidhi Diagnostics**  
 L-86, Swatantra-Senani Nagar,  
 Opp. Akhbarnagar Bus Terminals,  
 Nr. Akhbarnagar Circle,  
 New Wadaj, Ahmedabad-13.

Dr. Vidhi D. Modi  
 MBBS  
 Reg. No. G-74540



~~Roshaben~~

Roshaben



GPS Map Camera

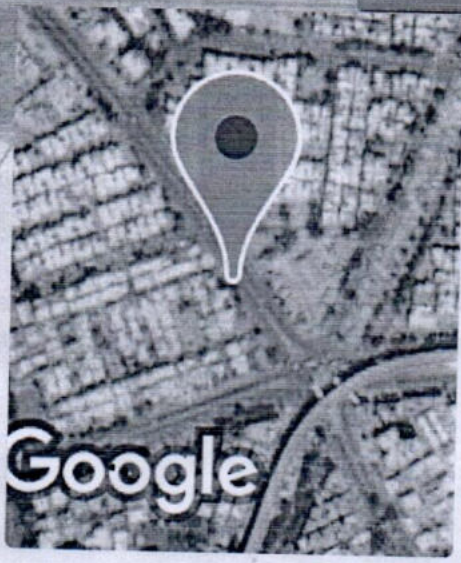
Ahmedabad, Gujarat, India

3H96+6PR, Chandlodiya Rd,  
Swatantra Senani Nagar, Nava Vadaj,  
Ahmedabad, Gujarat 380013, India

Lat 23.068153°

Long 72.561767°

28/01/23 09:39 AM GMT +05:30



Dr. Vidhi D. Modh  
MBBS  
Reg. No. G/15540

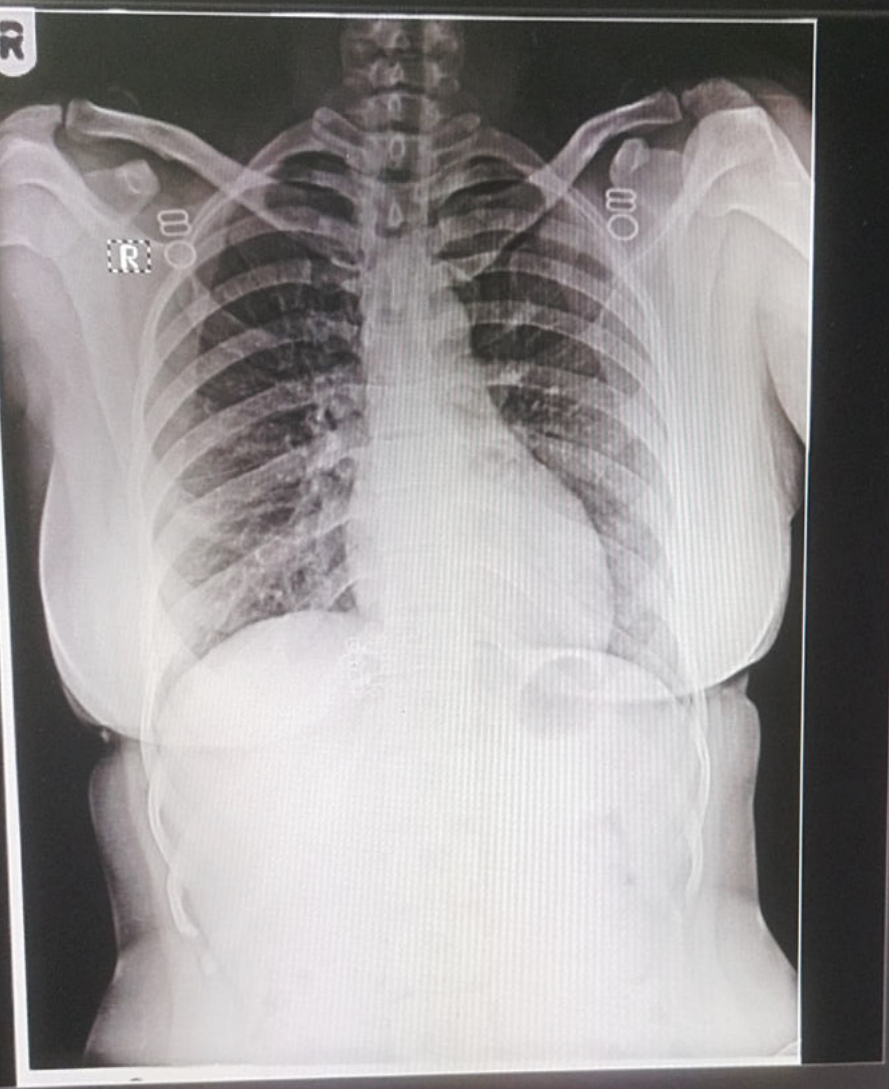
**Vidhi Diagnostics**  
L-86, Swatantra-Senani Nagar,  
Opp. Akhbarnagar Bus Terminal,  
Nr. Akhbarnagar Circle,  
New Wadaj, Ahmedabad-13.



Dr. Dinesh S. M.

12303

RESHMABEN C VAGHELA 37YI



MAI

GA

GS

S

Navigation icons: zoom in, zoom out, window, and other controls.

1 (1)

Navigation icons: back, forward, close, search, and other controls.

DELL