

बैंक ऑफ बड़ौदा
Bank of Baroda



नाम- कपिल कुमार
Name - KAPIL KUMAR
कर्मचारी कूट क्र- 182822
E.C.No. - 182822

जारीकर्ता प्राधिकारी
Issuing Authority

धारक के हस्ताक्षर
Signature of Holder

मिलने पर निम्नलिखित को लौटाएं
सहायक महाप्रबन्धक (सुरक्षा)
बैंक ऑफ बड़ौदा कॉर्पोरेट सेंटर
सी-26, जी-ब्लॉक, बान्द्रा कुर्ला, कॉम्प्लेक्स, मुंबई 400 051, भारत
फोन 91 22 5698 5196 फैक्स 91 22 2652 5747

If found, Please return to
Assst. General Manager (Security)
Bank of Baroda, Baroda Corporate Centre
C-28, G-Block, Bandra Kurla Complex, Mumbai - 400 519 India
Phone - 91 22 5698 5196 Fax - 91 22 2652 5747
रक्त समूह/Blood Group: **B+ve**
पहचान चिन्ह/Identification Mark-**Mark on Forehead**


DR. J.K. GULATI
MD, DNB
GULATI HOSPITAL
Near Bus Stand, Yamuna Nagar



भारतीय विशिष्ट पहचान प्राधिकरण
Unique Identification Authority of India

पता:
S/O: राज कुमार, गाँव खेडा फार्म, खेडा (423),
यमुनानगर,
हरियाणा - 135003

Address:
S/O: Raj Kumar, village khera farm,
Khera (423), Yamunanagar,
Haryana - 135003



QR Code with Photograph

3585 5720 9784

VID: 9157 5225 6677 4996



UIDAI


www.uidai.gov.in



भारत सरकार
Government of India



कपिल कुमार
Kapil Kumar
जन्म तिथि/DOB: 07/10/1993
पुरुष/ MALE



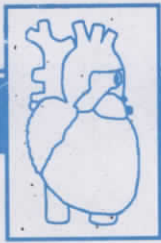
3585 5720 9784

VID: 9157 5225 6677 4996

मेरा आधार, मेरी पहचान

Antel

DR. J.K. GULATI
MD, DNB
GULATI HOSPITAL
Near Bus Stand, Yamuna Nagar,



GULATI HOSPITAL

169, Sarojini Colony, Near Bus Stand,
YAMUNA NAGAR - 135 001

Dr. J.K. Gulati

M.D., D.N.B. (AIIMS, New Delhi)
Consultant Physician & Heart Specialist

Dr. Sarita Gulati

D.G.O., DCH (Gynaecologist)
Ex. SMO, Civil Hospital, YNR.

ULTRASONOGRAPHY (WHOLE ABDOMEN)

NAME MR KAPIL KUMAR AGE & SEX 28 M 9.05.22

LIVER - Liver size is normal and it shows normal echopattern with normal vasculature and normal intrahepatic biliary radical pattern. No mass lesion seen.

GALL BLADDER - It shows normal echopattern with normal smooth wall. No evidence of hyperechoic shadow or acoustic shadow is seen in the region.

CBD measures within normal limits.

PANCREAS - Part of head visualized - shows normal echo pattern. Rest obscured.

KIDNEYS - Both kidneys measure within normal limits with normal echogenic Pattern and well maintained corticomedullary distinction. No evidence of hydronephrotic change is seen. No calculus seen.

SPLEEN - No abnormal echoes detected from the splenic area.

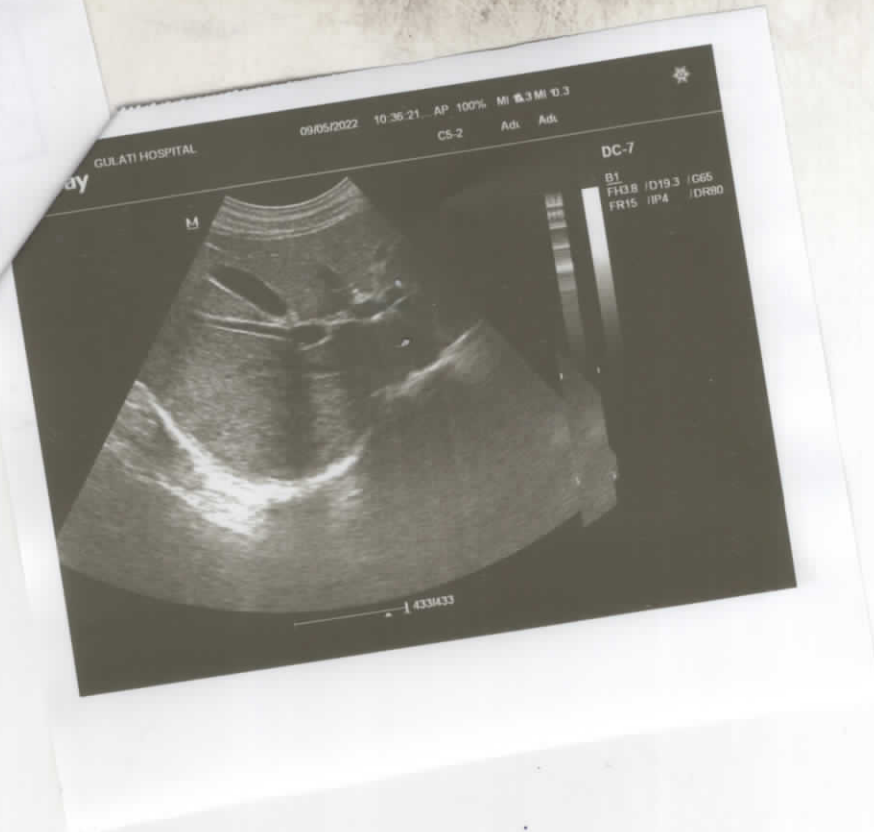
URINARY BLADDER - Bladder is well distended and has normal smooth wall. No mass lesion is seen

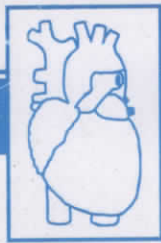
PROSTATE - No abnormal echoes could be seen from it.

No free fluid seen in the peritoneal cavity.

CONCLUSION :- NO ABNORMALITY IN THE PRESENT STUDY.

Amul
DR. J.K. GULATI
MD, DNB
GULATI HOSPITAL
Near Bus Stand, Yamuna Nagar





GULATI HOSPITAL

169, Sarojini Colony, Near Bus Stand,
YAMUNA NAGAR - 135 001

Dr. J.K. Gulati

ECHOCARDIOGRAPHY

M.D., D.N.B. (AIIMS, New Delhi)

Consultant Physician & Heart Specialist

Dr. Sarita Gulati

D.G.O., DCH (Gynaecologist)

Ex. SMO, Civil Hospital, YNR.

NAME MR KAPIL KUMAR

AGE & SEX 28 M

DATED 9.05.22

M-MODE PARAMETERS

		Normal Values
Left Ventricular ED Dimension	5.2 cm	(3.7-5.6cm)
Left Ventricular ES Dimension	3.6 cm	(2.2-4.0cm)
Right Ventricular ED Dimension	2.0 cm	(0.7-2.6cm)
Inter Ven. Septum thickness (D)	1.0 cm	(0.6-1.1cm)
LV Posterior Wall thickness (D)	0.9 cm	(0.6-1.1cm)
Aortic root diameter	2.5 cm	(2.0-3.7cm)
Left Atrial Diameter	3.0 cm	(1.9-4.0cm)

INDICES OF LV SYSTOLIC FUNCTIONS (NORMAL VALUES)

Ejection Fraction	60 %	(54-76%)
Fractional Shortening	35 %	(25-46%)

MITRAL VALVE

Thin, and it moves posteriorly during diastole. No subvalvular pathology, no anterior leaflet pathology, no prolapsed or flutter or systolic anterior motion

TRICUSPID VALVE

Valve is normal looking, no prolapse is seen

AORTIC VALVE

All three cusps seen, opens fully during systole with central closure

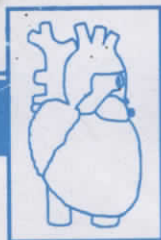
PULMONARY VALVE

Thin opens well, Pulmonary Artery not dilated

LEFT VENTRICLE

No hypertrophy, Chamber slightly dilated No segmental wall

motion abnormality



GULATI HOSPITAL

169, Sarojini Colony, Near Bus Stand,
YAMUNA NAGAR - 135 001

PULSE & CONTINUOUS WAVE DOPPLER

Dr. J.K. Gulati

M.D., D.N.B. (AIIMS, New Delhi)
Consultant Physician & Heart Specialist

NO mitral regurgitation.

No aortic regurgitation.

NO Tricuspid regurgitation .

No pulmonary regurgitation.

Predicted PA pressure (S)=25MM of Hg

Dr. Sarita Gulati

D.G.O., DCH (Gynaecologist)
Ex. SMO, Civil Hospital, YNR.

COLOUR FLOW IMAGING

No Mitral regurgitation.

No aortic regurgitation.

No tricuspid regurgitation.

No pulmonary regurgitation.

COMMENTS

No LA, LAA, LV CLOT seen.

No vegetation on any valve

No intra cardiac mass.

Pericardial effusion.

IAS, IVS intact.

IMPRESION:- Echocardiography Findings are suggestive of

Normal Systolic and diastolic Functions

No Evidence of Hypertrophy

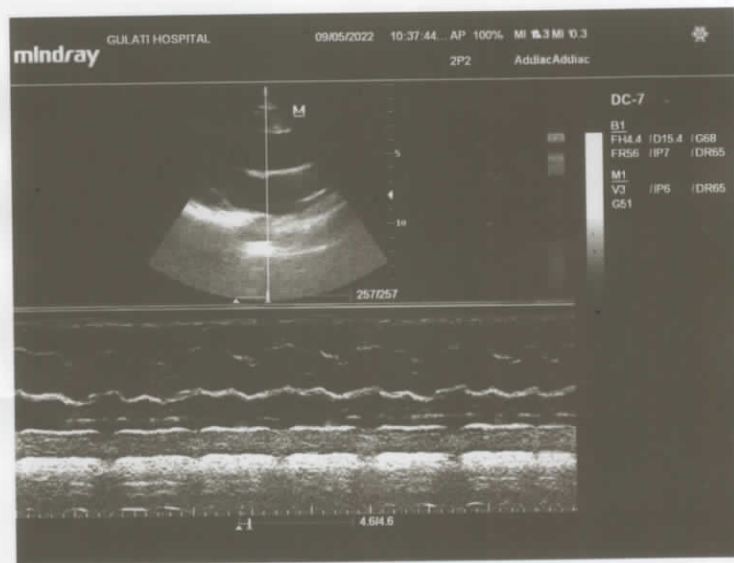
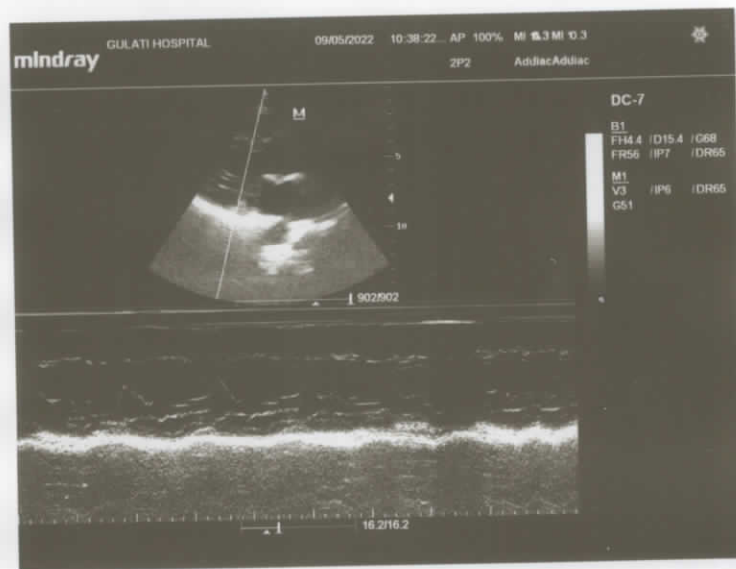
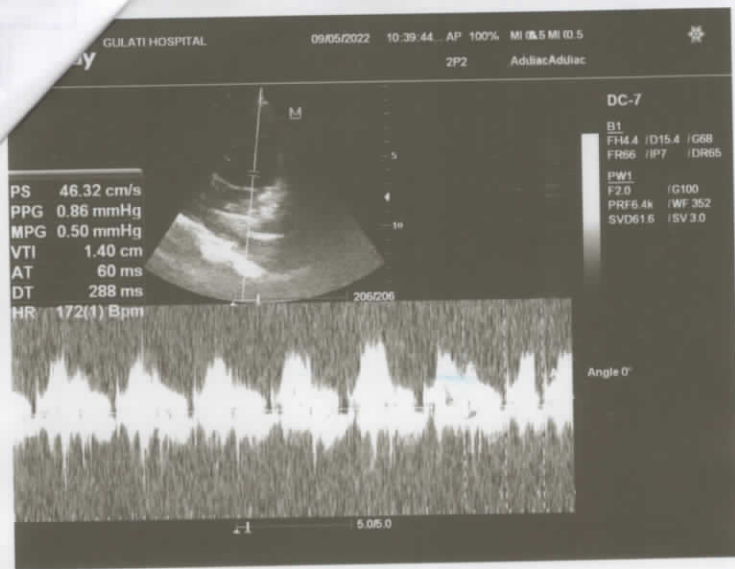
Dr J K Gulati MD, DNB (Medicine)

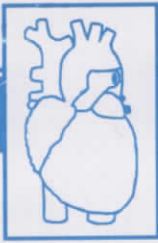
J.K. GULATI

MD, DNB

GULATI HOSPITAL

Near Bus Stand, Yamuna Nagar





GULATI HOSPITAL

169, Sarojini Colony, Near Bus Stand,
YAMUNA NAGAR - 135 001

Dr. J.K. Gulati

M.D., D.N.B. (AIIMS, New Delhi)
Consultant Physician & Heart Specialist

Dr. Sarita Gulati

D.G.O., DCH (Gynaecologist)
Ex. SMO, Civil Hospital, YNR.

MR.KAPIL KUMAR

AGE 27 /MALE

DATE 09.05.2022

TEST NAME

RESULTS

UNITS

BIO.REF.INTERVAL

THYROID PROFILE,TOTAL,SERUM

(CLIA)

T3.TOTAL

0.96

ng/mL

0.60-1.81

T4.TOTAL

6.24

ug/dL

5.01-12.45

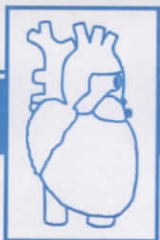
TSH

2.36

uIU/mL

0.35-5.50

DR. J.K. GULATI
MD, DNB
GULATI HOSPITAL
Near Bus Stand, Yamuna Nagar



GULATI HOSPITAL

169, Sarojini Colony, Near Bus Stand,
YAMUNA NAGAR - 135 001

Dr. J.K. Gulati

M.D., D.N.B. (AIIMS, New Delhi)
Consultant Physician & Heart Specialist

Dr. Sarita Gulati

D.G.O., DCH (Gynaecologist)
Ex. SMO, Civil Hospital, YNR.

NAME. MR.KAPIL KUMAR

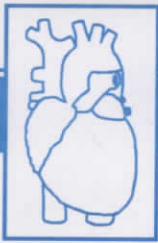
DATE :-09.5.2022

COMPLETE HAEMOGRAM

Normal Values

Hb	13.5gm%	12 – 17 gm%
RBC COUNT	5.2m/cu mm	4 – 5.5 m / cu mm
WBC COUNT	6,200cu/ mm	4000-11000 /cu mm
PLATELET COUNT	2.20ac/ cu mm	1.5 –4 lac/ cu mm
DLC		
Polymorph	65	40-70%
Lymphocytes	30	20-45%
Monocytes	02	2-19%
Eosinophils	03	1-6 %
MCH	32g	28-35pg/cell
MCV	92fl	86-98 fl
MCHC	33%	32- 36 gm%
HAEMATOCRIT	48%	42- 52 %
ESR	05mm/hr	0.0-10mm/hr

J.K. GULATI
MD, DNB
GULATI HOSPITAL
Near Bus Stand, Yamuna Nagar



GULATI HOSPITAL

169, Sarojini Colony, Near Bus Stand,
YAMUNA NAGAR - 135 001

Dr. J.K. Gulati

M.D., D.N.B. (AIIMS, New Delhi)
Consultant Physician & Heart Specialist

Dr. Sarita Gulati

D.G.O., DCH (Gynaecologist)
Ex. SMO, Civil Hospital, YNR.

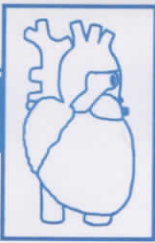
NAME MR. KAPIL KUMAR

DATE 09.05.2022

BLOOD PROFILE

TEST	RESULT	NORMAL VALUE
S.CREATININE	0.9 mg%	0.5-1.5mg%
B U N	15mg%	10 -205mg%
S.URIC ACID	5.3mg%	3.0-7.0mg%
Proteins Total	7.2gm%	6 -8 gm%
Albumin	3.9gm%	3.8 - 5.0 gm%
Globulin	3.3 gm%	2.3 - 5.3 gm%
A:G Ratio	1:1	
S. ALKALINE PHOSPHATASE	100U/L	30 -120 U/L
Blood Group	B'Positive	
SGOT	30 IU/L	5 - 40 IU/L
SGPT	20 IU/L	5 - 35 IU/L
GGTP	38 U/L	M 11-49U/L F 7-32 U/L
S. BILIRUBIN	0.8 mg%	0.2- 1.0mg%
DIRECT	0.2 mg%	0.0 -0.2 mg%
INDIRECT	0.6 mg%	0.1 - 1.0 mg%
B. Sugar F	92 mg%	70 -110 mg%
HbA1c	4.6%	< 6%
TOTAL CHOLESTROL	178mg%	(130- 200)
LDL	120 mg%	<130 mg%
H D L	38mg%	(30 - 55)
V L D L	20mg%	(5- 35)
TRIGLYCERIDES	100mg%	(65- 170)
CHOLESTROL / HDL RATIO	4.6	
PSA	2ng/ ml	< 4 ng/ml


DR. J.K. GULATI
MD, DNB
GULATI HOSPITAL
Near Bus Stand, Yamuna Nagar



HOS. 260633
RES. 261633

GULATI HOSPITAL

169, Sarojini Colony, Near Bus Stand,
YAMUNA NAGAR - 135 001

Dr. J.K. Gulati

M.D., D.N.B. (AIIMS, New Delhi)
Consultant Physician & Heart Specialist

Dr. Sarita Gulati

D.G.O., DCH (Gynaecologist)
Ex. SMO, Civil Hospital, YNR.

Patient's Name Mr. Kapil Kumar

Age/Sex: M

Advised By Dr. J.K. Gulati MD.

Date: 09-05-2022

INVESTIGATION	REPORT	NORMAL
---------------	--------	--------

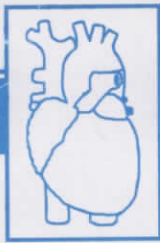
URINE EXAMINATION

Reaction	Acidic	Acidic
Albumin	Nil	Nil
Sugar	Nil	Nil
Specific gravity	1015	1008-1025

MICROSCOPI EXAM

Pus cell	Nil	/HPF
RBCs	Nil	/HPF
Epithelial Cell	Nil	/HPF
Crystals	Nil	/HPF
Casts	Nil	/HPF
Any other findings	Nil	/HPF


DR. J.K. GULATI
MD, DNB
GULATI HOSPITAL
Near Bus Stand, Yamuna Nagar



GULATI HOSPITAL

169, Sarojini Colony, Near Bus Stand,
YAMUNA NAGAR - 135 001

Dr. J.K. Gulati

M.D., D.N.B. (AIIMS, New Delhi)
Consultant Physician & Heart Specialist

Dr. Sarita Gulati

D.G.O., DCH (Gynaecologist)
Ex. SMO, Civil Hospital, YNR.

X - RAY Chest PA

Date:-09/05/2022

Name:-Mr.Kapil Kumar

Age/Sex:- 27 Y/M

Skin and soft tissue normal

Bony and skeleton normal

Trachea is central

Mediastinum is normal

Heart size and shape Normal

DR. J.K. GULATI
MD, DNB
GULATI HOSPITAL
Near Bus Stand, Yamuna Nagar

KAPIL KUMAR

ID :
Name : Kapil Kumar

Age : Years

Gender :

BP : (mmHg)

Weight : Kgs

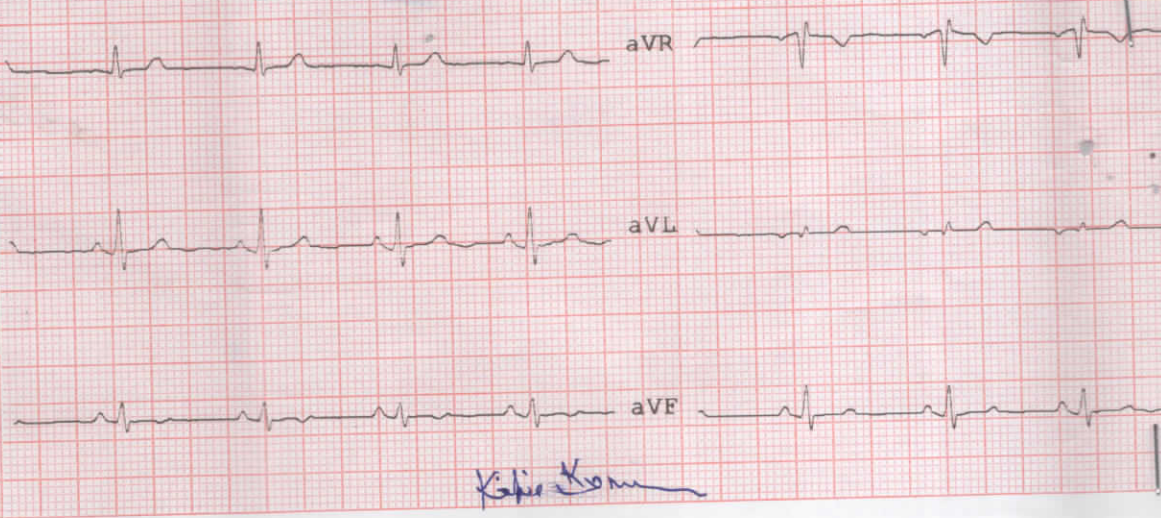
Date : 09/05/22

Note :

VESTA 301i
(Ver 3.15.31PC)
www.rmsindia.com

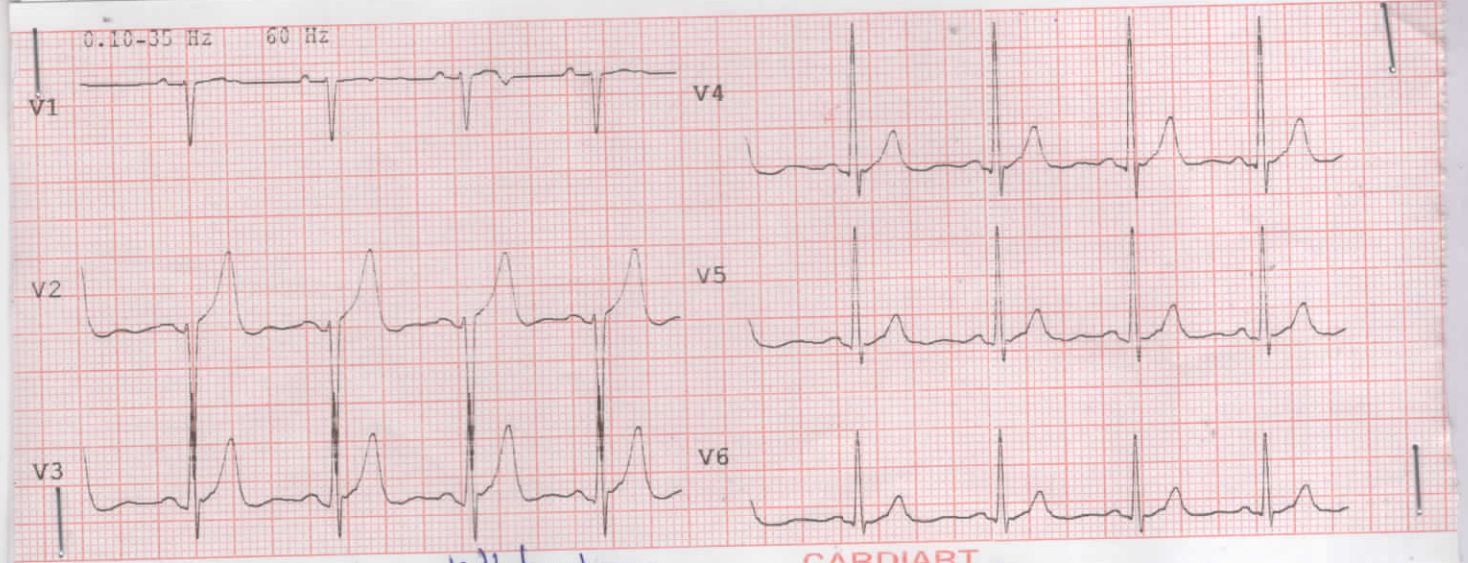
10 mm/mV 25 mm/s

BPL



Kapil Kumar

CARDIART

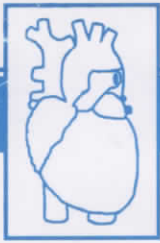


Kapil Kumar

CARDIART

ECG REPORT:-Within Normal Limits

Jay
Signature
DR. J.K. GULATI
MD, DNB
GULATI HOSPITAL
Near Bus Stand, Yamuna Nagar



GULATI HOSPITAL

169, Sarojini Colony, Near Bus Stand,
YAMUNA NAGAR - 135 001

Dr. J.K. Gulati

M.D., D.N.B. (AIIMS, New Delhi)
Consultant Physician & Heart Specialist

Dr. Sarita Gulati

D.G.O., DCH (Gynaecologist)
Ex. SMO, Civil Hospital, YNR.

Kapil kumar

9.05.22

Age-28/M

Certified that I have examined Mr
Kapil Kumar today & he has been found
to be medically fit.

Pulse - 78/mt regular

BP - 120/80

Chest - b/l vesicular breathing

CVS - S₁ & S₂ - normal

Abd - no abnormality

X Ray chest PA - no abnormality.

Dr. J.K. Gulati
9/5/22

DR. J.K. GULATI
MD, DNB

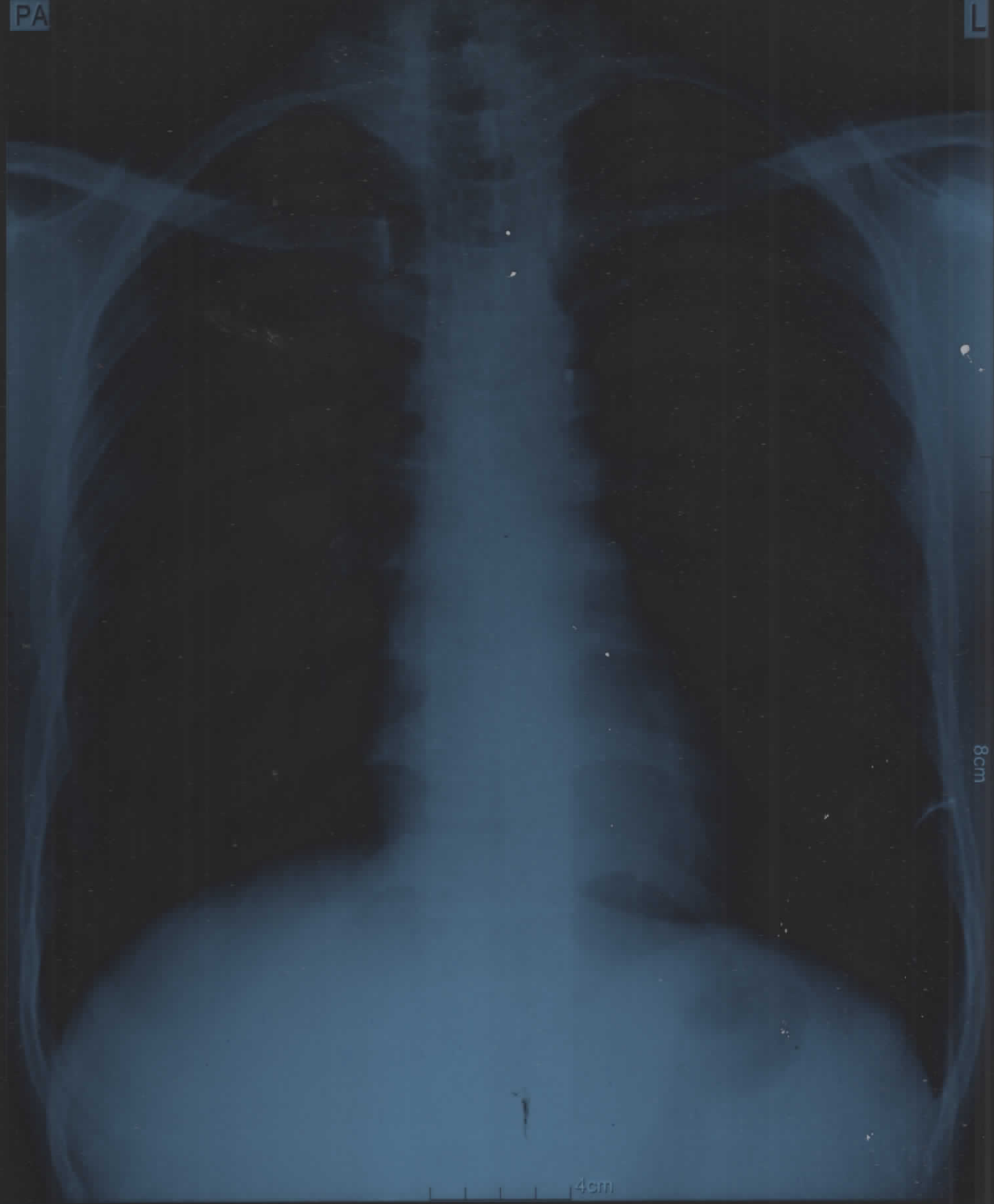
GULATI HOSPITAL
Near Bus Stand, Yamuna Nagar

Mr. Kapil Kumar 28Y M

09-05-2022

PA

L



8cm

4cm

Gulati Hospital Near Bus Stand Yamuna Nagar