

Patient's name	: ASHISH CHAUHAN	Age/Sex	: 29 Years/Male
Referred by	: Self	Reg. No	: 3593
Date	: 14/08/2021	Mobile	: 8968658818
Patient's Id	: AZ320	Ref ID.	:

Fitness Certificate

GENERAL EXAMINATION

Height (cms) : 171

Weight (kgs) : 96.7

Blood Pressure : 120/80 mmHg

Pulse : 62/Min

No Clubbing/Cynosis/Pallor/Pedel Oedem

Systemic Examination:

Cardio vascular System - S1,S2 Normal, No Murmur

Respiratory system - AEBE


Central Nervous System - No FND

Abdomen - Soft, Non Tender, No Organomegaly


----- End of Report -----

This is an electronically authenticated report.
Note:(LL-Very Low, L-Low, HH-Very High)

Approved On : 16/08/2021 11:57:00
Generated On : 16/08/2021 12:26






Dr Jinen M Shah
DNB (Medicine)FCCS (USA)


बैंक ऑफ बरोडा
Bank of Baroda

नाम Name Ashish

कर्मचारी कूट क्र. 184285
Employee Code No.



जारीकर्ता प्राधिकारी
Issuing Authority


आशिश
धारक के हस्ताक्षर
Signature of Holder

29/m

8968658818

Dr. Jidān M. Shāh
DNB (Medicine) FCCS (USA)
Reg. No.: G-20693



Patient's name : ASHISH CHAUHAN	Age/Sex : 29 Years/Male
Referred by : Self	Reg. No : 3593
Date : 14/08/2021	Mobile : 8968658818
Patient's Id : AZ320	Ref ID. :

HEMOGRAM REPORT

Performed on 5-Part Fully Auto Hematology Analyzer SIEMENS ADVIA 2120i)

Test	Result	Unit	Biological Reference Interval
Sample Type:	EDTA		
Haemoglobin:	15.9	gm/dL	13.5 - 18.0
Total WBC Count:	6000	/microlitre	4000 - 10500
Platelets Count:	236000	/microlitre	1,50,000 - 4,50,000
Differential Count:			
Neutrophils:	47	%	40-80
Lymphocytes:	48	%	20-40
Eosinophils:	02	%	Upto 6
Monocytes:	03	%	2-10
Basophils:	00	%	<1-2
RBC indices:			
RBC Count:	5.74	*10 ⁶ /microL	4.5 - 5.5
HCT:	49.2	%	40 - 50
MCV:	85.7	fL	83-101
MCH:	27.7	pg	27-32
MCHC:	32.3	%	31.5-34.5
RDW:	12.7	%	11.6 - 14.0
Erythrocytes Sedimentation Rate(ESR): (By AUTO ESR-10, USA)			
ESR 1st Hr:	05	mm	2 - 15 mm in 1Hr.
ESR 2nd Hr:	12	mm	12 - 20 mm in 2 Hr.
Thick Smear Preparation:			
Haemoparasite:	Malarial parasites are not seen.		
Peripheral Smear Examination:			
RBCs:	Normocytic & Normochromic.		
Platelet:	Platelet adequate & normal on smear.		

This is an electronically authenticated report.
Note:((LL-Very Low, L-Low, HH-Very High)




End of Report

Dr. KEYUR Patel
M.B.DCP

Patient's name	: ASHISH CHAUHAN	Age/Sex	: 29 Years/Male
Referred by	: Self	Reg. No	: 3593
Date	: 14/08/2021	Mobile	: 8968658818
Patient's Id	: AZ320	Ref ID.	:

Approved On : 15/08/2021 12:38:00
Generated On : 16/08/2021 12:46



Patient's name : ASHISH CHAUHAN Age/Sex : 29 Years/Male
Referred by : Self Reg. No : 3593
Date : 14/08/2021 Mobile : 8968658818
Patient's Id : AZ320 Ref ID. :

GLYCOSYLATED HAEMOGLOBIN (HbA1C) ESTIMATION

Test	Result	Unit	Biological Reference Interval
Sample Type: EDTA			
Glycosylated Haemoglobin (HbA1C)	4.90	%	Pre-Diabetic (Adult): 5.7 - 6.4 Diabetic (Adult): >6.5 Therapeutic goal for glycemic control: <7.0
Mean Blood Glucose Level (An average of 2 -3 Months)	94		

Method : HPLC on D-10, Bio-Rad,USA

INTERPRETATION:

- * Blood sample can be drawn at any time. Fasting is not required.
- * Reflects average blood sugar levels for the 2 to 3 months period before the test.
- * Provides information for evaluating diabetic treatment modalities and tracks control of blood glucose of particular value in diabetic children, diabetics in whom the renal threshold for glucose is abnormal, unstable insulin dependent diabetics where blood sugars vary markedly from day to day.
- * High value in poorly controlled DM and moves towards normal in patients with optimal control.

----- End of Report -----



Dr. KEYUR Patel
M.B.DCP

This is an electronically authenticated report.
Note:((LL-Very Low, L-Low, HH-Very High)

Approved On : 15/08/2021 12:37:00
Generated On : 16/08/2021 12:46




Patient's name : ASHISH CHAUHAN	Age/Sex : 29 Years/Male
Referred by : Self	Reg. No : 3593
Date : 14/08/2021	Mobile : 8968658818
Patient's Id : AZ320	Ref ID. :

LIPID PROFILE

(Performed on Semi Auto Chemistry Analyzer BeneSphera)

Test	Result	Unit	Biological Reference Interval
Sample Type: Fasting Serum			
S.Cholesterol (Oxidase Peroxidase)	170	mg/dL	< 200 Desirable 200-239 Boderline High > 240 High
S.HDLC (Direct) (Phosphotungsstic Acid)	43.5	mg/dL	< 40 Low > 60 High
S.Triglyceride (GPO-POD)	117.4	mg/dL	< 150 mg/dl Normal 150-199 Boderline High 200-499 High > 500 Very High
S.VLDL (Calculated)	23.48	mg/dL	10-40 Normal
S.LDLC (Calculated)	103.02	mg/dL	< 100 Optimal 100-129 Near to above optimal 130-159 Boderline high 160-189 High >190 Very High
S.Cholesterol / HDLC Ratio (Calculated)	3.91		< 4 Normal 4-6 Boderline 6-8 Risklevel > 8 High Risk
S.LDLC / HDLC Ratio (Calculated)	2.37		< 3 Normal 3-4 Boderline 4-6 Risk Level > 6 High Risk
Cholesterol / HDLC Ratio (Calculated)	3.91		< 3.5 Normal
Triglyceride / HDLC Ratio (Calculated)	2.7		< 2 Normal > 4 Risk Level > 6 High Risk
Non HDLC (Calculated)	126.5		< 130 Normal 130 - 159 Near Normal 160 - 189 Boderline 190 - 219 Risklevel > 220 High Risk

This is an electronically authenticated report.
Note:((LL-Very Low, L-Low, HH-Very High)



End of Report

Dr. KEYUR Patel
M.B.DCP

Approved On : 15/08/2021 12:36:00
Generated On : 16/08/2021 12:46

Patient's name : ASHISH CHAUHAN	Age/Sex : 29 Years/Male
Referred by : Self	Reg. No : 3593
Date : 14/08/2021	Mobile : 8968658818
Patient's Id : AZ320	Ref ID. :

LIVER FUNCTION TEST

(Performed on Fully Auto DRY Chemistry Analyzer VITROS-250)


Test	Result	Unit	Biological Reference Interval
Sample Type: Serum			
S.Bilirubin			
Total Bilirubin	1.11	mg/dl	0 - 1.2
(Azobilirubin)			
Conjugated Bilirubin	0.28	mg/dl	0 - 0.4
(Dual Wavelength spectrophotometric)			
Unconjugated Bilirubin	0.83	mg/dl	0.0 - 1.1
(Dual Wavelength spectrophotometric)			
S.G.P.T. (ALT)	51.3	IU/L	0 - 49
(Kinetic with Pyridoxal 5-Phosphate)			
S.G.O.T. (AST)	31.7	IU/L	Up to 46
(Kinetic with Pyridoxal 5-Phosphate)			
S.ALP (Alkaline Phosphatase)	211.1	U/L	80 - 306
(4-Nitrophenyl phosphate)			
S.Protein			
Total Protein	6.3	gm/dl	6.3 - 8.2
(Biuret)			
Albumin	5.15	gm/dl	3.5 - 5.2
(BCG)			
Globulin	1.15	gm/dl	1.9 - 3.5
(Calculated)			
Albumin Globulin Ratio	4.48		
S.GammaGT	66.6	IU/L	15-73
(L-Gamma Glutamyl-4-Nitroanalide)			

----- End of Report -----


Dr. KEYUR Patel
M.B.DCP

This is an electronically authenticated report.
Note:((LL-Very Low, L-Low, HH-Very High)

Approved On : 15/08/2021 12:36:00
Generated On : 16/08/2021 12:46



Patient's name : ASHISH CHAUHAN
Referred by : Self
Date : 14/08/2021
Patient's Id : AZ320
Age/Sex : 29 Years/Male
Reg. No : 3593
Mobile : 8968658818
Ref ID. :

BLOOD GROUP

Sample Type: EDTA
ABO Group : "AB"
Rh Type : Positive

RENAL FUNCTION TEST

(Performed on Fully Auto DRY Chemistry Analyzer VITROS-250)


Test	Result	Unit	Biological Reference Interval
Sample Type: Serum			
S.Urea (Urease with indicator dye)	21.2	mg/dl	Male: 19.6-43.6 Female: 15.2-37.0
S.Creatinine (Enzymatic)	1.05	mg/dL	0.55 - 1.30
S.Uric Acid (Uricase)	6.68	mg/dL	Male: 3.5-8.5 Female: 2.5-6.2

----- End of Report -----


Dr. KEYUR Patel
M.B.DCP

This is an electronically authenticated report.
Note:((LL-Very Low, L-Low, HH-Very High)

Approved On : 15/08/2021 12:37:00
Generated On : 16/08/2021 12:47



Patient's name : ASHISH CHAUHAN Age/Sex : 29 Years/Male
Referred by : Self Reg. No : 3593
Date : 14/08/2021 Mobile : 8968658818
Patient's Id : AZ320 Ref ID. :

BLOOD GLUCOSE LEVEL

Test	Result	Unit	Biological Reference Interval
Sample Type:	Flouride		
Fasting Blood Glucose (Hexokinase) Collection Time:	79.3	mg/dl	70-110
Collection Time:			
Post Prandial Blood Glucose (2 Hrs) (Hexokinase)	114.9	mg/dl	80-140

Tests Performed on Fully Auto DRY Chemistry Analyzer VITROS-250

SERUM LDH LEVEL

Test	Result	Unit	Biological Reference Interval
Sample Type:	Serum		
LDH Activity(Lactate Dehydrogenase): Pyruvate to lactate Kinetic Method	126.86	U/L	120 - 246


#Tests Performed on Fully Auto DRY Chemistry Analyzer VITROS-250

----- End of Report -----

Dr. KEYUR Patel
M.B.DCP

This is an electronically authenticated report.
Note: (LL-Very Low, L-Low, HH-Very High)

Approved On : 15/08/2021 12:37:00
Generated On : 16/08/2021 12:47



Patient's name : ASHISH CHAUHAN	Age/Sex : 29 Years/Male
Referred by : Self	Reg. No : 3593
Date : 14/08/2021	Mobile : 8968658818
Patient's Id : AZ320	Ref ID. :

Prostate Specific Antigen
(Carried out on miniVIDAS, Biomerieux)

Test	Result	Unit	Reference Interval
S.PSA : (Prostate Specific Antigen)	0.880	ng/ml	M : Healthy Male upto 4.00

THYROID FUNCTION TEST
(by CLIA on SIEMENS ADVIA Centaur XP)


Test	Result	Unit	Biological Reference Interval
Sample Type: Serum			
S.T3 (Total Triiodothyronine by CLIA)	1.13	ng/mL	1 - 23 Months: 1.17 - 2.39 2 - 12 Years: 1.05 - 2.07 13 - 20 Years: 0.86 - 1.92 Adult: 0.6 - 1.81
S.T4 (Total Thyroxine by CLIA)	9.60	mcg/dL	3.2 - 12.6
S.TSH (Thyroid Stimulating Hormone by CLIA)	2.012	microU/mL	0 - 12 Yrs: 0.77 - 5.64 12 - 19 Yrs: 0.75 - 3.69 19 - 100 Yrs: 0.35 - 5.50

----- End of Report -----


Dr. KEYUR Patel
M.B.DCP

This is an electronically authenticated report.
Note: (LL-Very Low, L-Low, HH-Very High)

Approved On : 15/08/2021 12:37:00
Generated On : 16/08/2021 12:47



Patient's name : ASHISH CHAUHAN	Age/Sex : 29 Years/Male
Referred by : Self	Reg. No : 3593
Date : 14/08/2021	Mobile : 8968658818
Patient's Id : AZ320	Ref ID. :

URINE ROUTINE ANALYSIS

Sample Type: Fresh Urine

Physical Examination

(Naked Eye Observation)

	Result	Biological Ref. Value
Amount	25 ml	>10 ml
Colour	Pale Yellow	Pale Yellow
Appearance	Clear	Clear

Chemical Examination

pH (Dip stick)	7	4.5-8.0
Specific Gravity (Bromothymol Blue)	1.015	1.002-1.030
Albumin (Tetrabromophenol)	Absent	Absent
Glucose (Specific Glucose Oxidase/Peroxidase)	Absent	Absent
Bilirubin (Azo-coupling reaction)	Absent	Absent
Acetone (Sodium Nitroprusside Reaction)	Absent	Absent
Urobilinogen (Modified Ehrlich Reaction)	Absent	Absent
Nitrites (Diazotization Reaction)	Absent	Absent

Microscopic Examination

(After centrifugation at 1500 RPM for 10min./hpf)


Pus Cells(WBCs)	Absent	Absent
Red Blood Cells(RBCs)	Absent	Absent
Epithelial cells	Absent	
T.Vaginals	Absent	Absent
Spermatozoa	Absent	Absent
Casts	Absent	Absent
Crystals	Absent	Absent
Amorphous Material	Absent	Absent

----- End of Report -----


Dr. KEYUR Patel
M.B.DCP

This is an electronically authenticated report.
Note:(LL-Very Low, L-Low, HH-Very High)

Approved On : 15/08/2021 12:37:00
Generated On : 16/08/2021 12:47



Patient's name	: ASHISH CHAUHAN	Age/Sex	: 29 Years/Male
Referred by	: Self	Reg. No	: 3593
Date	: 14/08/2021	Mobile	: 8968658818
Patient's Id	: AZ320	Ref ID.	:

Electrocardiogram

Findings

Normal Sinus Rhythm.

Within Normal Limit.

----- End of Report -----

This is an electronically authenticated report.
Note:((LL-Very Low, L-Low, HH-Very High)


Dr Jinen M Shah
DNB (Medicine)FCCS (USA)

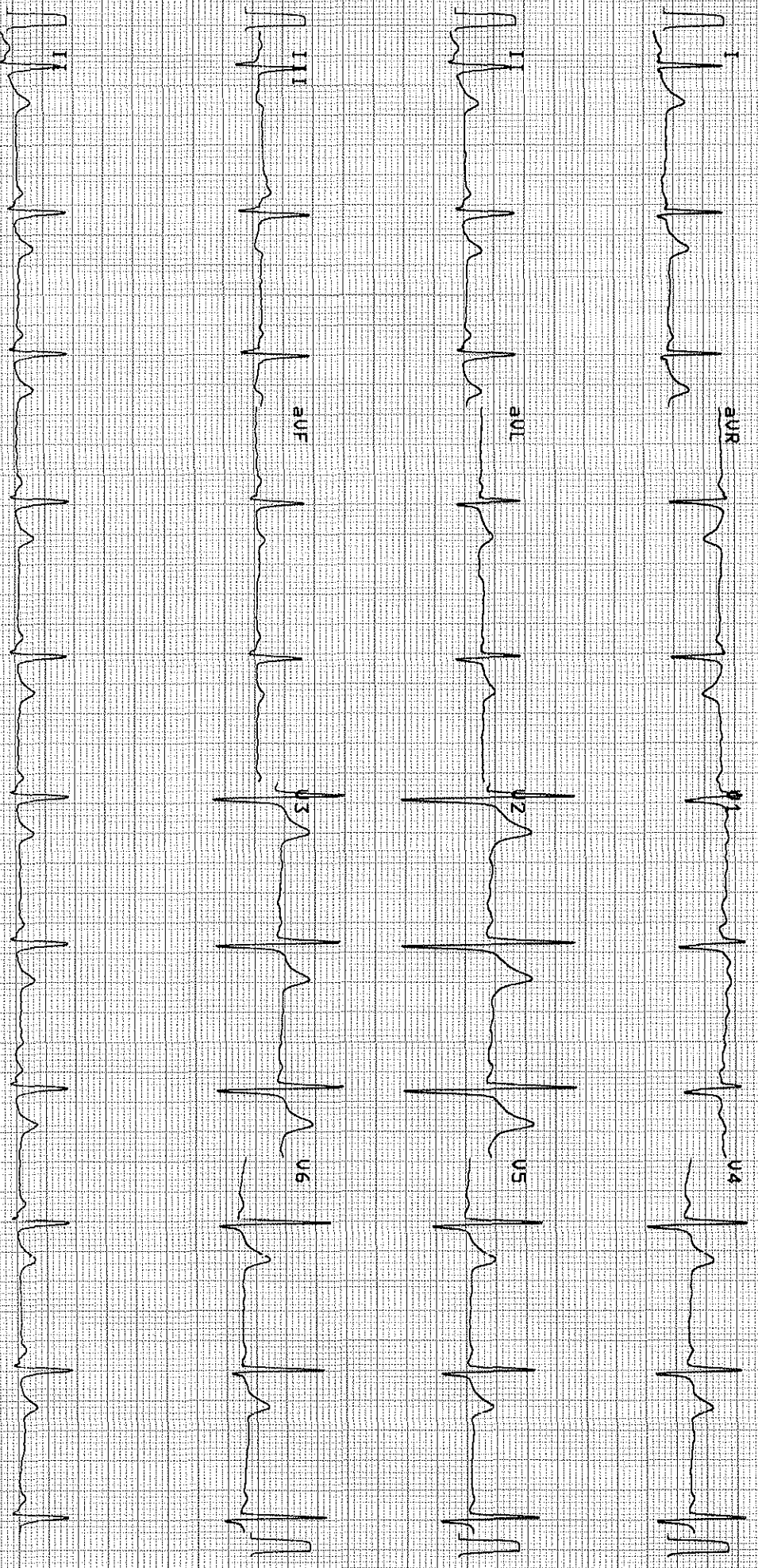
Approved On : 16/08/2021 11:58:00 AM
Generated On : 16/08/2021 12:16



Rshish
Chauhan
29
29 years / 171 cm / 97 kg
Male

HR 62/min
Axis: P - °
QRS 38 °
T 22 °
Intervals:
RR 964 ms
P - ms
PR - ms
QR5 92 ms
QT 362 ms
QTc 369 ms
(Bazett)
10 mm/mV

P (II) - mV
S (V1) -0.76 mV
R (V5) 1.37 mV
Sokol. 3.53 mV



10 mm/mV

10 mm/mV

25 mm/s
2.05-25.02
55C
55C
SBS
14.08.2024
12:21:27
CURQVIS HEALTHCARE
01-10-2023 05:12:40

Handwritten signature

Patient's name	: ASHISH CHAUHAN	Age/Sex	: 29 Years/Male
Referred by	: Self	Reg. No	: 3593
Date	: 14/08/2021	Mobile	: 8968658818
Patient's Id	: AZ320	Ref ID.	:

2D Echo Colour Doppler

OBSERVATION:

2 D Echo and color flow studies were done in long and short axis, apical and Sub coastal views.

1. Normal LV size. No RWMA at rest.
2. Normal RV and RA. Mild Concentric LVH.
3. All Four valves are structurally normal.
4. Good LV systolic function. LVEF = 60%.
5. Normal LV Compliance.
6. Trivial TR. Mild MR. No AR.
7. Mild PAH. RVSP = 38 mmHG.
8. Intact IAS and IVS.
9. No Clot, No Vegetation.
10. No pericardial effusion.

CONCLUSION


1. Normal LV size with Good LV systolic function.
2. Mild Concentric LVH . Normal LV Compliance
3. Trivial TR with Mild PAH. Mild MR. No AR
4. No RWMA at rest.


This echo doesn't rule out any kind of congenital cardiac anomalies.

This is an electronically authenticated report.
Note: (LL-Very Low, L-Low, HH-Very High)

Approved On : 16/08/2021 11:58:00
Generated On : 16/08/2021 12:26

----- End of Report -----




Dr Jinen M Shah
DNB (Medicine) FCCS (USA)

Patient's name	: ASHISH CHAUHAN	Age/Sex	: 29 Years/Male
Referred by	: Self	Reg. No	: 3593
Date	: 14/08/2021	Mobile	: 8968658818
Patient's Id	: AZ320	Ref ID.	:

X RAY CHEST PA

Both lung fields appear clear.

No evidence of any active infiltrations or consolidation.

Cardiac size appears within normal limits.

Both costo-phrenic angles appear free of fluid.

Both domes of diaphragm appear normal.

Bony thorax appears normal.


COMMENT: No significant abnormality is detected.

----- End of Report -----

This is an electronically authenticated report.
Note:((LL-Very Low, L-Low, HH-Very High))


Dr. Jaimin Shah
DMRD
Consultant Radiologist

Approved On : 14/08/2021 3:32:00 PM
Generated On : 14/08/2021 15:32



Patient's name : ASHISH CHAUHAN	Age/Sex : 29 Years/Male
Referred by : Self	Reg. No : 3593
Date : 14/08/2021	Mobile : 8968658818
Patient's Id : AZ320	Ref ID. :

USG ABDOMEN

Liver appears normal in size & echogenicity. No evidence of focal solid or cystic lesion seen. No evidence of dilatation of intra-hepatic biliary or portal radicals. PV is normal in caliber.

Gall bladder is normally distended. No evidence of calculus or mass seen. Gall bladder wall thickness appears normal.

Pancreas Visualized portion appears normal in size and echopattern. No evidence of focal lesions.

Spleen appears normal in size & echopattern. No evidence of focal lesions.

Both kidneys are normal in size, shape and position. C.M. differentiation on both sides is maintained. No evidence of hydronephrosis, calculus or solid mass on either side.

Urinary bladder is partially distended. No evidence of calculus or mass.

Prostate appears normal in size and echopattern. No evidence of focal lesions.

No evidence of free fluid in peritoneal cavity.

No evidence of para-aortic lymph adenopathy.

No evidence of dilated small bowel loops.

COMMENTS :


NO SIGNIFICANT ABNORMALITY DETECTED.

----- End of Report -----

This is an electronically authenticated report.
Note:((LL-Very Low, L-Low, HH-Very High))


Dr. Jaimin Shah
DMRD
Consultant Radiologist

Approved On : 14/08/2021 3:33:00 PM
Generated On : 14/08/2021 15:33



Patient's name : ASHISH CHAUHAN Age/Sex : 29 Years/Male
Referred by : Self Reg. No : 3593
Date : 14/08/2021 Mobile : 8968658818
Patient's Id : AZ320 Ref ID. :

Eye Check - Up

RIGHT EYE

SP: -0.75
CY: -0.25
AX: 162

LEFT EYE

SP: -0.50
CY: -0.25
AX: 16

	Without Glasses	With Glasses
Right Eye	6/6	N.A
Left Eye	6/6	N.A

Near Vision: Right Eye -N/6, Left Eye - N/6


Fundus Examination: Within Normal Limits.

Colour Vision: Normal

Comments: Normal

Dr.Kejal Patel
MB,DO(Ophth)

Approved On : 16/08/2021 12:02:00 PM
Generated On : 16/08/2021 12:06

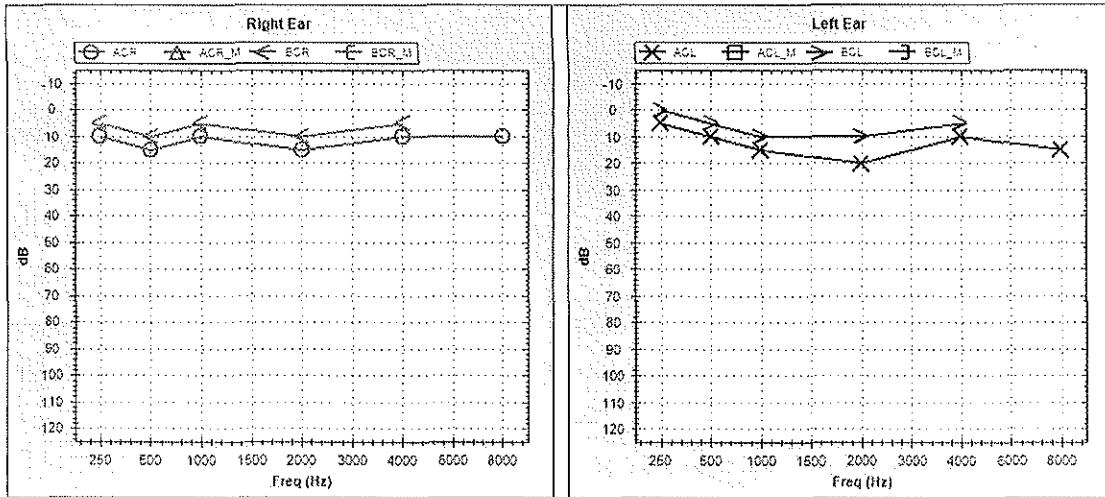


CLIENT NAME:- ASHISH CHAUHAN .

AGE:-29Y/ M

Date:-14/08/2021

AUDIOGRAM



EAR	MODE	Air Conduction		Bone Conduction		Colour Code	Threshold In dB	
		Masked	UnMasked	Masked	UnMasked		RIGHT	LEFT
LEFT		□	×	◻	>	Blue	AIR CONDUCTION	10
RIGHT		△	○	◻	<	Red	BONE CONDUCTION	
NO RESPONSE : Add ↓ below the respective symbols							SPEECH	

Comments:-

Bilateral Hearing Sensitivity Within Normal Limits.

