



HEALTH CHECKUP REPORT

DATE: 26/11/2022

Patient Name: NITU DEVI RAJPUT

Age/Gender: 40/F

Reg. No: 390564

Package: MEDIWHEEL

COMPLAINTS (IF ANY):

- Asymptomatic

HISTORY OF HEALTH STATUS:

- Occasionally hypertension rx

PRESENT MEDICATIONS: No

HYPERSENSITIVITY TO ANY DRUG: No

PERSONAL HISTORY:

- Bowel : Regular
- Micturition : Normal
- Sleep : Adequate
- Appetite : Adequate

Diet : Veg
Habits : No
Physical Activity/Exercise: Walking

HISTORY OF ILLNESS (WITH PAST MEDICATIONS): N

- Lmp:- 26/11/2022

FAMILY HISTORY:

- Brother :- ? brain stork

VITAL SIGNS:

- Pulse : 86/min.
- B.P: 118/80mmHg





PHYSICIAN CONSULTATION:

1) Clinical Impression

- Mild hyper uremia
- Dyslipidemia
- Small lt renal calculi
- Impaired fasting blood sugar

2) Recommendations

- Planty or oral lipid profile
- Diabetic diet
- Healthy life style

(Dr. Rashmi chovatia)

OPHTHALMO CONSULTATION:

Best corrected visual acuity

RE

6/6

LE

6/6

(Dr. Jignesh Shah)

DENTAL CONSULTATION:

Adv:

- Cleaning

(Dr. Parvin Chandarana)

GYNEC CONSULTATION: pending

(Dr. Devang patel)

Please take regular medicine as prescribed by the Doctor. (If given)



Patient ID 321881
Patient Name Mrs. NITUDEVI RAJPUT
Gender/Age Female/40
Doctor

Dt: 26/11/2022

Rx

	Drug Name	Generic Name		Morning	Afternoon	Evening	Night	Duration
Tab.	ROSUVAS	ROSUVASTATIN	(10 mg)	0	0	0	1	Continue
Tab.	FEBUTAS	FEBUXOSTAT.	(40 mg)	0	0	0	1	15 Day(s)

Dr. Rashmi Chovatia



Reg. No : CIMS/A/2022/390564
 Patient Name : Mrs. NITUDEVI RAJPUT
 Referring Doctor : Dr. CIMS DOCTOR
 Ward/Room :
 Visit No : HC/261122/16 [HCV]
 Age(Y-M-D)/Sex : 40 Y 2 M 26 D. / Female
 Doctor
 Bed

ORD/261122/382 Lab No : 2022174560 LSN : 93717B (Whole Blood) Sample Quality : Normal
 Collection Time : 26/11/2022 8:50:00 Arrival : 26/11/2022 9:16:02 Validation Time : 26/11/2022 11:58:50AM

	Result	Unit	Reference Range
CBC With ESR			
TOTAL COUNT			
Hemoglobin <i>(SLS Hemoglobin Detection method)</i>	12.4	g/dl	12.5 - 16.0 g/dl
Total RBC Count <i>(Hydro Dynamic Focusing Method)</i>	4.43	mill/Cmm	4.2 - 5.4 mill/Cmm
HCT <i>(Hydro Dynamic Focusing Method)</i>	38.3	%	37 - 47 %
Total WBC Count <i>(Flow Cytometry)</i>	5200	/Cmm	4000 - 10500 /Cmm
Platelet Count <i>(Hydro Dynamic Focusing Method)</i>	195000	/Cmm	150000 - 450000 /Cmm
DIFFERENTIAL COUNT (by Flow Cytometry)			
Polymorphs	51	%	40 - 70 %
Lymphocytes	39	%	22 - 45 %
Eosinophils	05	%	01 - 04 %
Monocytes	05	%	01 - 06 %
Basophils	00	%	00 - 01 %
Immature Granulocytes	00	%	0 - 2 %
Smear Study	RBCs shows Anisocytosis(+). Platelets are adequate in number. Malarial Parasites are not seen. No Premature cells are seen.		
BLOOD INDICES (by Calculated Method)			
M.C.V	86.5	fl	78 - 100 fl
M.C.H	28	pg	27 - 31 pg
M.C.H.C.	32.4	gm/dl	32 - 36 gm/dl
RDW-CV	15.3	%	11.5 - 14.0 %
ESR (Red Cell Aggregation)			
After One Hour	39	mm	0 - 12 mm
Blood Group Rh			
ABO	"O"		

Dr. Manisha Shah
 MB (Path & Bact)
 Consultant Pathologist
 Reg. No. : G-15496

Dr. Jitendra Nayak
 MD (Path)
 Consultant Pathologist
 Reg. No. : G-14786



CIMS Hospital Private Limited

Plot No 67/1, Opp. Panchamrut Bunglows, Near Shukan Mall, Off Science City Road, Sola, Ahmedabad - 380060, Gujarat

© 1800 309 9999 CIN No. U85110GJ2001PTC039962

Printed on: 26/11/2022 11:58:50AM



Reg. No : CIMS/A/2022/390564	Visit No : HC/261122/16 [HCV]
Patient Name : Mrs. NITUDEVI RAJPUT	Age(Y-M-D)/Sex : 40 Y 2 M 28 D. / Female
Referring Doctor : Dr. CIMS DOCTOR	Doctor
Ward/Room	Bed

ORD/261122/382 Lab No : 2022174560 LSN : 937178 (Whole Blood) Sample Quality : Normal
 Collection Time : 26/11/2022 8:50:00 Arrival : 26/11/2022 9:16:02 Validation Time : 26/11/2022 11:27:19AM

	<u>Result</u>	<u>Unit</u>	<u>Reference Range</u>
HbA1c (Glycosylated Haemoglobin)			
TEST			
HbA1c (Glyco Hb) <i>(Immuno Turbidimetric)</i>	5.88	%	4.8-5.9% Normal 5.9-7.0% Good diabetic control 7.0-10.0% Fair diabetic control >10.0% Poor diabetic control
Mean Plasma Glucose	131.9	mg/dL	80 - 140 mg/dL

Dr. Shreya Patel
MD(Path)
Consultant Pathologist

Dr. Manisha Shah
MD (Path & Bact)
Consultant Pathologist
Reg. No. : G-15496

Dr. Jitendra Nayak
MD (Path)
Consultant Pathologist
Reg. No. : G-14786





Reg. No : CIMS/A/2022/390564	Visit No : HC/261122/16 [HCV]
Patient Name : Mrs. NITUDEVI RAJPUT	Age(Y-M-D)/Sex : 40 Y 2 M 26 D. /Female
Referring Doctor : Dr. CIMS DOCTOR	Doctor
Ward/Room :	Bed
ORD/261122/382 Lab No : 2022174560	LSN : 937178 (Whole Blood) Sample Quality : Normal
Collection Time : 26/11/2022 8:50:00	Arrival : 26/11/2022 9:16:02 Validation Time : 26/11/2022 11:58:50AM

Rh

POSITIVE

*** END OF REPORT ***

20221126 09:16:02 937178 40 Y 2 M 26 D. /Female [HCV]

Jan

Dr. Manisha Shah
MD (Path & Bact)
Consultant Pathologist
Reg. No. : G-15496

Dr. Jitendra Nayak
MD (Path)
Consultant Pathologist
Reg. No. : G-14786





Reg. No : CIMS/A/2022/390564	VisitNo : HC/261122/16 [HCV]
Patient Name : Mrs. NITUDEVI RAJPUT	Age(Y-M-D)/Sex : 40 Y 2 M 28 D. / Female
Referring Doctor : Dr. CIMS DOCTOR	Doctor
Ward/Room	Bed


ORD/261122/382 Lab No : 2022174551 LSN : 937178 (SERUM) Sample Quality : Normal
 Collection Time : 26/11/2022 8:50:00 Arrival : 26/11/2022 9:16:02 Validation Time: 26/11/2022 11:25:47AM

Liver Function Test

	<u>Result</u>	<u>Unit</u>	<u>Reference Range</u>
Alkaline Phosphatase <i>(PNPP,AMP Buffer Method, Colorimetric)</i>	91.3	U/L	35 - 104 U/L
Billirubin			
Total Billirubin <i>(Diazospectral Iazonium Iron with Blank)</i>	0.94	mg/dL	0.0 - 1.0 mg/dL
Direct Billirubin <i>(Diazu,(Evelyn Malloy) with Blank)</i>	0.29	mg/dL	0.0 - 0.2 mg/dL
Indirect Billirubin <i>(Calculated from Total and Direct Billirubin)</i>	0.65	mg/dL	0.0 - 0.8 mg/dL
SGPT (ALT) <i>(IFCC without pyridoxal phosphate)</i>	12.1	U/L	0 - 33 U/L
SGOT (AST) <i>(IFCC without pyridoxal 5 phosphate)</i>	20.1	U/L	0 - 32 U/L
Total Protein			
Total Proteins <i>(Biuret Method)</i>	8.01	gm/dl	6.4 - 8.3 gm/dl
Albumin <i>(Bromocresol Green Colorimetric)</i>	4.83	gm/dl	3.97 - 4.95 gm/dl
Globulin	3.18	gm/dl	2.2 - 3.5 gm/dl
A/G Ratio	1.52		0.9 - 2.1

Dr. Manisha Shah
MD (Path & Bact)
Consultant Pathologist
Reg. No. : G-15196

Dr. Jitendra Nayak
MD (Path)
Consultant Pathologist
Reg. No. : G-14786


Dr. Shreya Patel
MD(Path)
Consultant Pathologist





Marengo CIMS Hospital

CMS/2022

Reg. No : CIMS/A/2022/390564	Visit No : HC/261122/16 [HCV]
Patient Name : Mrs. NITUDEVI RAJPUT	Age(Y-M-D)/Sex : 40 Y 2 M 26 D. / Female
Referring Doctor : Dr. CIMS DOCTOR	Doctor :
Ward/Room :	Bed :
ORD/261122/382 Lab No : 2022174561 LSN : 937178 (SERUM)	Sample Quality : Normal
Collection Time : 26/11/2022 8:50:00 Arrival : 26/11/2022 9:16:02	Validation Time: 26/11/2022 11:25:46AM

	Result	Unit	Reference Range
Creatinine <i>(Buffered Jaffe Reaction Kinetic Compensated)</i>	0.78	mg/dL	0.5 - 0.9 mg/dL
Estimated GFR	89.3	mL/min/1.73m ²	50 - 102 mL/min/1.73m ²
Fasting Glucose <i>(Hexokinase)</i>	105.2	mg/dL	70 - 100 mg/dL
Thyroid Function Test			
TOTAL T3 (T3) * <i>(Electrochemiluminescence Assay)</i>	0.81	ng/ml	0.846 - 2.02 ng/ml
TOTAL T4 (T4) * <i>(Electrochemiluminescence Assay)</i>	5.62	µg/dl	5.13 - 14.06 µg/dl
TSH <i>(Electrochemiluminescence Assay)</i>	2.43	µIU/ml	0.27 - 4.20 µIU/ml
Uric Acid <i>(Uricase Colorimetric Enzymatic)</i>	5.76	mg/dL	2.4 - 5.7 mg/dL

*** END OF REPORT ***

Marengo CIMS Hospital

Dr. Shreya Patel
MD(Path)
Consultant Pathologist



Dr. Manisha Shah
MD (Path & Bact)
Consultant Pathologist
Reg. No. : G-15496

Dr. Jitendra Nayak
MD (Path)
Consultant Pathologist
Reg. No. : G-14786

CIMS Hospital Private Limited

Plot No 67/1, Opp. Panchamrut Bunglows, Near Shukan Mall, Off Science City Road, Sofa, Ahmedabad - 380060, Gujarat

© 1800 309 9999 CIN No. U85100GJ2001PTC039962

Plot No. : 67/1, Opp. Panchamrut Bunglows, Near Shukan Mall, Off Science City Road, Sofa, Ahmedabad - 380060, Gujarat



**Marengo CIMS
Hospital**


cims.org

Reg. No : CIMS/A/2022/390564	Visit No : HC/261122/16 [HCV]
Patient Name : Mrs. NITUDEVI RAJPUT	Age(Y-M-D)/Sex : 40 Y 2 M 26 D. /Female
Referring Doctor : Dr. CIMS DOCTOR	Doctor
Ward/Room	Bed
ORD/261122/382 Lab No : 2022174562 LSN : 937178 (SERUM)	Sample Quality : Normal
Collection Time : 26/11/2022 8:50:00 Anival : 26/11/2022 9:16:02	Validation Time : 28/11/2022 11:29:21AM

	<u>Result</u>	<u>Unit</u>	<u>Reference Range</u>
BUN * (Ureas with UV)	9.8	mg/dL	6 - 20 mg/dL

*** END OF REPORT ***

26/11/2022 08:50:00 2022174562 937178 SERUM



Dr. Shreya Patel
MD(Path)
Consultant Pathologist



Dr. Manisha Shah
MD (Path & Bact)
Consultant Pathologist
Reg. No. : G-15496

Dr. Jitendra Nayak
MD (Path)
Consultant Pathologist
Reg. No. : G-14786

CIMS Hospital Private Limited

Plot No 67/1, Opp. Panchamrut Bunglows, Near Shukan Mall, Off Science City Road, Sola, Ahmedabad - 380060, Gujarat

☎ 1800 309 9999 CIN No. U85110GJ2001PTC039962

Print By: ankita rainut

Reg. No : CIMS/A/2022/390564	Visit No : HC/261122/16 [HCV]
Patient Name : Mrs. NITUDEVI RAJPUT	Age(Y-M-D)/Sex : 40 Y 2 M 26 D. / Female
Referring Doctor : Dr. CIMS DOCTOR	Doctor
Ward/Room	Bed

ORD/261122/382 Lab No : 2022174567 LSN : 937178 (SERUM) Sample Quality : Normal
 Collection : 26/11/2022 8:50:00AM Arrival: 26/11/2022 9:23:52 Validation Time 26/11/2022 11:21:49

<u>Lipid Profile (With Direct LDL)</u>	<u>Result</u>	<u>Unit</u>	<u>Reference Range</u>
Type of Sample	: Fasting		
Cholesterol <i>(Enzymatic/Colorimetric, Cholesterol Oxidase, Esterase, Peroxidase Gen. 2)</i>	: 219.6	mg/dL	Less than 160 mg/dl Excellent Less than 200 mg/dl Desirable 200-239 mg/dl Borderline High 240 mg/dl & over High
Triglyceride <i>(Enzymatic Colorimetric without Glycerol Blank without Serum Blank)</i>	: 100	mg/dL	Less than 150 mg/dl Normal 150 - 199 mg/dl Borderline High 200-499 mg/dl High 500 mg/dl or greater Very High
HDL Cholesterol <i>(Direct Measured Homogenous Technique Modified Enzymatic Colorimetric Gen. 3)</i>	: 32.9 <i>7.45</i>	mg/dL	Less than 40 mg/dl Low 60 mg/dl or above Excellent
LDL Cholesterol (DIRECT) <i>(Homogenous Enzymatic colorimetric Assay)</i>	: 170.7 <i>130</i>	mg/dL	Less than 80 mg/dl Excellent Less than 100 mg/dl Optimal 100 - 129 mg/dl Near or above optimal 130 - 159 mg/dl Borderline High 160 - 189 mg/dl High 190 mg/dl & above Very High
VLDL Cholesterol <i>(Calculated)</i>	: 20	mg/dL	15 - 30 mg%
Cholesterol/HDL Ratio <i>(Calculated)</i>	: 6.67		Normal upto 4.5
LDL/HDL Ratio <i>(Calculated)</i>	: 5.19		Less than 3.5

Remarks :



Dr. Shreya Patel
MD(Path)
Consultant Pathologist

Dr. Manisha Shah
MD (Path & Bact)
Consultant Pathologist
Reg. No. : G-15496

Dr. Jitendra Nayak
MD (Path)
Consultant Pathologist
Reg. No. : G-14786




Reg. No : CIMS/A/2022/390564	Visit No : HC/261122/16 [HCV]
Patient Name : Mrs. NITUDEVI RAJPUT	Age(Y-M-D)/Sex : 40 Y 2 M 26 D. / Female
Referring Doctor : Dr. CIMS DOCTOR	Doctor
Ward/Room	Bed

ORD/261122/382 Lab No : 2022174651 LSN : 937178 (Urine) Sample Quality : Normal
 Collection Time : 26/11/2022 10:49:21 Arrival : 26/11/2022 10:49:21 Validation Time : 26/11/2022 11:59:05AM

	Result	Unit	Reference Range
Urine R & M			
PHYSICAL EXAMINATION			
Quantity	20 cc		
Colour	Pale Yellow		
Transperancy	Clear		
Reaction	S.O		
(QDS-10 Strip)			
Sp. Gravity	1.010		1.005 - 1.035
(QDS-10 Strip)			
CHEMICAL EXAMINATION			
U. Albumin	Nil		
(QDS-10 Strip/Manual)			
U. Glucose	Nil		
(QDS-10 Strip/Manual)			
U. Acetone	Absent		
(QDS-10 Strip/Manual)			
BS/BP	Absent		
(QDS-10 Strip/Manual)			
MICROSCOPIC EXAMINATION			
Pus Cell	Occasional	/H.P.F.	/H.P.F.
Red Blood Cell	Nil	/H.P.F.	/H.P.F.
Epithelial Cell	1-2	/H.P.F.	/H.P.F.
Cast	Not Seen		
Crystals	Not Seen		
Amorphous	Absent		
Monilia	Absent		

*** END OF REPORT ***



Dr. Manisha Shah
MD (Path & Bact)
Consultant Pathologist
Reg. No. : G-15496

Dr. Jitendra Nayak
MD (Path)
Consultant Pathologist
Reg. No. : G-14786



CIMS Hospital Private Limited

Plot No 67/1, Opp. Panchamrut Bunglows, Near Shukan Mal. Off Science City Road, Sola, Ahmedabad - 380060, Gujarat

1800 309 9999 CIN No. U85105GJ2001PTC039962

26-11-2022 09:23:47
ID: 1083

Years

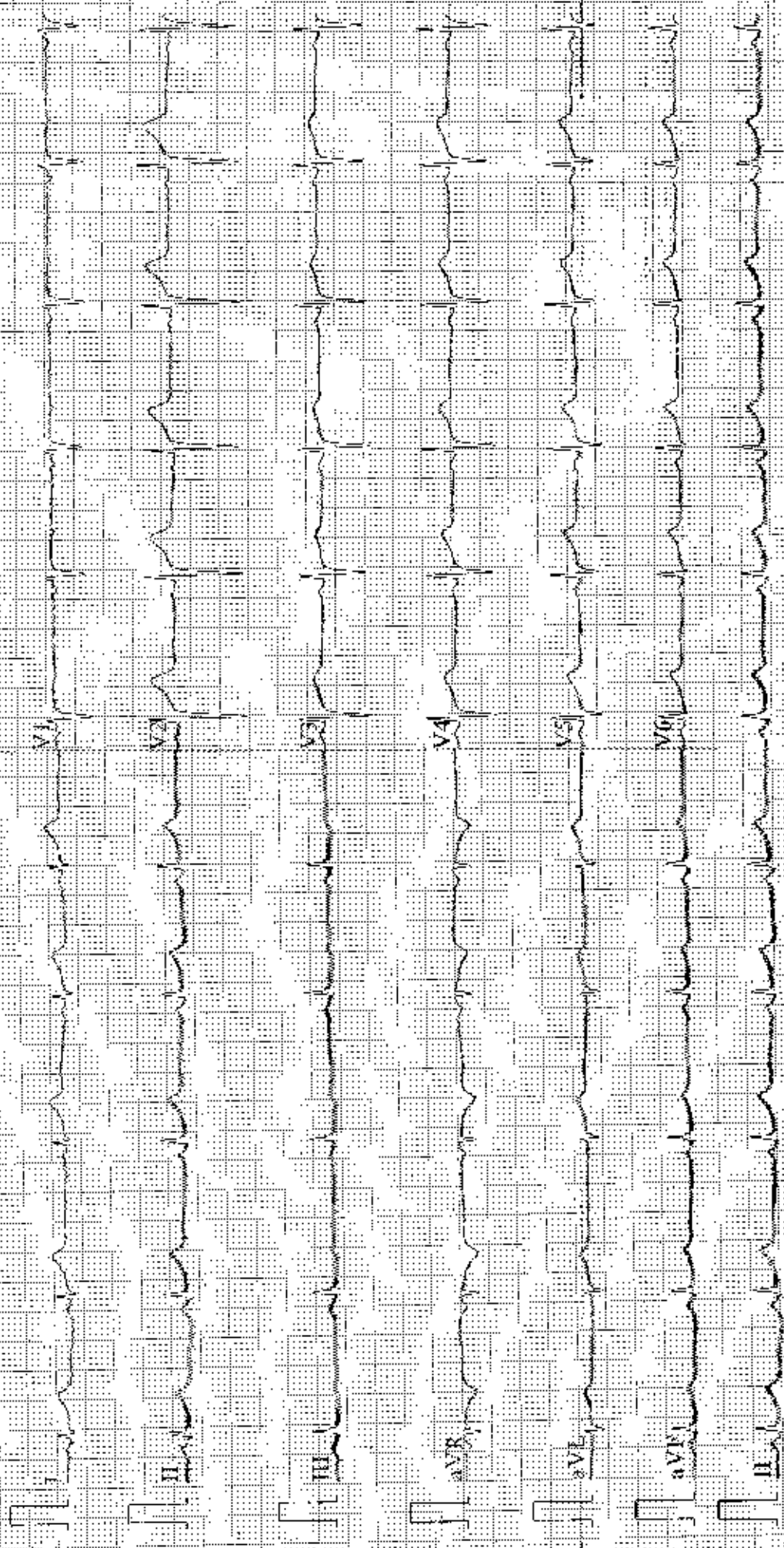
HR 61 bpm
 P 106 ms
 PR 133 ms
 QRS 80 ms
 QTc 394 ms
 P-QRS 607 ms
 RV5 SV1 0.526/0.567 mV

Diagnosis Informa

Name : Mrs. NITUDEVI RAJPUT
 Reg No : CIMS/A/2022/S9056
 DOB / Sex : 30/08/1982 / Female

NSR/WM

Report Confirmed by:



Name : Mrs. NITUDEVI RAJPUT

Reg No : CIMS/A/2022/390564

DoB / Sex : 30/08/1982 / Female

ECHO Report

Dt : 26/11/2022

Patient Details

Patient ID 321881
Name Mrs. NITUDEVI RAJPUT
Age 40 Years
Gender Female
Blood Group
Referral Doctor

ECHO Identification Detail

Doctor Incharge Dr. Vipul KAPOOR
Clinical Status Of Patient
ECHO Code RP
Finding Description

1. Normal cardiac chambers dimensions.
2. Normal LV systolic function, LVEF: 60%.
3. No RWMA.
4. Stage I diastolic dysfunction.
5. All cardiac valves are structurally normal.
6. Mild MR, Mild TR, Trivial PR, No AR.
7. No PAH, RVSP: 34 mmHg.
8. No clot/vegetation/pericardial effusion.

Dr. VIPUL KAPOOR



13 (12A)

NABH

MC-3049

OUR ACCREDITATIONS

CIMS Hospital Private Limited

Plot No 67/1, Opposite Panchmrut Bunglows Near Shakun Mall, Off Science City Road, Sola, Ahmedabad, Gujarat 380060

1800 309 9999 CIN No. U85110GJ2001PLC039962



Patient's Name :NITUDEVI RAJPUT
Reg. No. (IP/OP):HC-390564
Referred By Dr. :CIMS

Age, Sex :40Y/F
Date :26/11/2022

Plain Skiagram of Chest PA Standing View:

(Serial No-B-6749)

Both lung fields appear normal.

No evidence of pleural effusion or pneumothorax is seen on either side.

Mediastinal shadow appears normal.

Heart size and aorta appear normal.

Domes of diaphragm appear normal.

Bones under view appears normal.

Kindly correlate clinically

DR KIRTAN SHAH DR DEEPA SHAH DR UMA MEHTA DR NIMISH SHARMA DR RAVINA CHAUHAN DR YASH PATEL DR SUNALI DESAI
M.D., RADIOLOG. M.D., D.M.R.E D.M.R.D. F.R.C.R D.M.R.D. (D.N.B.) M.D. RADIOLOG. M.D., D.N.B. MD, DNB, DM, FRCR
CONS. RADIOLOGIST CONS. RADIOLOGIST CONS. RADIOLOGIST CONS. RADIOLOGIST CONS. RADIOLOGIST CONS. RADIOLOGIST NEURORADIOLOGIST

Note: This is only a radiological impression and not the final diagnosis. All diagnostic modalities have their own limitations.
Therefore radiological modality report should be interpreted in correlation with clinical and pathological findings.

FOR RADIOLOGY REPORTS ONLY





Patient's Name : NITUDEVI RAJPUT
Reg. No. (IP/OP): HC-390564
Referred By Dr. : CIMS

Age, Sex : 40Y/F
Date : 26/11/2022

USG OF ABDOMEN & PELVIS

LIVER: Liver is normal in size and echotexture. No evidence of focal SOL or dilatation of IHBR seen. Porta hepatis appear normal.

GALLBLADDER: Gallbladder appeared normal. No calculus or mass lesion seen.

PANCREAS: Visualised pancreas appeared normal in size and echotexture. No focal lesion, mass or pancreatitis.

SPLEEN: Spleen appears normal in size and echotexture.

PARAAORTIC REGION: Aorta grossly appeared normal. No paraaortic lymphnodes seen.

KIDNEYS: Both kidneys appear normal in size, shape and in position.

Left kidney shows 4mm size calculus in lower pole calyx and 3mm sized calculus in upper pole.

No obstructive uropathy on left side.

Cortex and collecting system of right kidney appeared normal.

No calculus or obstructive uropathy on right side.

Right kidney: 103x33mm. Left kidney: 91x33mm.

URINARY BLADDER: Bladder appeared normal. No calculus or mass lesion is seen.

UTERUS: Uterus appears bulky and measures 90x43x63mm.

Few small fibroids are noted in anterior / posterior subserous region and intramural location, largest one in anterior wall subserous region measures 12x12mm.

Presence of few echogenic foci noted in junctional zone anteriorly.

Endometrial thickness appears normal and measures 9mm with evidence of well-circumscribed echogenic lesion centrally with internal vascular stalk measuring 21x7x18mm, suggesting endometrial polyp.

No GS seen.

OVARIES: Both ovaries are adherent to uterus. No adnexal mass lesion seen on either side.
Right ovary: 29x14mm. Left ovary: 24x12mm.

No evidence of free fluid or collection is seen in peritoneal spaces.
Normal small bowel peristalsis noted.

COMMENTS: Appearance suggests

- Left renal non-obstructive calculi as described.
- Bulky polyfibroid uterus with ? early changes of adenomyosis.
- Solitary endometrial polyp centrally.
- Bilateral adherent ovaries to uterus.

Kindly correlate clinically.

DR KIRTAN SHAH M.D., D.M.R.E. CONS. RADIOLOGIST
DR DEEPA SHAH M.D., D.M.R.E. CONS. RADIOLOGIST
DR UMA MEHTA D.M.R.D., F.R.C.R. CONS. RADIOLOGIST
DR NIMISH SHARMA D.M.R.D. (D.N.B.) CONS. RADIOLOGIST
DR RAVINA CHAUHAN M.D. RADIODIAG. CONS. RADIOLOGIST
DR YASH PATEL M.D., D.N.B. CONS. RADIOLOGIST
DR SUNALI DESAI MD, DNB, DM, FRCC NEURORADIOLOGIST

Note: This is only a radiological impression and not the final diagnosis. All diagnostic modalities have their own limitations. Therefore radiological modality report should be interpreted in correlation with clinical and pathological findings.



FOR RADIOLOGY REPORTS ONLY