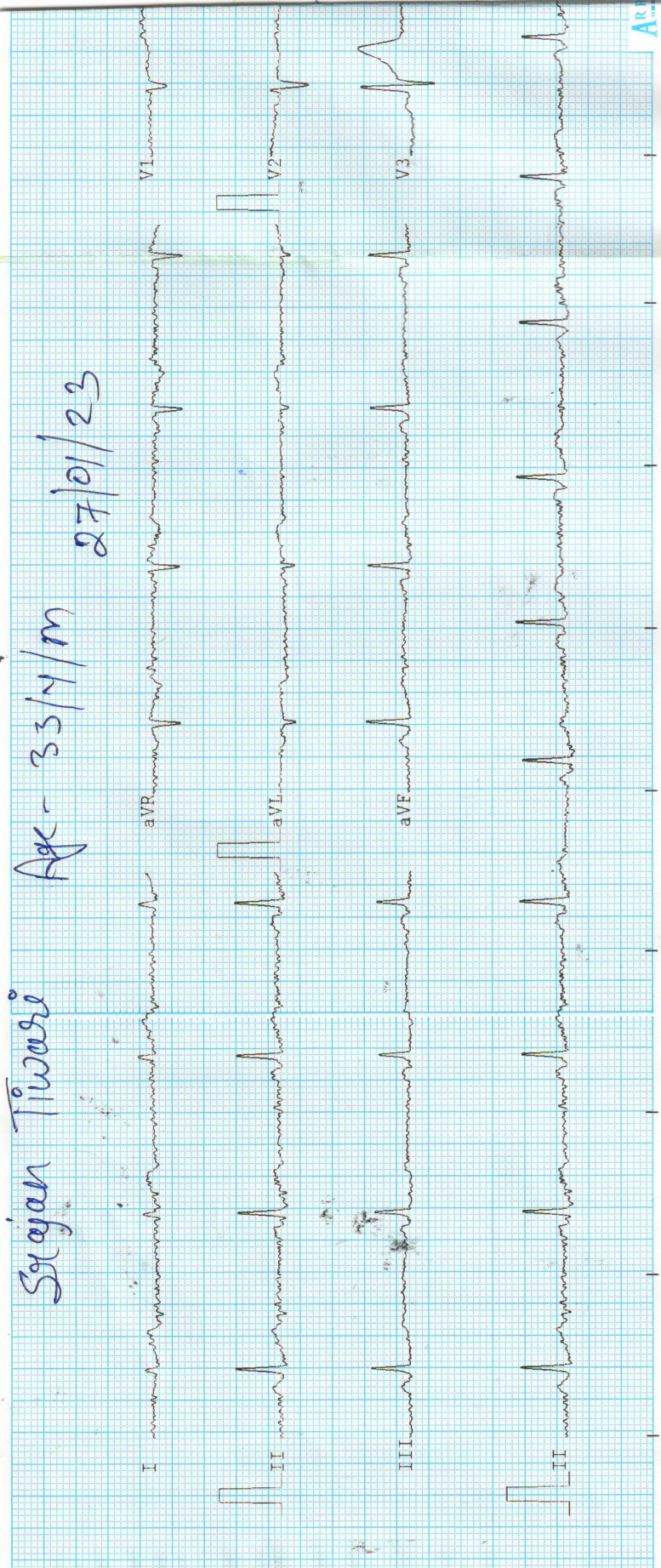


Srejan Tiwari

Age - 33/4/m

27/01/23



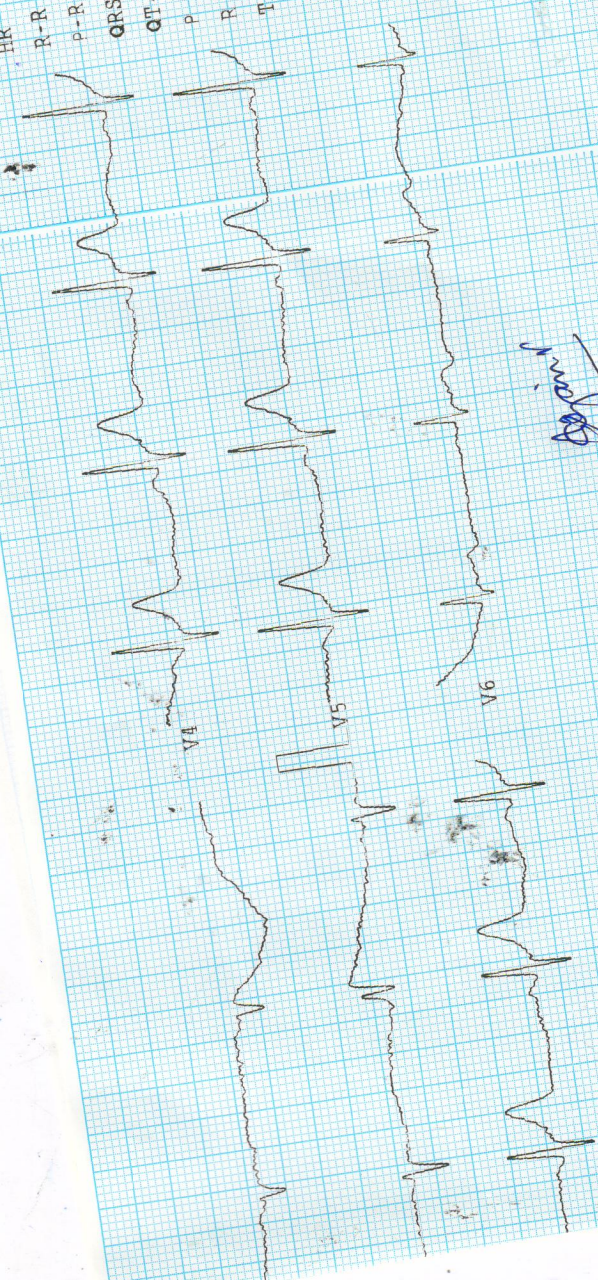

310521 best-innovu

A.R.

126011 ADDP

Observations

HR - 66 bpm
R-R - 904 ms
P-R - 061 ms
QRS - 72 ms
QT/QTc - 303/318 ms
P Axis - 90°
R Axis - 83°
T Axis - 86°



Signature

Remarks

Unconfirmed report

W CE



डिवाकर डायग्नोस्टिक सेंटर
E-7/636, पंजाब नेशनल बैंक के पास, मैन रोड, अरसा कॉलोनी, भोपाल (म.प्र.)
फॉन : 9826340190



Pathologist
MBBS, CCP
Consultant Pathologist

A. PHYSICAL EXAMINATION	
1. Colour	Pale Yellow
2. Appearance	Clear
3. Specific Gravity	Q.N.S.
B. CHEMICAL EXAMINATION	
1. Reaction	Acidic
2. Albumin	Nil
3. Sugar	Nil
4. Bile Salts	Absent
C. MICROSCOPIC EXAMINATION	
Pus Cells	2-3/HPF
R.B.C.	Nil
Epithelial Cell	2-3/HPF
Cast	Nil
Crystals(Cal.Oxa)	Nil
Bacteria	Nil
Amorphous	Nil
T. Vaginitis	Nil

URINE ANALYSIS

Pt Name :- Mr. Srajan Tiwari
Age :- 33/M
Lab. No. :- 03
Date :- 27/01/2023

डिवाकर डायग्नोस्टिक सेंटर
E-7/636, पंजाब नेशनल बैंक के पास, मैन रोड, अररा कॉलोनी, भीपाल (म.प्र.)
मॉ : 9826340190



फॉन : 9826340190

EXAMINATION OF BLOOD

TEST	RESULT	NORMAL VALUE
Haemoglobin	14.5gms%	Female 12-16gms%, Male 14-18gms%
Red Cell count	5.50	4.5-5.6 million /cumm
Platelete Count	2.34	1.5-5.6 Lac/cumm
Leucocytes per.cu.mmm	6000/cumm	5000-11000/cumm
Neutrophils	56%	50-70%
Lymphocytes	37%	20-40%
Eosinophils	03%	0-7%
Monocytes	04%	2-8%
PCV	45.2	37-47
MCV	82.2	76-96
MCH	26.3	27-32
MCHC	32.0	31-35
ESR	08	Male 0-9, Female 0-20mm/FHR
Blood Group	"B" Positive	By slide method
Total Serum Cholesterol	178.0	100-250 mg%
Serum Triglyceride	148.0	Up to 150 mg%
Serum Cholesterol HDL	51.0	Up to 65 mg%
Serum Cholesterol LDL	97.4	Up to 125 mg%
VLDL	29.6	Up to 30 mg%
S.Bilirubin(Total)	0.9	0.2-1.0mg/dl
Direct	0.5	0.0-0.25mg/dl
Indirect	0.4	
SGOT	26.0	5-35U/L
SGPT	30.0	8-40U/L
Alk Phosphatase	8.9	3-13 KA units
S.Protein(Total)	7.0	6.0-8.0mg%
Albumin	4.9	3.7-5.3mg%
Globulin	2.4	1.5 to 3.5 mg%
Blood Urea	22.0	Up to 40 mg%
S.Creatine	0.98	0.5-1.4mg/dl
S. Uric Acid	6.0	3.5-7.5mg%
GGTP	24.0	5-35 UL/dl
Fasting Blood Sugar	84.2	Up to 110 mg%
PP Blood Sugar	110.0	Up to 125 mg%
Glycosylated Hemoglobin	5.5	Below - 6.0% -Non Diabetic control 6-7% -Excellent control Above- 8% -Poor control
HB1c		
Thyrod Stimulating Hormone(TSH)	3.9	0.27-4.2

Dr. B. M. Agarwal
 Pathologist
 MBBS, DCP
 Consultant Pathologist



All test have technical limitation. Collaborative clinic pathological interpretation is mandatory. In case of disparity test may be repeated immediately. Typographical mistakes should be get correct instantly. This report is not valid for medico legal purpose

PTO

Right Kidney is normal in size, shape and position. Corticomedullary differentiation (CMD) is well maintained. Normal cortical thickness is noted. No E/O hydronephrosis or calculus is noted.

Pancreas appear normal in size, shape and echo texture with smooth contour. No peripancreatic pathology seen. (Not seen due to gases) Spleen is normal / enlarged in size and normal in echo texture. IVC and aorta appear to be normal. No evidence of lymphadenopathy is noted. No evidence of free fluid is noted.

Gall Bladder is physiologically well distended / collapsed. No E/O echogenic foci in GB lumen. GB wall is normal / thickened. No E/O pericholecystic collection. common duct reveals normal course and caliber.

Liver appears normal / enlarged in size and shape with smooth in outline. Normal / increased parenchymal echogenicity is noted. No E/O focal lesion / IHBR dilatation is seen. Hepatic veins and portal veins appear normal. *gr. I. fatty liver.* No E/O Subdiaphragmatic Collection.

Indication :
WHOLE ABDOMEN ULTRASOUND REPORT

Name : Mrs. *Sargan Tiwar 33/Male* R/B
Health check-up.
Date : *27/1/23*
Age : YRS./F

श्री. सविता रेडियोलॉजिक
34, भूतल, मोहिनी अदिति आर्कड, शाहपुरा मस्जिद के पास
भरत नगर रोड, ई-7/194, अररा कॉलोनी, भोपाल - 462038
Mob. : 8989649694, 9516333619
Clinic Registration : CL/5392/Jun/2017
PNDT Registration : MPPCPNDT/BPL/2017/206



Left Kidney is normal in size, shape and position. CMD is well maintained. Normal cortical thickness is noted. No E/O hydronephrosis or calculus is noted.

Urinary Bladder is well distended (physiological) / collapsed. Its contents are echo free. No E/O bladder wall thickening is noted. Post-void residue is insignificant.

Prostate is normal in size, shape and echo texture with smooth outline. No E/O focal lesion is noted.


Uterus is ante/retroverted and normal in size, shape and echo texture with smooth outline. No E/O focal lesion is noted, endometrial echo appear normal. Cervical and vaginal shadows appear normal.

Right Ovary appears Enlarged / Normal in size, shape and echo texture.

Left Ovary appears Enlarged / Normal in size, shape and echo texture.

Impression : Normal study.

Dr I Jothy Kumar



Advised clinical Correlation.

