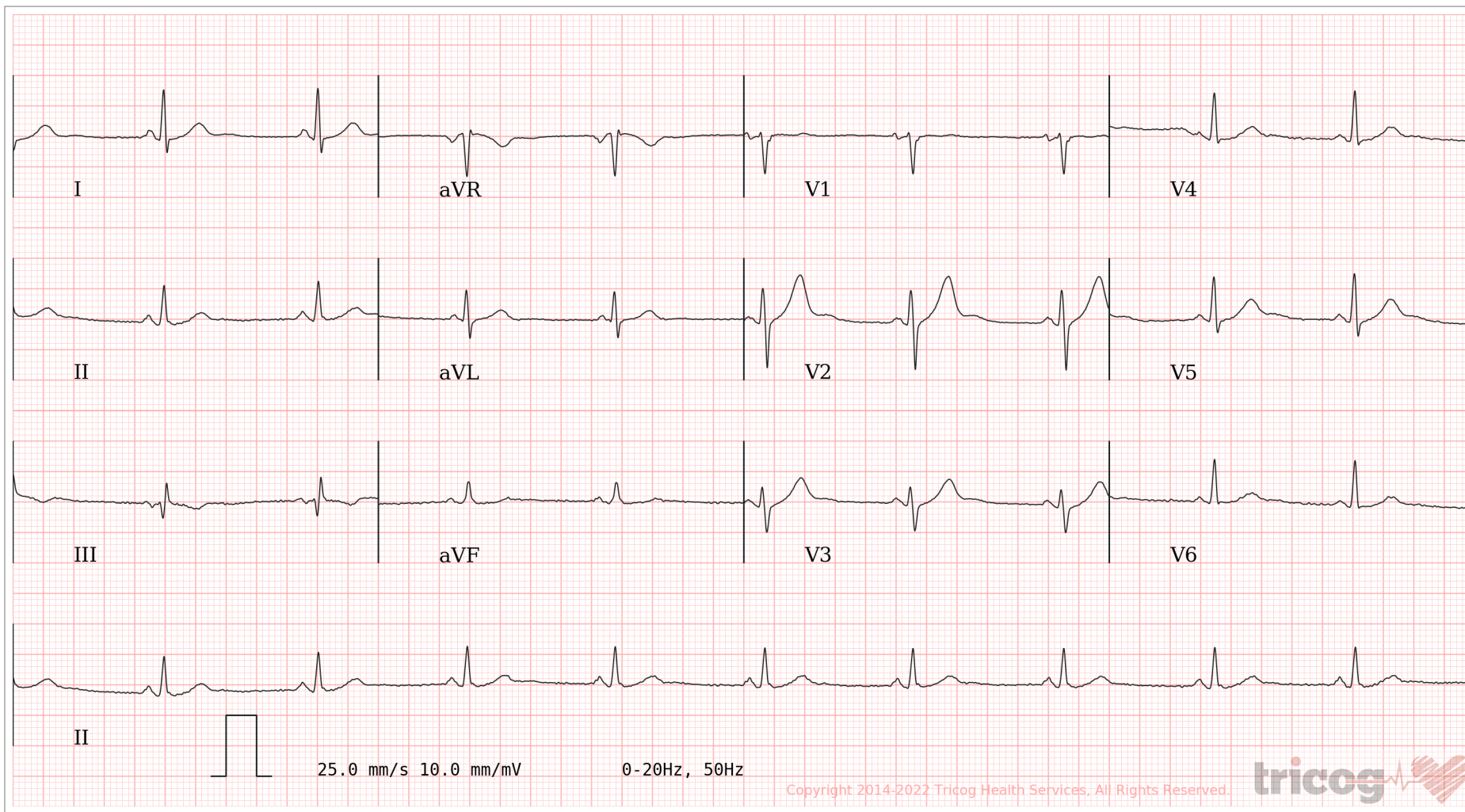




Age / Gender: 32/Male  
Patient ID: CHL20146162223  
Patient Name: ATUL KUMAR ECG

Date and Time: 27th Aug 22 9:44 AM



AR: 62bpm VR: 62bpm QRSD: 78ms QT: 370ms QTc: 375ms PRI: 112ms P-R-T: 32° 44° 24°

ECG Within Normal Limits: Sinus Rhythm, Normal Axis. Please correlate clinically.

AUTHORIZED BY

Dr. Charit  
MD, DM: Cardiology

63382

REPORTED BY

Dr. Avinash K

76720