



भारतीय विशिष्ट पहचान प्राधिकरण
UNIQUE IDENTIFICATION AUTHORITY OF INDIA

पता:

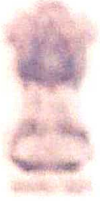आत्मज: शिव बचन साहू
बिशुनपुरा, बिशुनपुरा, पटना
बिहार, 800111

Address:

S/O: Sheo Bachan Sahu
Bishunpura, Bishunpura, Patna
Bihar, 800111

9285 5829 4802

Aadhaar - Aam Aadmi ka Adhikar



भारत सरकार

GOVERNMENT OF INDIA



विजय प्रकाश

Vijay Prakash

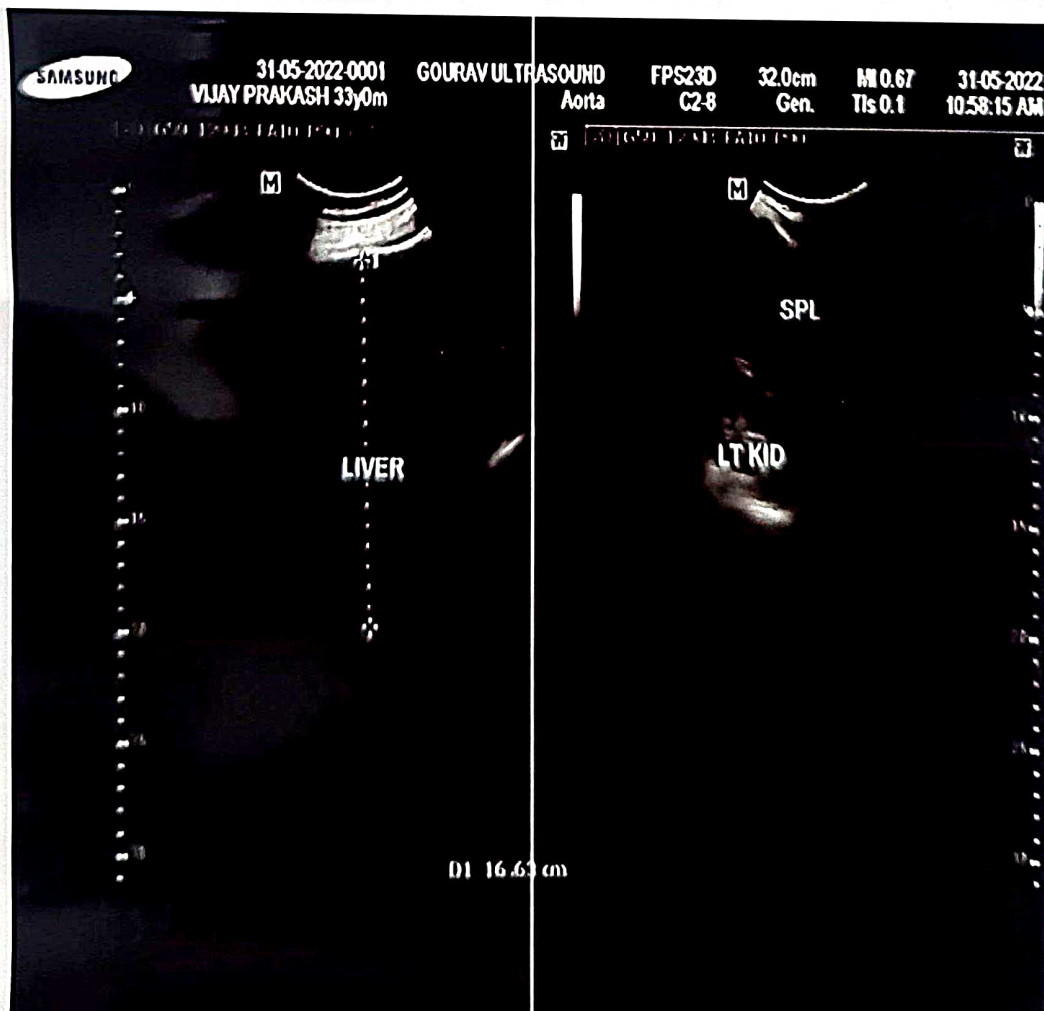
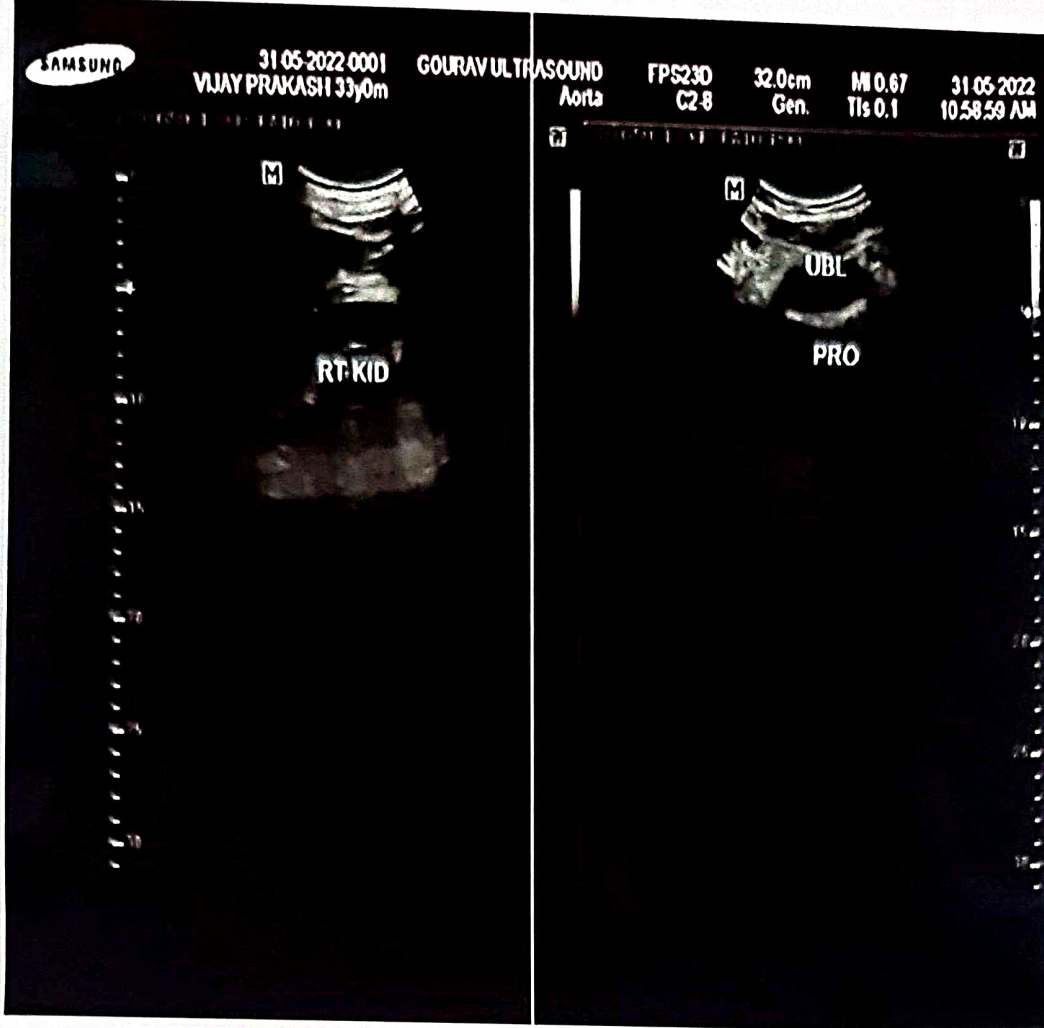
जन्म तारीख/DOB:11/03/1988

पुरुष Male



9285 5829 4802

आधार - आम आदमी का अधिकार



GAURAV MULTI SPECIALITY HOSPITAL

TOKEN NO - 1

NEAR CHHAYA CINEMA, THIKHAMPUR, BALLIA
05498 - 241635

Dr. D. Rai

MBBS (Hons)
M.D (General Medicine) . IMS BHU
Cardiologist & General Physician
Member
Association of Physician of India



UHID No. 10,197

Date 31/05/2022

Patient Name Mr. Vijay Prakash

Father Name/Husband Name

Age 33 Sex M

Weight 80 kg

TEMP. - 96.3

Address Bishunpura Ptna

B.P - 120/80 Pulse - 77

SPO2 - 97

Mobile No 9536691100

Medical Examination Report from Physician

no complaints, no fever, no abnormal examinations

o/e: Palms - Nil, no jaundice

hr: 90 beat/min, B.P. 120/80 SPO2 97

WT - 80kg, TB 96.3°F

e/e: Chest: Normal breath sound,

no crepts or rhonchi

CVS: Normal heart sound
no murmur

l/a: soft, non-tender
hepatomegaly

caus - Normal

Conclusion

On medical examination Patient is
medically fit

31.05.22

Dr. D. Rai

M.B.B.S., M.D. (Medicine)
Reg. No.: 29811

Gaurav Multispeciality Hospital
Tikhampur, Ballia

GAURAV MULTI SPECIALITY HOSPITAL

TOKEN NO - 1

NEAR CHHAYA CINEMA, THIKHAMPUR, BALLIA
05498 - 241635

Dr. D. Rai

MBBS (Hons)
M.D (General Medicine) . IMS BHU
Cardiologist & General Physician
Member
Association of Physician of India



UHID No.	10,197	Date	31/05/2022
Patient Name	Mr. Vijay Prakash	Father Name/Husband Name	
Age	33 Sex M	Weight	80 kg
Address	Bishunpura Ptna	B.P	-120/80
Mobile No	9536691100	Pulse	- 77
		TEMP.	- 96.3
		SPO2	- 97

Medical Examination Report from Physician

no complaints, no fever, no abnormal examinations

o/e: Pallas - Nil, NO Tenderness
pulse: 90 beat/min, Bp. 120/80 SPO2: 97
wt - 80kg, Ht 96.3"

o/e: Chest: normal breath sound,
no crepts or rhonchi

CVS: Normal heart sound
no murmur

P/A: soft, non-tender
hepatomegaly

Coils - Normal

Conclusion

On medical examination patient is
medically fit

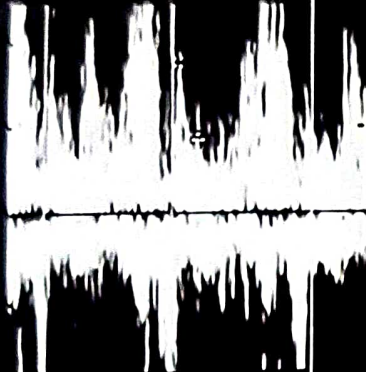
31.05.22
Dr. D. Rai
M.B.B.S., M.D. (Medicine)
Reg. No.: 29811
Gaurav Multispeciality Hospital
Tikhampur, Ballia

SAMSUNG


VDJAY PRAKASH 33/M 31/05/2022

14:02:46

MV1 25.73 cm/s
 MV A 53.83 cm/s
 MVE/A 0.48
 HR 100 bpm



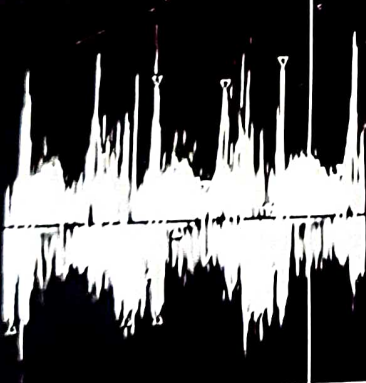
IV1 20.98 cm/s
 IV A 51.22 cm/s
 IVE/A 0.39



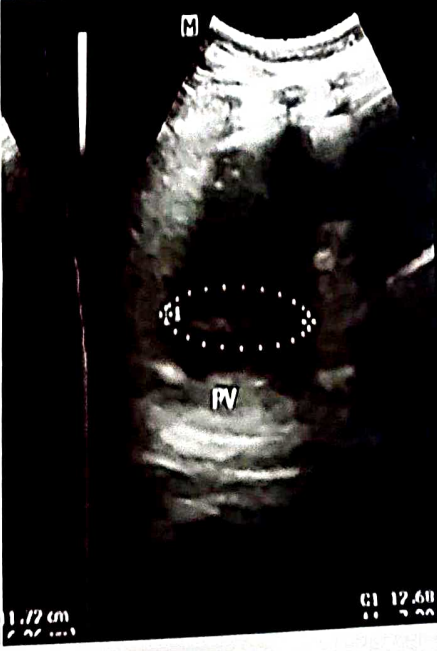
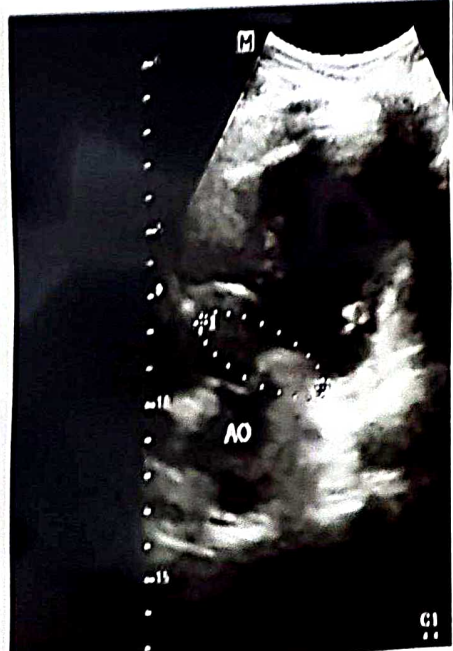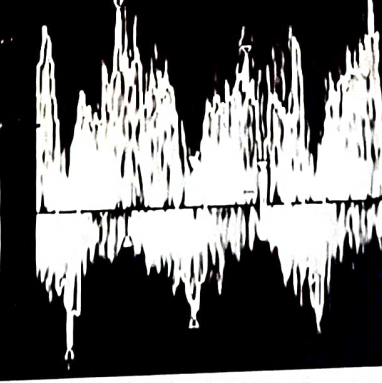
SAMSUNG

VDJAY PRAKASH 33/M 31/05/2022

PV Vmax 51.56 cm/s
 PV Vmean 17.51 cm/s
 PV PGmax 1.06 mmHg
 PV PGmean 0.14 mmHg
 PV V11 0.98 cm
 PV PHT 47.72 ms
 PV Acc1 58 gms
 PV Acc 1811.93 cm/s
 PV Dec1 14 ms
 PV Dec 3588.75 cm/s²



AV Vmax 51.56 cm/s
 AV Vmean 33.05 cm/s
 AV PGmax 1.06 mmHg
 AV PGmean 0.47 mmHg
 AV P11 38 cm
 AV V11 1.72 cm
 AV Acc1 42 gms
 AV Acc 1717.50 cm/s
 AV Dec1 129 ms
 AV Dec 398.75 cm/s²



C1 1.72 cm

C1 12.60

Electrocardiogram Report

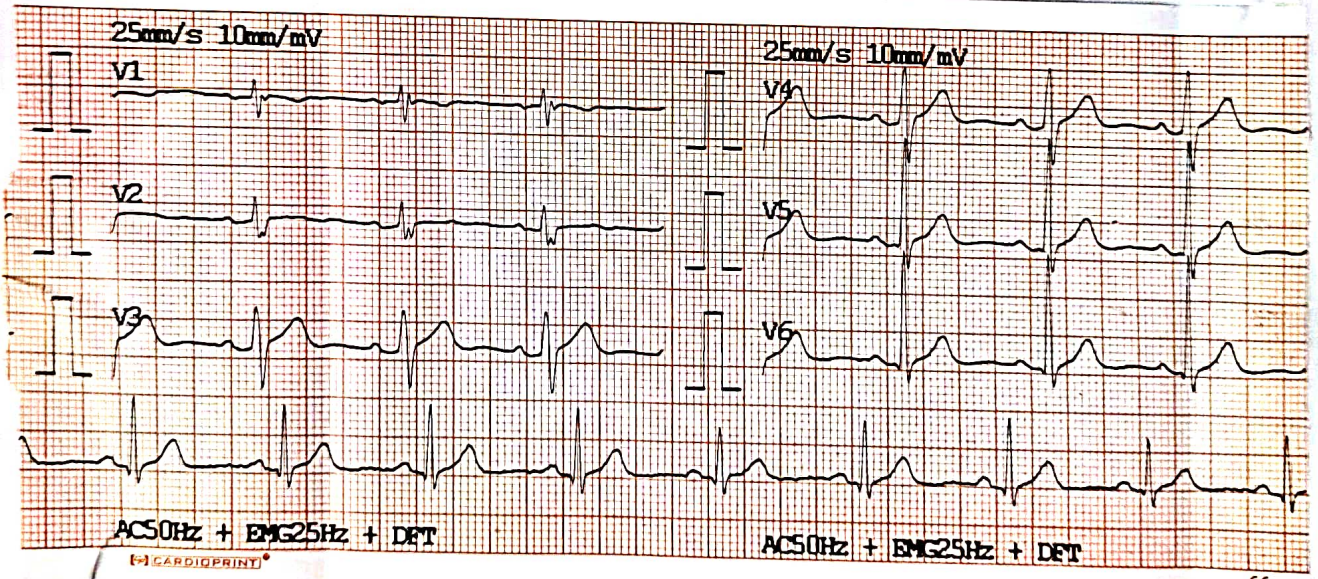
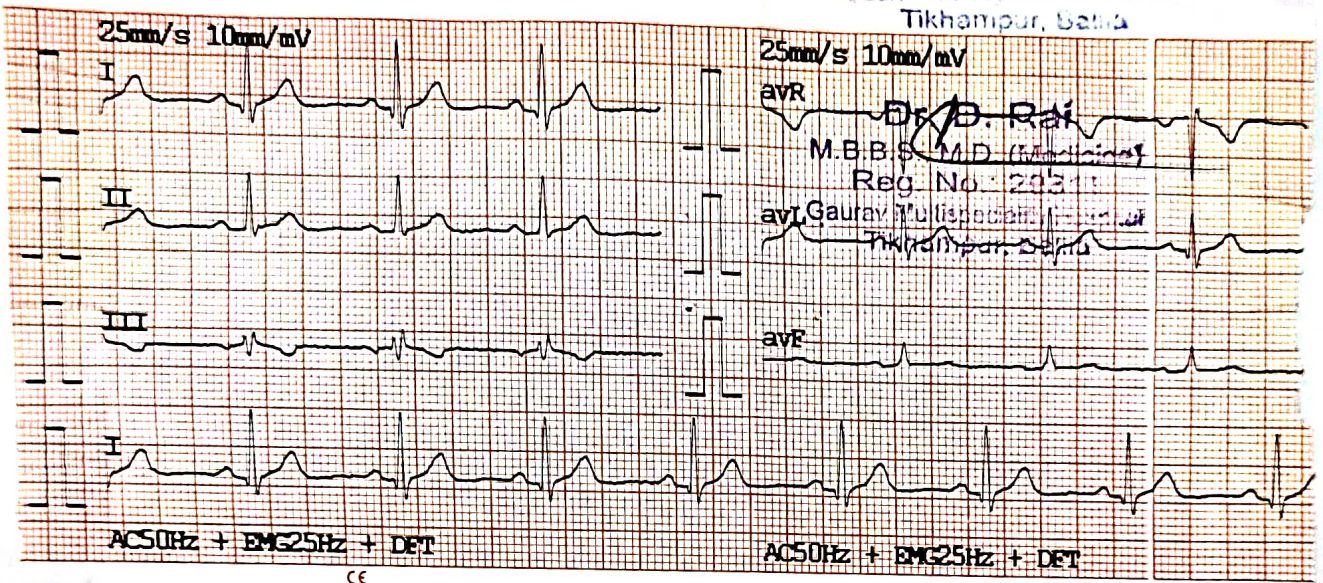
- Client Name **VIJAY PRAKASH** Age **33/M** Date **3/10/2022**
- Clinical summary **NO COMPLAINT**
- ECG Findings **Normal**
- Rate **76** Rhythm **Regular** Sinus Axis **Normal**
- P wave **Upright** Mechanism PR interval **0.16 sec** complex **0.08 sec**
- ST Segment **0.28 sec** T Wave **Upright** Q Wave QT interval **0.36 sec**
- Diagnosis / **Normal** Absent
- Impression **Normal**
- Speed **25 mm/s**
- Voltage **10 mV**

Dr. D. Rai

M.B.B.S., M.D. (Medicine)

Dr. signature

Tikhampur, Banda



भारत सरकार

GOVERNMENT OF INDIA



विजय प्रकाश

Vijay Prakash

जन्म तारीख/DOB:11/03/1988

पुरुष Male



9285 5829 4802

आधार - आम आदमी का अधिकार

Dr. P. Rai
M.B.B.S. (Medicine)
Reg. No. 2011
Gaurey Multi Speciality Hospital
Tikra, Patna



Ph: 05498-241635

Gaurav Multispeciality Hospital

Near Chhaya Cinema, Tikhampur, Ballia (U.P.)

Pathology & Radiology

PATIENT NAME: VIJAY PRAKASH

SEX: M

AGE: 33 YRS

ADV BY : Dr D Rai MBBS MD

DATE : 31/05/2022

INV : X Ray Chest PA View

Findings:

- Both the lungs fields are equally translucent.
- The Tracheal silhouette in mid line.
- Heart size and Cardiac out lines are normal.
- The costo-phrenic angles are clear.
- No hilar mediastinal mass is seen.
- No obvious skeletal abnormality seen.

Impression : No Abnormality detected. Normal Chest X ray.

Dr Seema pandey
MBBS MD (Radio Diagnosis)
Radiologist

Dr. Seema Pandey (Radiologist)

M.B.B.S., M.D.

Reg. No.-38790

Note.: We use sterilized disposable syringe & needle for every patient.
This report not valid for medico-legal purpose. It is to help clinician better patient management.
Discrepancies due to technical or typing error should be reported immediately within 24 hours for correction.



Ph: 05498-241635

Gaurav Multispeciality Hospital

Near Chhaya Cinema, Tikhampur, Ballia (U.P.)

Pathology & Radiology

PATIENT: VIJAY PRAKASHI
REFERED BY DR. D. RAI

DATE 31/05/2022
AGE 33 Yr./M.

ECHOCARDIOGRAPHY & COLOR DOPPLER REPORT

Regional Wall Motion Abnormality (RWMA): Normal at Rest.

Sinus Rhythm & No-Arrhythmia:- 74 BpM.

DOPPLER STUDY :

MR 0-0/4 ; TR 0/4 ; / AR 0-0/4 ; PR 0/4. (Normal Value 0-1 / 4).

PA Pressure : Normal. . PASP = 31.4 mm./Hg.

COLOR FLOW MAPPING :

Regurgitation Not Audible at MV, AV, : Regurgitation Not Audible at TCV,; PV.

FINAL IMPRESSION :

1. NORMAL; M.V. & A.V & NORMAL LT. ATRIUM & LT.VENTRICLE.
2. NORMAL LV EJECTION FRACTION ; LVEF = 57 %.
3. PULMONARY & TRICUSPID VALVES ARE NOT STENOSED.
4. NORMAL RV, S & D FUNTION & LV, S & D FUNTION; NORMAL PASP.
5. NORMAL RWMA AT REST; NO CARDIOMEGALY APPARENT.
6. SINUS RHYTHM; NO ARRHYTHMIA AND NO APPENDICULAR CLOT SEEN..

CARDIOLOGIST
Dr. Seema Pandey (Redia)
M.B.B.S., M.D.
Reg. No.-38790

Note.: We use sterilized disposable syringe & needle for every patient.
This report not valid for medico-legal purpose. It is to help clinician better patient management.
Discrepancies due to technical or typing error should be reported immediately within 24 hours for correction.



Ph: 05498-241635

Gaurav Multispecialty Hospital

Near Chhaya Cinema, Tikhampur, Ballia (U.P.)

Name .VIJAY PRAKASH

AGE: 53/M


Ref.by - DR.D.RAI MBBS M

Pathology & Radiology

DATE 31/05 /2022

BIOCHEMISTRY				HEAMATOLOGY			
TEST	RESULT	UNIT	NORMAL	TEST.....	RESULT.....	UNIT....	NORMAL
SUGAR(F)...	79	mg/dl...	70-110	HB.....	12.5	gm%	11.5-14.8
BUN	15	Mg/dl....	10-50	TLC	9800	cu/mm....	5000-11000
CREATININE	0.8	mg/dl ...	0.6-2.0	DLC			
CHOLESTEROL..	152	mg/dl ...	<150	NEUTROPHILS	68	%	50-70
HDL	51	mg/dl	<60	LYMPHOCYTES	27	%	30-50
LDL	89	mg/dl..	<100	EOSINOPHILS	05	%	0-5
VLDL	102	mg/dl.	<110	MONOCYTES		%	
TRIGLYCERIDE	157	mg/dl	<160	ESR	3	mm(at the end of one hr)	0-10
BILIRUBIN(T)	1.6	mg%	0-1	PLATELET COUNT	2.91000		1.5-3.5 lakh
BILIRUBIN(D)	0.9	mg%	0.2-0.7	RBC	4.8	cells/ul	3.5-5.5
BILIRUBIN(I)	0.7	mg%	0.2-0.8	MCV	93	fl	80-100
SGOT	49	IU/L	15-40	MCH	31	pg	27-34
SGPT	65	IU/L	20-45	MCHC	33	g/dl	32-36
S.CALCIUM	9.4	mg/dl	8.0-11.0	HCT.	46	%	37-55
ALKALINE PHOSPHATASE	149	IU/L	70-150	HBsAg -	NEGATIVE		
TOTAL PROTEIN	7.9	g/100ml	6.5-8.3	HIV I&II -	NEGATIVE ELISA METHOD		
ALBUMIN	4.5	g/100ml	3.5-5.5	HbA1c	4.9	(HPLC METHOD)	RANGE 4-6%
GLOBULIN	3.6	g/100ml	1.5-3.8				
A/G RATIO	2.1	1.5-2.5		BLOOD GROUP	O+ POSITIVE		
URIC ACID	4.9	mg/dl	3-7	T3	1.78	0.89-2.44nmol/L	
GGT	16	IU/L	3.0-28.7	T4	13.2	9.0-21.0 mmol/L	
				TSH	2.2	0.35-4.94 Mu/L	

PATHOLOGIST

Dr. 
M.B.B.S.
DNB (Pathology)

Note: We use sterilized disposable syringe & needle for every patient.

This report not valid for medico-legal purpose. It is to help clinician better patient management.

Discrepancies due to technical or typing error should be reported immediately within 24 hours for correction.

Gaurav Multispecialty Hospital
Tikhampur, Ballia.



Ph: 05498-241635

Gaurav Multispeciality Hospital

Near Chhaya Cinema, Tikhampur, Ballia (U.P.)

Pathology & Radiology

PATIENT : VIJAY PRAKASH
REFERED BY DR. D. RAI

DATE 31/05/2022
AGE 33 Yr. /M.

LIVER

Liver enlarged in shape and size is 15.2 Cm. Intrahepatic biliary radicals, portal veins and hepatic veins are not dilated. Echogenicity is normal. No Mass seen in liver

GALL BLADDER.

G.B. not visualize. CHOLECYSTECTOMY

C.B.D. : Normal in caliber.

PANCREAS.

Pancreas is normal in shape, size and echo pattern.

SPLEEN.

Spleen is normal in shape and size & size is 8.8 cm.

KIDNEYS

Rt kidney is normal in shape and size. Lt kidney is also normal in shape and size. Cortico-medullary differentiation is normal and no evidence of hydronephrosis or nephrocalculosis seen..

URINARY BLADDER

Normal in shape, size inner mucosal thickening. Echopattern is normal. No calculi / Mass / Lesion is seen.

PROSTATE

It is normal in size, Capsules are normal & Intact. It's volume is about 17 cc./Gms.

IMPRESSION

1. HEPATOMEGALY.
2. CHOLECYSTECTOMY.
3. CBD NORMAL.
4. BOTH KIDNEYS NORMAL.
5. SPLEEN NORMAL.
6. URINARY BLADDER NORMAL.
7. PROSTATE NORMAL
8. GASEOUS BOWEL'S LOOPS.

Dr. Seema Pandey (Radiologist)
SONOLOGIST
M.B.B.S., M.D.
Reg. No. - 38790

Note.: We use sterilized disposable syringe & needle for every patient.
This report not valid for medico-legal purpose. It is to help clinician better patient management.
Discrepancies due to technical or typing error should be reported immediately within 24 hours for correction.



Gaurav Multispeciality Hospital

Ph: 05498-241635

Near Chhaya Cinema, Tikhampur, Ballia (U.P.)

Pathology & Radiology

PATIENT : VIJAY PRAKASH
REFERED BY DR. D. RAI

DATE 31/05/2022
AGE 33 Yr. /M.

ECHOCARDIOGRAPHY & COLOR DOPPLER REPORT

Quality of Imaging : FAIR

MEASUREMENT/DIMENSIONS	ABSOLUTE VALUE	NORMAL (Adult)
Aortic Root Diameter	29.84mm.	20 - 37 mm. < 22 mm/ m2
Aortic Valve Opening	24.8 mm.	15 - 26 mm.
Left Atrial Dimension	24.2 mm.	19 - 40 mm. < 22 mm/ m2
RV Dimension	24.8	07 - 26 mm.
RV Thickness	08 mm.	03 - 09 mm.
LV ED Dimension	42.5 mm.	37 - 56 mm. < 32 mm/ m2
LV ES Dimension	28.3 mm.	22 - 40 mm.
IVS Thickness	09.6 mm.	09 - 11 mm.
LVPW Thickness	10.5 mm.	05 - 11 mm.
Mitral Valve Area	6.10 cm ²	> 6 cm ² .
Tricuspid Valve Area	7.08cm ²	> 7 cm ² .
IVSeD / IV SeS	07 - 09 mm	06 - 12 mm.

MORPHOLOGICAL					
Mitral Valve	NORMAL	Right Ventricle	Normal	Inter Atrial Septum	Normal
Tricuspid Valve	NORMAL	Left Ventricle	Normal	I.Ventricular Septum	Normal
Aortic Valve	NORMAL	Right Atrium	Normal	Aorta	Normal
Pulmonary Valve	NORMAL	Left Atrium	Normal	Pulmonary Artery	Normal

2 D IMAGING :

LV & LA. are Normal & RV & RA is normal in size.

Pulmonary & Tricuspid Valves are normal.

Aortic & Mitral valve are not Stenosed.

I.V. Systolic function : TRIVIAL.

I.V. Diastolic function : TRIVIAL.

M.R. & A.R. are not audible ; T.R. & P.R. & are not audible.

LV Ejection Fraction = 57 %.

RV Function : Normal

Continued Pg. 2.

Note.: We use sterilized disposable syringe & needle for every patient.
This report not valid for medico-legal purpose. It is to help clinician better patient management.
Discrepancies due to technical or typing error should be reported immediately within 24 hours for correction.