



H Swaminarayan Nagar, Off Mumbai-Agra Highway,
Panchvati, Nashik - 422 003.

+91- 253 - 2510250 / 350 / 450 / 550 / 750

apollonashik@apollohospitals.com

www.askapollo.com

QFAHN/BILL/003/V1



Name : Mr. MAHESH RAMESH THUBE (35 /M)

Date : 08/11/2022

Address : MUMBAI NAKA NASHIK, NASHIK, NASHIK, MAHARASHTRA, INDIA

Examined by:

UHID : MHN1.0000127853

Package : MediWheel Full Body Health Checkup Male Below 40
Package

AHC No : NSKAH28203



CHIEF COMPLAINTS

For corporate health checkup
No specific complaints

PRESENT KNOWN ILLNESS

Present known illness

No history of : - Diabetes mellitus, Hypertension, Thyroid disorder, Heart disease, Stroke, Asthma, COPD, Cancer



DRUG ALLERGY

NO KNOWN ALLERGY

:08/11/2022



SYSTEMIC REVIEW

Cardiovascular system

- Nil Significant

Past medical history

Do you have any allergies? - No

Do you have any drug allergies? - No

Past medical history - nil significant

Covid 19 - No

Surgical history

Others - Kidney Stone 14 yrs
befour, Lt Leg # 3 yrs
befour

Immunization history

- Covid Dose1, Covid Dose2



Personal history

Marital status - Married
No. of children - 01
Diet - Mixed Diet
Alcohol - consumes alcohol
occasionally

Smoking - No
Chews tobacco - No
Physical activity - Active

Family history

Hypertension - mother
Coronary artery disease - none
Cancer - None

PHYSICAL EXAMINATION

General

General appearance - normal
Build - normal
Height - 162
Weight - 67.1
BMI - 25.57
Pallor - No
Oedema - no
Temperature - 97
SpO2 - 98



H Swaminarayan Nagar, Off Mumbai-Agra Highway,
Panchvati, Nashik - 422 003.

+91- 253 - 2510250 / 350 / 450 / 550 / 750

apollonashik@apollohospitals.com

www.askapollo.com

QFAHN/BILL/003/V1



Name : Mr. MAHESH RAMESH THUBE (35 /M)

UHID : MHN1.0000127853

Date : 08/11/2022

Package : MediWheel Full Body Health Checkup Male Below 40 Package

AHC No : NSKAH28203



Cardiovascular system

Heart rate (Per minute) - 85
Rhythm - Regular
- B.P. Supine
Systolic(mm of Hg) - 110
Diastolic(mm of Hg) - 70
Heart sounds - S1S2+

Respiratory system

Breath sounds - Normal vesicular breath sounds



Abdomen

Organomegaly - No
Tenderness - No





H Swaminarayan Nagar, Off Mumbai-Agra Highway,
Panchvati, Nashik - 422 003.

+91- 253 - 2510250 / 350 / 450 / 550 / 750

apollonashik@apollohospitals.com

www.askapollo.com

QFAHN/BILL/003/V1



Name : Mr. MAHESH RAMESH THUBE (35 /M)

UHID : MHN1.0000127853

Date : 08/11/2022

Package : MediWheel Full Body Health Checkup Male Below 40 Package

AHC No : NSKAH28203

C B C WITH ESR (AUTOMATION + STANDARD METHOD)

Test Name	Result	Unit	Level	Range
Hemoglobin	16.5	g/dl	●	13.0-18.0
Haematocrit	51.3	%	●	39.0-54.0
RBC COUNT	5.7	Million/ ul	●	4.2-6.5
MCV	90.5	fl	●	75.0-95.0
MCH	29.2	pg	●	26.0-32.0
MCHC	32.2	g/dl	●	31.0-36.0
W	15	%	●	11-16
Platelet Count(Optical/Impedance)	302	10 ³ /m m ³	●	140-440
TLC Count	5.8	10 ³ /m m ³	●	4.0-11.0
Neutrophils	49	%	●	45-75
Lymphocytes	40	%	●	20-45
Eosinophils	02	%	●	1-6
Monocytes	09	%	●	1-10
Basophils	00	%	●	0-1
ERYTHROCYTE SEDIMENTATION RATE (ESR)	2.1	mm/1st hr	●	0-10

ALBUMIN:GLOBULIN - 1.3 ● 1.1-1.8
SERUM(RATIO)
(Calculated)

ALKALINE 54 U/L ● 0-100
PHOSPHATASE -
SERUM/PLASMA

AST (SGOT) - SERUM 40 * U/L ● 15-37

BILIRUBIN, TOTAL - 1.4 * mg/dL ● 0.0-1.0
SERUM

LIPID PROFILE TEST (PACKAGE)

Test Name	Result	Unit	Level	Range
Total Cholesterol	168	mg/dL	●	0-200

CREATININE - SERUM / PLASMA

Test Name	Result	Unit	Level	Range
CREATININE - SERUM / PLASMA	0.8	mg/dL	●	0.8-1.3

LIVER FUNCTION TEST (PACKAGE)

Test Name	Result	Unit	Level	Range
GGTP: GAMMA GLUTAMYL TRANSPEPTIDASE - SERUM	66 *	U/L	●	0-50

BLOOD GROUPING AND TYPING (ABO and Rh)

Test Name	Result	Unit	Level	Range
ABO Group:	A			
Rh (D) Type:	POSITIVE			

GLUCOSE - SERUM / PLASMA (FASTING)

Test Name	Result	Unit	Level	Range
Glucose - Plasma (Fasting)	110 *	mg/dL	●	70-100

URINE Sample not received
GLUCOSE(FASTING):
(Strip Method)

LIVER FUNCTION TEST (PACKAGE)

Test Name	Result	Unit	Level	Range
ALT(SGPT) - SERUM / PLASMA	76 *	U/L	●	30-65
ALBUMIN - SERUM	4.4	g/dL	●	3.5-5
GLOBULIN - SERUM: (Calculated)	3.4	g/dL	●	1.8-3.6

GLUCOSE - SERUM / PLASMA (POST PRANDIAL)

Test Name	Result	Unit	Level	Range
Glucose - Plasma (POST PRANDIAL)	99	mg/dL	●	70-140

● Within Normal Range ● Borderline High/Low ● Out of Range



H Swaminarayan Nagar, Off Mumbai-Agra Highway,
Panchvati, Nashik - 422 003.

+91- 253 - 2510250 / 350 / 450 / 550 / 750

apollonashik@apollohospitals.com

www.askapollo.com

QFAHN/BILL/003/V1



Name : Mr. MAHESH RAMESH THUBE (35 /M)

UHID : MHN1.0000127853

Date : 08/11/2022

Package : MediWheel Full Body Health Checkup Male Below 40 Package

AHC No : NSKAH28203

URINE	Nil	Test Name	Result	Unit	Level	Range
GLUCOSE(POST PRANDIAL):(Strip Method)		URIC ACID - SERUM	7.0	mg/dL	●	3.5-7.2

LIPID PROFILE TEST (PACKAGE)

Test Name	Result	Unit	Level	Range
HDL CHOLESTEROL - SERUM / PLASMA	52	mg/dL	●	40-60
TOTAL CHOLESTEROL/HDL CHOLESTEROL (Calculated)	3.2		●	0.0-4.5
LDL Cholesterol (Direct LDL)	120	mg/dL	●	

LIVER FUNCTION TEST (PACKAGE)

Test Name	Result	Unit	Level	Range
BILIRUBIN CONJUGATED (DIRECT) - SERUM	0.4 *	mg/dL	●	0.0-0.3
BILIRUBIN UNCONJUGATED - SERUM(Calculated)	1.0 *	mg/dL	●	0.0-0.7

CARDIAC STRESS TEST - (TMT)

ECG

ULTRASOUND - WHOLE ABDOMEN

Grade I fatty infiltration of liver.
A simple right renal cortical cyst.
Significant postvoid residue.

LIVER FUNCTION TEST (PACKAGE)

Test Name	Result	Unit	Level	Range
PROTEIN, TOTAL - SERUM / PLASMA	7.8	g/dL	●	6.4-8.2
PROTEIN, TOTAL - SERUM / PLASMA	7.8	g/dL	●	6.4-8.2

X-RAY CHEST PA

No significant abnormality is detected.

THYROID PROFILE - I(T3,T4 AND TSH)

Test Name	Result	Unit	Level	Range
TOTAL T3: TRI IODOTHYRONINE - SERUM	134	ng/dL	●	Healthy Adults: 69 - 215
TOTAL T4: THYROXINE - SERUM	11.1	µg/dL	●	Healthy Adults:5.2-12.7

INVESTIGATIONS NOT DONE / NOT YET REPORTED / NOT PART OF PACKAGE(LAB,RADIOLOGY & CARDIOLOGY)

Haematology

STOOL ROUTINE

LIPID PROFILE TEST (PACKAGE)

Test Name	Result	Unit	Level	Range
Triglycerides - Serum	61	mg/dL	●	0-150

THYROID PROFILE - I(T3,T4 AND TSH)

Test Name	Result	Unit	Level	Range
TSH: THYROID STIMULATING HORMONE - SERUM	2.9	uIU/mL	●	Euthyroid: 0.3 - 4.5 Hypothyroid: 7.1 - >75

URIC ACID - SERUM

● Within Normal Range ● Borderline High/Low ● Out of Range



H Swaminarayan Nagar, Off Mumbai-Agra Highway,
Panchvati, Nashik - 422 003.

+91- 253 - 2510250 / 350 / 450 / 550 / 750

apollonashik@apollohospitals.com

www.askapollo.com

QFAHN/BILL/003/V1



Name : Mr. MAHESH RAMESH THUBE (35 /M)

UHID : MHN1.0000127853

Date : 08/11/2022

Package : MediWheel Full Body Health Checkup Male Below 40 Package

AHC No : NSKAH28203

Printed By :

AHC Physician / Consultant Internal Medicine



Note :- The Health Check-up examinations and routine investigations have certain limitations and may not be able to detect all the diseases. Any new or persisting symptoms should be brought to the attention of the Consulting Physician. Additional tests, consultations and follow up may be required in some cases.

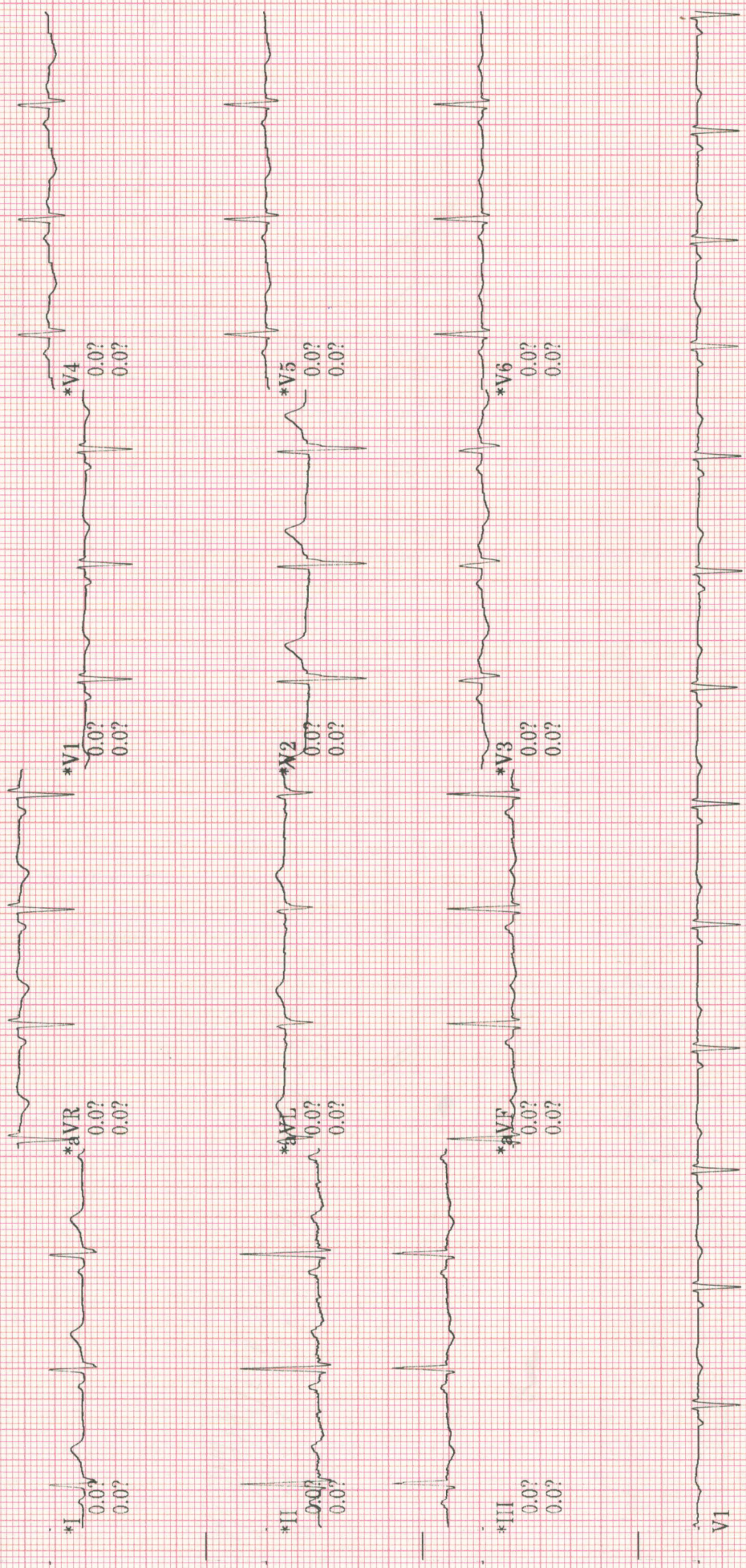
ID: 000127853
Visit:
8-Nov-2022
10:58:59

79bpm
BP: 110/80
ST @ 10mm/mV
80ms postJ

BRUCE
** *mph
** *%

PRETEST
SUPINE
0:30

Lead
ST(mm)
Slope(mV/s)



Raw Rhythm

40 Hz 25.0 mm/s 10.0 mm/mV A H S 50Hz HR 46

* Computer Synthesized Rhythm

MAC55 010B



Swaminarayan Nagar, Off Mumbai-Agra Highway,
Panchvati, Nashik - 422 003.
+91- 253 - 2510250 / 350 / 450 / 550 / 750
apollonashik@apollohospitals.com
www.askapollo.com

QFAHN/BILL/003/V1



MD (Radiology)

Patient Details : Mr. MAHESH RAMESH THUBE | Male | 35Yr 0Mth 0Days

UHID : MHN1.0000127853

Patient Location: AHC

Patient Identifier: NSKAH28203



DRN : 122043866

Completed on : 08-NOV-2022 10:50

Ref Doctor : Dr. Rajashri Dhongade

X-RAY CHEST PA

Both lung fields are clear.

Both hila are normal in size and position.

Costophrenic and cardiophrenic angles are clear.

Cardiac size and contour are within normal limits.

Rib cage is normal.

Soft tissues are normal.

Impression

No significant abnormality is detected.

--- END OF THE REPORT ---

Kunal Kalyanrao Patil

Consultant - MD (Radiodiagnosis)



H Swaminarayan Nagar, Off Mumbai-Agra Highway,
Panchvati, Nashik - 422 003.

+91- 253 - 2510250 / 350 / 450 / 550 / 750

apollonashik@apollohospitals.com

www.askapollo.com

QFAHN/BILL/003/V1



Apollo
HOSPITALS
NASHIK

MD (Radiology)

Patient Details : Mr. MAHESH RAMESH THUBE | Male | 35Yr 0Mth 0Days

UHID : MHN1.0000127853

Patient Location: AHC

Patient Identifier: NSKAH28203



DRN : 222027027

Completed on : 08-NOV-2022 11:36

Ref Doctor : Dr. Rajashri Dhongade

ULTRASOUND - WHOLE ABDOMEN

LIVER : Normal in size. Diffuse increase in echogenicity of the liver parenchyma is suggestive of fatty infiltration.

No I.H.B.D./ focal lesions.

PORTAL VEIN: Normal in size.

GALL BLADDER: Well distended with normal walls and lumen.

No calculi/pericholecystic fluid.

COMMON BILE DUCT: Normal in size.

PANCREAS : Visualized portion of head and body of pancreas appears normal in size and echotexture. Rest of the pancreas is obscured due to bowel gases.

AORTA, IVC and para aortic areas are normal.

SPLEEN : Normal in size and echotexture.

KIDNEYS: Both kidneys are normal in site, size and echotexture.

No evidence of calculi/ hydronephrosis.

Right kidney measures: 11.2 x 5.0 cm.

A cortical cyst of size 3.9 x 2.1 cm is seen in the posterior cortex of the mid pole of the right kidney.

Left kidney measures : 10.6 x 5.3 cm.

Extra renal pelvis is seen on the left.

URINARY BLADDER: Well distended with normal walls.

No evidence of calculi/ growth/ diverticula .



H Swaminarayan Nagar, Off Mumbai-Agra Highway,
Panchvati, Nashik - 422 003.

+91- 253 - 2510250 / 350 / 450 / 550 / 750

apollonashik@apollohospitals.com

www.askapollo.com

QFAHN/BILL/003/V1



Apollo
HOSPITALS
NASHIK

Mr. MAHESH RAMESH THUBE

MHN1.0000127853

NSKAH28203

ULTRASOUND - WHOLE ABDOMEN

Prevoid urine volume = 374cc.

Post void residual urine = 75cc.

PROSTATE : Normal in size with homogenous echogenicity. No evidence of calcification within.

Prostate measures : 21.4gms.

Seminal vesicles are normal.

Visualized bowel loops appear grossly normal.


No evidence of any free fluid in the peritoneal cavity.

Impression

Grade I fatty infiltration of liver.

A simple right renal cortical cyst.

Significant postvoid residue.



Kunal Kalyanrao Patil

Consultant - MD (Radiodiagnosis)



H Swaminarayan Nagar, Off Mumbai-Agra Highway,
Panchvati, Nashik - 422 003.

+91- 253 - 2510250 / 350 / 450 / 550 / 750

apollonashik@apollohospitals.com

www.askapollo.com

QFAHN/BILL/003/V1



For

8/11/22

Mahesh Thube

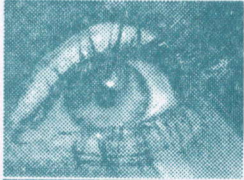
Stains

+	+
+	+

Actw- scaling.



1
EP



OPHTHALMOLOGY



Name : Mr. Mahesh Thube Date 8/11/22 UNIT _____
 Occupation : _____ Room No. _____ Out Patient
 Age : 35 Sex : Male Female S/M/W/D _____
 Address : NSK Ref. Physician : _____
 Tel. No. _____ Copies to : _____

REPORT ON OPHTHALMIC EXAMINATION

HISTORY : - H/O kidney stone operated by back.

PRESENT COMPLAINT : -

PAST HISTORY : DM / HTN / ALLERGY

ON EXAMINATION

VISION :

RE
6/6

LE
6/6

	RIGHT				LEFT			
PGP	SPH	CYL	AXIS	VA	SPH	CYL	AXIS	VA
DIST	<u>L</u>	<u>-</u>	<u>-</u>	<u>6/6</u>	<u>-</u>	<u>-</u>	<u>-</u>	<u>6/6</u>
NEAR	<u>-</u>	<u>-</u>	<u>-</u>	<u>-</u>	<u>-</u>	<u>-</u>	<u>-</u>	<u>-</u>

REFRACTION / Retinoscopy :

	RIGHT			LEFT		
	SPH	CYL	AXIS	SPH	CYL	AXIS
	<u>L</u>	<u>-</u>	<u>-</u>	<u>L</u>	<u>-</u>	<u>-</u>

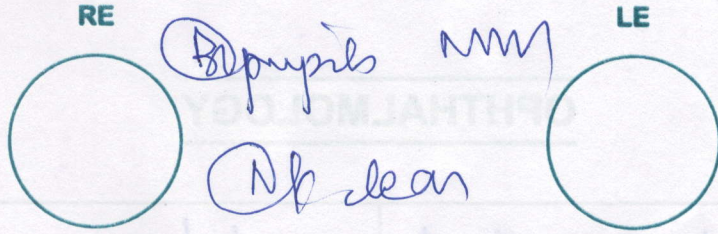
Refraction or Acceptance :

	RIGHT				LEFT			
	SPH	CYL	AXIS	VA	SPH	CYL	AXIS	VA
DIST	<u>L</u>	<u>-</u>	<u>-</u>	<u>6/6</u>	<u>L</u>	<u>-</u>	<u>-</u>	<u>6/6</u>
NEAR	<u>-</u>	<u>-</u>	<u>-</u>	<u>6/6</u>	<u>-</u>	<u>-</u>	<u>-</u>	<u>6/6</u>


OK

CONSULTANT OPTOMETRIST

Anterior Segment :



Fundus :




Diagnosis :

PCP	SPT	CYL	AXIS	VA	PCP	SPT	CYL	AXIS	VA

Advise / Rx:

Prescription for both eyes



PCP	SPT	CYL	AXIS	VA	PCP	SPT	CYL	AXIS	VA

CONSULTANT OPHTHALMOLOGIST

THUBE, MAHESH

TABULAR SUMMARY REPORT

ID: 000127853

Visit:

35years

Asian

Male

BRUCE

Max HR: 171bpm 97% of max predicted 175bpm

Max BP: 130/80

Reason for Termination: Max HR attained

Comments:

Total Exercise time: 7:13

8.8METS

25.0 mm/s

10.0 mm/mV

100hz

Referred by:
Test ind:

Phase Name	Stage Name	Time in Stage	Speed (mph)	Grade (%)	WorkLoad (METS)	HR (bpm)	BP (mmHg)	RPP (x100)
PRETEST	SUPINE	0:37	**.*	**.*	1.0	87	110/80	96
	STANDING	0:21	**.*	**.*	1.0	85	110/80	94
	HYPERVENT	0:05	0.3	0.0	1.0	87	110/80	96
EXERCISE	STAGE 1	3:00	1.7	10.0	4.6	122	110/80	134
	STAGE 2	3:00	2.5	12.0	7.0	149	120/80	179
	STAGE 3	1:13	3.4	14.0	8.8	171	130/80	222
RECOVERY	Post	3:03	**.*	**.*	1.0	121	130/80	157

Bardine ECG ST-T change

TMT Mild positive / Bardine fws11

[Non-specific]

Technician: MEGHA

APOLLO HOSPITAL NASIK

Unconfirmed

MAC55 010B