



DEPARTMENT OF PATHOLOGY

Patient Name : Mrs. ARTI KUMARI

MR No : 30545

Age/Sex : 34 Years 4 Months 22 Days / Female

Type : OPD

TPA/Corporate : MEDIWHEEL

Bill Date : 23/03/2024

Reporting Date : 23/03/2024

Sample ID : 74125

Bill/Req. No. : 24097463

Ref Doctor : Dr.CONSULTANT

Test	Result	Bio. Ref. Interval	Units
BLOOD SUGAR 2 HR. PP			
BLOOD SUGAR P.P.	89.62	80 - 150	mg/dl

***** END OF THE REPORT *****



Sample no.

Dr.VIGYAN MISHRA
CONS.PATHOLOGIST

Dr. VAISHALI YADAV Dr.REETU JADHAV Dr. PARDIP KUMAR S.C.GAUR
CONS.PATHOLOGIST CONS.PATHOLOGIST MICROBIOLOGIST & ICO LAB INCHARGE USER'NM SEHDEV

(This is only professional opinion and not the diagnosis, Please correlate clinically)

J-Block, Sector-10, Near Court, Faridabad - 121004, Haryana

Tel.: 0129-4200000 E-mail : parkfaridabad@gmail.com



DEPARTMENT OF PATHOLOGY

Patient Name : Mrs. ARTI KUMARI
 MR No : 30545
 Age/Sex : 34 Years 4 Months 22 Days / Female
 Type : OPD
 TPA/Corporate : MEDIWHEEL

Bill Date : 23/03/2024
 Reporting Date : 23/03/2024
 Sample ID : 74125
 Bill/Req. No. : 24097463
 Ref Doctor : Dr. CONSULTANT

Test	Result	Bio. Ref. Interval	Units
CBC			
HAEMOGLOBIN	9.4 L	12 - 15	gm/dL
PACKED CELL VOLUME	33.9 L	35.0 - 50.0	%
RED BLOOD CELL COUNT	3.78	3.5 - 5.5	millions/ μ L
MEAN CORPUSCULAR VOLUME	91.0	83 - 101	fL
MEAN CORPUSCULAR HAEMOGLOBIN	25.2 L	27 - 31	pg
MEAN CORPUSCULAR HB CONC	27.7 L	33 - 37	g/dl
RDW	13.1	11.6 - 14.5	%
TOTAL LEUCOCYTE COUNT	6630	4000-11000	/ μ L
DIFFERENTIAL COUNT			
NEUTROPHILS	68	40.0 - 80.0	%
LYMPHOCYTES	25	20 - 40	%
MONOCYTES	05	2.0 - 10.0	%
EOSINOPHILS	02	0.0 - 5.0	%
BASOPHILS	00	0.0 - 2.0	%
PLATELET COUNT	2.67	1.50 - 4.50	lac/cumm

***** END OF THE REPORT *****



Sample no.

Dr. VIGYAN MISHRA
 CONS. PATHOLOGIST

Dr. VAISHALI YADAV
 CONS. PATHOLOGIST

Dr. REETU JADHAV
 CONS. PATHOLOGIST

Dr. PARDIP KUMAR
 MICROBIOLOGIST & ICO

S.C. GAUR

LAB INCHARGE USER NM SEHDEV

(This is only professional opinion and not the diagnosis, Please correlate clinically)

J-Block, Sector-10, Near Court, Faridabad - 121004, Harvana
 Tel.: 0129-4200000



DEPARTMENT OF PATHOLOGY

Patient Name : Mrs. ARTI KUMARI
MR No : 30545
Age/Sex : 34 Years 4 Months 22 Days / Female
Type : OPD
TPA/Corporate : MEDIWHEEL
Bill Date : 23/03/2024
Reporting Date : 23/03/2024
Sample ID : 74125
Bill/Req. No. : 24097463
Ref Doctor : Dr.CONSULTANT

Test	Result	Bio. Ref. Interval	Units
------	--------	--------------------	-------

BLOOD GROUPING AND rh FACTOR

BLOOD GROUP	" O " Rh POSITIVE		
-------------	-------------------	--	--

***** END OF THE REPORT *****



Sample no.

Dr.VIGYAN MISHRA
CONS.PATHOLOGIST

Dr. VAISHALI YADAV Dr.REETU JADHAV Dr. PARDIP KUMAR S.C.GAUR
CONS.PATHOLOGIST CONS.PATHOLOGIST MICROBIOLOGIST & ICO LAB INCHARGE USER NM SEHDEV

(This is only professional opinion and not the diagnosis, Please correlate clinically)

J-Block, Sector-10, Near Court, Faridabad - 121004, Haryana

Tel.: 0129-4200000 E-mail : parkfaridabad@gmail.com



DEPARTMENT OF PATHOLOGY

Patient Name : Mrs. ARTI KUMARI
MR No : 30545
Age/Sex : 34 Years.4 Months 22 Days / Female
Type : OPD
TPA/Corporate : MEDIWHEEL

Bill Date : 23/03/2024
Reporting Date : 23/03/2024
Sample ID : 74125
Bill/Req. No. : 24097463
Ref Doctor : Dr.CONULTANT

Test	Result	Bio. Ref. Interval	Units
LIPID PROFILE			
LIPID PROFILE			
TOTAL CHOLESTEROL	140.47	120.0 - 200.0	mg/dL
SERUM TRIGLYCERIDES	52.53	40.0 - 160.0	mg/dl
HDL-CHOLESTEROL	44.21	30 - 70	mg/dl
VLDL CHOLESTEROL	10.51	6 - 32	mg/dL
LDL	85.75	50 - 135	mg/dl
LDL CHOLESTEROL/HDL RATIO	1.94	1.0 - 3.0	mg/dL
TOTAL CHOLESTEROL/HDL RATIO	3.18	2.0 - 5.0	mg/dl

***** END OF THE REPORT *****



Sample no.

Dr.VIGYAN MISHRA
CONS.PATHOLOGIST

Dr. VAISHALI JADAV Dr.REETU JADHAV Dr. PARDIP KUMAR S.C.GAUR
CONS.PATHOLOGIST CONS.PATHOLOGIST MICROBIOLOGIST & ICO LAB INCHARGE USER NM SEHDEV

(This is only professional opinion and not the diagnosis, Please correlate clinically)



DEPARTMENT OF PATHOLOGY

Patient Name : Mrs. ARTI KUMARI
MR No : 30545
Age/Sex : 34 Years 4 Months 22 Days / Female
Type : OPD
TPA/Corporate : MEDIWHEEL

Bill Date : 23/03/2024
Reporting Date : 23/03/2024
Sample ID : 74125
Bill/Req. No. : 24097463
Ref Doctor : Dr.CONULTANT

Test	Result	Bio. Ref. Interval	Units
KFT (RENAL PROFILE)			
KFT			
SERUM UREA	18.3	10 - 45	mg/dL
SERUM CREATININE	0.63	0.4 - 1.4	mg/dL
SERUM URIC ACID	3.7	2.5 - 7.0	mg/dL
SERUM SODIUM	136.5	136 - 148	mmol/L
SERUM POTASSIUM	3.6	3.5 - 5.5	mmol/L
CHLORIDE	96.0	96 - 106	mmol/L

***** END OF THE REPORT *****



Sample no.

Dr.VIGYAN MISHRA
CONS.PATHOLOGIST

Dr. VAISHALI YADAV Dr.REETU JADHAV Dr. PARDIP KUMAR S.C.GAUR
CONS.PATHOLOGIST CONS.PATHOLOGIST MICROBIOLOGIST & ICO LAB INCHARGE USER NM SEHDEV

This is only professional opinion and not the diagnosis, Please correlate clinically)



DEPARTMENT OF PATHOLOGY

Patient Name : Mrs. ARTI KUMARI
 MR No : 30545
 Age/Sex : 34 Years 4 Months 22 Days / Female
 Type : OPD
 TPA/Corporate : MEDIWHEEL
 Bill Date : 23/03/2024
 Reporting Date : 23/03/2024
 Sample ID : 74125
 Bill/Req. No. : 24097463
 Ref Doctor : Dr.CONSULTANT

Test	Result	Bio. Ref. Interval	Units
LFT (LIVER FUNCTION TEST)			
LFT			
TOTAL BILIRUBIN	0.6	0 - 1.2	mg/dL
DIRECT BILIRUBIN	0.2	0 - 0.4	mg/dL
INDIRECT BILIRUBIN	0.4	0.10 - 0.6	mg/dL
SGOT (AST)	16.3	0 - 45	U/L
SGPT (ALT)	20.1	0 - 45	U/L
ALKALINE PHOSPHATASE	100.7	30 - 170	IU/L
TOTAL PROTEIN	6.6	6.4 - 8.0	g/dL
ALBUMIN	3.7	3.3 - 5.5	g/dL
GLOBULIN	2.9	2.3 - 4.5	g/dL
A/G RATIO	1.28	1.1 - 2.2	

***** END OF THE REPORT *****



Sample no.

Dr.VIGYAN MISHRA
CONS.PATHOLOGIST

Dr. VAISHALI YADAV Dr.REETU JADHAV Dr. PARDIP KUMAR S.C.GAUR
 CONS.PATHOLOGIST CONS.PATHOLOGIST MICROBIOLOGIST & ICO LAB INCHARGE USER NM SEHDEV

(This is only professional opinion and not the diagnosis, Please correlate clinically)

J-Block, Sector-10, Near Court, Faridabad - 121004, Haryana

Tel.: 0129-4200000 E-mail : parkfaridabad@gmail.com



DEPARTMENT OF PATHOLOGY

Patient Name :	Mrs. ARTI KUMARI	Bill Date :	23/03/2024
MR No :	30545	Reporting Date :	23/03/2024
Age/Sex :	34 Years 4 Months 22 Days / Female	Sample ID :	74125
Type :	OPD	Bill/Req. No. :	24097463
TPA/Corporate :	MEDIWHEEL	Ref Doctor :	Dr.CONSULTANT

Test	Result	Bio. Ref. Interval	Units
BLOOD SUGAR FASTING			
PLASMA GLUCOSE FASTING	80.16	60 - 110	mg/dl

***** END OF THE REPORT *****



Sample no.

Dr.VIGYAN MISHRA
CONS.PATHOLOGIST

Dr. VAISHALI YADAV Dr.REETU JADHAV Dr. PARDIP KUMAR S.C.GAUR
CONS.PATHOLOGIST CONS.PATHOLOGIST MICROBIOLOGIST & ICO LAB INCHARGE USER NM SEHDEV

(This is only professional opinion and not the diagnosis, Please correlate clinically)

J-Block, Sector-10, Near Court, Faridabad - 121004, Haryana
Tel.: 0129-4200000 E-mail : parkfaridabad@gmail.com



DEPARTMENT OF PATHOLOGY

Patient Name : Mrs. ARTI KUMARI

MR No : 30545

Age/Sex : 34 Years 4 Months 22 Days / Female

Type : OPD

TPA/Corporate : MEDIWHEEL

Bill Date : 23/03/2024

Reporting Date : 23/03/2024

Sample ID : 74125

Bill/Req. No. : 24097463

Ref Doctor : Dr.CONSULTANT

Test	Result	Bio. Ref. Interval	Units
------	--------	--------------------	-------

URINE ROUTINE AND MICROSCOPY

PHYSICAL CHARACTERSTICS

QUANTITY	30.0 ML	5 - 100	ML
COLOUR	Pale Yellow		
TURBIDITY	Clear	clear	
SPECIFIC GRAVITY	1.000	1.003 - 1.030	
PH	6.5	Acidic	

CHEMICAL EXAMINATION-1

URINE PROTEIN	NIL	NIL	
GLUCOSE	NIL	NIL	

MICRO.EXAMINATION

PUS CELL	0 - 1/HPF		CELLS/HPF
RED BLOOD CELLS	Nil	0-2	CELLS/HPF
EPITHELIAL CELLS	1-2/HPF	0-5	CELLS/HPF
CASTS	NIL	NIL	CELLS/HPF
CRYSTALS	NIL	NIL	CELLS/HPF
OTHER	NIL		

***** END OF THE REPORT *****



Sample no.

Dr.VIGYAN MISHRA
CONS.PATHOLOGIST

Dr. VAISHALI YADAV Dr.REETU JADHAV Dr. PARDIP KUMAR S.C.GAUR
CONS.PATHOLOGIST CONS.PATHOLOGIST MICROBIOLOGIST & ICO LAB INCHARGE USER NM SEHDEV

(This is only professional opinion and not the diagnosis, Please correlate clinically)

J-Block, Sector-10, Near Court, Faridabad - 121004, Haryana

Tel.: 0129-4200000 E-mail : parkfaridabad@gmail.com



DEPARTMENT OF PATHOLOGY

Patient Name : Mrs. ARTI KUMARI	Bill Date : 23/03/2024
MR No : 30545	Reporting Date : 23/03/2024
Age/Sex : 34 Years 4 Months 22 Days / Female	Sample ID : 74125
Type : OPD	Bill/Req. No. : 24097463
TPA/Corporate : MEDIWHEEL	Ref Doctor : Dr.CONSULTANT

Test	Result	Bio. Ref. Interval	Units
HB A1C GLYCOSYLATED HAEMOGLOBIN			
HBA1C	5.0		%

Note : Non-Diabetics 4.0 - 6.0 %

In Diabetics
 Good Control 6.1 - 6.8 %
 Fair Control 6.9 - 7.6 %
 Poor Control > 7.6 %

***** END OF THE REPORT *****

OUT SOURCE
PARK HOSPITAL



Sample no.

Dr.VIGYAN MISHRA
CONS.PATHOLOGIST

Dr. VAISHALI YADAV Dr.REETU JADHAV Dr. PARDIP KUMAR S.C.GAUR
 CONS.PATHOLOGIST CONS.PATHOLOGIST MICROBIOLOGIST & ICO LAB INCHARGE USER NM SUNIL

(This is only professional opinion and not the diagnosis, Please correlate clinically)



DEPARTMENT OF PATHOLOGY

Patient Name : Mrs. ARTI KUMARI
MR No : 30545
Age/Sex : 34 Years 4 Months 22 Days / Female
Type : OPD
TPA/Corporate : MEDIWHEEL

Bill Date : 23/03/2024
Reporting Date : 24/03/2024
Sample ID : 74125
Bill/Req. No. : 24097463
Ref Doctor : Dr.CONSULTANT

Test	Result	Bio. Ref. Interval	Units
THYROID PROFILE			
TRI-iodothyronine (T3)	1.15	0.60 - 1.81	ng/ml
THYROXINE (T4)	8.7	5.01 - 12.45	µg/dL
THYROID STIMULATING HORMONE	1.10	0.5-5.50	µIU/ml

***** END OF THE REPORT *****

OUT SOURCE
PARK HOSPITAL
GGN



Sample no.

Dr.VIGYAN MISHRA
CONS.PATHOLOGIST

Dr. VAISHALI YADAV Dr.REETU JADHAV Dr. PARDIP KUMAR S.C.GAUR
CONS.PATHOLOGIST CONS.PATHOLOGIST MICROBIOLOGIST & ICO LAB INCHARGE USER NM SEHDEV

(This is only professional opinion and not the diagnosis, Please correlate clinically)

J-Block, Sector-10, Near Court, Faridabad - 121004, Haryana

Tel.: 0129-4200000 E-mail : parkfaridabad@gmail.com



ECHO REPORT

Name of the patient: Mrs: ARTI KUMARS Age: 34 Sex: Male Female

UHID No: 30545 IPD No: 24092463 Date: 23/02/2024

Refer By Doctor: DR. R. Arora

LVEF% 60%

2D ECHO

> Mitral Value Normal Pulmonary Value NI Pulm
> Artery NI
> Aortic avice NI Tricuspid valve NI

2D RWMA

> NO RWMA (Regional wall motion abnormality) at rest

COLD DOPPLER

> NO Significant Vavular stenosis / Regurgiation

COMMENTS AND SUMMARY

> All cardiac chambers of NI size and shape NO dilatation or hypertrophy.
> NO RWMA (Regional wall motion abnormality) at rest
> NO Cloth / Vegetation/ pericardial effusion
> LV 60% Systolic function
> NO Significant Vavular stenosis / Regurgiation

Final Impression

> EF at Rest 60%

COMMENTS 2DECHO & Color Doppler study with

Arora

Consultant Cardiology

Doctor Name : Dr.
Date :

Dr. Rakesh Kumar Arora
MBBS, MD, DM (Cardiology)
Signature :
Time :
Consultant - Cardiology
Park Hospital, Faridkot



DEPARTMENT OF RADIOLOGY

Patient Name	Mrs. ARTI KUMARI	Billed Date	: 23/03/2024	9.29 AM
Reg No	30545	Reported Date	: 23/03/2024	
Age/Sex	34 Years 4 Months 22Days / Female	Req. No.	: 24097463	
Type	OPD	Consultant Doctor	: Dr. CONSULTANT	

USG WHOLE ABDOMEN

LIVER : The liver is normal in size, shape and echotexture. IHBR is not dilated. **There are approx three well defined lobulated predominantly hyperechoic lesions with central hypoechoic areas in them are seen in left lobe adjacent to each other, largest of the lesion measures ~5.2x6.7x6.2cm. The lesions show flow on color doppler evaluation-----** Hepatic mass lesions ??hemangiomas. **ADV : TRIPLE PHASE CT ABDOMEN** for further evaluation

GALL BLADDER : The gall bladder is well distended. No evidence any calculus or mass seen. GB wall thickness with in normal limits. No evidence of pericholecystic fluid is seen. The common bile duct is normal.

SPLEEN :The spleen is normal in size and shape. Its echotexture is homogeneous. No evidence of focal lesion is noted.

PANCREAS :The pancreas is normal in size, shape, contours and echotexture.

BILATERAL KIDNEYS : The bilateral kidneys are normal in size and echotexture. Cortico-medullary differentiation is maintained. There is no evidence of obvious hydronephrosis seen. **A calculus of approx. size 4.5mm is seen in upper calyx of right kidney-----Right renal calculus.**

URINARY BLADDER :The urinary bladder is well distended. Wall thickness within normal limits. No evidence of calculus is seen. No evidence of mass or diverticulum is noted.

UTERUS: The uterus is gravid. **ADV : Review with proper documentation for early pregnancy along with ID proof**

No free fluid is seen in peritoneal cavity.

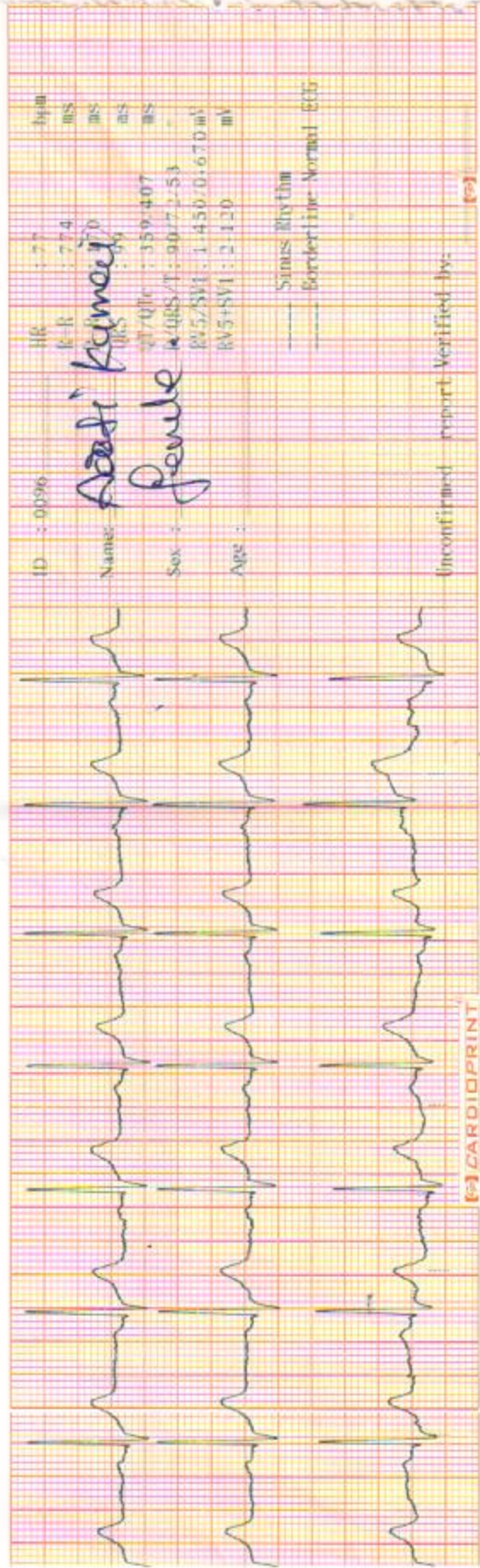
No evidence of obvious retroperitoneal or mesenteric lymphadenopathy is seen.

DR. BINOD KR CHAUDHARY
MBBS, MD
CONSULTANT RADIOLOGIST

(This is only professional opinion and not the diagnosis, Please correlate clinically)

J-Block, Sector-10, Near Court, Faridabad - 121004, Haryana

Tel : 0129-4200000 E-mail : parkfaridabad@gmail.com



ID : 00596
 Name: *Aarti Kameel*
 Sex : *Female*
 Age :

HR : 77
 PR : 168
 QRS : 90.7
 QT : 359.407

--- Sinus Rhythm
 - - - - - Borderline Normal ECG

Unconfirmed report Verified by: []

ECG CARDIOPRINT