



HEALTH CHECK-UP SUMMARY

Race Course Road, Vadodara

Name: VINITA GAUR	Date: 14/09/2024
SH No: 232342	Gender: FEMALE
Age: 44	

ASSESSMENT:

- OVER WEIGHT(BMI:26.31)
- K/C/O: CERVICAL SPONDYLOSIS,MIGRAINE
- C/O: SEVERE BACKACHE RADIATING TO LEGS,HEEL PAIN,INCREASE FINGER JOINT PAIN FEELING OF RIGHT LEG,FEELS LIKE INSIDE STETCHING ALONG WITH RIGHT HEEL PAIN,FEELING OF COUGH ALWAYS PRESENT INSIDE THROAT ,REDUCED APETITE,LATE NIGHT SLEEP, BIPARIETAL HEAVINESS OF HEAD, HEADACHE,IRREGULAR PERIODS SINCE 2-3 MONTHS
- F/H/O:DIABETES(MOTHER),ASTHMA(FATHER)
- OCCASIONAL ANXIETY PRESENT
- HEARTBURN AND FLATUS PRESENT
- OCCASIONAL VAGINAL DISCHARGE PRESENT
- BORDERLINE LOW HB(11.5), BORDERLINE LOW MCH(26.2), BORDERLINE LOW MCHC(31), BORDERLINE HIGH RDW CV(14.60)
- HIGH ESR(31)
- BORDERLINE HIGH HBA1C(5.80)
- BORDERLINE HIGH CHOLESTEROL(226),HIGH HDL CHOLESTEROL(71),BORDERLINE HIGH DIRECT LDL(134)
- LOW GGT(GAMMA GLUTAMYL; TRANSFERASE)(11),BORDERLINE HIGH ALKALINE PHOSPHATASE(132), LOW A/G RATIO(1.27)
- URINE R/M: HIGH SPECIFIC GRAVITY(1.030)
- 2D ECHO : GRADE 1 DIASTOLIC DYSFUNCTION, LVEF 60%
- PAP SMEAR-MILD ACUTE INFLAMMATION.
- :

ADVISED:

- PLENTY OF LIQUIDS
- ANTI DIABETIC, LOW FAT& IRON RICH DIET
- AVOID OUT SIDE FOOD AND WATER
- REGULAR EXERCISE .
- CORRECTION OF ANAEMIA AND WORK UP
- REGULAR BLOOD SUGAR MONITORING AND CONTROL
- REPEAT LIPID PROFILE AFTER 3 MONTH
- OPHTHALMOLOGIST ADVICE : FOLLOW ADVICE
- ORTHOPEDIC CONSULTATION
- ENT CONSULATION:
- GYNAC CONSULTATION
- PHYSICIAN CONSULTATION

Sterling Addlife India Limited  
Unit-Sterling Hospital Vadodara  
Race Course Circle, (West)  
VADODARA - 390 007.  
DR. JAY S PANDIT  
Prevention & Rehabilitation Dept

Hospital Address: Sterling Hospitals, Race Course Road, Opp. Inox Cinema Hari Nagar, Circle West, Vadodara – 390007, Gujarat, India | Call: 0265-6144111, 0265-2354455, 98 98 98 78 78 www.sterlinghospitals.com | info@sterlinghospitals.com

Registered Office: Sterling Addlife India Private Limited | CIN U85110GJ2000PTC039121 Sterling Hospital, Sterling Hospital Road, Memnagar, Ahmedabad-380052, Gujarat, India



**HEALTH CHECK UP  
MEDICAL EXAMINATION**

Name : Vinita Gaur. Employee ID : \_\_\_\_\_  
 Company Name : \_\_\_\_\_ Age : 49 Sex : ♀  
 Height : 152 cms. Weight : 60.8 Kgs BMI : 26.31 Blood Group : B+UP.  
 Name of HO / Registrar taking History : Dr. Jay's. Pandit

Allergies :  None  Yes (If Yes, describe)

Drugs/Food/Latex/Dyes/Contrast/Other .....	Reaction
1. <u>1</u>	<u>1</u>
2.	
3.	

Chief Complaints : Alone.  
old - Backache & radiating to legs.  
K/O - cervical & thoracic vertebrae  
increased. Heel pain (+). increased/jump joint

Physical Examination : bellies of knees & mild stretch 2 RT Heel  
 Vital Signs : K/O - migrant continuous motion itching pain mae.  
 Temp : 98 °F SPO<sub>2</sub> : \_\_\_\_\_ Pulse : 62 /min R/R : 18 /min B.P. : 130/70 mm Hg

**Past History :**

If Hypertension, since On Medication 1) _____ 2) _____ 3) _____	If Diabetes, since On Medication 1) _____ 2) _____ 3) _____
If Ischaemic Heart Disease since On Medication 1) _____ 2) _____ 3) _____	Under Treatment Dr. _____
Under Treatment of Dr. _____	If Tuberculosis, When _____
Any Intervention done _____	Any Other P/H _____ <u>Chondylax &amp; migon</u>
P/H of Operation Diagnosis : _____ Name of Operation : _____ Year of Operation : _____	Any Other Medication _____ <u>Chemical &amp; Sy. medic</u>
Others _____	P/H of Hospitalization _____ Diagnosis : _____ Year : _____ Duration : _____ Blood Transfusion History : Yes <input checked="" type="checkbox"/> No <input type="checkbox"/> Year : _____

**Family History :** (Specify : F-Father, M-Mother, B-Brother, S-Sister)

(Pl. Circle whichever is applicable e.g. If Father has h/o 10 yrs then, Yes / No F/10 yrs)

Hypertension	Yes/No (No)	Asthma	Yes/No (F)
Heart Disease	Yes/No (No)	Stroke	Yes/No (No)
Diabetes	Yes/No (M)	Arthritis/Gout	Yes/No (No)
Tuberculosis	Yes/No (No)	Cancer	Yes/No (No)
Epilepsy	Yes/No (No)	Other Chronic disease	Yes/No (No)

**Personal History :**

Diet	Veg	Smoking	Yes/No (No)	since ..... / ..... per day
Appetite	Reduce appetite	Alcohol	Yes/No (No)	since ..... / ..... (freq.)
Sleep	late night sleep	Drugs	Yes/No (No)	since ..... / ..... (freq.)
Micturition	regular	Tobacco	Yes/No (No)	since ..... / ..... (freq.)
Bowel Habits		Any other habit		

**FOR FEMALES :**

 Obstetric History : L.D. A.M.P. - 4/9/2024 92 PTA h2 1st child 9:15 AM  
 Abortion : - 2nd child 07:10 AM  
 Others : .....

**General Examination :**

- 
- Anemia
- 
- Cyanosis
- 
- Jaundice
- 
- Generalized Lymphadenopathy
- 
- Pedal oedema

**General Examination :**
**Head :**  NSF    Headache, Bipapital pressures of 115/80

Injuries (Specify if any) : .....

**Eyes :**  NSF    glasses for both vision, regular

- Vision :  Normal     Blurred     Double     Colour Blind
- Pupils :  Normal     Abnormal
- Other :  Inflammation     Pain     Itching     Discharge     No complaint

Remarks (if any) : .....

**Ears :**  NSF

- Deaf     Yes     No    • Pain     Yes     No    • Discharge     Yes     No
- Dizziness     Yes     No

**Nose :**  NSF

- Nosebleed     Yes     No    • Congestion     Yes     No    • Sinus problem     Yes     No

**Mouth :**  NSF

- Lesion     Yes     No
- Dental Hygiene     Good     Poor    Bleeding gums     Yes     No
- Sense of taste     Yes     No

**Throat/Neck :**  NSF

- Swollen glands  Yes  No
- Stiffness  Yes  No
- Dysphagia  Yes  No

**SYSTEMIC EXAMINATION**
**Neurological :**  NSF

- Headache  Yes  No
- Memory changes  Yes  No
- Dizziness  Yes  No
- Syncope  Yes  No
- Seizures  Yes  No
- Paralysis  Yes  No if yes  R  L
- Cooperative  Yes  No
- Anxiety  Yes  No
- Depression  Yes  No
- Suicidal attempt  Yes  No
- Any psychiatric illness No
- Oriented  Yes  No if disoriented, to  Person  Place  Time
- Reaction:  Brisk  Sluggish  No response
- LOC:  Alert  Confused  Sedated
- Speech:  Clear  Slurred

**Respiratory :**  NSF

- Lung sounds: AEB clear
- Dyspnoea:  None  With activity  At rest  Lying down  Retractions
- Cough:  None  Non-productive  Productive - colour white
- Hemoptysis:  Yes  No
- Night Sweats:  Yes  No
- Cyanosis:  Yes  No Where .....

**Cardiovascular :**  NSF

- Chest discomfort  Yes  No
- Oedema  Yes  No Location: .....  Pitting  Non-pitting

**Extremities-Musculoskeletal :**  NSF

- Skin:  Warm  Cool  Dry  Firm  Flaccid  Colour
- Extremities: Tingling  Yes  No Weakness  Yes  No Deformity  Yes  No
- Joints: Pain  Yes  No Stiffness  Yes  No
- Uses:  Walker  Wheelchair  None

**Gastrointestinal :**  NSF

- Appetite  Good  Poor
- Nausea  Yes  No
- Vomiting  Yes  No
- Distension  Yes  No
- Heartburn  Yes  No
- Flatus  Yes  No
- Pain  Yes  No
- Rectal Bleeding  Yes  No
- Colostomy  Yes  No
- Illeostomy  Yes  No

**Bowel**

- Diarrhoea  Constipation  Incontinence  Blood in stool  None
- Pain  Yes  No Place: .....
- Hemorrhoids  Yes  No
- Frequency of stool 2 times/day
- Interventions:  None  Laxatives  Yes  No Type: ..... Frequency: .....

**Genitorurinary :**
 NSF

Colour of Urine

Pale yellow

Frequency

4-5 times/day

Pain

 Yes  No

Burning

 Yes  No

Itching

 Yes  No

Urgency

 Yes  No

Incontinence

 Yes  No

Nocturia

 Yes  No

Urostomy

 Yes  No

History of calculi

 Yes  No

History of UTI

 Yes  No

Foleys Catheter

 Yes  No

Date of Insertion \_\_\_\_\_

**Reproductive :**
 NA

 NSF

LMP

4/9/24

Regular / Irregular

since 2-3 months

Dysmenorrhea

 Yes  No

Amenorrhea

 Yes  No

if yes, Duration \_\_\_\_\_

Menopausal

 Yes  No

if yes, Duration \_\_\_\_\_

Vaginal discharge

 Yes  No

Itching

 Yes  No

**Breasts**
 NA  NSF

Breast Feeding

 Yes  No

Lumps

 Yes  No

**Positive Finding & Advice**

.....

.....

.....

.....

Sterling Addlife India Limited  
 Unit-Sterling Hospital Vadodara  
 Race Course Circle, (West)  
 VADODARA - 390 007.

**Sign and Stamp of Medical Officer**
**Sterling Hospital**  
**Racecourse Road**
**EMERGENCY HELPLINE**
**992 444 9972**
**0265 - 61 44 111**
**Sterling Hospital**  
**Bhayli**
**EMERGENCY HELPLINE**
**908 1000 557**
**0265 - 61 23 333**



OPHTHALMIC CHECK-UP

SIGNIFICANT HISTORY:

PAST HISTORY:

Refractive Error:

Any Surgery:

Color Blind:

Diabetes:

Hypertension:

Any Treatment:

EXAMINATION OF EYES:

Right Eye:

Left Eye:

Distant Vision without Glasses:

Distant Vision with Glasses:

Near Vision without Glasses:

Near Vision with Glasses:

Intraocular Pressure:

Anterior Segment:

Fundus:

PRESCRIPTION OF GLASSES:

	RIGHT			LEFT		
	Sphere	Cylinder	Axis	Sphere	Cylinder	Axis
Distant	+0.75	—	—	+0.75	+0.5	180°
Near	+2.25	—	—	+2.25	+0.5	180°

Type of glass:

ADVICE:

**Sterling Addlife India Limited**  
 Unit-Sterling Hospital Vadodara  
 Race Course Circle, (West)  
**VADODARA - 390 007.**  
**DR MAYA PATEL**  
 (OPHTHALMOLOGIST)

**Hospital Address:** Sterling Hospitals, Race Course Road, Opp. Inox Cinema Hari Nagar, Circle West, Vadodara – 390007, Gujarat, India | Call: 0265-6144111, 0265-2354455, 98 98 98 78 78 | www.sterlinghospitals.com | info@sterlinghospitals.com

**Registered Office:** Sterling Addlife India Private Limited | CIN U85110GJ2000PTC039121 | Sterling Hospital, Sterling Hospital Road, Memnagar, Ahmedabad-380052, Gujarat, India





GYNAECOLOGIST CHECK UP

NAME: MRS Vinita Gaur

DATE: 14/9/24.

AGE: 44Y1F

ML - 18 year

COMPLAINTS: No any complaint

15 year old female  
10 year old male.

O/H PARA: G2P2A0L2

both born  $\pm$  Normal  
delivery.

MENSTRUAL H/O: LMP - 04/9/24

mc 30 days  
3-4 days

P/A: Soft

P/S: NAD

P/V: NAD

ADVICE: Pap Smear Taken.

  
Sterling Addlife India Limited  
Unit Sterling Hospital Vadodara  
Race Course Circle, (West)  
VADODARA - 390 007.

**DR. ARCHANA DWIVEDI**  
(GYNAECOLOGIST)



Passport No :

**LABORATORY TEST REPORT**


Patient Information	Sample Information	Location Information
Name : Mrs. Vinita . Gaur	Lab Id : 092407501402	Pt. Type : Sterling Hospital Vadodara Health Checkup
Sex/Age : Female / 44 Y 20-Jul-1980	Registration on : 14-Sep-2024 09:16	Location : Main BNo./
Ref. Id : 232342 / 2809833	Collected at : SAWPL	Approved on : 14-Sep-2024 12:15 Status : Final
Ref. By : Dr. RMO . STERLING...	Collected on : 14-Sep-2024 09:20	Printed On : 14-Sep-2024 16:32
	Sample Type : EDTA blood	Process At : 75 - Sterling Hospital, Race course (Vadodar

**MEDIWHEEL FULL BODY ANNUAL PLUS CHECK/ ADVANCE**
**Complete Blood Count**

Test	Result	Unit	Biological Ref. Interval
Hemoglobin Colorimetric	L 11.5	g/dL	12.0 - 16.0
RBC Count Electrical impedance	4.39	million/cmm	3.8 - 4.8
Hematocrit Calculated	37.1	%	36 - 48
MCV Derived	84.5	fL	83 - 101
MCH Calculated	L 26.2	pg	26.4 - 33.2
MCHC Calculated	L 31.0	g/dL	31.8 - 35.9
RDW CV Calculated	H 14.60	%	11.6 - 14

**Total WBC and Differential Count**

WBC count SF Cube cell analysis 5020 /cmm 4000 - 10000

**Differential Count**

Differential Count	Result	Unit	Absolute Count
Neutrophils Microscopic	52	% 40 - 80	2610 /cmm 2000 - 6700
Lymphocytes Microscopic	39	% 20 - 40	1958 /cmm 1000 - 3000
Eosinophils Microscopic	03	% 1 - 6	151 /cmm 20 - 500
Monocytes Microscopic	06	% 2 - 10	301 /cmm 200 - 1000
Basophils Microscopic	00	% 0 - 2	0 /cmm 0 - 100

**Platelet Count**

Platelet Count Electrical impedance 230000 /cmm 150000 - 410000

MPV Calculated 12.10 fL 7.5 - 10.3

Platelets Morphology Platelets are adequate on Smear


**Dr. C. Shrinivasan..**

 M.D ( Pathology ) [G-18341]  
Consultant Pathologist

Page 1 of 14

**Sterling Accuris Pathology Laboratory**

 Sterling Hospital, Opp. Inox Cinema, Race Course Circle (West), Vadodara - 390 007, tests marked with # are referred tests  
Ph: 0265-6144210

pathlab@sterlinghospitals.com | Website: www.sterlinghospitals.com / www.sterlingaccuris.com

This is an Electronically Authenticated Report.



Download Accuris App







Passport No :

**LABORATORY TEST REPORT**


Patient Information	Sample Information	Location Information
Name : <b>Mrs. Vinita . Gaur</b>	Lab Id : <b>092407501402</b>	Pt. Type : Sterling Hospital Vadodara Health Checkup
Sex/Age : <b>Female / 44 Y</b> 20-Jul-1980	Registration on : 14-Sep-2024 09:16	Location : Main BNo./
Ref. Id : 232342 / 2809833	Collected at : SAWPL	Approved on : 14-Sep-2024 12:15 Status : Final
Ref. By : Dr. RMO . STERLING...	Collected on : 14-Sep-2024 09:20	Printed On : 14-Sep-2024 16:32
	Sample Type : EDTA blood	Process At : 75 – Sterling Hospital, Race course (Vadodar

**MEDIWHEEL FULL BODY ANNUAL PLUS CHECK/ ADVANCE**
**Complete Blood Count**

Test	Result	Unit	Biological Ref. Interval
<b>Erythrocytes Sedimentation Rate</b>			
ESR <small>Capillary photometry</small>	H 31	mm/1hr	0 - 21

**Differential Count**
**Absolute Count**

**Dr. C. Shrinivasan..**

M.D ( Pathology )[G-18341]

Consultant Pathologist

Page 2 of 14


**Sterling Accuris Pathology Laboratory**

 Sterling Hospital, Opp. Inox Cinema, Race Course Circle (West), Vadodara - 390 007, tests marked with # are referred tests  
 Ph: 0265-6144210

pathlab@sterlinghospitals.com | Website: www.sterlinghospitals.com / www.sterlingaccuris.com

This is an Electronically Authenticated Report.



Download Accuris App



Passport No :

**LABORATORY TEST REPORT**


Patient Information	Sample Information	Location Information
Name : Mrs. Vinita . Gaur	Lab Id : 092407501402	Pt. Type : Sterling Hospital Vadodara Health Checkup
Sex/Age : Female / 44 Y 20-Jul-1980	Registration on : 14-Sep-2024 09:16	Location : Main BNo./
Ref. Id : 232342 / 2809833	Collected at : SAWPL	Approved on : 14-Sep-2024 12:19 Status : Final
Ref. By : Dr. RMO . STERLING...	Collected on : 14-Sep-2024 09:20	Printed On : 14-Sep-2024 16:32
	Sample Type : EDTA blood	Process At : 75 – Sterling Hospital, Race course (Vadodar

**MEDIWHEEL FULL BODY ANNUAL PLUS CHECK/ ADVANCE**
**Blood Group**

Test	Result	Unit	Biological Ref. Interval
ABO Type <i>Tube Agglutination</i>	"B"		
Rh (D) Type	Positive		

  
**Dr. C. Shrinivasan..**

 M.D ( Pathology )[G-18341]  
 Consultant Pathologist

Page 3 of 14


**Sterling Accuris Pathology Laboratory**

 Sterling Hospital, Opp. Inox Cinema, Race Course Circle (West), Vadodara - 390 007, tests marked with # are referred tests  
 Ph: 0265-6144210

pathlab@sterlinghospitals.com | Website: www.sterlinghospitals.com / www.sterlingaccuris.com

This is an Electronically Authenticated Report.



Download Accuris App



Passport No :

**LABORATORY TEST REPORT**


Patient Information	Sample Information	Location Information
Name : Mrs. Vinita . Gaur	Lab Id : 092407501402	Pt. Type : Sterling Hospital Vadodara Health Checkup
Sex/Age : Female / 44 Y 20-Jul-1980	Registration on : 14-Sep-2024 09:16	Location : Main BNo./
Ref. Id : 232342 / 2809833	Collected at : SAWPL	Approved on : 14-Sep-2024 11:40 Status : Final
Ref. By : Dr. RMO . STERLING...	Collected on : 14-Sep-2024 09:20	Printed On : 14-Sep-2024 16:32
	Sample Type : Serum, Urine	Process At : 75 – Sterling Hospital, Race course (Vadodar

**MEDIWHEEL FULL BODY ANNUAL PLUS CHECK/ ADVANCE**

Test	Result	Unit	Biological Ref. Interval
<b>Fasting Blood Glucose</b> <i>GOD-POD</i>	100.0	mg/dL	74 - 100
<b>Fasting Urine Glucose</b> <i>GOD-POD</i>	Absent		Absent
<b>Fasting Urine Ketone</b> <i>Nitroprusside</i>	Absent		Absent

	Fasting Blood Glucose*	Postprandial Blood Glucose #	Random Blood Glucose
Normal	< 100 mg/dL	< 140 mg/dL	< 140 mg/dL
Prediabetic	100 – 125 mg/dL	140 – 199 mg/dL	140 – 199 mg/dL
Diabetic	>/=126 mg/dL	>/= 200 mg/dl	>/= 200 mg/dl

\* Fasting is defined as no caloric intake for more than 8 hours

# The test should be performed as described by the WHO, using a glucose load containing the equivalent of 75 g anhydrous glucose dissolved in water.

**Criteria for Diagnosis of Diabetes:**

1. Fasting blood glucose (FPG)  $\geq$  126 mg/dL
2. Two-hour blood glucose (2-h OGTT) = 200 mg/dL
3. HbA1c values (A1c)  $\geq$  6.5%
4. Random plasma glucose  $\geq$  200 mg/dL

(With symptoms of hyperglycemia or hyperglycemic crisis)

In the absence of unequivocal hyperglycemia, diagnosis of DM using A1C, FPG or 2-h OGTT requires two abnormal test results from the same sample or in two separate samples.

**References:**

1. American diabetes association. Standards of medical care in diabetes 2024
2. National Library of Medicine – National Institute of Health (USA) – Diabetes Mellitus
3. World Health Organization – Factsheet on Diabetes – Prevention and treatment


**Dr. C. Shrinivasan..**

M.D ( Pathology ) [G-18341]

Consultant Pathologist

Page 4 of 14


**Sterling Accuris Pathology Laboratory**

 Sterling Hospital, Opp. Inox Cinema, Race Course Circle (West), Vadodara - 390 007. tests marked with # are referred tests  
Ph: 0265-6144210

pathlab@sterlinghospitals.com | Website: www.sterlinghospitals.com / www.sterlingaccuris.com

This is an Electronically Authenticated Report.



Download Accuris App



Passport No :

**LABORATORY TEST REPORT**


Patient Information	Sample Information	Location Information
Name : Mrs. Vinita . Gaur	Lab Id : 092407501402	Pt. Type : Sterling Hospital Vadodara Health Checkup
Sex/Age : Female / 44 Y 20-Jul-1980	Registration on : 14-Sep-2024 09:16	Location : Main BNo./
Ref. Id : 232342 / 2809833	Collected at : SAWPL	Approved on : 14-Sep-2024 16:19 Status : Final
Ref. By : Dr. RMO . STERLING...	Collected on : 14-Sep-2024 12:08	Printed On : 14-Sep-2024 16:32
	Sample Type : Fluoride	Process At : 75 – Sterling Hospital, Race course (Vadodar

**MEDIWHEEL FULL BODY ANNUAL PLUS CHECK/ ADVANCE**

Test	Result	Unit	Biological Ref. Interval
<b>Post-breakfast Blood Glucose</b> <i>GOD-POD</i>	107	mg/dL	70 - 140
<b>Post-breakfast Urine Glucose</b> <i>GOD-POD</i>	Absent		Absent
<b>Post Breakfast Urine Ketone</b> <i>Nitroprusside</i>	Absent		Absent


**Dr. C. Shrinivasan..**

 M.D ( Pathology )[G-18341]  
 Consultant Pathologist

Page 5 of 14

**Sterling Accuris Pathology Laboratory**

 Sterling Hospital, Opp. Inox Cinema, Race Course Circle (West), Vadodara - 390 007. tests marked with # are referred tests  
 Ph: 0265-6144210

 pathlab@sterlinghospitals.com | Website: www.sterlinghospitals.com / www.sterlingaccuris.com

This is an Electronically Authenticated Report.



Download Accuris App





Passport No :

**LABORATORY TEST REPORT**


Patient Information	Sample Information	Location Information
Name : Mrs. Vinita . Gaur	Lab Id : 092407501402	Pt. Type : Sterling Hospital Vadodara Health Checkup
Sex/Age : Female / 44 Y 20-Jul-1980	Registration on : 14-Sep-2024 09:16	Location : Main BNo./
Ref. Id : 232342 / 2809833	Collected at : SAWPL	Approved on : 14-Sep-2024 13:49 Status : Final
Ref. By : Dr. RMO . STERLING...	Collected on : 14-Sep-2024 09:20	Printed On : 14-Sep-2024 16:32
	Sample Type : EDTA blood	Process At : 75 – Sterling Hospital, Race course (Vadoda)

**MEDIWHEEL FULL BODY ANNUAL PLUS CHECK/ ADVANCE**
**HbA1c (Glycosylated Hemoglobin) by HPLC**

Test	Result	Unit	Biological Ref. Interval
HbA1c	H 5.80	%	For Screening: Diabetes: $\geq 6.5\%$ ; Pre-Diabetes: 5.7 - 6.4%; Non-Diabetes: $< 5.7\%$
Mean Blood Glucose	119.76	mg/dL	For Diabetic Patient: Poor Control : $> 7.0\%$ ; Good Control : 6.0-7.0%

**Description:**

- Total haemoglobin A1 c is continuously synthesized in the red blood cell through its 120 days life span. The concentration of HBA1c in the cell reflects the average blood glucose concentration it encounters.
- The level of HBA1c increases proportionately in patients with uncontrolled diabetes. It reflects the average blood glucose concentration over an extended time period and remains unaffected by short-term fluctuations in blood glucose levels.
- The measurement of HbA1c can serve as a convenient test for evaluating the adequacy of diabetic control and in preventing various diabetic complications. Because the average half life of a red blood cell is sixty days, HbA1c has been accepted as a measurement which reflects the mean daily blood glucose concentration, better than fasting blood glucose determination, and the degree of carbohydrate imbalance over the preceding two months.
- It may also provide a better index of control of the diabetic patient without resorting to glucose loading procedures.

**HbA1c assay Interferences:**

Erroneous values might be obtained from samples with abnormally elevated quantities of other Haemoglobins as a result of either their simultaneous elution with HbA1c (HbF) or differences in their glycation from that of HbA (HbS).

**Reference:** American diabetes association. Standards of medical care in diabetes 2024


**Dr. C. Shrinivasan..**

 M.D ( Pathology ) [G-18341]  
 Consultant Pathologist

Page 6 of 14

**Sterling Accuris Pathology Laboratory**

 Sterling Hospital, Opp. Inox Cinema, Race Course Circle (West), Vadodara - 390 007, tests marked with # are referred tests  
 Ph: 0265-6144210

pathlab@sterlinghospitals.com | Website: www.sterlinghospitals.com / www.sterlingaccuris.com

This is an Electronically Authenticated Report.



Download Accuris App





Bio-Rad

D-10

S/N: #DJ8G550303

Sample ID:

Injection date

Injection #: 10

Rack #: ---

DATE: 14/09/2024

TIME: 01:29 PM

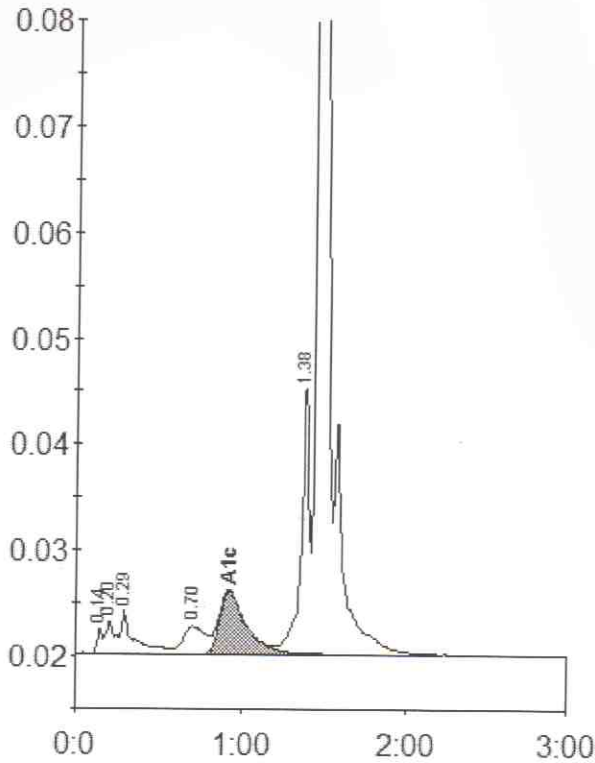
Software version: 4.30-2

092407501402

14/09/2024 01:29 PM

Method: HbA1c

Rack position: 4



Peak table - ID: 092407501402

Peak	R.time	Height	Area	Area %
Unknown	0.14	2336	5186	0.3
A1a	0.20	3059	8762	0.6
A1b	0.29	4095	25504	1.7
LA1c/CHb-1	0.70	2590	24407	1.6
A1c	0.93	5944	66265	5.8
P3	1.38	25284	91405	6.1
A0	1.45	472579	1268453	85.1
Total Area:		1489982		

Concentration:	%
A1c	5.8





Passport No :

**LABORATORY TEST REPORT**


Patient Information	Sample Information	Location Information
Name : Mrs. Vinita . Gaur	Lab Id : 092407501402	Pt. Type : Sterling Hospital Vadodara Health Checkup
Sex/Age : Female / 44 Y 20-Jul-1980	Registration on : 14-Sep-2024 09:16	Location : Main BNo./
Ref. Id : 232342 / 2809833	Collected at : SAWPL	Approved on : 14-Sep-2024 11:39 Status : Final
Ref. By : Dr. RMO . STERLING...	Collected on : 14-Sep-2024 09:20	Printed On : 14-Sep-2024 16:32
	Sample Type : Serum	Process At : 75 - Sterling Hospital, Race course (Vadodar

**MEDIWHEEL FULL BODY ANNUAL PLUS CHECK/ ADVANCE**
**Lipid Profile**

Test	Result	Unit	Biological Ref. Interval
<b>Cholesterol</b> <i>Cholesterol oxidase - Peroxidase</i>	H 226.0	mg/dL	Desirable : <200 Borderline High : 200-239 High : >240
<b>Triglyceride</b> <i>Ezymatic (Lipase/GK/GPo/POD)</i>	132.0	mg/dL	Normal : <150 Borderline : 150-199 High : 200-499 Very High : >500
<b>HDL Cholesterol</b> <i>PTA/MgCl<sub>2</sub></i>	H 71.0	mg/dL	Low: <40.0 High: >60.0
<b>Direct LDL</b> <i>Direct measured</i>	H 134.00	mg/dL	Optimal: <100 Near to above Optimal: 100-129 Borderline High: 130-159 High: 160-189 Very High: =190
<b>VLDL</b> <i>Calculated</i>	26.40	mg/dL	15 - 35
<b>CHOL/HDL Ratio</b> <i>Calculated</i>	3.2		Up to 5.0
<b>dLDL/HDL Ratio</b> <i>Calculated</i>	1.9		Up to 3.5

  
**Dr. C. Shrinivasan..**

 M.D ( Pathology )[G-18341]  
 Consultant Pathologist

Page 8 of 14

**Sterling Accuris Pathology Laboratory**

 Sterling Hospital, Opp. Inox Cinema, Race Course Circle (West), Vadodara - 390 007, tests marked with # are referred tests  
 Ph: 0265-6144210

pathlab@sterlinghospitals.com | Website: www.sterlinghospitals.com / www.sterlingaccuris.com

This is an Electronically Authenticated Report.



Download Accuris App





Passport No :

**LABORATORY TEST REPORT**


Patient Information	Sample Information	Location Information
Name : Mrs. Vinita . Gaur	Lab Id : 092407501402	Pt. Type : Sterling Hospital Vadodara Health Checkup
Sex/Age : Female / 44 Y 20-Jul-1980	Registration on : 14-Sep-2024 09:16	Location : Main BNo./
Ref. Id : 232342 / 2809833	Collected at : SAWPL	Approved on : 14-Sep-2024 11:39 Status : Final
Ref. By : Dr. RMO . STERLING...	Collected on : 14-Sep-2024 09:20	Printed On : 14-Sep-2024 16:32
	Sample Type : Serum	Process At : 75 – Sterling Hospital, Race course (Vadodar

**MEDIWHEEL FULL BODY ANNUAL PLUS CHECK/ ADVANCE**

Test	Result	Unit	Biological Ref. Interval
<b>Uric Acid</b> <i>Uricase</i>	6.00	mg/dL	2.5 - 6.2
<b>Blood Urea Nitrogen</b> <i>Calculated</i>	13.08	mg/dL	7.0 - 17.0
<b>Urea</b> <i>Urease, Colorimetric</i>	28.0	mg/dL	15.0 - 36.4
<b>Creatinine, serum</b> <i>Creatinine Amidohydrolase</i>	0.90	mg/dL	0.52 - 1.04
<b>BUN Creatinine Ratio</b> <i>Calculated</i>	14.53		
<b>Urea Creatinine Ratio</b> <i>Calculated</i>	31.11		


**Dr. C. Shrinivasan..**

M.D ( Pathology )[G-18341]

Consultant Pathologist

Page 9 of 14


**Sterling Accuris Pathology Laboratory**

 Sterling Hospital, Opp. Inox Cinema, Race Course Circle (West), Vadodara - 390 007, tests marked with # are referred tests  
 Ph: 0265-6144210

pathlab@sterlinghospitals.com | Website: www.sterlinghospitals.com / www.sterlingaccuris.com

This is an Electronically Authenticated Report.



Download Accuris App





Passport No :

**LABORATORY TEST REPORT**


Patient Information	Sample Information	Location Information
Name : Mrs. Vinita . Gaur	Lab Id : 092407501402	Pt. Type : Sterling Hospital Vadodara Health Checkup
Sex/Age : Female / 44 Y 20-Jul-1980	Registration on : 14-Sep-2024 09:16	Location : Main BNo./
Ref. Id : 232342 / 2809833	Collected at : SAWPL	Approved on : 14-Sep-2024 11:39 Status : Final
Ref. By : Dr. RMO . STERLING...	Collected on : 14-Sep-2024 09:20	Printed On : 14-Sep-2024 16:32
	Sample Type : Serum	Process At : 75 – Sterling Hospital, Race course (Vadodar

**MEDIWHEEL FULL BODY ANNUAL PLUS CHECK/ ADVANCE**
**Liver Function Test**

Test	Result	Unit	Biological Ref. Interval
<b>ALT (SGPT)</b> <i>UV with P5P, IFCC</i>	15.0	U/L	0 - 35
<b>AST (SGOT)</b> <i>UV with P5P</i>	27.0	U/L	14 - 36
<b>GGT (Gamma Glutamyl Transferase)</b> <i>L-y-Glytamyl-p-nitroanilide</i>	L 11.0	U/L	12 - 43
<b>Alkaline Phosphatase</b> <i>PNPP, AMP Buffer, IFCC</i>	H 132.0	U/L	38 - 126
<b>Total Bilirubin</b> <i>Azobilirubin chromophores</i>	0.70	mg/dL	0.2 - 1.3
<b>Conjugated Bilirubin</b> <i>Cationic Mordant Binding</i>	0.10	mg/dL	0.0 - 0.3
<b>Unconjugated Bilirubin</b> <i>Cationic Mordant Binding</i>	0.40	mg/dL	0.0 - 1.1
<b>Delta Bilirubin</b> <i>Calculated</i>	0.20	mg/dL	0.0 - 0.2
<b>Total Protein</b> <i>Copper tartrate to colour complex</i>	7.50	g/dL	6.3 - 8.2
<b>Albumin</b> <i>Bromocresol Green Method</i>	4.20	g/dL	3.5 - 5.0
<b>Globulin</b> <i>Calculated</i>	3.30	g/dL	2.3 - 3.5
<b>A/G Ratio</b> <i>Calculated</i>	L 1.27		1.3 - 1.7



**Dr. C. Shrinivasan..**  
M.D ( Pathology ) [G-18341]  
Consultant Pathologist

Page 10 of

**Sterling Accuris Pathology Laboratory**

Sterling Hospital, Opp. Inox Cinema, Race Course Circle (West), Vadodara - 390 007, tests marked with # are referred tests  
Ph: 0265-6144210

pathlab@sterlinghospitals.com | Website: www.sterlinghospitals.com / www.sterlingaccuris.com

This is an Electronically Authenticated Report.



Download Accuris App



Passport No :

**LABORATORY TEST REPORT**


Patient Information	Sample Information	Location Information
Name : Mrs. Vinita . Gaur	Lab Id : 092407501402	Pt. Type : Sterling Hospital Vadodara Health Checkup
Sex/Age : Female / 44 Y 20-Jul-1980	Registration on : 14-Sep-2024 09:16	Location : Main BNo./
Ref. Id : 232342 / 2809833	Collected at : SAWPL	Approved on : 14-Sep-2024 11:40 Status : Final
Ref. By : Dr. RMO . STERLING...	Collected on : 14-Sep-2024 09:20	Printed On : 14-Sep-2024 16:32
	Sample Type : Serum	Process At : 75 – Sterling Hospital, Race course (Vadodar

**MEDIWHEEL FULL BODY ANNUAL PLUS CHECK/ ADVANCE**
**Thyroid Function Tests**

Test	Result	Unit	Biological Ref. Interval
T3, total (Triiodothyronine) <i>CLIA</i>	1.21	ng/mL	0.58 - 1.59
T4, total (Thyroxine) <i>CLIA</i>	7.27	µg/dl	4.87 - 11.72
TSH (3rd Gen.) <i>Chemiluminescence</i>	1.7660	µIU/mL	Non-Pregnant Woman: 0.4001-4.049; Pregnant Woman: 1st Trimester: 0.1298-3.120; 2nd Trimester: 0.2749-2.652; 3rd Trimester : 0.3127-2.947


**Dr. C. Shrinivasan..**

M.D ( Pathology )[G-18341]

Consultant Pathologist

Page 11 of


**Sterling Accuris Pathology Laboratory**

Sterling Hospital, Opp. Inox Cinema, Race Course Circle (West), Vadodara - 390 007, tests marked with # are referred tests  
Ph: 0265-6144210

pathlab@sterlinghospitals.com | Website: www.sterlinghospitals.com / www.sterlingaccuris.com

This is an Electronically Authenticated Report.



Download Accuris App



Passport No :

**LABORATORY TEST REPORT**


Patient Information	Sample Information	Location Information
Name : Mrs. Vinita . Gaur	Lab Id : 092407501402	Pt. Type : Sterling Hospital Vadodara Health Checkup
Sex/Age : Female / 44 Y 20-Jul-1980	Registration on : 14-Sep-2024 09:16	Location : Main BNo./
Ref. Id : 232342 / 2809833	Collected at : SAWPL	Approved on : 14-Sep-2024 11:40 Status : Final
Ref. By : Dr. RMO . STERLING...	Collected on : 14-Sep-2024 09:20	Printed On : 14-Sep-2024 16:32
	Sample Type : Serum	Process At : 75 – Sterling Hospital, Race course (Vadodar

**MEDIWHEEL FULL BODY ANNUAL PLUS CHECK/ ADVANCE**

Levels of TSH in pregnancy ( $\mu\text{IU/mL}$ ): First Trimester 0.1 - 2.5; Second Trimester 0.2 – 3.0; Third Trimester 0.3 – 3.0.

**NOTE:** TSH concentrations in apparently normal euthyroid subjects are known to be highly skewed, with a strong tailed distribution towards higher TSH values. This is well documented in the pediatric population including the infant age group.

TSH	T3/FT3	T4/FT4	Suggested interpretation of Thyroid function tests pattern
Within range	Decreased	Within range	Isolated low T3 often seen in elderly & associated Non-Thyroid illness. In elderly the drop in T3 level can be up to 25%.
Raised	Within Range	Within Range	Isolated High TSH Especially in the range of 4.7 to 15 mIU/ml is commonly associated with physiological & Biological TSH Variability; Subclinical Autoimmune Hypothyroidism; Intermediate T4 therapy for hypothyroidism; Recovery phase after Non-Thyroidal illness.
Raised	Decreased	Decreased	Chronic Autoimmune Thyroiditis; Post thyroidectomy, post radioiodine; Hypothyroid phase of transient thyroiditis.
Raised or within range	Raised	Raised or within range	Interfering antibodies to thyroid hormones (anti-TPO antibodies); Intermediate T4 therapy of T4 overdose; Drug Interference-Amiodarone, Heparin, Beta blocker, steroids, anti-epileptics.
Decreased	Raised or within range	Raised or within range	Isolated Low TSH – Especially in the range of 0.1 to 0.4 often seen in elderly & associated with Non-Thyroidal illness; Subclinical Hyperthyroidism; Thyroxine ingestion.
Decreased	Decreased	Decreased	Central Hypothyroidism; Non-Thyroidal illness; Recent treatment for Hypothyroidism (TSH remains suppressed).
Decreased	Raised	Raised	Primary Hyperthyroidism (Graves' disease), Multinodular goitre Toxic nodule; Transient thyroiditis: postpartum, Silent (lymphocytic), Post viral (granulomatous, subacute, DeQuervain'a) Gestational thyrotoxicosis hyperemesis gravidarum.
Decreased or within range	Raised	Within range	T3 toxicosis; Non-Thyroidal illness.

Reference: Wallach's Interpretation of Diagnostic by Mary Williamson, 10th edition, 2015.


**Dr. C. Shrinivasan..**

 M.D ( Pathology ) [G-18341]  
Consultant Pathologist

Page 12 of

**Sterling Accuris Pathology Laboratory**

 Sterling Hospital, Opp. Inox Cinema, Race Course Circle (West), Vadodara - 390 007, tests marked with # are referred tests  
Ph: 0265-6144210

pathlab@sterlinghospitals.com | Website: www.sterlinghospitals.com / www.sterlingaccuris.com

This is an Electronically Authenticated Report.



Download Accuris App





Passport No :

**LABORATORY TEST REPORT**


Patient Information	Sample Information	Location Information
Name : Mrs. Vinita . Gaur	Lab Id : 092407501402	Pt. Type : Sterling Hospital Vadodara Health Checkup
Sex/Age : Female / 44 Y 20-Jul-1980	Registration on : 14-Sep-2024 09:16	Location : Main BNo./
Ref. Id : 232342 / 2809833	Collected at : SAWPL	Approved on : 14-Sep-2024 12:02 Status : Final
Ref. By : Dr. RMO . STERLING...	Collected on : 14-Sep-2024 09:20	Printed On : 14-Sep-2024 16:32
	Sample Type : Urine	Process At : 75 – Sterling Hospital, Race course (Vadodara)

**MEDIWHEEL FULL BODY ANNUAL PLUS CHECK/ ADVANCE**
**URINE ROUTINE EXAMINATION**

Test	Result	Unit	Biological Ref. Interval
<b>Physical &amp; Chemical (Dip strip) examination</b>			
Colour	Pale Yellow		Pale Yellow
pH <i>Double indicator</i>	5.5		5.5 - 7.0
Specific Gravity <i>Polyelectrolyte based reaction</i>	H 1.030		1.015 - 1.025
Protein <i>Protein error of indicators</i>	Absent		Absent
Glucose <i>GOD-POD</i>	Absent		Absent
Ketone <i>Nitroprusside</i>	Absent		Absent
Blood <i>Peroxidase like reaction</i>	Absent		Absent
Bilirubin <i>Diazo reaction</i>	Absent		Absent
Leucocytes <i>Esterase reaction</i>	Absent		Absent
Nitrite <i>p-arsanilic acid to diazonium compound</i>	Absent		Absent
<b>Microscopic Examination</b>			
Erythrocytes (RBCs)	Absent	/hpf	0 - 2
Pus Cells	1-2	/hpf	0 - 5
Epithelial Cells	Occasional	/hpf	
Crystals	Absent		Absent
Casts	Absent		Absent
Bacteria	Absent		Absent
Amorphous Material	Absent		Absent
Yeast	Absent		Absent


  
Dr. C. Shrinivasan..

M.D ( Pathology ) [G-18341]  
Consultant Pathologist

Page 13 of

**Sterling Accuris Pathology Laboratory**

Sterling Hospital, Opp. Inox Cinema, Race Course Circle (West), Vadodara - 390 007. tests marked with # are referred tests  
Ph: 0265-6144210

 pathlab@sterlinghospitals.com | Website: www.sterlinghospitals.com / www.sterlingaccuris.com

This is an Electronically Authenticated Report.



Download Accuris App





Scan to check report authenticity

Histo / Cyto No : **C4000730**

**LABORATORY REPORT**



Patient Information		Sample Information		Client / Location Information	
Name	: Mrs. Vinita . Gaur	Lab ID	: 092407501402	Client Name	: Sterling Hospital Vadodara Health Checkup Main
Sex/Age	: Female /44 Years	Registered on	: 14-Sep-2024 09:16	Location	:
Ref. Id	:	Collected at	: non SAWPL	Approved on	: 14-Sep-2024 16:13
Ref. By	: Dr. RMO . STERLING...	Collected on	: 14-Sep-2024 12:30	Printed on	: 14-Sep-2024 16:32
		Sample Type	: PAP Material	Processed at	: 17 – Sterling Hospital, Bhayli (Vadodara)
Branch	: 75 – Sterling Hospital, Race course (Vadodara)				

**CYTOPATHOLOGY**

\* **PAP Smear No. :**

P - 521/24

\* **Obstetric History :**

G2 P2 A0 L2

\* **Menstrual History :**

LMP - 04/09/24

\* **Per-Speculum Examination :**

NAD

\* **Per-Vaginal Examination :**

NAD

\* **Specimen Adequacy :**

Satisfactory for evaluation ; Endocervical and transformation zone present.

\* :

Negative for intraepithelial lesion or malignancy.

\* :

Mild acute inflammation.

----- End Of Report -----



**Dr. Swati Gupta**  
MD (Path) DipRCPath

This is an electronically authenticated report.

tests marked with # are referred tests





Report Date: 14 Sep 2024 - 10:08 AM

Patient Id	: RCR-232342	Patient Name	: GAUR VINITA .
Age	: 44Y 1M 25D	Sex	: Female
Ref. Doctor	: DR. RMO . STERLING	Study Date	: 14 Sep 2024 - 09:48 AM

**X-RAY CHEST PA VIEW**

Both lung fields show prominent broncho-vascular markings.  
Cardiac size appears within normal limit.  
Trachea and mediastinal soft tissue shadow appear unremarkable.  
Lateral C.P. angles and both domes of diaphragm appear normal.  
Bony thorax under vision appears normal.

**CONCLUSION:**

**No significant chest abnormality detected.**

**Dr. Shilpi Gupta MD**  
**Sr. Consultant Radiologist**

**Hospital Address:** Sterling Hospitals, Race Course Road, Opp. Inox Cinema Hari Nagar, Circle West, Vadodara – 390007, Gujarat, India | Call: 0265-6144111, 0265-2354455, 98 98 98 78 78  
www.sterlinghospitals.com | info@sterlinghospitals.com

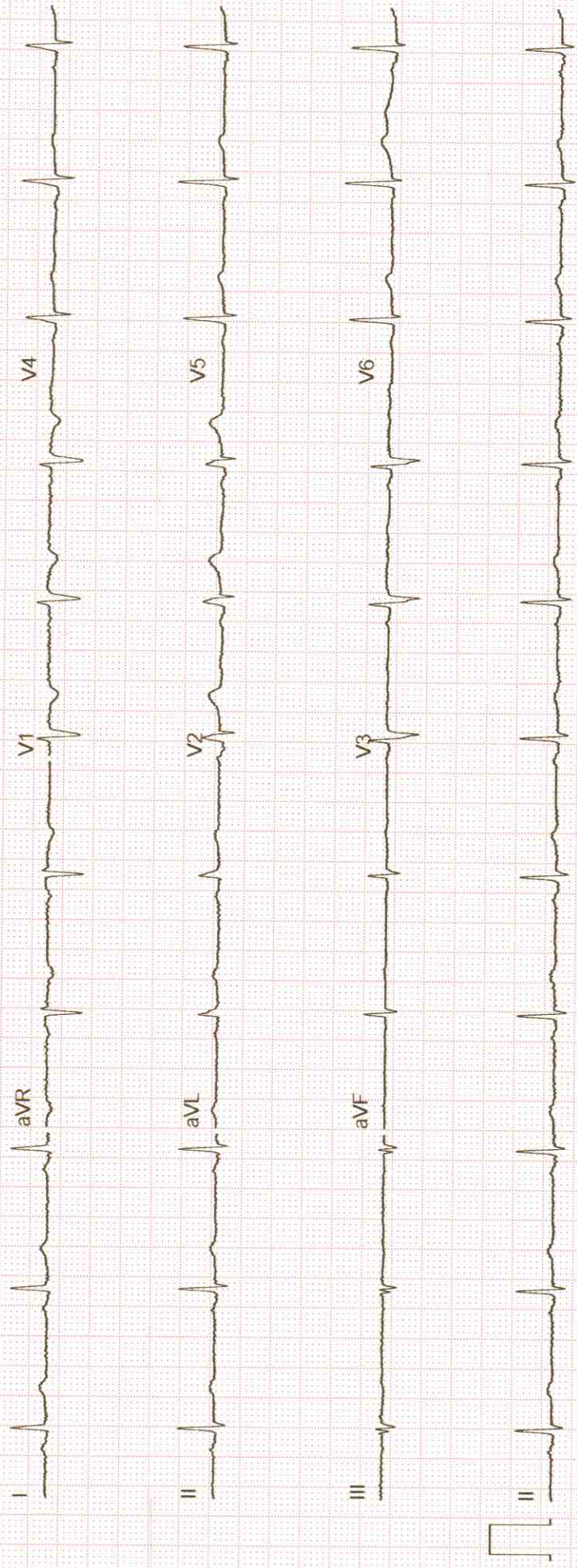
**Registered Office:** Sterling Addlife India Private Limited | CIN U85110GJ2000PTC039121  
Sterling Hospital, Sterling Hospital Road, Memnagar, Ahmedabad-380052, Gujarat, India



Female

QRS : 80 ms  
 QT / QTcBaz : 400 / 416 ms  
 PR : 142 ms  
 P : 98 ms  
 RR / PP : 924 / 923 ms  
 P / QRS / T : 29 / 20 / 18 degrees

*10/11*



44 Years



## 2D ECHOCARDIOGRAPHY REPORT



Race Course Road, Vadodara

Name: Mrs. VINITA GAUR  
Age: 44 Years  
Sex: F  
Date: 14-Sep-2024

Ref By: HCP  
Study: 2D Echo

### M-MODE:

IVS	09mm	LVDD	44mm
PW	10mm	LVDS	26mm
LA	36mm	LV EF	55-60 %

### DOPPLER STUDY:

MITRAL	E 0.55 A 0.79
AORTIC	1.54
TRICUSPID	N
PULMONARY	N

### CONCLUSION :

- NORMAL SIZED CHAMBERS
- NORMAL LV SYSTOLIC FUNCTION LVEF 60 %
- NO RWMA AT REST
- GRADE I DIASTOLIC DYSFUNCTION
- NORMAL RV SIZE AND FUNCTION
- ALL VALVES ARE NORMAL
- NO CLOT OR VEGETATION
- NO PERICARDIAL EFFUSION
- NORMAL IVC

Dr. RANJEETKUMAR SHUKLA MD,DM  
Consultant interventional Cardiologist

Hospital Address: Sterling Hospitals, Race Course Road, Opp. Inox Cinema Hari Nagar, Circle West,  
Vadodara – 390007, Gujarat, India | Call: 0265-6144111, 0265-2354455, 98 98 98 78 78  
www.sterlinghospitals.com | info@sterlinghospitals.com

Registered Office: Sterling Addlife India Private Limited | CIN U85110GJ2000PTC039121  
Sterling Hospital, Sterling Hospital Road, Memnagar, Ahmedabad-380052, Gujarat, India

SonoDoc 91-20-25443913







Report Date: 14 Sep 2024 - 12:38 PM

Patient Id	: RCR-232342	Patient Name	: GAUR VINITA .
Age	: 44Y 1M 25D	Sex	: Female
Ref. Doctor	: DR. RMO . STERLING	Study Date	: 14 Sep 2024 - 11:42 AM

**BILATERAL MAMMOGRAM: -**

**Technique:** Dedicated low dose film screen mammography with cranio-caudal and Medio lateral view was performed.

**Clinical profile:** Routine checkup, no complaints

**REPORT**

The mammary parenchyma is inhomogeneously dense- because of prominent fibro-glandular tissues (ACR type C). This somewhat lowers the sensitivity of mammography.

No evidence of any distortion noted.

No evidence of any suspicious hyperdense nodular lesions noted on either side.

No evidence of any abnormal micro calcification is seen.

No evidence of skin thickening or nipple retraction noted on either side.

Accessory breast tissue is seen along axilla on either side.

Soft opacities seen in axilla on either side are suggestive of axillary nodes. No evidence of enlarged pathological lymph nodes seen on either side.

**CONCLUSION: -**

- **No significant abnormality detected (BIRADS 1).**
- Adv: Routine annual mammogram.

The false negative mammography is approximately 10%. Management of a palpable abnormality must be based upon clinical grounds. **Sensitivity of mammography is limited without sonography. Sonography is recommended if strong clinical suspicion is there.**



**Dr. Shilpi Gupta MD**  
**Sr. Consultant Radiologist**

**Hospital Address:** Sterling Hospitals, Race Course Road, Opp. Inox Cinema Hari Nagar, Circle West, Vadodara – 390007, Gujarat, India | Call: 0265-6144111, 0265-2354455, 98 98 98 78 78  
www.sterlinghospitals.com | info@sterlinghospitals.com

**Registered Office:** Sterling Addlife India Private Limited | CIN U85110GJ2000PTC039121  
Sterling Hospital, Sterling Hospital Road, Memnagar, Ahmedabad-380052, Gujarat, India





Patient Id	: RCR-232342	Patient Name	: GAUR VINITA .
Age	: 44Y 1M 25D	Sex	: Female
Ref. Doctor	: DR. RMO . STERLING	Study Date	: 14 Sep 2024 - 12:25 PM

## ULTRASOUND OF ABDOMEN AND PELVIS

### FINDINGS

**Liver** is normal in size and shows normal echotexture. No focal lesion seen. No IHBR dilatation. **Portal vein** (11.2 mm) and CBD (4.7 mm) appear normal.

**Gall bladder** is partially distended and shows normal wall thickness. No evidence of calculus or mass lesion seen.

Visualized **pancreas** appears normal.

**Spleen** appears normal in size (8.5 cm) and shows normal echotexture.

**Right kidney** (8.3 x 3.6 cm) appears normal. There is no evidence of scarring, hydronephrosis or calculi. Normal cortical echogenicity and cortico-medullary differentiation are maintained.

**Left kidney** (9 x 4.1 cm) appears normal. There is no evidence of scarring, hydronephrosis or calculi. Normal cortical echogenicity and cortico-medullary differentiation are maintained.

**Urinary bladder** is well distended and shows normal wall. No calculus or mass lesion is seen.

**Uterus** is retroverted. appears normal in size and reveals normal echotexture. Endometrial thickness is 7 mm.

Both **ovaries** appear normal. No adnexal mass is seen.

No evidence of ascites seen.

### IMPRESSION

- **No significant intra-abdominal abnormality seen in present study.**

**Dr. Palak Nandolia**  
**Consultant Radiologist**

Hospital Address: Sterling Hospitals, Race Course Road, Opp. Inox Cinema Hari Nagar, Circle West, Vadodara – 390007, Gujarat, India | Call: 0265-6144111, 0265-2354455, 98 98 98 78 78  
www.sterlinghospitals.com | info@sterlinghospitals.com

Registered Office: Sterling Addlife India Private Limited | CIN U85110GJ2000PTC039121  
Sterling Hospital, Sterling Hospital Road, Memnagar, Ahmedabad-380052, Gujarat, India

