

Ishrat Shaikh.
49/F.

10/2/24

Eye checkup

	(R)		(L)
VA	(A) 6/6		(A) 6/6
	(A) N6		(A) N6
Celestyn	(A)		(A)
A/S	(A)		(A)
(E)	(A)		(A)

(E) OK

by

ECHO Report

Date: 10/02/2024

Patient Details

Patient ID –

Name- MR ISHRAT SHAIKH

Age- 49 YEARS

Gender- FEMALE

Referral BY - MEDIWHEEL

Doctor Incharge DR. MAHESH PADSALGE

Clinical Status of Patient -

Finding description -

- 1. Normal cardiac chambers dimensions .**
- 2. Normal LV systolic function.**
- 3. No RWMA.**
- 4. All cardiac valves are structurally normal.**
- 5. Trivial MR, Trivial PR, NO AR.**
- 6. No PAH (PASP – 25mmHg).**
- 7. Normal RV systolic function.**
- 8. No clot/vegetation/pericardial effusion.**
- 9. No coarctation of aorta.**

LVID (Diastole) 35-56(mm) - 44.00
IVS (Diastole) 8-12(mm) - 09.00
LVPWT (Diastole) 6-11(mm) - 09.00
LVEF (%) - 66 %

LVID (Systole) 24-42(mm) - 28.00
IVS (Systole) 14-42(mm) - 13.00
EPSS - 2.00
LVFS (%) - 36.00

LV Volume (Diastolic)(mm³)
Meridional Wall Stress in System

LV Volume (Systolic)(mm³)
Cubed LV Volume in Diastole (mm³)

Cubed LV+ myocardial volume (mm³)

Velocity of circumferential
Shortening (mm)

Aortic root 22-37(mm) - 30.00
Left Atrium Length (mm) - 30.00
Left Atrium Volume (mm³)
RV size Normal
Normal
RV volume (mm³)
Normal
Pericardium Normal
Effusion None
Resp Variation Present
Predicted RV Systolic Pressure

Left Atrium Width (mm)
Left Atrium Area (mm²)
RV Function

RA Size

IVC Size (mm) – 17mm Collapsible

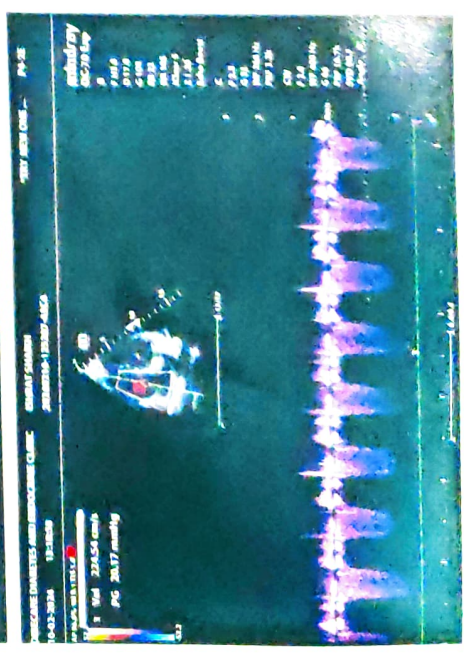
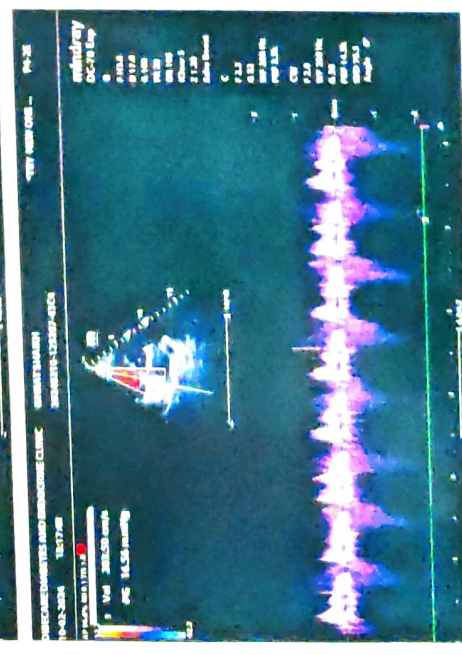
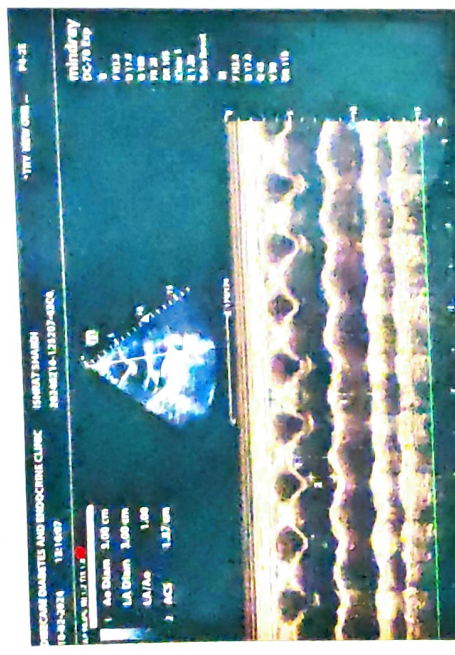
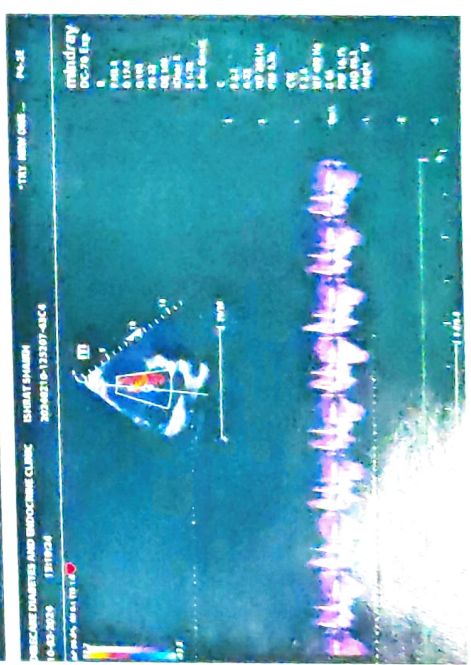
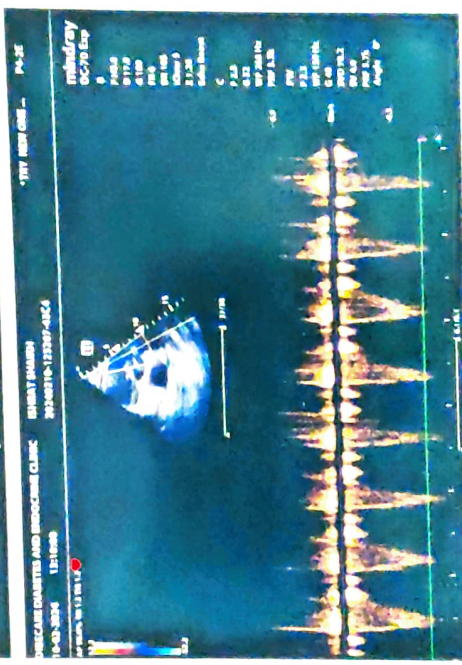
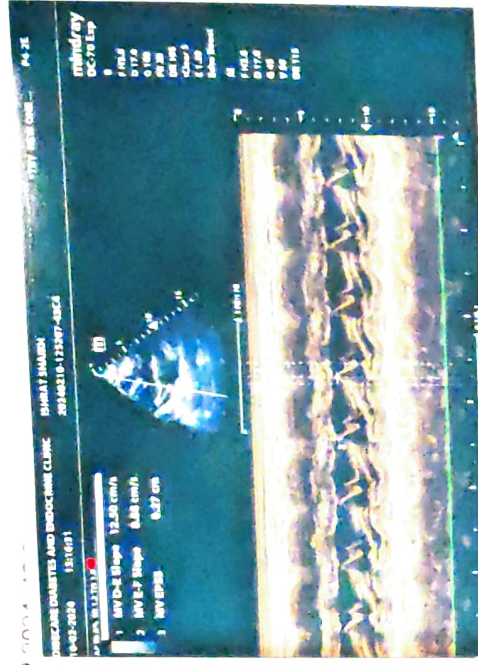
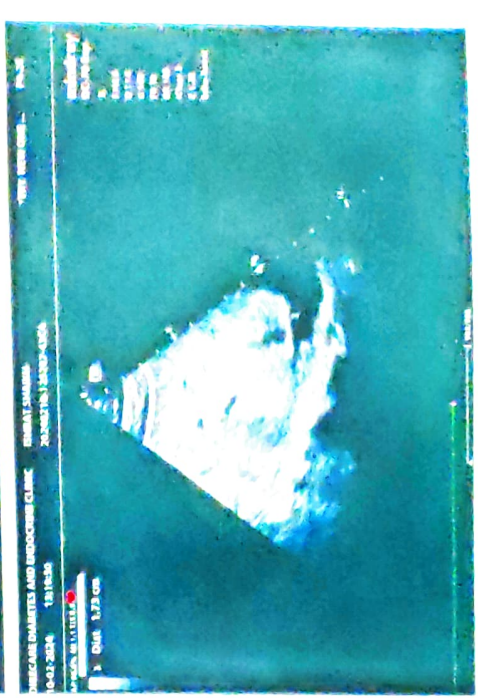
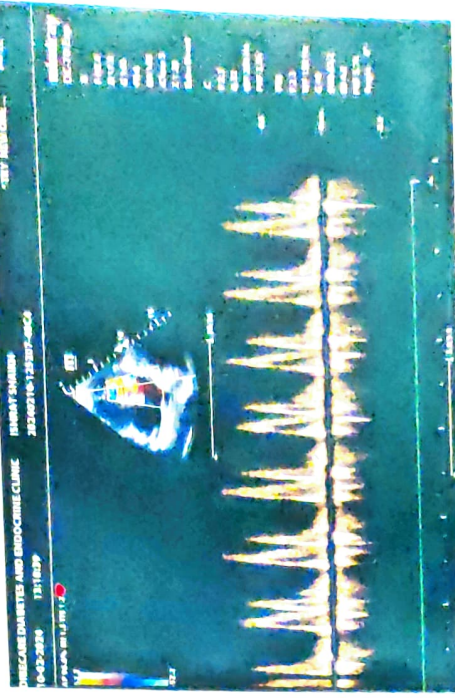

Doppler Findings- I



Dr. Mahesh Padsalge

Dr. Mahesh V. Padsalge
MD. (Medicine)
Consultant Physician
Reg. No. 91424 (MMC)

10.02.2024



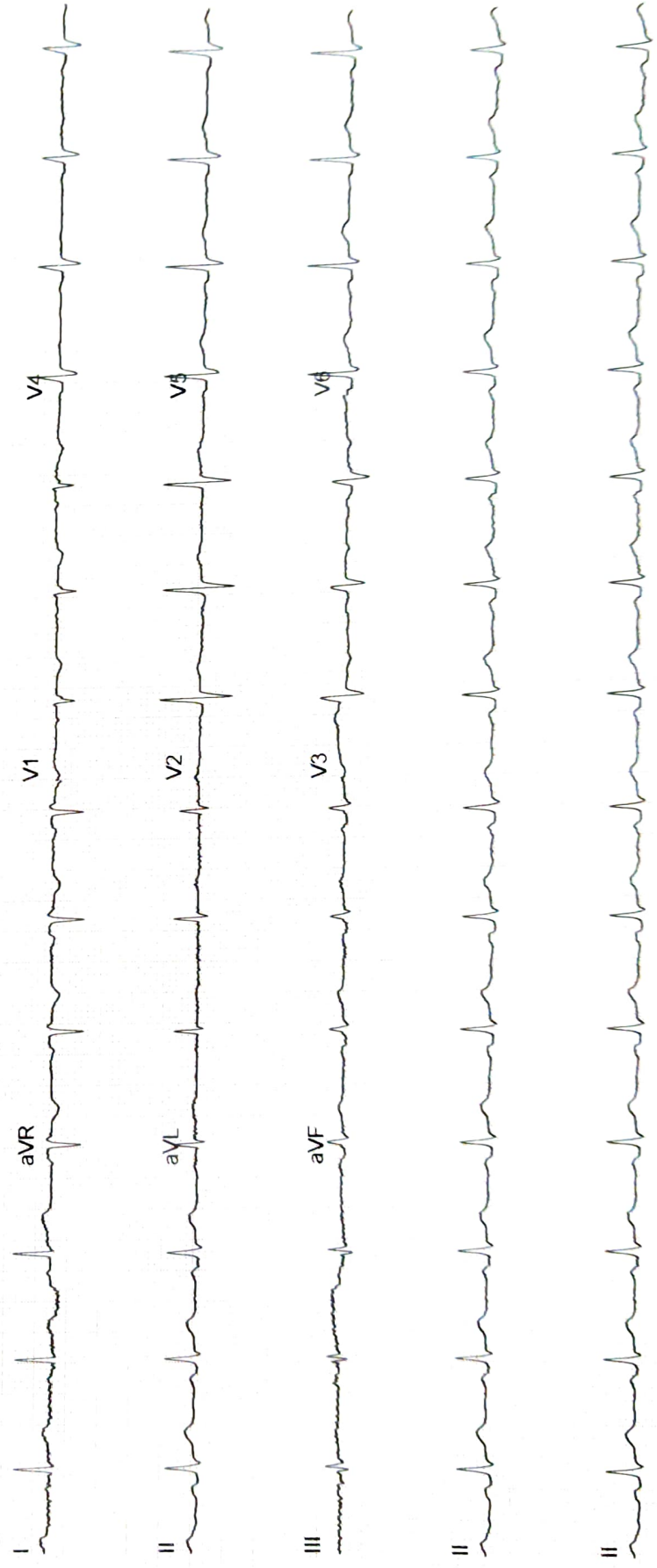
Female

QRS : 84 ms
QT / QTcBaz : 368 / 437 ms
PR : 144 ms
P : 94 ms
RR / PP : 706 / 705 ms
P / QRS / T : 65 / 37 / 56 degrees

Normal sinus rhythm
Normal ECG

ECG within normal limit

cyb
Dr. Mahesh V. Padsalge
MD. (Medicine)
Consultant Physician
Reg. No. 91424 (MMC)





भारतीय विशिष्ट ओळख प्राधिकरण

भारत सरकार
Unique Identification Authority of India
Government of India

नोंदविण्याचा क्रमांक / Enrollment No 1104/20574/25945

To,
इशरत सदरुल हमन शेख
Ishrat Sadrul Hasan Shaikh
W/O: Sadrul Hasan Shaikh
Near Geeta Vikas School Plot No-23/N/4, Road No-3, Shivaji
Nagar, Govandi
Shivaji Nagar
Shivaji Nagar Shivaji Nagar Mumbai
Maharashtra 400043

15/11/2012

Ref: 4 / 16A / 7500 / 7980 / P



SH073587794DF



आपला आधार क्रमांक / Your Aadhaar No. :

5734 2229 5462

आधार — सामान्य माणसाचा अधिकार



भारत सरकार
GOVERNMENT OF INDIA



इशरत सदरुल हमन शेख
Ishrat Sadrul Hasan Shaikh
जन्म वर्ष / Year of Birth : 1974
स्त्री / Female



5734 2229 5462

आधार — सामान्य माणसाचा अधिकार

Dr. Mahesh V. Padsalge
MD. (Medicine)
Consultant Physician
Reg. No. 91424 (MMC)

NAME- ISHRAT SHAIKH

DATE-10/2/2024

AGE- 49/F

X-RAY CHEST PA

The Bony Thorax is Normal.

Both The Costophrenic And Cardiophrenic Angles Are Clear.

Cardiac Shape And Size Appears Normal.

The Lung Field Appears Normal.

Both The Hila Are Normal In Density And Position.

Impression: - Normal Chest X-Ray.

For, Annot

DR.MRUDULA BABAR
CONSULTANT RADIOLOGIST

DR. MRUDULA BABAR
MBBS, DNB, DMRE (RADIOLOGY)
CPS MUMBAI 2009
REG. NO. 2005/03/2139

Name: ISHRAT SHAIKH	Age/sex: 49Yrs / FEMALE
Ref by: MEDIWHEEL	Date: 10/02/2024

ULTRASOUND EXAMINATION OF ABDOMEN & PELVIS

Findings-

The Liver is normal in size (14.1cm) shape and raised echogenicity. No focal lesion is seen. The Hepatic veins appear normal. There is no IHBR dilatation. The portal vein appears normal.

The gall bladder is partially distended. The extra hepatic C.B.D. is of normal caliber.

The visualized Pancreas appears normal in size and reflectivity. The pancreatic duct is not dilated. The spleen is normal in size (8.1cm), No focal lesion is seen. Splenic vein is normal at hilum.

Both kidneys are normal in position and size. They show normal cortical reflectivity and cortico-medullary differentiation. There is no evidence of renal calculus, hydronephrosis or mass.

Right kidney measures 8.7 x 4.3 cm

Left kidney measures 10.5 x 3.9 cm

The Urinary bladder is well distended. No evidence of any intraluminal mass or calculi.

Uterus is anteverted post-menopausal status. Endometrial echoes are mid line and measure 3.1 mm.

No adnexal mass lesion

No free fluid is noted in abdomen and pelvis.

No probe tenderness seen in present study

IMPRESSION:-

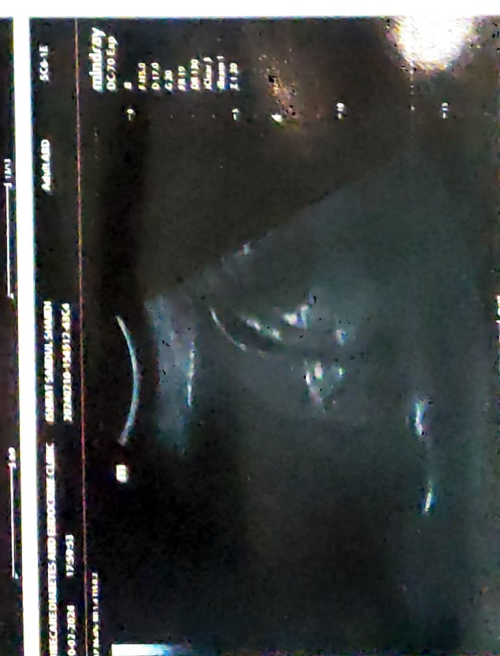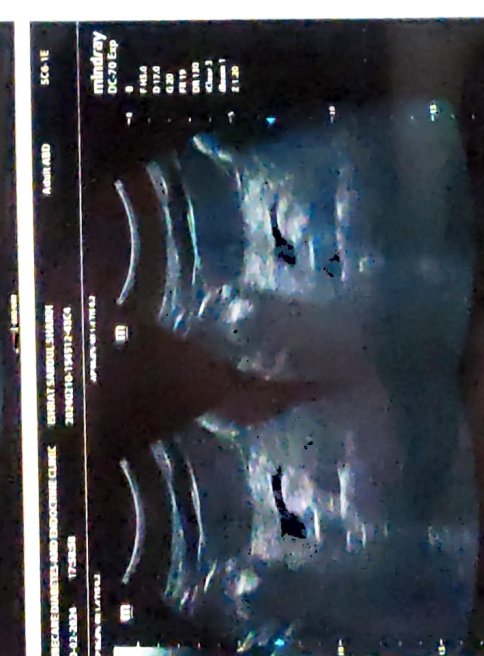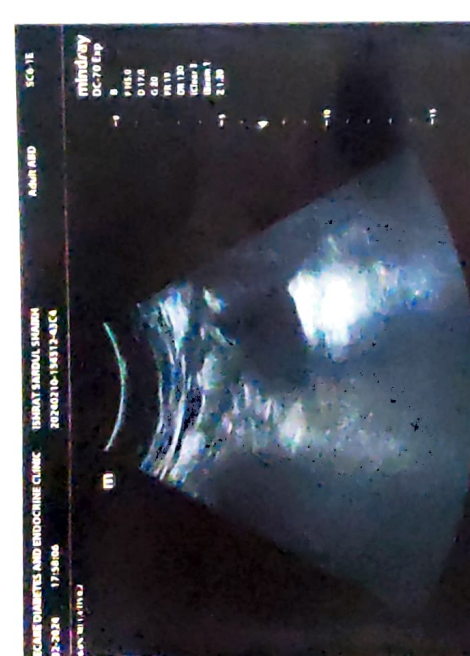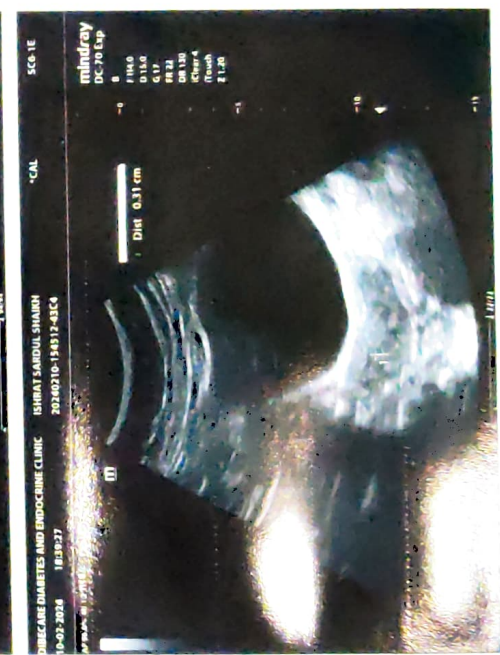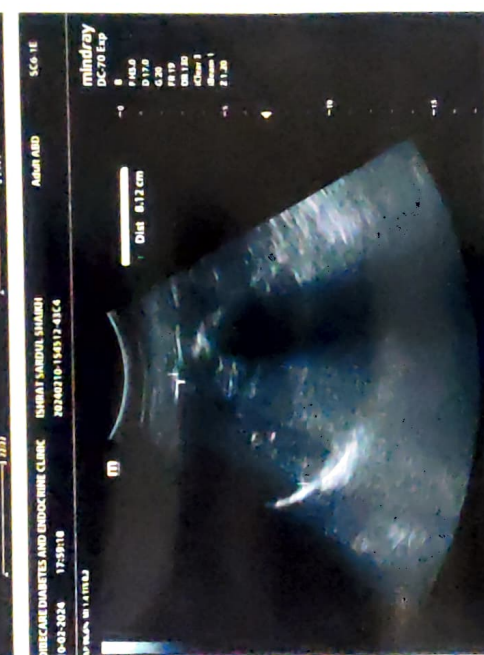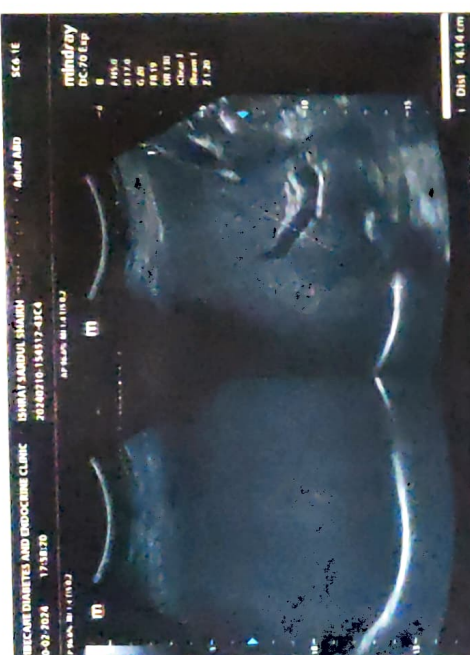
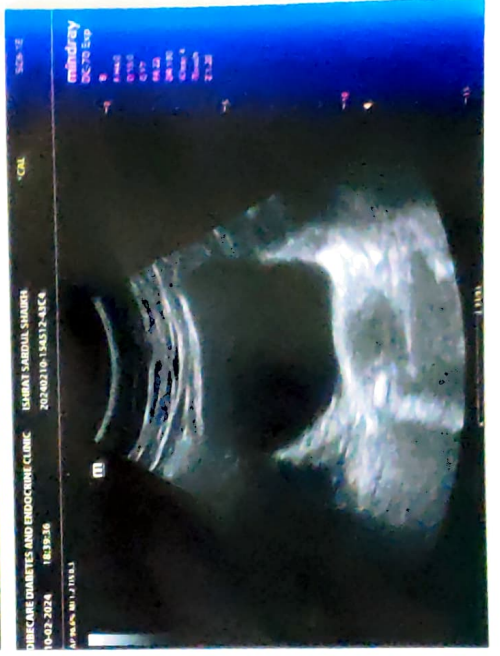
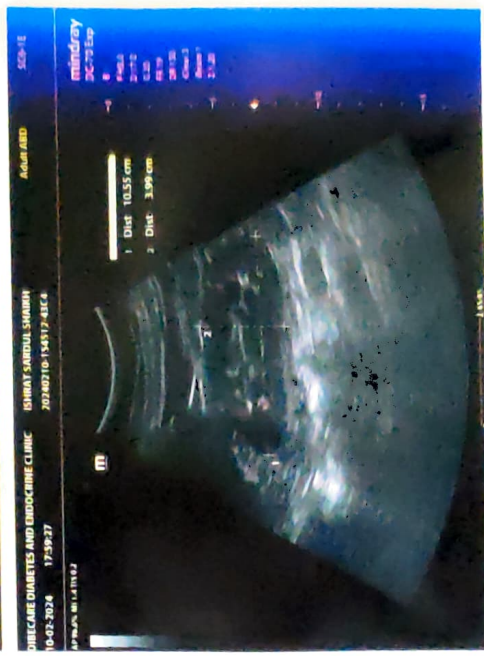
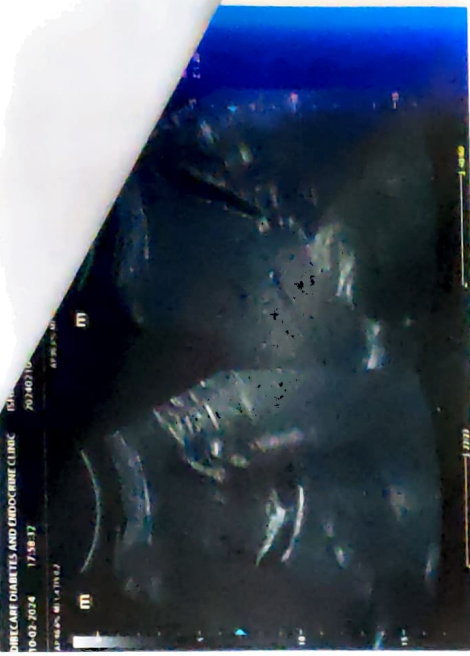
Grade 1 -2 fatty infiltration of liver

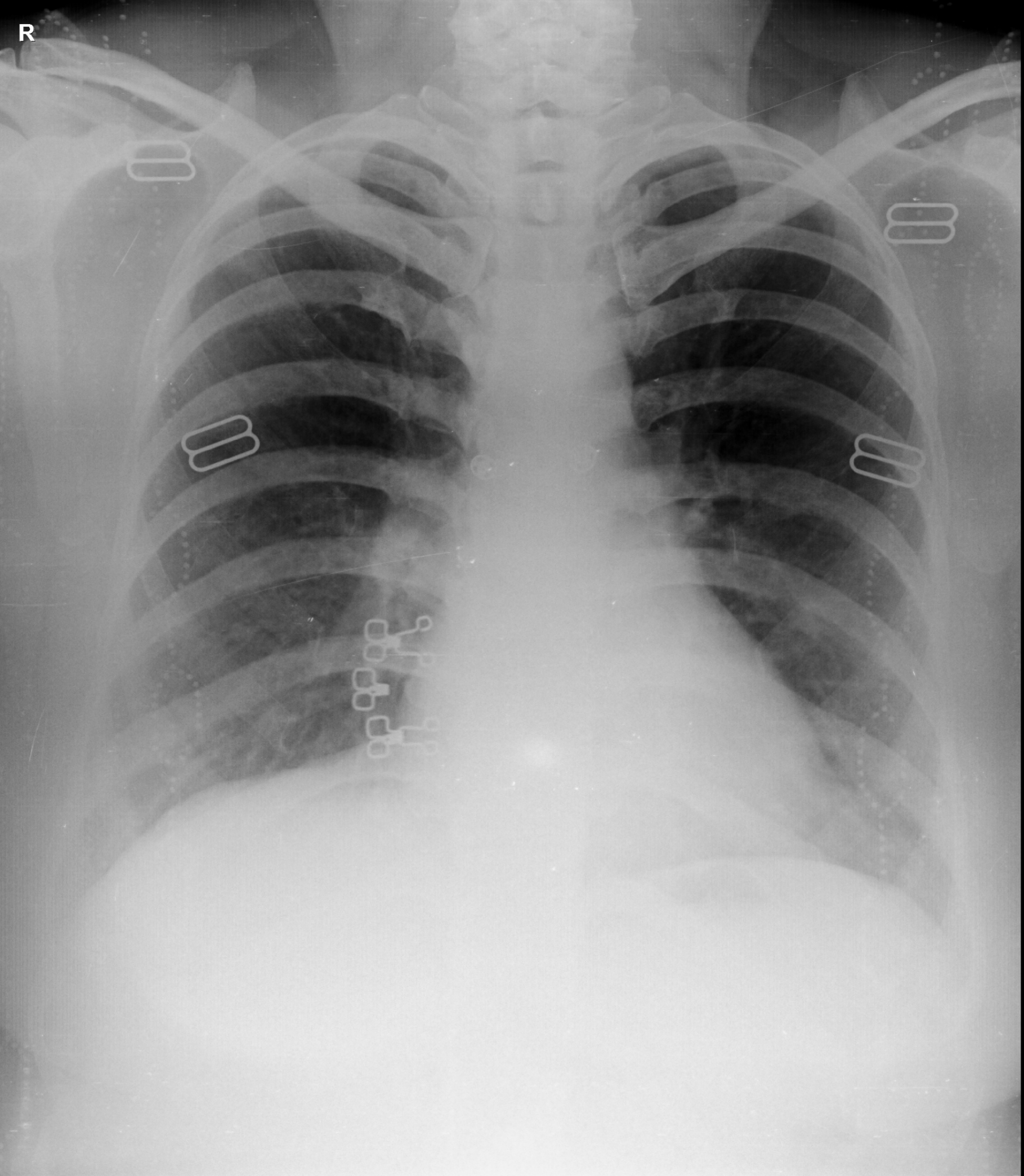
Adv: clinical correlation



DR.MRUDULA BABAR
CONSULTANT RADIOLOGIST.

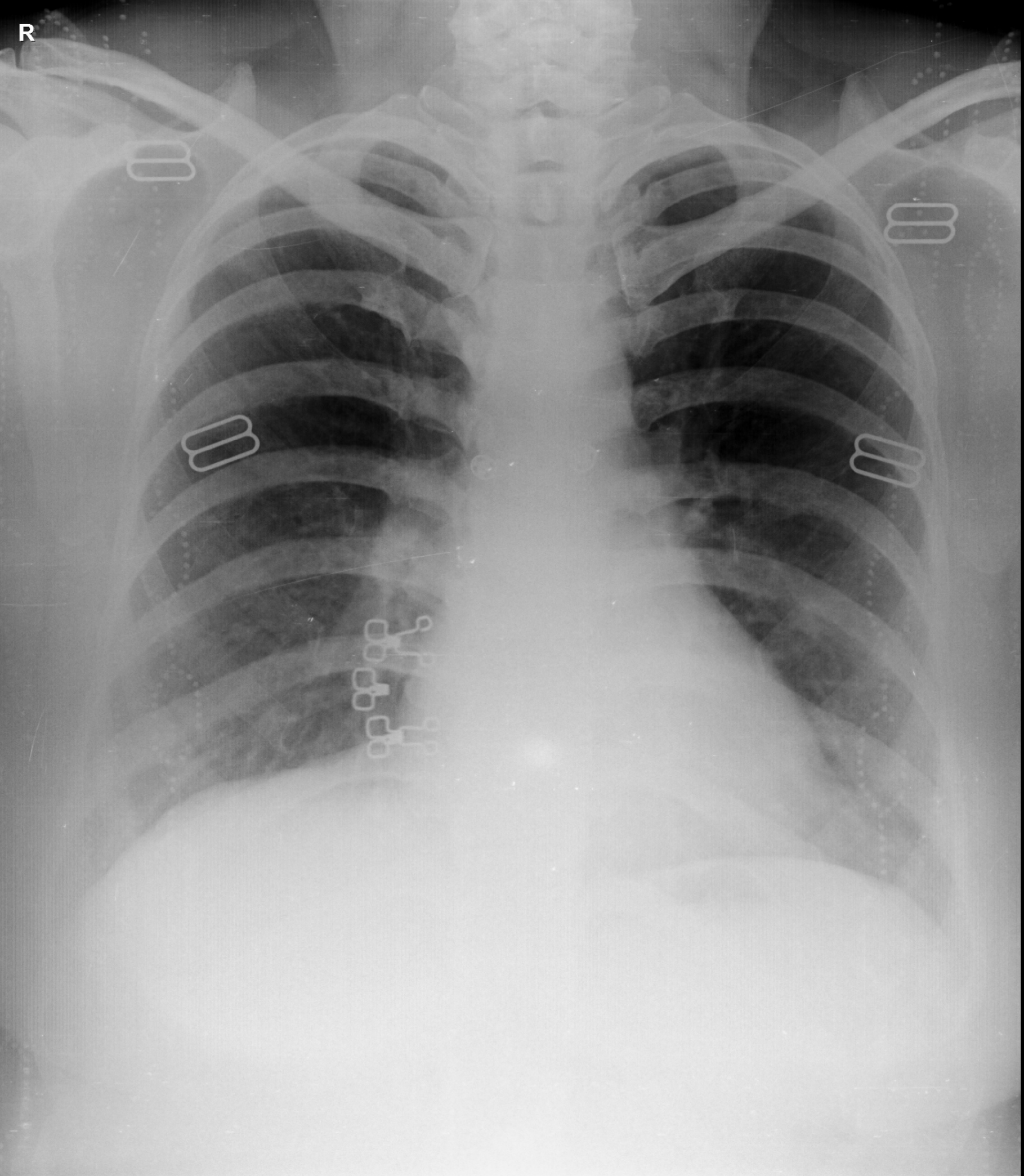
DR. MRUDULA BABAR
MBBS, MD, DMRE (RADIOLOGY)
CPS MUMBAI 2009
REG. NO. 2005/03/2139





R

ISHRAT SHAIKH 49YRS F 2/10/2024 03:50 AM
OLIVE DIAGNOSTIC, SEAWOOD SEC 40



R

ISHRAT SHAIKH 49YRS F 2/10/2024 03:50 AM
OLIVE DIAGNOSTIC, SEAWOOD SEC 40