

DR. NETRAVALKAR'S ASHWINI PATHOLOGY LABORATORY

(For all investigation in Histopathology, Cytopathology, Haematology, Clinical Pathology, Microbiology & Hormonal Chemistry)

Consultant Pathologist **Dr. Prasad Netravalkar** MBBS, MD (Path) BOM

(HOME COLLECTION FACILITY AVAILABLE)

Panaji : 1st, Floor, Rizvi Sadan, Above Saroj Emporium, Near Inox Theatre, Opp. Municipal Market, Panaji.

Ph.: 2229142, 8407912840, 8390242524

E-mail : ashwinilabpanaji@gmail.com, drprasadnetravalkar@gmail.com

Mapusa : F8, Ramchandra Chambers, 1st Floor, Mapusa Clinic Road, Mapusa - Bardez, Goa. Ph.: 2252320, 2250709

Sanquelim : 1st floor, Shanta Commercial Complex, Sanquelim - Goa. Ph.: 2364524, 9067292714

Pt.No. : 69 180324

Pt.Name : - Kamble Seema Shankar

Age : 37 Yrs. Sex : F

Ref. By : -

Date : 18-03-2024

Normal Range

COMPLETE HEMOGRAM


Haemoglobin	: 10.7	g/dl	11.5 - 16.5 g/dl
W.B.C Count	: 8800	cells/ cu-mm	4000 - 11000 cells/ cu-mm
R.B.C Count	: 4.76	millions / cu-mm	3.8 - 4.5 millions / cu-mm
MCV	: 63.9	fl	80 - 99 fl
MCH	: 22.4	Pg	27 - 33 Pg
MCHC	: 35.1	%	32 - 37 %
PCV	: 30.4	%	37 - 47 %
Platelet Count	: 3.26	lakhs /cu mm	1.5 - 4.5 lakhs /cu mm
E.S.R (Westergren)	: 17	mm/hr	0 - 20 mm/hr

DIFFERENTIAL COUNT

Stab Cells	: 04	%	1-5 %
Neutrophils	: 56	%	40- 60 %
Lymphocytes	: 32	%	20 - 45 %
Eosinophils	: 01	%	1 - 6 %
Monocytes	: 07	%	0 - 10 %
Basophils	: 00	%	0 - 1 %
Abnormal Cells	: Nil		

SMEAR EXAMINATION

RBC Morphology	: Mild Hypochromia + in RBCs , Microcytes + , Mild Anisocytosis , and Poikilocytosis +
W.B.C Morphology	: Within Normal Limits
Platelets on Smear	: Adequate
Parasites	: Absent
Blood Group	: 'B' Rh Positive



Pathologist

Dr. Prasad Netravalkar
MBBS, MD (Bom)
GMC Reg. No. 1294

We Care

All Diagnostic facilities under one roof in Panaji centre - Lab, ultrasound, X ray, ECG, TMT, ECHO

DR. NETRAVALKAR'S ASHWINI PATHOLOGY LABORATORY

(For all investigation in Histopathology, Cytopathology, Haematology, Clinical Pathology, Microbiology & Hormonal Chemistry)

Consultant Pathologist **Dr. Prasad Netravalkar** MBBS, MD (Path) BOM

(HOME COLLECTION FACILITY AVAILABLE)

Panaji : 1st, Floor, Rizvi Sadan, Above Saroj Emporium, Near Inox Theatre, Opp. Municipal Market, Panaji.
Ph.: 2229142, 8407912840, 8390242524

E-mail : ashwinilabpanaji@gmail.com, drprasadnetravalkar@gmail.com

Mapusa : F8, Ramchandra Chambers, 1st Floor, Mapusa Clinic Road, Mapusa - Bardez, Goa. Ph. 2252320, 2250709

Sanquelim : 1st floor, Shanta Commercial Complex, Sanquelim - Goa. Ph.: 2364524, 9067292714

Pt.No. : 69 180324

Pt.Name : - Kamble Seema Shankar

Age : 37 Yrs. Sex : F

Ref. By : -

Date : 18-03-2024

		<u>Normal Range</u>
Fasting Blood Sugar	: 102.0 mg/dl	70-110 mg/dl
2 Hrs. Blood Sugar	: 110.0 mg/dl	110-140 mg/dl


GLYCOSYLATED HAEMOGLOBIN IN BLOOD (HPLC METHOD)

HbA1C : 5.80 %

Mean Blood Glucose : 119 mg %

INTERPRETATION:

	HbA1c %
NORMAL	Below 6.5 %
GOOD DIABETIC CONTROL	6.5 % - 7.5 %
FAIR CONTROL	7.5 % - 8.0 %
UNSATISFACTORY CONTROL	8.0 % - 10.0 %
POOR CONTROL	Above 10.0 %



Pathologist

Dr. Prasad Netravalkar
MBBS, MD (Bom)
GMC Reg No. 1294

We Care

All Diagnostic facilities under one roof in Panaji centre - Lab, ultrasound, X ray, ECG, TMT, ECHO

DR. NETRAVALKAR'S ASHWINI PATHOLOGY LABORATORY

(For all investigation in Histopathology, Cytopathology, Haematology, Clinical Pathology, Microbiology & Hormonal Chemistry)

Consultant Pathologist **Dr. Prasad Netravalkar** MBBS, MD (Path) BOM

(HOME COLLECTION FACILITY AVAILABLE)

Panaji : 1st, Floor, Rizvi Sadan, Above Saroj Emporium, Near Inox Theatre, Opp. Municipal Market, Panaji.
Ph.: 2229142, 8407912840, 8390242524

E-mail : ashwinilabpanaji@gmail.com, drprasadnetravalkar@gmail.com

Mapusa : FS, Ramchandra Chambers, 1st Floor, Mapusa Clinic Road, Mapusa - Bardez, Goa. Ph.: 2252320, 2250709

Sanquelim : 1st floor, Shanta Commercial Complex, Sanquelim - Goa. Ph.: 2364524, 9067292714

Pt.No. : 69 180324

Pt.Name : - Kamble Seema Shankar

Age : 37 Yrs. Sex : F

Ref. By : -

Date : 18-03-2024


Normal Range

BIOCHEMISTRY REPORTS

Blood Urea	: 17.0 mg/dl	15 - 40 mg/dl
Blood Urea Nitrogen	: 7.94 mg/dl	5 - 21 mg/dl

KIDNEY FUNCTION TESTS

S. Creatinine	: 0.82 mg/dl	0.5 - 1.2 mg/dl
S. Uric Acid.	: 4.70 mg/dl	1.5 - 6.0 mg/dl
S. Sodium	: 141.0 mEq/L	135 - 155 mEq/L
S. Potassium	: 3.90 mEq/L	3.5 - 5.5 mEq/L
S. Chlorides	: 107.0 mEq/L	99 - 108 mEq/L



(Signature)
Pathologist

Dr. Prasad Netravalkar
MBBS, MD (Bom)
GMC Reg. No. 1294

We Care

All Diagnostic facilities under one roof in Panaji centre - Lab, ultrasound, X ray, ECG, TMT, ECHO

DR. NETRAVALKAR'S ASHWINI PATHOLOGY LABORATORY

(For all investigation in Histopathology, Cytopathology, Haematology, Clinical Pathology, Microbiology & Hormonal Chemistry)

Consultant Pathologist : **Dr. Prasad Netravalkar** MBBS, MD (Path) BOM

(HOME COLLECTION FACILITY AVAILABLE)

Panaji : 1st, Floor, Rizvi Sadan, Above Saroj Emporium, Near Inox Theatre, Opp. Municipal Market, Panaji.

Ph.: 2229142, 8407912840, 8390242524

E-mail : ashwinilabpanaji@gmail.com, drprasadnetravalkar@gmail.com

Mapusa : F8, Ramchandra Chambers, 1st Floor, Mapusa Clinic Road, Mapusa - Bardez, Goa. Ph.: 2252320, 2250709

Sanquelim : 1st floor, Shanta Commercial Complex, Sanquelim - Goa. Ph.: 2364524, 9067292714

Pt.No. : 69 180324

Pt.Name : - Kamble Seema Shankar

Age : 37 Yrs. Sex : F

Ref. By : -

Date : 18-03-2024

Normal Range

LIVER FUNCTION TEST

S. Bilirubin (Total)	: 0.28	mg/dl	0 - 1 mg/dl
S. Bilirubin (Direct)	: 0.18	mg/dl	0 - 0.25 mg/dl
S. Bilirubin (Indirect)	: 0.1	mg/dl	0 - 0.75 mg/dl
S.G.O.T	: 28.0	U/L	0 - 42 U/L
S.G.P.T	: 21.0	U/L	0 - 42 U/L
S. Alkaline Phosphatase	: 90.0	IU/L	15 - 112 IU/L
GGTP	: 20.0	U/L	9-37 U/L
Total Proteins	: 6.81	g/dl	6.0 - 10.0 g/dl
S. Albumin	: 3.91	gm%	3.2 - 5.5 gm%
S. Globulin	: 2.9	g/dl	2.3 - 3.5 g/dl
A/G Ratio	: 1.3 : 1		



(Signature)
Pathologist

Dr. Prasad Netravalkar
MBBS, MD (Bom)
GMC Reg. No. 1294

We Care

All Diagnostic facilities under one roof in Panaji centre - Lab, ultrasound, X ray, ECG, TMT, ECHO

DR. NETRAVALKAR'S ASHWINI PATHOLOGY LABORATORY

(For all investigation in Histopathology, Cytopathology, Haematology, Clinical Pathology, Microbiology & Hormonal Chemistry)

Consultant Pathologist **Dr. Prasad Netravalkar** MBBS, MD (Path) BOM

(HOME COLLECTION FACILITY AVAILABLE)

Panaji : 1st, Floor, Rizvi Sadan, Above Saroj Emporium, Near Inox Theatre, Opp. Municipal Market, Panaji.

Ph.: 2229142, 8407912840, 8390242524

E-mail : ashwinilabpanaji@gmail.com, drprasadnetravalkar@gmail.com

Mapusa : F8, Ramchandra Chambers, 1st Floor, Mapusa Clinic Road, Mapusa - Bardez, Goa. Ph.: 2252320, 2250709

Sanquelim : 1st floor, Shanta Commercial Complex, Sanquelim - Goa. Ph.: 2364524, 9067292714

Pt.No. : 69 180324

Pt.Name : - Kamble Seema Shankar

Age : 37 Yrs. Sex : F

Ref. By : -

Date : 18-03-2024

EXAMINATION OF URINE

PHYSICAL EXAMINATION

Quantity : 20 ml
Colour : Pale Yellow
Appearance : Slightly Hazy
pH : 6.5
Specific Gravity : 1.010

CHEMICAL EXAMINATION

Proteins : Present (+)
Glucose : Absent
Ketone Bodies : Absent
Bile Salts : Absent
Bile Pigments : Absent
Occult Blood : Present (+)
Urobilinogen : Normal

MICROSCOPIC EXAMINATION [As per hpf]


Epithelial Cells : 8 - 10 /hpf
Pus Cells : 3 - 4 /hpf
Red Blood Cells : 10 - 12 /hpf
Casts : Absent
Crystals : Absent

OTHER FINDINGS

Bacteria : Present (Trace)



Pathologist



Dr. Prasad Netravalkar
MBBS, MD (Bom)
GMC Reg. No. 1294

We Care

All Diagnostic facilities under one roof in Panaji centre - Lab, ultrasound, X ray, ECG, TMT, ECHO

ultrasound ECHO

DR. NETRAVALKAR'S ASHWINI PATHOLOGY LABORATORY

(For all investigation in Histopathology, Cytopathology, Haematology, Clinical Pathology, Microbiology & Hormonal Chemistry)

Consultant Pathologist : **Dr. Prasad Netravalkar** MBBS, MD (Path) BOM

(HOME COLLECTION FACILITY AVAILABLE)

Panaji : 1st, Floor, Rizvi Sadan, Above Saroj Emporium, Near Inox Theatre, Opp. Municipal Market, Panaji.
Ph.: 2229142, 8407912840, 8390242524

E-mail : ashwinilabpanaji@gmail.com, drprasadnetravalkar@gmail.com

Mapusa : F8, Ramchandra Chambers, 1st Floor, Mapusa Clinic Road, Mapusa - Bardez, Goa. Ph.: 2252320, 2250709

Sanquelim : 1st floor, Shanta Commercial Complex, Sanquelim - Goa. Ph.: 2364524, 9067292714

Patient Name : KAMBLE SEEMA SHANKAR

Age / Gender : 37 / Female

Patient ID : 31373

Source : DIRECT

Referral : SELF

Reporting Time : Mar 18, 2024, 02:09 p.m.


Sample ID :



240780021

Test Description	Value(s)	Reference Range	Unit
Thyroid Profile			
T3 (Total) Method : Serum ECL	1.80	1.30 - 3.10	nmol/l
T4 (Total)* Method : Serum ECL	95.97	66.0 - 181.0	nmol/l
TSH(Ultrasensitive)* Method : Serum ECL	6.47	0.270 - 4.20	uIU/ml

END OF REPORT



Pathologist

Dr. Prasad Netravalkar
MBBS, MD (Bom)
GMC Reg. No. 1294

We Care

Page 1 of 1

All Diagnostic facilities under one roof in Panaji centre - Lab, ultrasound, X ray, ECG, TMT, ECHO

DR. NETRAVALKAR'S ASHWINI PATHOLOGY LABORATORY

(For all investigation in Histopathology, Cytopathology, Haematology, Clinical Pathology, Microbiology & Hormonal Chemistry)

Consultant Pathologist : **Dr. Prasad Netravalkar** MBBS, MD (Path) BOM

(HOME COLLECTION FACILITY AVAILABLE)

Panaji : 1st, Floor, Rizvi Sadan, Above Saroj Emporium, Near Inox Theatre, Opp. Municipal Market, Panaji.

Ph.: 2229142, 8407912840, 8390242524

E-mail : ashwinilabpanaji@gmail.com, drprasadnetravalkar@gmail.com

Mapusa : F8, Ramchandra Chambers, 1st Floor, Mapusa Clinic Road, Mapusa - Bardez, Goa. Ph.: 2252320, 2250709

Sanquelim : 1st floor, Shanta Commercial Complex, Sanquelim - Goa. Ph.: 2364524, 9067292714

Patient Name : KAMBLE SEEMA SHANKAR

Referral : SELF

Age / Gender : 37 / Female

Reporting Time : Mar 18, 2024, 02:09 p.m.

Patient ID : 31373

Sample ID :



Source : DIRECT

Test Description	Value(s)	Reference Range	Unit
------------------	----------	-----------------	------

Vitamin D3 Total


Vitamin D3 Total	< 3.0	30.0 - 100.0	ng/ml
------------------	-------	--------------	-------

Method : ECL

Interpretations

- Cholicalciferol (VitaminD3) is synthesized in the skin from 7 dehydrocholesterol in response to sunlight, some part also comes from Diet and supplements. Ergocalciferol(Vitamin D2) comes essentially from diet and supplements.
- Both Cholicalciferol and Ergocalciferol are converted in the liver to 25 OH Vitamin D. 25 OH Vitamin D is further hydroxylated in the kidneys to produce 1, 25 Dihydroxy Vitamin D.
- The measurement of 1,25 Dihydroxy Vitamin D is indicated in several disorders affecting calcium metabolism such as sarcoidosis, renal failure, hyper or hypo -parathyroidism, rickets, tumour associated hypercalcemia, vitamin resistant dysfunction and treatment with anti-convulsive medication.

END OF REPORT



Pathologist

Dr. Prasad Netravalkar
- MBBS, MD (Bom)
GMC Reg. No. 1294

Page 1 of 1

We Care

All Diagnostic facilities under one roof in Panaji centre - Lab, ultrasound, X ray, ECG, TMT, ECHO

DR. NETRAVALKAR'S ASHWINI PATHOLOGY LABORATORY

(For all investigation in Histopathology, Cytopathology, Haematology, Clinical Pathology, Microbiology & Hormonal Chemistry)

Consultant Pathologist : **Dr. Prasad Netravalkar** MBBS, MD (Path) BOM.

(HOME COLLECTION FACILITY AVAILABLE)

Panaji : 1st, Floor, Rizvi Sadan, Above Saroj Emporium, Near Inox Theatre, Opp. Municipal Market, Panaji.

Ph.: 2229142, 8407912840, 8390242524

E-mail : ashwinilabpanaji@gmail.com, drprasadnetravalkar@gmail.com

Mapusa : F8, Ramchandra Chambers, 1st Floor, Mapusa Clinic Road, Mapusa - Bardez, Goa. Ph.: 2252320, 2250709

Sanquelim : 1st floor, Shanta Commercial Complex, Sanquelim - Goa. Ph.: 2364524, 9067292714

Patient Name : KAMBLE SEEMA SHANKAR

Referral : SELF

Age / Gender : 37 / Female

Reporting Time : Mar 18, 2024, 02:09 p.m.

Patient ID : 31373

Sample ID :



Source : DIRECT

Test Description	Value(s)	Reference Range	Unit
------------------	----------	-----------------	------

Vitamin B12, Cynacobalamin

Vitamin B12-Cyanocobalamin	219.0	187 - 883	pg/mL
----------------------------	-------	-----------	-------

Method : Serum, ECLIA

Interpretation:


1. Vit B12 levels are decreased in megaloblastic anemia, partial/total gastrectomy, pernicious anemia, peripheral neuropathies, chronic alcoholism, senile dementia, and treated epilepsy.
2. An associated increase in homocysteine levels is an independent risk marker for cardiovascular disease and deep vein thrombosis.
3. HoloTranscobalamin II levels are a more accurate marker of active VitB12 component.

Note: Patients on Biotin supplement may have interference in some immunoassays. With individuals taking high dose Biotin (more

than 5 mg per day) supplements, at least 8-hour wait time before blood draw is recommended.

Ref: Arch Pathol Lab Med—Vol 141, November 2017

END OF REPORT



(Handwritten signature)

Pathologist

Dr. Prasad Netravalkar

MBBS, MD (Bom)

GMC Reg. No. 1294

Page 1 of 1

We Care

All Diagnostic facilities under one roof in Panaji centre - Lab. ultrasound, X ray, ECG, TMT, ECHO

MER- MEDICAL EXAMINATION REPORT

Date of Examination	18th march 2024		
NAME	Kamble Seema Shantanu		
AGE	37	Gender	F
HEIGHT(cm)	164	WEIGHT (kg)	73
B.P.	110/70 mmHg		
ECG	Normal		
X Ray	Normal		
Vision Checkup	Color Vision : Normal		
	Far Vision Ratio : 6/6		
	Near Vision Ratio : 6/6		
Present Ailments	-NO-		
Details of Past ailments (If Any)	-NO-		
Comments / Advice : She /He is Physically Fit	She is Physically fit		

Signature with Stamp of Medical Ex



CERTIFICATE OF MEDICAL FITNESS

This is to certify that I have conducted the clinical examination

of Kamble Seema Shankar on 18th March 2024

After reviewing the medical history and on clinical examination it has been found that he/she is

• Medically Fit

• Fit with restrictions/recommendations

Though following restrictions have been revealed, in my opinion, these are not impediments to the job.

1.....

2.....

3.....

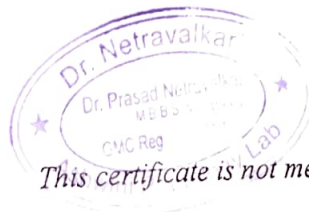
However the employee should follow the advice/medication that has been communicated to him/her.


Review after _____

• Currently Unfit.

Review after _____ recommended

• Unfit



Dr. 
Medical Officer
The Apollo Clinic, (Location)

This certificate is not meant for medico-legal purposes

भारत सरकार
Government of India

सेमा शंकर कांबळे
Seema Shankar Kamble
जन्म तारीख / DOB : 15/11/1986
स्त्री / Female




7023 5098 1351

माझे आधार, माझी ओळख

Kamble

MR

भारतीय विशिष्ट ओळख प्राधिकरण
Unique Identification Authority of India

आधार

पत्ता खडस, ता- माळशिरस, खुदस,
सोलापूर, खुदस, महाराष्ट्र, 413113


Address: Khudus, Tal- Malshiras, Khudus,
Solapur, Khudus, Maharashtra, 413113


7023 5098 1351

www.uda.gov.in

Dr. Netravati
Dr. Pra...
www.uda.gov.in



 GPS Map Camera



Panañi, Goa, India
B 165, New Municipal Market, Panañi, Goa 403001, India
Lat 15.498474°
Long 73.822397°
18/03/24 08:32 AM GMT +05:30

201,202,203, Rizvi Sadan, 2nd Floor, Near Municipal Market, Next to Vaidya Hospital, Panaji - Goa.

Tel.: 0832 2238122 | Email : drashanetravalkar@gmail.com

NAME: MS .SEEMA KAMBLE

AGE: 37/YRS

REF BY: DR. SELF

DATE: 18/03/2024

SEX: F

SONOMAMMOGRAPHY OF BOTH BREASTS

BOTH BREASTS:

Normal fibroglandular and fatty tissue is seen.

Grossly no mass or calcification or cystic lesion is seen.


No dilated ducts are seen.

Axillary tail and areolar region appears normal.

No Lymphnodes are seen in axillary region.

Impression : Normal study.

With regards,



DR.ASHADEVI NETRAVALKAR,MD
RADIOLOGIST

DR. ASHADEVI NETRAVALKAR

MBBS., MD, AFIH

Consultant Radiologist

2nd Floor, Rizvi Sadan Panaji

Tel: 0832-2238122 | Email: drashanetravalkar@gmail.com

201,202,203, Rizvi Sadan, 2nd Floor, Near Municipal Market, Next to Vaidya Hospital, Panaji - Goa.
Tel.: 0832 2238122 | Email : drashanetravalkar@gmail.com

NAME: MS .SEEMA KAMBLE
AGE: 37/YRS
REF BY: DR. SELF

DATE: 18/03/2024
SEX: F

ULTRASONOGRAPHY OF ABDOMEN AND PELVIS

LIVER – It shows normal echotexture and size. No focal lesions are seen. Intrahepatic biliary and portal radicals appear normal. Length of liver is 11.2cm.PV -9mm.

PANCREAS— It shows normal echotexture and size. No focal lesions are seen.

GALL BLADDER---It is moderately distended. No calculus is seen. Pericholecystic space is normal.CBD is normal.

SPLEEN----- It shows normal echotexture and size. Length of spleen is 7.5cm.

BOTH KIDNEYS Both kidneys show normal echotexture and size. Perirenal space is normal.

Corticomedullary differentiation is seen well .No calculus or hydronephrosis is seen .

Right kidney--measures 10.5cm x 4cms .

Left kidney—measures 10.6cms x4cms.

Urinary Bladder is well distended .No calculus and mass is seen.Both vesicoureteric junctions are normal.

UTERUS : It is anteverted and It measures 8.3cms x5.1cms x 4cms.

Myometrium show normal echotexture.No mass is seen.

Endometrial thickness is 12mm.An echogenecity measuring 9mm is seen in endometrial cavity.?Polyp.

Both ovaries show normal echotexture and size.


Right ovary—measures 3.9cms x1.9cms . Left ovary -measures 3.1cms x 2.8cms .

No adnexal mass is seen.

No free fluid is seen in pelvis.Plenty of bowel gases are seen.

Impression : ?Endometrial polyp.To follow after menses.

With regards,



DR.ASHADEVI NETRAVALKAR,MD
RADIOLOGIST

DR. ASHADEVI NETRAVALKAR, MD
RADIOLOGIST
Consultant Radiologist & Sonologist
2nd Floor, Rizvi Sadan, Panaji - Goa.
Tel: 0832 2238122 | Email: drashanetravalkar@gmail.com

201,202,203, Rizvi Sadan, 2nd Floor, Near Municipal Market, Next to Vaidya Hospital, Panaji - Goa.
Tel.: 0832 2238122 | Email : drashanetravalkar@gmail.com

NAME: MS .SEEMA KAMBLE
AGE: 37/YRS
REF BY: DR. SELF

DATE: 18/03/2024
SEX: F

X-RAY CHEST--- PA VIEW

Lung fields are clear.

Both costophrenic angles are clear.

Cardiac size is normal

Both domes of diaphragm are normal.

Rib cage is normal.

IMPRESSION : Normal study

With regards,



RADIOLOGIST

DR. ASHADEVI NETRAVALKAR, MD

DR. ASHADEVI NETRAVALKAR

MBBS., MD, AFIH

Consultant Radiologist & Sonologist

2nd Floor, Rizvi Sadan, Panaji

Goa

201,202,203, Rizvi Sadan, 2nd Floor, Near Municipal Market, Next to Vaidya Hospital, Panaji - Goa.

Tel.: 0832 2238122 | Email : drashanetravalkar@gmail.com

Cardiology Report

Page 1/2

ASHWINI LABORATORY

Patient / Exam Information

Date of Exam: 18.03.2024


Patient ID VS8802280-24-03-18-1
Name SEEMA KAMBLE 37
DOB, Age
Sex Female
Height
Weight
BSA
HR

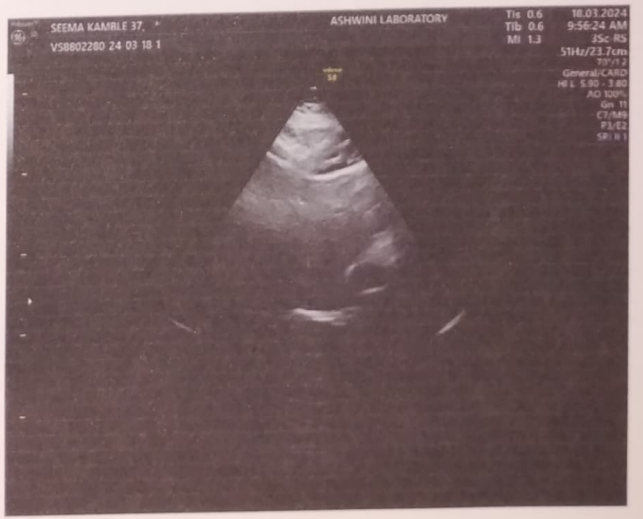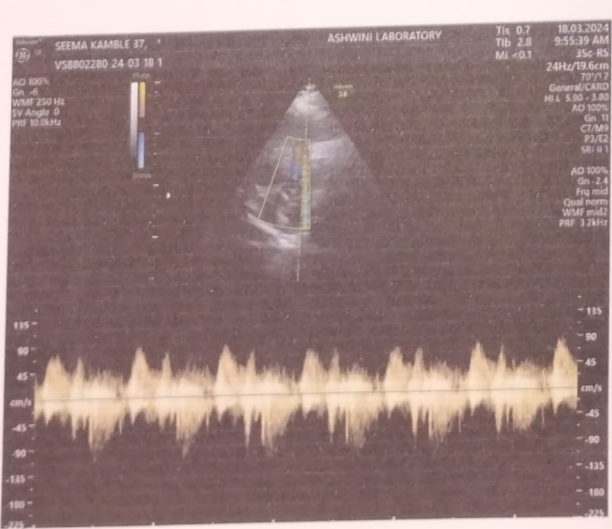
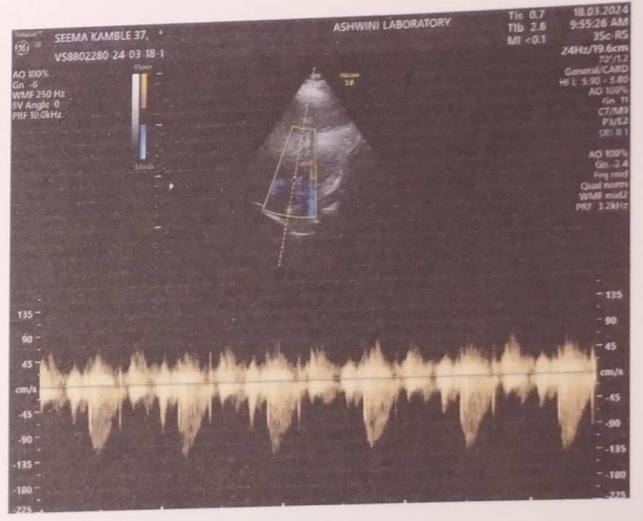
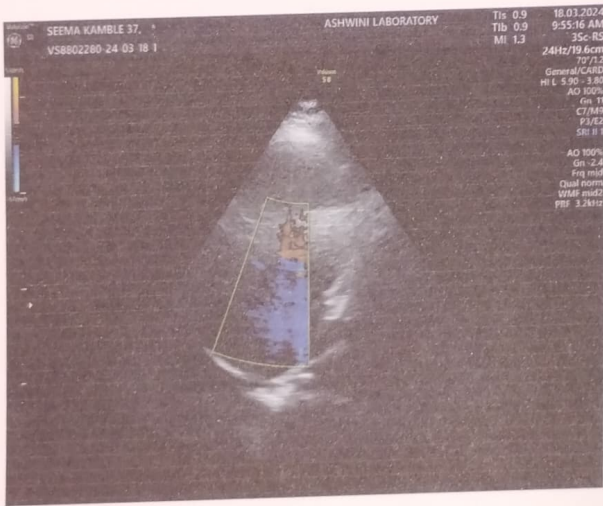
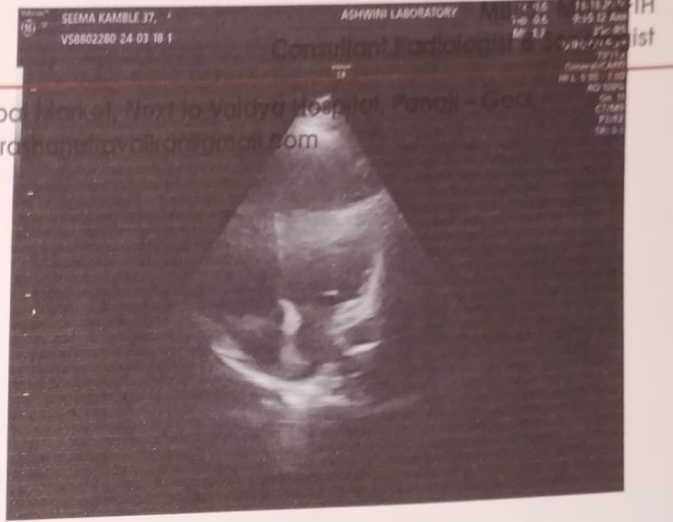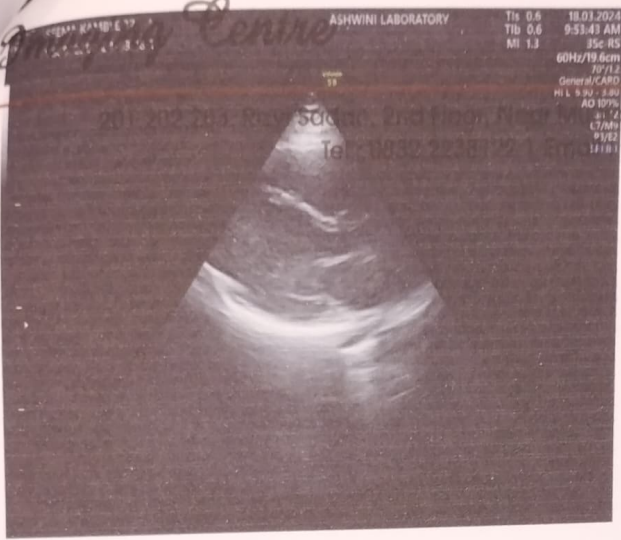Perf. Phys. Ref. Phys. Sonographer
Comment Indication

M-Mode Measurements	Value	m1	m2	m3	m4	m5	m6	Meth.
Left Ventricle								
IVSd	0.60 cm	0.60						avg.
LVDd	4.64 cm	4.64						avg.
LVPWd	0.70 cm	0.70						avg.
IVSs	1.10 cm	1.10						avg.
LVDs	3.14 cm	3.14						avg.
LVPWs	1.70 cm	1.70						avg.
EDV (Teich)	99.330 ml	99.330						
EDV (Cubed)	99.897 ml	99.897						
ESV (Teich)	39.118 ml	39.118						
ESV (Cubed)	30.959 ml	30.959						
SV (Teich)	60.212 ml	60.212						
SV (Cube)	68.938 ml	68.938						
EF (Teich)	60.62 %	60.62						
EF (Cube)	69.01 %	69.01						
Fract. Short.	32.33 %	32.33						
LV Mass	100.47 g	100.47						
AV/IA								
Ao Root Diam.	2.20 cm	2.20						avg.
LA Diam.	2.35 cm	2.35						avg.

Comment

NORMAL CARDIAC CHAMBERS DIMENSIONS. NORMAL BI VENTRICLE SYSTOLIC FUNCTION. NO REGIONAL WALL MOTION ABNORMALITIES. VALVES ARE NORMAL. AORTIC ROOT IS NORMAL. PERICARDIUM IS NORMAL.

 1/2
18.03.2024 9:58:44 AM



Dr. Netravalkar's Imaging Centre

Dr. Ashadevi Netravalkar

MBBS., MD, AFIH

Consultant Radiologist & Sonologist

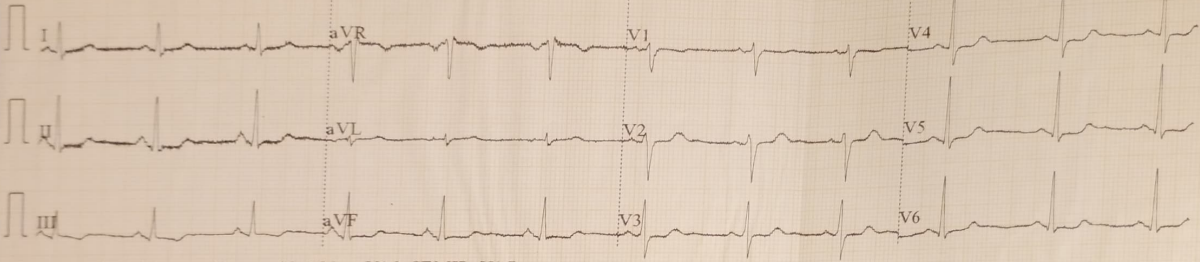
Name SEEMA KAMBLE
Age 37 M/F M Date : 18-03-24
Investigation ECG
Ref. by Dr. _____

201,202,203, Rizvi Sadan, 2nd Floor, Near Municipal Market,
Next to Vaidya Hospital, Panaji - Goa.

Tel.: 0832 2238122 | Email : drashanetravalkar@gmail.com

Timing : 8.00 am to 1.00 pm | 4.00 pm to 7.00 pm

SPL
ID: 4292 18-03-2024 22:31:37



0.5-100Hz 25mm/s 10mm/mV ♥86 V1.0 SEMIP V1.7

ID: 4292

Female / mmHg
37Years
cm kg

Scumble

HR : 69 bpm
P : 103 ms
PR : 126 ms
QRS : 100 ms
QT/QTc : 397/426 ms
P/QRS/T : 67/67/39 °
RV5/SV1 : 1.417/0.570 mV

266 Noor
[Signature]
18/3



DR. SIGN.