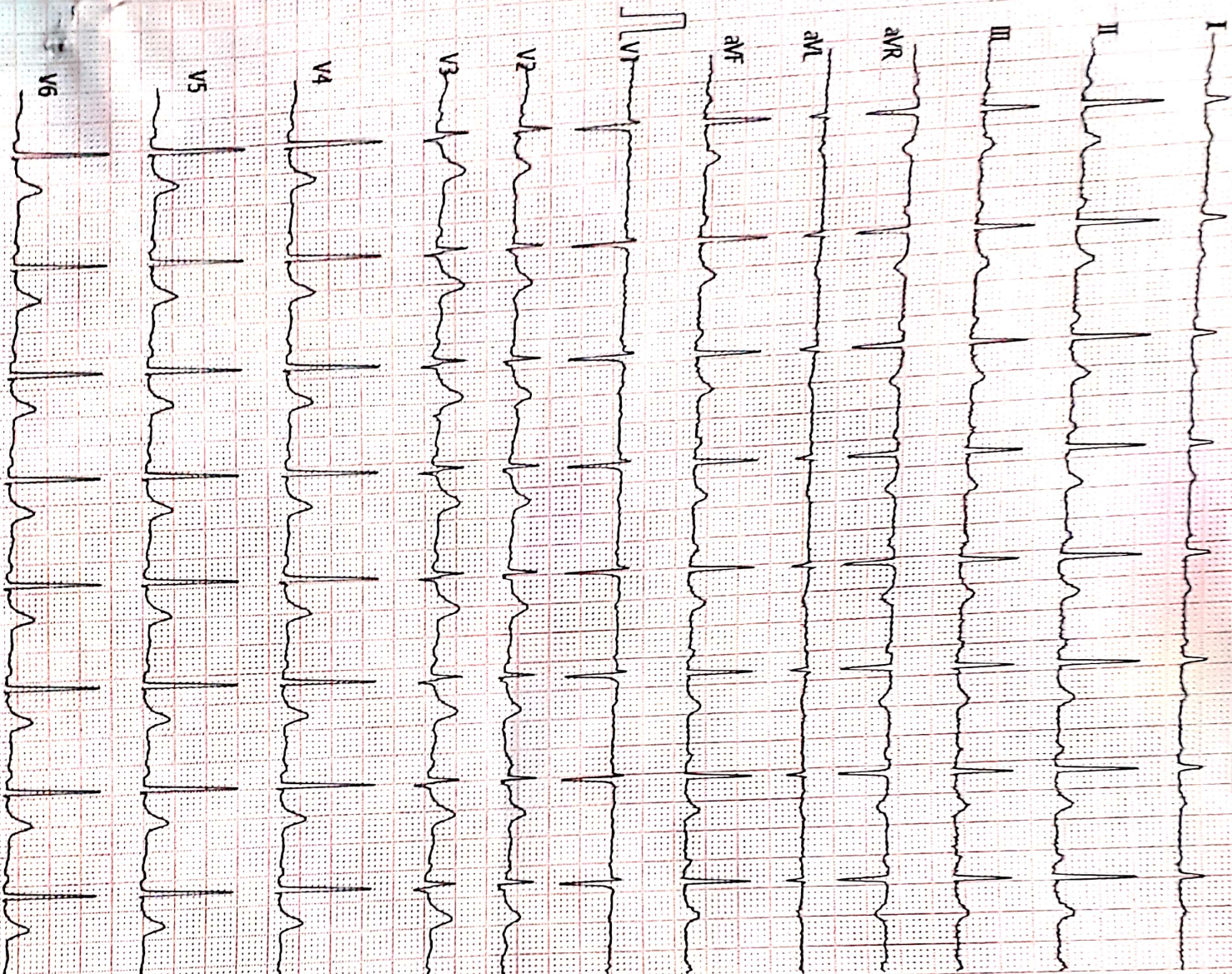

Vent. Rate (bpm) : 85

P-R Int. (ms) : 113

P-QRS/T Int. (ms) : 85 91 168

QT/QTc Int. (ms) : 350 421

P/QRS/T Axis (Deg.) : 68 75

RV1/SV5 Amp. (mV) : 0.16 0.03

RV6/SV1 Amp. (mV) : 1.47 0.82

V2.33 Technician :

ECG Analysis Result:

800 Normal Sinus Rhythm

401 Short P-R Interval

\*\*\* Borderline Normal ECG \*\*\*

Note : Unconfirmed Report Need to Revs



ST LEVEL (mV)

I	II	III	aVR	aVL	aVF
+0.00	+0.00	+0.00	+0.00	+0.00	+0.00
V1	V2	V3	V4	V5	V6
+0.02	+0.03	+0.04	+0.00	+0.01	+0.01



CHASREEE JI > 775510089161 F 30Y

755 cm/ks 55 /55

 <p>भारत सरकार Government of India</p>	 <p>सूचना AADHAAR</p>
<p>भारतीय विशिष्ट पहचान प्राधिकरण Unique Identification Authority of India</p> <p>संलग्नक संख्या: Enrollment No.: 0645/02622/19023</p> <p>To: Jaspreet Kaur Jaspreet Kaur C/O Harjit Singh Kalia Street No. 04 Raja Park Jalandhar House No. 250 Jalandhar Nagar Jalandhar Jalandhar Region - 151004 8302403211</p> <p>आपका आधार क्रमांक / Your Aadhaar No. : <b>3908 0112 1790</b> VD : 9128 6191 8727 2344</p> <p>मेरा आधार, मेरी पहचान</p>	<p>सूचना</p> <ul style="list-style-type: none"> <li>आधार पहचान का अर्थ है, नागरिकता का नहीं।</li> <li>पुष्टि QR कोड / ऑनलाइन XML / ऑनलाइन प्रमाणीकरण से पहचान प्रमाणित करें।</li> <li>यह एक इलेक्ट्रॉनिक प्रतिलिपि दस्तावेज है।</li> </ul> <p>INFORMATION</p> <ul style="list-style-type: none"> <li>Aadhaar is a proof of identity, not of citizenship.</li> <li>Verify identity using Secure QR Code/ Offline XML/ Online Authentication.</li> <li>This is electronically generated letter.</li> </ul> <p>आधार देश भर में मान्य है। आधार कई सरकारी और नि-सरकारी सेवाओं को प्राप्त करने में मदद करता है। आधार में परिवर्तन कर और ईमेल ID अपडेट करें। आधार को अपने स्मार्ट फोन पर रखें, mAadhaar App के साथ।</p> <p>Aadhaar is valid throughout the country Aadhaar helps you avail various Government and non-Government services easily Keep your mobile number &amp; email ID updated in Aadhaar. Carry Aadhaar in your smart phone – use mAadhaar App.</p>
<p>आधार संख्या</p> <p>Jaspreet Kaur Jaspreet Kaur आधार ID: 0301/1904 लिंग FEMALE</p> <p>3908 0112 1790 VD : 9128 6191 8727 2344</p> <p>मेरा आधार, मेरी पहचान</p>	<p>भारतीय विशिष्ट पहचान प्राधिकरण Unique Identification Authority of India</p> <p>सूचना</p> <p>आधार संख्या</p> <p>Jaspreet Kaur Jaspreet Kaur आधार ID: 0301/1904 लिंग FEMALE</p> <p>3908 0112 1790 VD : 9128 6191 8727 2344</p> <p>मेरा आधार, मेरी पहचान</p>

*Jaspreet*

Name	:	Jaspreet kaur	Age	:	30yrs. / F
Thanks To	:	Mediwheel wellness	Date	:	27/1/2024

**X-RAY CHEST (PA VIEW)**

Both lung fields appear normal.

No c/o Koch's lesion or consolidation seen.

Both CP angles appear clear.

Both domes of diaphragm appear normal.

Heart size and aorta are within normal limits.

Bony thorax under vision appears normal.

Both hila appear normal.



**(This report is not valid for any Medico-legal purpose)**

**2-B, Ground Floor, Court Choraha, Main Road Tehsil Ke Samne, Udaipur 313001 (Raj.)**  
**Mob. : 7229961115, 7229970005, 7229901188**  
**(24 x 7 Customer Service) Email : Kshipralabsudaipur@gmail.com**

MRS. Jaspreet

30/F

27/01/24

ClO for Eye check up.

DVA ← 6/6  
6/6

NVA ← M/6  
M/6

Colour vision - (N)

  
**DR. SHARVA PANDYA**  
MBBS, MS (OPHTH.)  
RMC : 021537 (MBBS) 007516 (MS.)  
JAI DRISHTI EYE HOSPITAL  
UDAIPUR (RAJ.)

Name	: Jaspreet kaur	Age	: 30Yrs. / F
Thanks To	: Mediwheel	Date	: 27/1/2024

## ULTRASOUND STUDY OF WHOLE ABDOMEN

### LIVER:

Liver is normal in size, shape & echotexture. No focal mass lesion is seen. Intra hepatic biliary radicles are normal. Portal vein is normal in caliber.

### GALL BLADDER :

Gall bladder is well distended. The wall thickness appears normal. No evidence of calculus or mass lesion is seen. C.B.D. appears normal.

### PANCREAS :

Pancreas is normal in size, shape & echotexture. No focal mass lesion is seen.

### SPLEEN :

Spleen is normal in size, shape & echotexture. No focal mass lesion is seen.

### BOTH KIDNEYS :

Both kidneys are normal in size, shape & echotexture. Renal parenchyma appears normal. No evidence of hydronephrosis, calculus or cortical scarring is seen in either kidney.

Right kidney measures : 9.3x4.0 cms.

Left kidney measures : 10.0 x 4.1 cms.

### URINARY BLADDER :

Urinary bladder is well distended and appears normal in contour. The wall thickness appears normal.

### UTERUS :

Uterus is AVAF, normal in size, shape and echotexture. It measures 6.9 x 4.4 x 3.8 cms. Endometrial appears normal and measures 5.8 mm.

### BOTH OVARIES :

Both ovaries are normal in size, shape and echotexture.

Right ovary measures: 2.8 x 1.8 cms.


Left ovary measures: 3.4 x 1.8 cms.

No obvious abdominal lymphadenopathy is seen.

No free fluid is seen in peritoneal cavity.

### OPINION:

- No significant abnormality is seen.



Dr Bharat jain  
MD (Radio-Diagnosis)  
Consultant Radiologist

(This report is not valid for any Medico-legal purpose)

ENCL:- PCPNDT Registration Certificate is printed on the back side of this report.

2-B, Ground Floor, Court Choraha, Main Road Tehsil Ke Samne, Udaipur 313001 (Raj.)

Mob. : 7229961115, 7229970005, 7229901188

(24 x 7 Customer Service) Email : Kshipralabsudaipur@gmail.com

## MER-MEDICAL EXAMINATION REPORT

DATE OF EXAMINATION	27/01/2024
NAME	JASPREET KAUR
AGE	30YRS / FEMALE
HEIGHT	159CM
WEIGHT	53 KG
BP	118 / 72
ECG	NORMAL
X-RAY	NORMAL
PRESENT AILMENTS	NO
DETAILS OF PAST AUMENTS (IF AY)	NO
COMMENTS/ADVICE :SHE/HE IS PHYSICALLY FIT	YES



Signature With Stamp Of Medical Examiner



**TEST REPORT**

Reg. No : 2401100842

Name : JASPREET KOUR

Age : 30 Years / FEMALE

Ref. By :-

Client :

Reg. Date : 27-Jan-2024 18:42

Collected On : 27-Jan-2024 18:42

Approved On : 27-Jan-2024

Printed On : 27-Jan-2024

**PAP SMEAR**

Adequacy : Satisfactory  
Maturity Index : 10/30/60  
Inflammation : + + +  
Bacilli : ++  
RBC : Absent  
Endocervical Cells : Present  
Dysplasia : NIL  
Clue Cells : Present  
Class : II Inflammatory with shift in flora.  
Bethesda category : NILM( Negative for Intraepithelial Lesion or Malignancy)

