

**DAKSH HOSPITAL**

396 - 397, Gandhi Nagar, Scheme No. 8, ALWAR -301001

Ref. No.

Date.....

MEDICAL EXAMINATION REPORT

Mediwheel (BOB)

Name: Mr. Hari Singh yadav      Age: 36 yrs      Sex: Male      Date: 27/04/2024

General Physical ExaminationHeight : 169 cm  
Pulse : 84 mt  
Respiration : 18/mtWeight : 80 kg  
BP : 120/70 mm/hg  
BMI : 28 kg/m<sup>2</sup>Systemic Exam:-

NORMAL

New # Calculated. (RF)

Dental Check up:-

NORMAL

Eye check-up:-

NORMAL

Skin Check up:-

NORMAL

ENT Check up:-

NORMAL

Impression:-

SGPT 41, TG 205, TSH 5.21, Grade I Fatty liver

Recommendation:① Life style modifications - Limit alcohol  
- Fat/Pred/Pan/Pow  
- Diet as

② HbSAt, HCV, ANA

③ Anti TSH After 1 month / Anti TPO Antibody

Dr. Mukesh Kumar Gupta  
MD Gen. Medicine  
Reg. No 5423/16262डॉ० मुकेश गुप्ता  
M.D.F.C.C.S.फिजिशियन एवं मधुमेह रोग विशेषज्ञ  
दक्ष हॉस्पिटल, अलवर  
रजि० नं०-5423/16262

## Results

Run Date 27/04/2024 09:20:47 AM

Operator DAKSH

Last Name

Sample ID 1

First Name MR HARISINGH

Department

Gender Male

Age

Physician DR. MUKESH GUPTA M.D

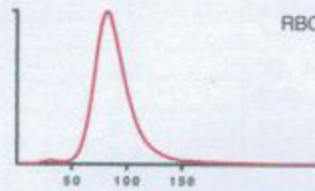
Patient ID AUTO\_PID21184

Type Man

Date of birth

Sample comments

				Range
RBC	5.12	*	10 <sup>6</sup> /μL	3.80 - 5.50
HGB	13.3		g/dL	13.0 - 17.0
HCT	45.6	*	%	39.0 - 52.0
MCV	89.1	*	μm <sup>3</sup>	76.0 - 100.0
MCH	25.9		pg	26.0 - 34.0
MCHC	29.0	L	g/dL	32.0 - 35.0
RDW-CV	17.6	H	%	11.0 - 16.0
RDW-SD	60.4	H	μm <sup>3</sup>	37.0 - 49.0



### Recommended actions


Slide review

### Susp. Pathologies

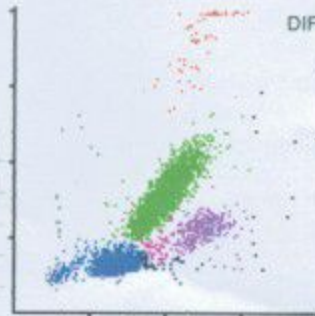
Anisocytosis

Macroplatelets

				Range
PLT	176	*	10 <sup>3</sup> /μL	150 - 450
PCT	0.27	*	%	0.15 - 0.40
MPV	15.2	H*	μm <sup>3</sup>	8.0 - 11.0
PDW	39.2	H*	μm <sup>3</sup>	11.0 - 22.0
P-LCC	115		10 <sup>3</sup> /μL	44 - 140
P-LCR	65.2	h	%	18.0 - 50.0



			Range		Range
WBC	7.65		10 <sup>3</sup> /μL		3.50 - 10.00
	#		Range	%	Range
NEU	4.18		1.60 - 7.00	54.9	40.0 - 75.0
LYM	3.10	h	1.00 - 3.00	40.6	20.0 - 45.0
MON	0.15		0.20 - 0.80	2.0	2.0 - 10.0
EOS	0.11		0.00 - 0.50	1.4	1.0 - 6.0
BAS	0.09		0.00 - 0.15	1.1	0.0 - 1.0
LIC	0.02		0.00 - 0.10	0.3	0.0 - 1.0



*Dr. R.S. Gupta*  
**Dr. R.S. GUPTA**  
 MD (Pathology) (MAHE)  
 RMC No. 7924/19778

# दक्ष हॉस्पिटल

396-397, गाँधी नगर स्कीम नं.8, अलवर

☎ 0144 - 2703340, 8824692704

E-mail : drmukeshgupta@yahoo.co.in

Date :- 27/04/2024

Name :- MR HARI SINGH

Age & Sex :- 36 Yrs / Male

Refd. :- Dr Mukesh Gupta M.D.

	TEST NAME	RESULT	REFERENCE RANGE	
	ESR	10	00 - 20 mm/hrs	
	Blood Group & Rh Factor	O POSITIVE		
	HbA1C	4.85	4 - 5.6%	
	Blood Sugar (F)	79.2	< 70 - 100 mg/dl	
	Blood Sugar (PP)	94.1	< 140 mg/dl	
	Urine Sugar (F)	NIL	-	
	Urine Sugar (PP)	-	-	
<b>LIVER</b>	S.Bilirubin Total	0.90	0.30 - 1.20 mg/dl	
	S.Bilirubin Direct	0.20	0.10 - 0.30 mg/dl	
	S.Bilirubin Indirect	0.70	0.30 - 0.90 mg/dl	
	S.G.O.T.	33	> 37 u/l	
	S.G.P.T.	41	> 40 u/l	
	S.Ak. Phosp.	188	80 - 306 u/l	
	G.G.T.	20	5 - 40 u/l	
	Total Protein	6.8	6.5 - 8.5 gm/dl	
	Albumin	3.7	3.8 - 5.4 gm/dl	
	Globulin	3.1	2.3 - 3.5 gm/dl	
	A/G Ratio	1.2	-	
	AST/ALT Ratio	0.8	-	
<b>KIDNEY</b>	Blood Urea	35.1	15 - 45 mg/dl	
	S.Creatinine	1.2	0.60 - 1.30 mg/dl	
	BUN	18.1	6 - 24 mg/dl	
	S.Uric Acid	5.1	M 3.1 - 7.0, F 2.5 - 5.6 mg/dl	
	BUN/Creatinine Ratio	18.1	-	
	Total Cholesterol	175.1	Up to 200 mg/dl	
<b>LIPID PROFILE</b>	S.HDL	44.1	30 - 70 mg/dl	
	S.LDL	90.1	Up to 170 mg/dl	
	S.VLDL	41.1	5.0 - 40 mg/dl	
	S. Triglycerides	205.1	Up to 170 mg/dl	
	LDL/HDL Ratio	2.04	-	
	Total Cholesterol/ HDL Ratio	3.9	-	
<b>THYROID</b>	T3	110.1	40 - 181 ng/dl	
	T4	5.29	4.6 - 10.5 µg/dl	
	TSH	5.21	0.30 - 5.0 mIU/l	
<b>URINE EXAMINATION</b>			<i>Microscopic Examination:</i>	
<b>General/Chemical Examination:</b>	Colour	Pale Yellow	RBC	Absent
	Reaction	Acidic	WBC	3 - 4
	Specific Gravity	QNS	Epithelial Cells	0 - 1
	Appearance	Clear	Cast	Absent
	Albumin	Nil	Crystal	Absent
	Sugar	Nil	Spermatozoa	Absent
			Amorphous Sediments	Absent
			Other	Absent
<b>X-RAY CHEST</b>	NORMAL STUDY			
<b>STOOL EXAMINATION</b>			<i>Microscopic Examination:</i>	
<b>General/Chemical Examination:</b>	Colour	-	RBC	-
	Consistency	-	WBC	-
			Ova & Parasites	-

*Dr. R.S. Gupta*  
**Dr. R.S. GUPTA**  
 MD (Pathology) (MAHE)  
 RMO No. 7924/19778

**TECHNOLOGIST**

All investigation have their own limitations regarding the sensitivity & specificity of individual assay procedures. Isolated laboratory investigations never confirm the final diagnosis of the disease. They only help in arriving at a diagnosis in conjunction with clinical presentation and other related investigations. Report is not valid for medico-legal purpose subject to ALWAR jurisdiction only.



# दक्ष हॉस्पिटल

396, गाँधी नगर स्कीम नं.8, अलवर (राज०) ☎ 0144-2703340

## Sonography / 2D Echo Cardiography / Doppler Report

### 2D/ ECHO REPORT

Name: - Mr HARI SINGH

Age: -364 Yrs

Date: - 27-Apr-24

Reg. No.: - Alw/2009/04  
BOB health checkup

#### PROCEDURES:

M-MODE/2D/DOPPLER/COLOR/CONTRAST B.A.S. M<sup>2</sup>

#### MEASUREMENT:

AOD	22	NORMAL
LA	23	(20- 37mm)
AVO	18	(19- 40mm)
RVDd.	11	(12- 25mm)
		(03- 09mm)
LVDd	42	(37- 56mm)
LVDs	26	(22- 40mm)
IVS d	8	(06- 12mm)
IVS s	11	
PWd	6	(05- 10mm)

#### DOPPLER:

MV	0.7	NORMAL (cm/sec.)	MR	No
AV	1.4	(0.8- 1.3)	AR	No
TV	0.6	(1.2- 1.8)	TR	No
PV	0.8	(0.3- 0.8)	PR	No
		(0.7- 1.1)		

#### MITRAL VALVE-

AML	Normal
PML	Normal

#### AORTIC VALVE

Normal

TV & PV are normal.

#### LV FUNCTION

M- E- S Separation	<0.9cm
Minor	24.42%
LV Ejection Fraction	68% 65 +/- 12%

MITRAL E>A

LV WALL MOTION: NO RWMA

ALL CARDIAC CHAMBERS ARE NORMAL

ALL VALVES ARE NORMAL

NO CLOT, VEGETATION, PERICARDIAL EFFUSION

Adv: - Follow up/ review at higher center for confirmation

Note:- Please Correlate clinically. Due to technical limitations as well as inaccuracies inherent in the laboratory and statistical analysis of biological process. Diagnostic accuracy of ECHO is up to 95% only. Report is not valid for medico-legal purpose.

  
DR. MUKESH GUPTA  
Dr. Mukesh GUPTA  
Physician & Sonologist  
RM 5423/18262



"भ्रूण लिंग परीक्षण की शिकायत  
104 टोल फ्री सेवा पर भी की  
जा सकती है"  
भ्रूण लिंग परीक्षण की शिकायत 104 टोल फ्री सेवा पर भी की जा सकती है।



# दक्ष हॉस्पिटल

396, गाँधी नगर स्कीम नं.8, अलवर (राज०) ☎ 0144-2703340

## Sonography / 2D Echo Cardiography / Doppler Report

Name: MR. HARI SINGH /M/36 YRS

Date: 27-Apr-24

BOB HEALTH CHECK UP

### U.S.G. OF ABDOMEN & PELVIS

#### LIVER

Liver is **14.9 cm at vertically** with normal echo-texture. Intra hepatic biliary radicals are not dilated. No evidence of focal or diffuse lesion.

#### GALL BLADDER

Gall bladder is partially contracted, visualized Lumen appear clear. Wall thickness normal. CBD normal

#### PANCREAS

Pancreas is normal in size, shape & echo-texture.

#### SPLEEN

7.9 in size with normal shape & echo- texture.

#### BOTH KIDNEY

Both kidney normal shape, size & echo texture. CMD maintained

PROSTATE is normal shape, size & echo texture..

URINARY BLADDER is normally distended, visualized lumen appear clear.

Advice- Grade I Fatty liver.

Please correlate clinically. USG accuracy is 95 % due to technical limitations as well as inaccuracies inherent in the laboratory and statistical analysis biological process.

This report is not valid for medico-legal cases.

  
DR. MUKESH KUMAR GUPTA  
SONOLOGIST  
Physician & Sonologist  
RM 5423/16262



"भ्रूण लिंग परीक्षण की शिकायत  
104 टोल फ्री सेवा पर भी की  
जा सकती है"

भ्रूण लिंग परीक्षण की शिकायत 104 टोल फ्री सेवा पर भी की जा सकती है।

ID:

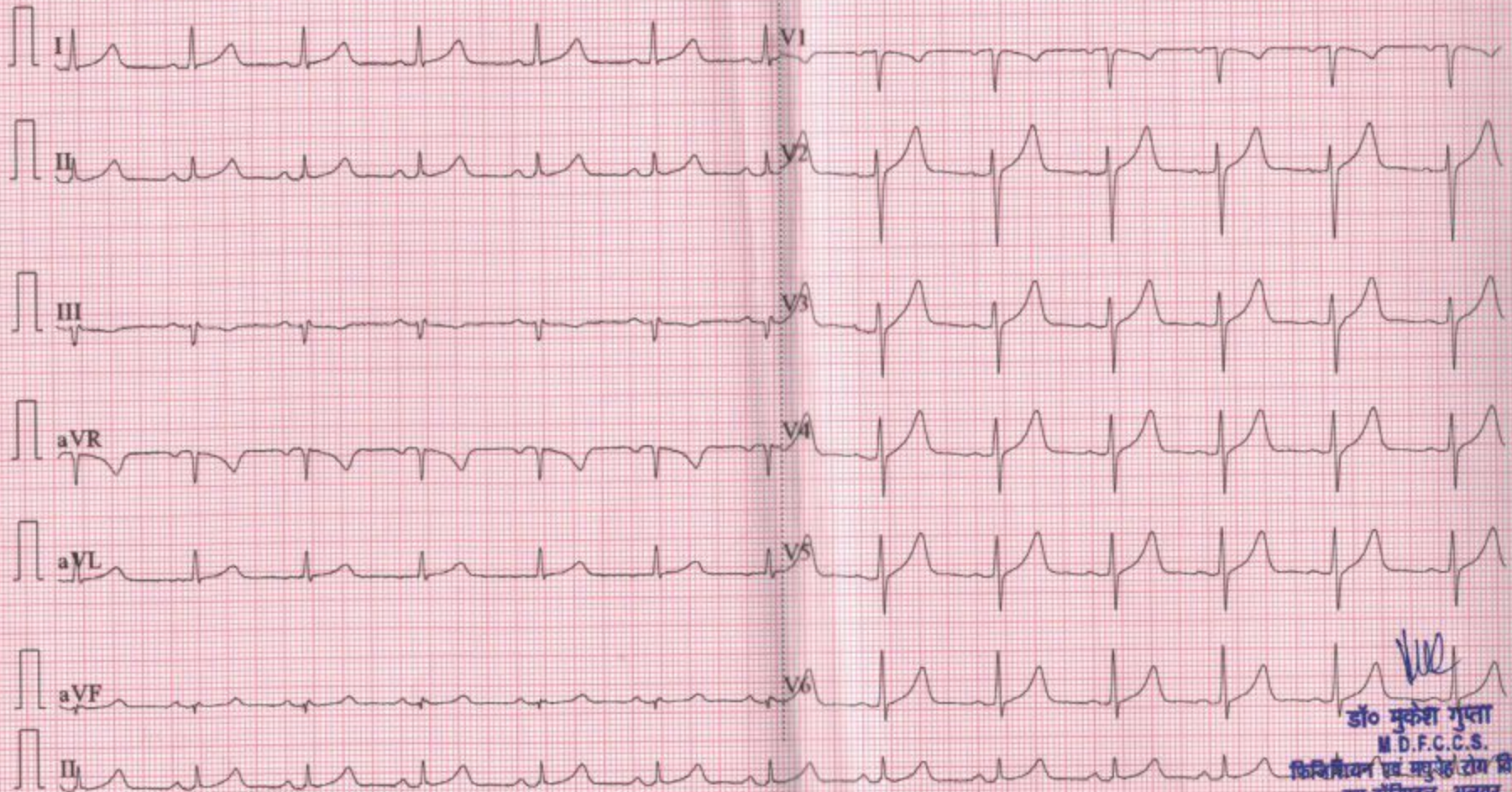
Male      Years

HR	: 75	bpm
P	: 105	ms
PR	: 160	ms
QRS	: 78	ms
QT/QTc	: 386/433	ms
P/QRS/T	: 65/10/22	°
RV5/SV1	: 0.755/0.670	mV

Diagnosis Information:

Sinus Rhythm  
\*\*\*Normal ECG\*\*\*

Report Confirmed by:



*[Signature]*  
 डॉ० मुकेश गुप्ता  
 M.D.F.C.C.S.  
 कर्माचार्य एवं मधुसूदन टोंग सिरीयस  
 दस हॉस्पिटल, अलवर  
 फ़ोन नं०-5423/16282

R

