

IPSITA RANI BEHERA

35 YEARS/FEMALE

09/11/2024

**REAL TIME SONOGRAPHY OF THE ABDOMEN & PELVIS**

**LIVER** - It is normal in size (14.3 cm). It shows normal echo pattern. No evidence of solid or cystic focal lesion is seen. The intrahepatic biliary system is normal and shows no dilatation of the radicals. The portal vein, CBD and hepatic veins appear normal.

**GALL BLADDER** - It is distended and appears normal. No evidence of sludge or calculus is seen. The wall appears normal.

**PANCREAS** - It is visualized and appears normal.

**SPLEEN** - It appears normal in size (10.7 cm), shape and in echo texture. No focal lesions.

**KIDNEYS** - . Both the kidneys appear normal in size, shape and show normal corticomedullary differentiation. Normal echogenicity of both kidneys.

Right kidney measures 10.7 X 3.2 cm. Left kidney measures 10.6 X 4.4 cm.

Calculus of size 4.4 mm is noted in upper calyx of right kidney.

No hydronephrosis is seen on either side.

**Urinary bladder** is distended and appears normal. No evidence of calculus / mass lesion is seen. The walls appear normal.

Uterus appears normal. ET measures 10.0 mm. No focal lesion.

Both adnexa appears normal.

No evidence of any lymphadenopathy or ascites is noted.

**IMPRESSION:**

**RIGHT RENAL CALCULUS.NO HYDRONEPHROSIS.**



**DR. SARJAN VASAVA,**  
CONSULTANT RADIOLOGIST.

**DR SARJAN VASAVA**  
M.B.B.S., D.M.R.D.  
Reg. No. G-26527  
**SAMANVAY HOSPITALS**

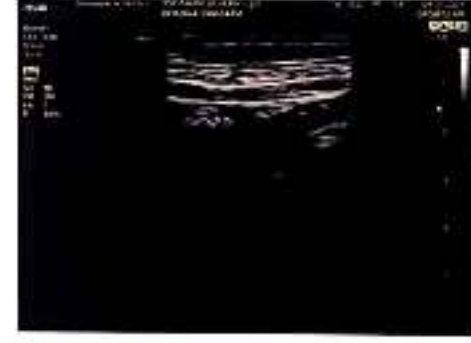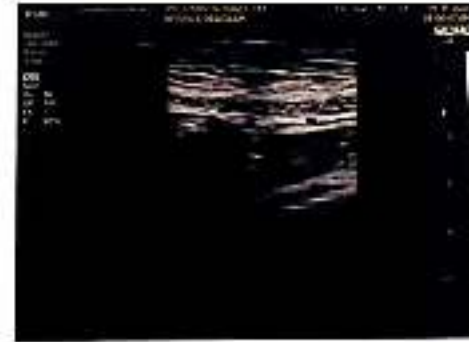

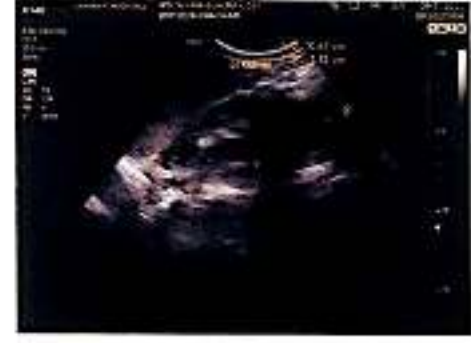
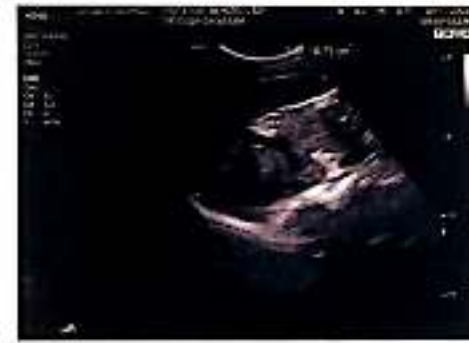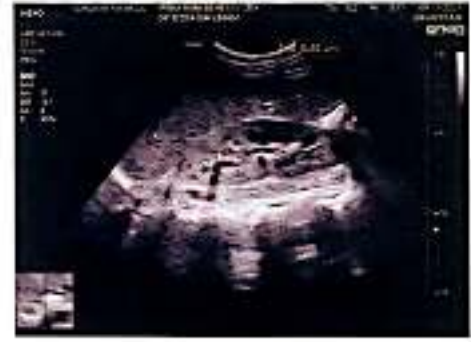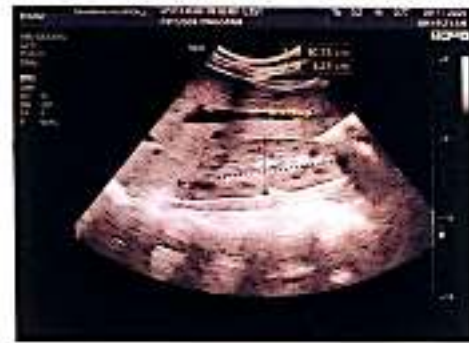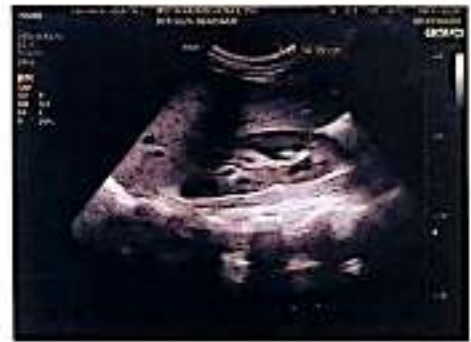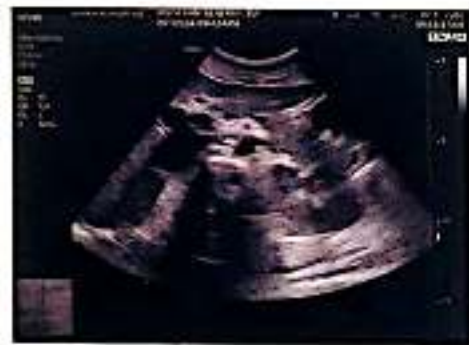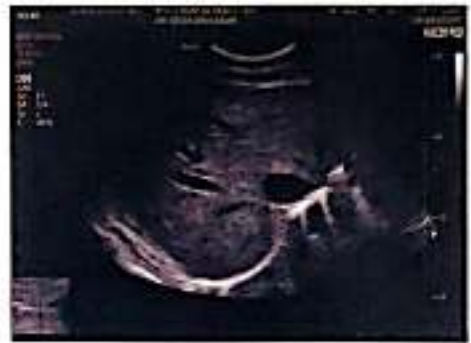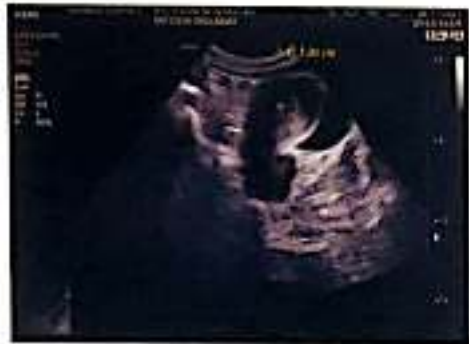Patient

ID 09112024-094634AM  
Name IPSITA RANI BEHERA F/35Y  
Birth Date  
Gender

Exam

Accession #  
Exam Date 09-11-2024  
Description  
Operator

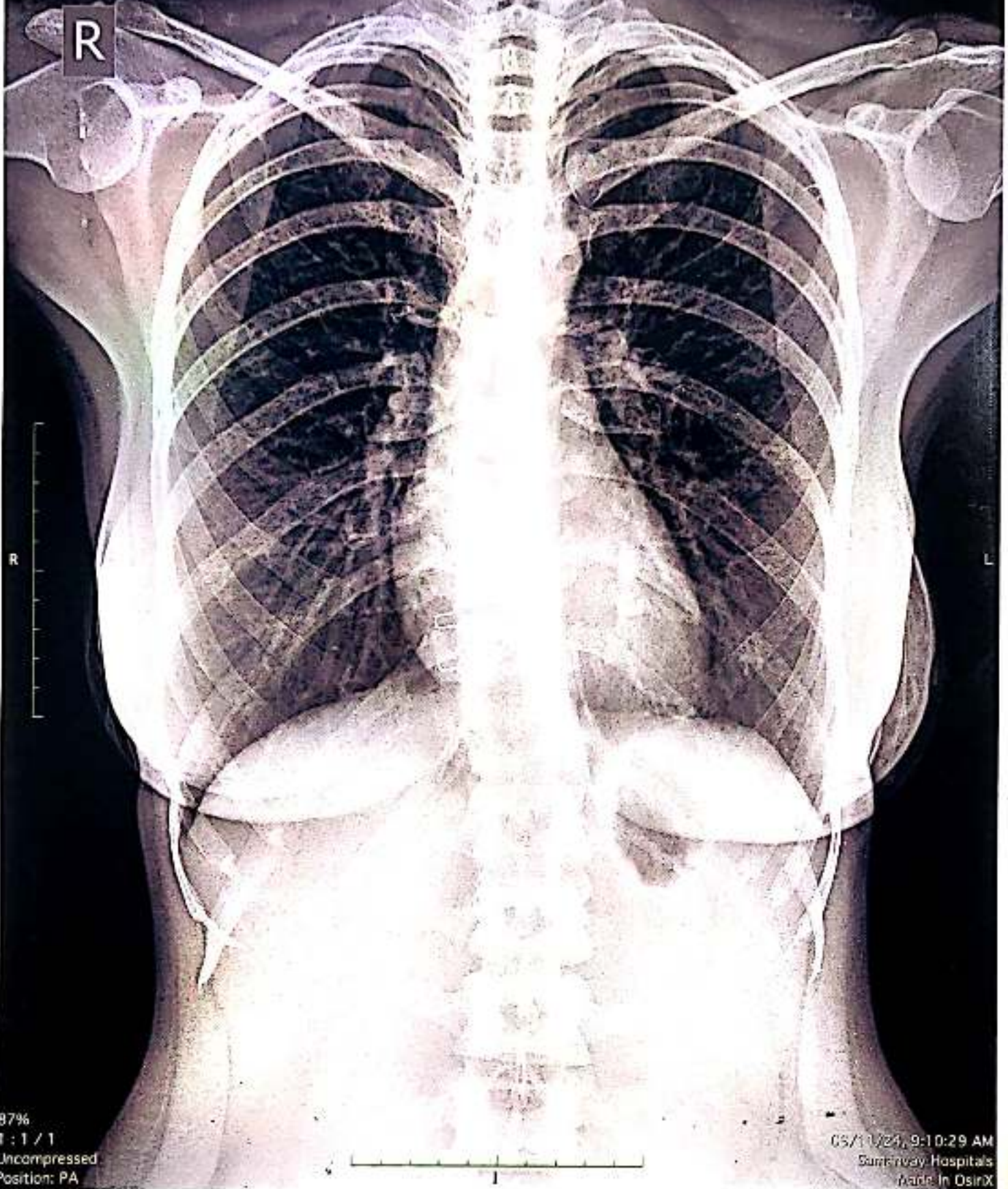


Ipsita Rani Behera F/35y

09-11-24

2280 x 2812  
WL: 128 WW: 256

Ipsita Rani Behera 35Yrs 68 ( - , - )  
Chest





SINUS RHYTHM  
 LOW LIMB LEAD VOLTAGE  
 NON-SPECIFIC T-ABNORMALITY

UNCONFIRMED REPORT

**DR. PAVAN ROY**  
 MD, DM (CARDIOLOGY)  
 CONSULTANT CARDIOLOGIST  
 REG. NO. 3389  
 M. No. 3363, 3163

Axis: P 38°, QRS 39°, T 38°

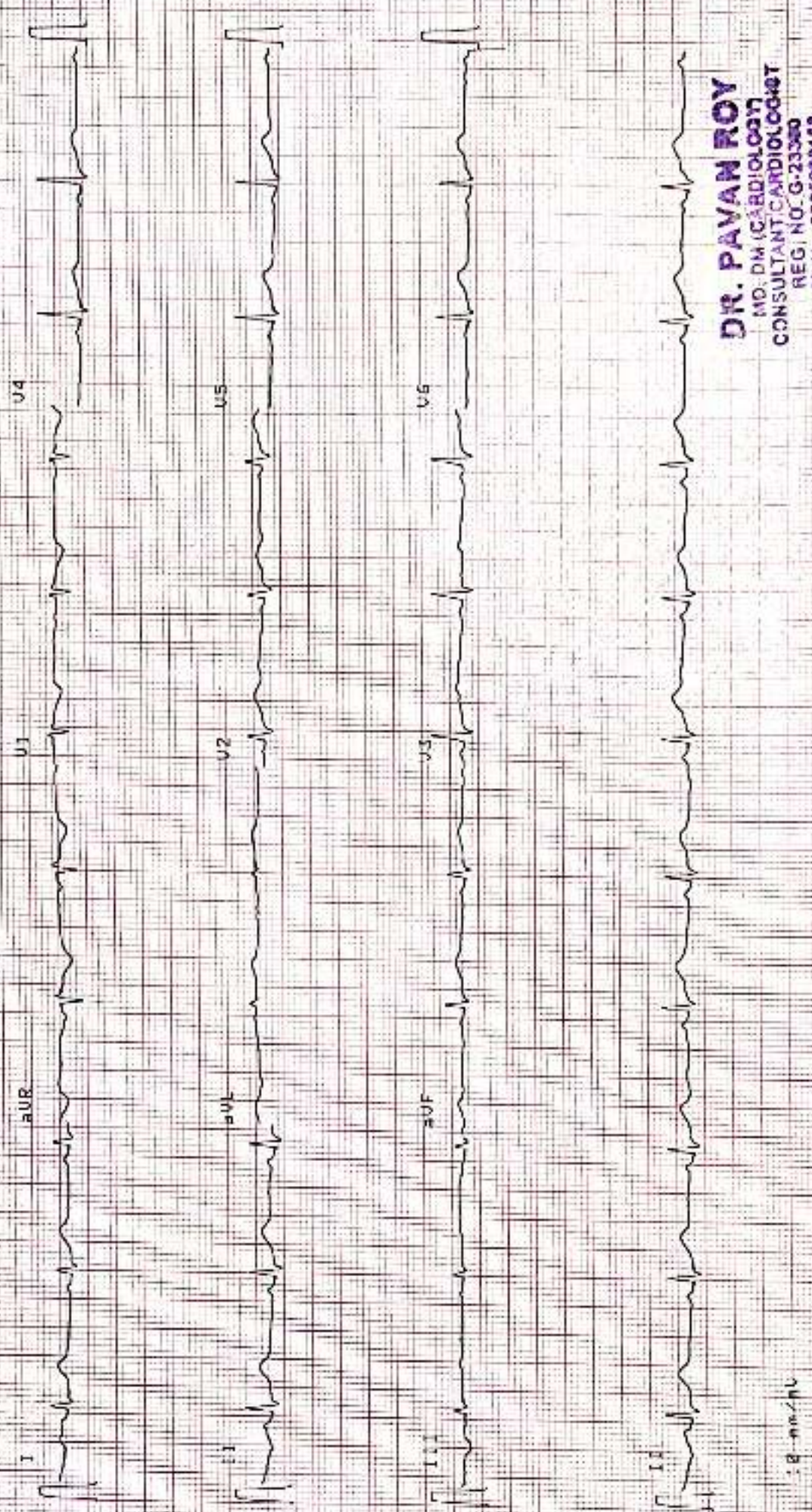
HR: 63/min

Intervals: P-R-T

RR: 949 ms  
 P: 86 ms  
 PR: 128 ms  
 QRS: 78 ms  
 QT: 414 ms  
 QTc: 427 ms

10 mm/mV

10 mm/mV



**DR. PAVAN ROY**  
 MD, DM (CARDIOLOGY)  
 CONSULTANT CARDIOLOGIST  
 REG. NO. G-23380  
 M. No. 3363, 3163

25 mm/s  
 8 mm/mV

## GYNECOLOGICAL CHECK UP

S/B Dr. : Swati Bhimani Date : 9/11/24

Name : Mrs. Ipsita Rami Age / Sex : 35/F

COMPLAINTS : NO COMPLAINTS  
Abdominal pain / Leucorrhoea / Dysmenorrhoea / Menorrhoea /  
Polymenorrhoea / Discharge PV / Itching PV / Mass PV /  
Post Coital Bleed / Dysparunja

MENSTRUAL HISTORY : \_\_\_\_\_

MENSTRUAL CYCLE : Reg

DAYS / Irreg., \_\_\_\_\_

FLOW : Mod / Heavy \_\_\_\_\_

LMP : 25/10.

OBS HISTORY : \_\_\_\_\_

Duration of Married Life

NO. OF CHILDREN : G<sup>1</sup> P<sup>1</sup> L<sup>1</sup> A<sup>1</sup> 1A 1ND / 9/3 1/2 yrs/e.

NO.	AGE	SEX	MODE OF DELIVERY	OTHERS

DESIRES CONTRACEPTION : YES / NO

MODE OF CONTRACEPTION : Safe Period / Barrier / IDU / OCP / Others

D/E : P/A : ln

P/S : Arterial tension + etc.

P/V : \_\_\_\_\_

BREAST ND : Rt : \_\_\_\_\_ Lt : \_\_\_\_\_

ADVICE : \_\_\_\_\_

CONSULTANT'S SIGNATURE



## **2D ECHOCARDIOGRAPHY AND COLOUR DOPPLER STUDY**

**NAME : MRS.IPSITA RANI**

**DATE :09-11-24**

**AGE/SEX :35 YRS / F WARD: HCP**

**REF BY : SAMANVAY HOSPITAL**

### **OBSERVATION:**

- NORMAL LV SIZE WITH NORMAL LV SYSTOLIC FUNCTION
- LVEF 60%, NO RWMA AT REST
- E/O NORMAL LV DIASTOLIC DYSFUNCTION, NORMAL LA SIZE
- AORTIC VALVE, NO AR, NO AS
- MITRAL VALVE, TRIVIAL MR, NO MS
- TRIVIAL TR, NO PAH, RVSP 26 MMHG
- NORMAL SIZED RA, RV WITH NORMAL RV FUNCTION
- PULMONARY VALVE- NO PR, NO PS, NORMAL SIZED PA & ITS BRANCHES
- IAS, IVS ARE INTACT
- NO INTRACARDIAC CLOT, VEGETATION
- PERICARDIUM NORMAL, NO PERICARDIAL EFFUSION
- IVC NORMAL IN SIZE

### **MEASUREMENTS:**

M MODE: AORTA: 22 MM LA: 24 MM LV DD/DS: 48/29 MM IVS/PW: 10/09 MM  
DOPPLER: MV RATIO E/A: 0.9/0.4 M/S AV VMAX: 1.1 M/S PV VMAX: 0.5 M/S

### **CONCLUSION:**

**NORMAL LV SIZE AND LV SYSTOLIC FUNCTION**  
**LVEF 60%, NO RWMA AT REST**  
**TRIVIAL MR, TRIVIAL TR, NO PAH**  
**E/O NORMAL LV DIASTOLIC DYSFUNCTION**



**Patient Name** : MRS. IPSITA RANI BEHERA  
**Age & Sex.** : 35Y 3M 26D /F  
**Bill date** : 09/11/2024 12:38 PM

**Bill No.** : OPB/1/24/10973  
**Reg No.** : REG-14260  
**Sponsor** : MEDIWHEEL

**X-RAY CHEST PA**

Both the lung fields appear normal.  
Both costophrenic angles appear clear.  
Cardiac silhouette appear normal.  
Both hila appears normal.  
Mediastinum and aorta appear normal.  
Bony thorax appears normal.  
No evidence of free gas seen under dome of diaphragm.

**COMMENTS:**

- NORMAL BOTH LUNG FIELDS.
- NORMAL CARDIAC SIZE.

**Impression :**  
**Conclusion :**



**Dr. Sarjan Vasava**  
Radiology

(Reg No-G-26527)

**DR SARJAN VASAVA**  
M.B.B.S., D.M.R.D.,  
Reg. No. G-26527  
SAMANVAY HOSPITALS



### COMPREHENSIVE HEALTH CHECK UP

Case No. : \_\_\_\_\_ Date : \_\_\_\_\_

Name : Ipsita Bani Age/Sex : \_\_\_\_\_

MEDICAL HISTORY : Paral Cabali + Hypothyroidism on Ayurvedic Medication

PERSONAL HISTORY : \_\_\_\_\_

Appetite : \_\_\_\_\_ Smoking : \_\_\_\_\_

Sleep : \_\_\_\_\_ H/O Alcohol : \_\_\_\_\_

Bladder : \_\_\_\_\_ Lifestyle : \_\_\_\_\_

Bowel : \_\_\_\_\_ Exercise : \_\_\_\_\_

DRUG HISTORY : \_\_\_\_\_

PAST HISTORY : \_\_\_\_\_

FAMILY HISTORY : \_\_\_\_\_

#### GENERAL PHYSICAL EXAMINATION :

Built and Nourishment :

Height : 156 cm SpO<sub>2</sub> : 97%

B. P. : 100/70 mm of Hg Weight : 45.2 Kg

Character : \_\_\_\_\_ Pulse : 64 /Min

Nails : \_\_\_\_\_ Odema : \_\_\_\_\_

Tonsils : \_\_\_\_\_ Skin : \_\_\_\_\_

Tongue : \_\_\_\_\_ Sclera : \_\_\_\_\_

Eat. & Joints : \_\_\_\_\_ Glands : \_\_\_\_\_



Iron deficiency  
- on Ayurvedic  
meds

Adv  
- Iron studies / S.I.P.H /  
S.VIT B12 etc  
- Tb, NCCFR 070  
- Tb, SUBIE plus CD 010  
एवम कं 012





SAMANVAY  
HOSPITALS

### EYE CHECK UP

Reg. No. : \_\_\_\_\_ Date : 9-11-2024  
Name : Ipsita Rami Age / Sex : 35 / F

	RIGHT EYE	LEFT EYE
DISTANCE : (With / Without Glasses)	$6/60 - 2.0$ $\times - 0.75$ $\times 85$	$6/5 \times 2.0$ $- 0.75 \times 60$
NEAR VISION : (With / Without Glasses)	N.6	N.6
ANTERIOR SEGMENT :	WNL	WNL
I O P (MM of Hg)	140	140
FUNDUS :	WNL	WNL
COLOR VISION :	WNL	WNL
CLINICAL IMPRESSION :	Myopic Astigmatism	
ADVICE :	glc	

Doctor's Signature :



Dental



MRS. Ipsita Rumi - 35/F


9-11-2024

Ch : No complains .

Adv : Follow-up every 6 months .




Patient Name : MRS. IPSITA RANI BEHERA  
 Age / Sex : 35Y 3M 26D/Female  
 IP/Reg.No/UHID : Reg-14260 /UHID14260  
 Lab No : LA24010349  
 Referred By : Dr.SAMANVAY HOSPITAL  
 Bedcategory/Bed :  
 Mobile No : 9178130971  
 UHID : UHID14260  
 Consultant : Mr. Samanvay Hospital  
 Sponsor : **MEDIWHEEL**  
 ABHA Address :  
 Barcode No. : **38035,38036,38037,38038**

Bill No : OPB/1/24/10973  
 Sample Collected : Nov 9 2024 9:39AM  
 Sample Received : Nov 9 2024 9:48AM  
 Report On : Nov 9 2024 9:48AM  
 Bill Creation Date : Nov 9 2024 9:04AM  
 Bar Code :   
 Reg No : Reg-14260  
 IPNo :  
 Passport No. :  
 Verified On : **Nov 9 2024 12:01PM**  
 ABHA Num :


Test Name	Results	Units	Biological Reference
<b>MICRO</b>			
<b>URINE ANALYSIS</b>			
<b>PHYSICAL EXAMINATION</b>			
VOLUME	30 ML		
COLOUR	PALE YELLOW		
APPEARANCE	CLEAR		
<b>CHEMICAL EXAMINATION</b>			
PH	6.0		4.5 - 8.0
SPECIFIC GRAVITY	1.025		1.000 - 1.030
PROTEIN	Negative		
GLUCOSE	Negative		
KETONE	Negative		
BLOOD	Negative		
UROBILINOGEN	Negative		
BILE PIGMENTS	Negative		
BILE SALT	Negative		
NITRITE	Negative		
LEUKOCYTE ESTERASE	Negative		
<b>MICROSCOPIC EXAMINATION</b>			
PUS CELLS	1--2	CELLS/HPF	0 - 5
RBC	NIL	RBC'S/HPF	0 - 2
EPITHELIAL CELLS	2--3	OCC/HPF	0 - 5
CASTS	NIL		
CRYSTALS	NIL		
<b>HPLC</b>			
<b>HBA1C/ GLYOCO HB</b>			
GLYCOCYLATED HAEMOGLOBIN(HBA1C)(HPLC)	4.2	%	4.0 - 6.0

Mrs. Neena Ravi Patel

Prepared by

  
 Dr. Sweta Patel  
 MD (Pathology)  
 Verified By

Patient Name : MRS. IPSITA RANI BEHERA  
Age / Sex : 35Y 3M 26D/Female  
IP/Reg.No/UHID : Reg-14260 /UHID14260  
Lab No : LA24010349  
Referred By : Dr.SAMANVAY HOSPITAL  
Bedcategory/Bed :  
Mobile No : 9178130971  
UHID : UHID14260  
Consultant : Mr. Samanvay Hospital  
Sponsor : **MEDIWHEEL**  
ABHA Address :  
Barcode No. : **38035,38036,38037,38038**

Bill No : OPB/1/24/10973  
Sample Collected : Nov 9 2024 9:39AM  
Sample Received : Nov 9 2024 9:48AM  
Report On : Nov 9 2024 9:48AM  
Bill Creation Date : Nov 9 2024 9:04AM  
Bar Code :   
Reg No : Reg-14260  
IPNo :  
Passport No. :  
Verified On : **Nov 9 2024 12:01PM**  
ABHA Num :

Test Name	Results	Units	Biological Reference
AVERAGE BLOOD SUGAR	73.84	mg/dl	0 - 140.0
<b>BIOCHEMISTRY</b>			
<b>LIPID PROFILE</b>			
CHOLESTROL (TOTAL)(CHOD-PAP)	139.0	mg/dl	0.0 - 200.0 Desirable blood cholesterol : <200 mg/dl Borderline high blood cholesterol : 200-239 mg/dl High blood cholesterol : >239 mg/dl
TRIGLYCERIDE(GPO-METHOD)	56.8	mg/dl	0 - 161.0 NORMAL : <161 MG/DL HIGH : 161-199 MG/DL HYPERTRIGLYCERIDEMIC : 200-499 MG/DL
HDL CHOLESTEROL(DIRECT METHOD)	59.2	mg/dl	42.0 - 88.0
CHOLESTROL (TOTAL)/HDL RATIO(CALCULATED)	↓ 2.35		3.30 - 4.40
VLDL	11.36		0 - 30.0
LDL CHOLESTEROL(CALCULATED)	79.8		0 - 130.0
LDL/HDL RATIO	1.35		
CREATININE (BLOOD)(ENZYMATIC)	0.62	mg/dl	0.6 - 1.1
UREA(UREASE-GLDH)	22.1	mg/dl	21.0 - 43.0
BUN(UREASE-GLDH)	10.32	mg/dl	5.0 - 21.0
URIC ACID	3.2	mg/dl	2.6 - 6.0
BUN CREATININE RATIO(CALCULATED)	16.6	mg/dl	10.0 - 20
<b>LIVER FUNCTION TEST</b>			
BILIRUBIN-TOTAL(DIAZO)	0.48	mg/dl	0.00 - 2.0
BILIRUBIN-DIRECT(DIAZO)	0.28	mg/dl	0.00 - 0.4
BILIRUBIN-INDIRECT(DIAZO)	0.20	mg/dl	0.00 - 1.10

Mrs. Neena Ravi Patel


Prepared by



Dr. Sweta Patel  
MD (Pathology)

Verified By

Patient Name : MRS. IPSITA RANI BEHERA  
Age / Sex : 35Y 3M 26D/Female  
IP/Reg.No/UHID : Reg-14260 /UHID14260  
Lab No : LA24010349  
Referred By : Dr.SAMANVAY HOSPITAL  
Bedcategory/Bed :  
Mobile No : 9178130971  
UHID : UHID14260  
Consultant : Mr. Samanvay Hospital  
Sponsor : **MEDIWHEEL**  
ABHA Address :  
Barcode No. : **38035,38036,38037,38038**

Bill No : OPB/1/24/10973  
Sample Collected : Nov 9 2024 9:39AM  
Sample Received : Nov 9 2024 9:48AM  
Report On : Nov 9 2024 9:48AM  
Bill Creation Date : Nov 9 2024 9:04AM  
Bar Code :   
Reg No : Reg-14260  
IPNo :  
Passport No. :  
Verified On : **Nov 9 2024 12:01PM**  
ABHA Num :

Test Name	Results	Units	Biological Reference
-----------	---------	-------	----------------------

SGOT(IFCC WITHOUT PYRIDOXAL PHOSPHATE)	22.8	U/L	0 - 31
SGPT(IFCC WITHOUT PYRIDOXAL PHOSPHATE)	12.7	U/mL	0 - 34
ALKALINE PHOSPHATASE(ALKP04)* (AMP-METHOD)	47.0	U/L	42 - 141
PROTEIN (SERUM)(BIURET)	7.36	g/dl	6.4 - 8.3
ALBUMIN(BCG)	4.18	g/dl	3.5 - 5.2
GLOBULIN(CALCULATED)	3.18	g/dl	2.3 - 3.7
A/G RATIO(CALCULATED)	1.31	Ratio	1.0 - 2.0
GAMMA GT(GLUPA C METHOD)	35.0	U/L	0.0 - 58.0

#### IMMUNOLOGY

#### T3 T4 TSH

TOTAL T3(CHEMILUMINESCENCE / CLIA)	0.82	ng/ml	0.19 - 6.51
TOTAL T4(CHEMILUMINESCENCE / CLIA)	6.43	ug/dl	4.5 - 12.7
TSH(CHEMILUMINESCENCE / CLIA)	<b>↑ 6.68</b>	μIU/mL	0.35 - 4.78

Interpretation :

1. TSH results between 4.5 to 15.0 show considerable physiologic and seasonal variation, suggest clinical correlation or repeat testing with fresh sample.
- 2.TSH results between 0.1 to 0.45 requires correlation with patient age and clinical symptoms. As with increasing age, there are marked changes in thyroid hormone production, metabolism and its action resulting in an increase prevalence of sub-clinical thyroid disease.
3. TSH values may be transiently altered because of non- thyroidal illness like severe infections, liver diseases, renal and heart failure, severe burns, trauma and surgery etc.
- 4.Drugs that decreased TSH values e.g. L-dopa, glucocorticoid. Drugs that increase TSH values e.g .Iodine, Lithium and amiodarone.

#### BIOCHEMISTRY

#### FASTING BLOOD GLUCOSE\*

FASTING BLOOD GLUCOSE(FBS)(GOD-POD)	88.6	mg/dl	74.0 - 100.0
FASTING URINE GLUCOSE	NIL		

#### HEMATOLOGY

BLOOD GROUP RH "B" POSITIVE

#### CBC WITH ESR




Dr. Sweta Patel  
MD (Pathology)  
Verified By

Mrs. Neena Ravi Patel

Prepared by

Nr. St. Kabir School, Opp. Raneshwar Temple, Vasna Road, Vadodara-15

Patient Name : MRS. IPSITA RANI BEHERA  
Age / Sex : 35Y 3M 26D/Female  
IP/Reg.No/UHID : Reg-14260 /UHID14260  
Lab No : LA24010349  
Referred By : Dr.SAMANVAY HOSPITAL  
Bedcategory/Bed :  
Mobile No : 9178130971  
UHID : UHID14260  
Consultant : Mr. Samanvay Hospital  
Sponsor : **MEDIWHEEL**  
ABHA Address :  
Barcode No. : **38035,38036,38037,38038**

Bill No : OPB/1/24/10973  
Sample Collected : Nov 9 2024 9:39AM  
Sample Received : Nov 9 2024 9:48AM  
Report On : Nov 9 2024 9:48AM  
Bill Creation Date : Nov 9 2024 9:04AM  
Bar Code :   
Reg No : Reg-14260  
IPNo :  
Passport No. :  
Verified On : **Nov 9 2024 12:01PM**  
ABHA Num :

Test Name	Results	Units	Biological Reference
<b>RBCS PARAMETER</b>			
HAEMOGLOBIN(SLS METHOD)	↓ 8.3	g/dl	13.0 - 17.0
RBC COUNT(IMPEDENCE)	↓ 4.32	10 <sup>6</sup> /uL	4.50 - 5.50
PCV (HEAMATOCRIT)(IMPEDENCE)	↓ 29.1	%	40.0 - 50.0
MCV(CALCULATED)	↓ 67.4	fl	80.0 - 100.0
MCH(CALCULATED)	↓ 19.2	pg	27.0 - 33.0
MCHC(CALCULATED)	↓ 28.5	g/dl	32.0 - 36.0
RDW-CV(PARTICLE COUNTER(CALCULATED))	↑ 16.8	%	11.6 - 14.0
RDW-SD(PARTICLE COUNTER(CALCULATED))	41.0	fl	39 - 46
<b>WBCS PARAMETER</b>			
TOTAL COUNT(FLOW CYTOMETRY)	↓ 3070	/uL	4000 - 10000
<b>DLC</b>			
NEUTROPHILS(FLOW CYTOMETRY)	47	%	40 - 70
LYMPHOCYTES(FLOW CYTOMETRY)	↑ 43	%	20 - 40
MONOCYTES(FLOW CYTOMETRY)	07	%	2 - 8
EOSINOPHILS(FLOW CYTOMETRY)	03	%	1 - 4
BASOPHILS(FLOW CYTOMETRY)	00	%	0.0 - 1.0
ABSOLUTE NEUTROPHIL COUNT(CALCULATED)	↓ 1440.0	10 <sup>3</sup> /uL	2000.0 - 7000.0
ABSOLUTE LYMPHOCYTE COUNT(CALCULATED)	1320.0	10 <sup>3</sup> /uL	1000.0 - 3000.0
ABSOLUTE MONOCYTE COUNT(CALCULATED)	210.0	10 <sup>3</sup> /uL	200.0 - 1000.0
ABSOLUTE EOSINOPHIL COUNT(CALCULATED)	80.0	10 <sup>3</sup> /uL	20.0 - 500.0
<b>PLATELETS PARAMETER</b>			
PLATELET COUNT(IMPEDENCE)	↓ 97000	/uL	150000 - 450000
ESR	10	mm/hr	0 - 20

-----End of the Report-----

Mrs. Neena Ravi Patel

Prepared by



Dr. Sweta Patel  
MD (Pathology)

Verified By

Nr. St. Kabir School, Opp. Raneshwar Temple, Vasna Road, Vadodara-15