

& Mediwheel




THE UNION OF INDIA  
MAHARASHTRA STATE MOTOR DRIVING LICENCE



DL No. MH01 19990007886    DOI : 04-02-1999  
Valid Till : 03-02-2024 (NT)

DLD 04-10-2019

FORM 7  
RULE 16 (7)



AUTHORISATION TO DRIVE FOLLOWING CLASS  
OF VEHICLES THROUGHOUT INDIA  
COV            DOI  
MCWG    04-02-1999



DOB : 30-08-1970    BG :

Name : SHAIKH SHAKEEL AHMED  
S/DW of : SHAIKH ABDUL KARIM  
Add : SIMON BLDG 3RD FLR R NO 30  
DONGRI MUMBAI  
MUMBAI, MUMBAI, MH  
PIN : 400009

Signature & ID Of *Shakeel Ahmed*  
Issuing Authority : MH01

Signature/Thumb  
Impression of Holder

*Shakeel*

521M

DR. PLUS HEALTHCARE CENTRE  
'NATHANI HEIGHTS', B-WING  
42, MUMBAI CENTRAL (EAST)

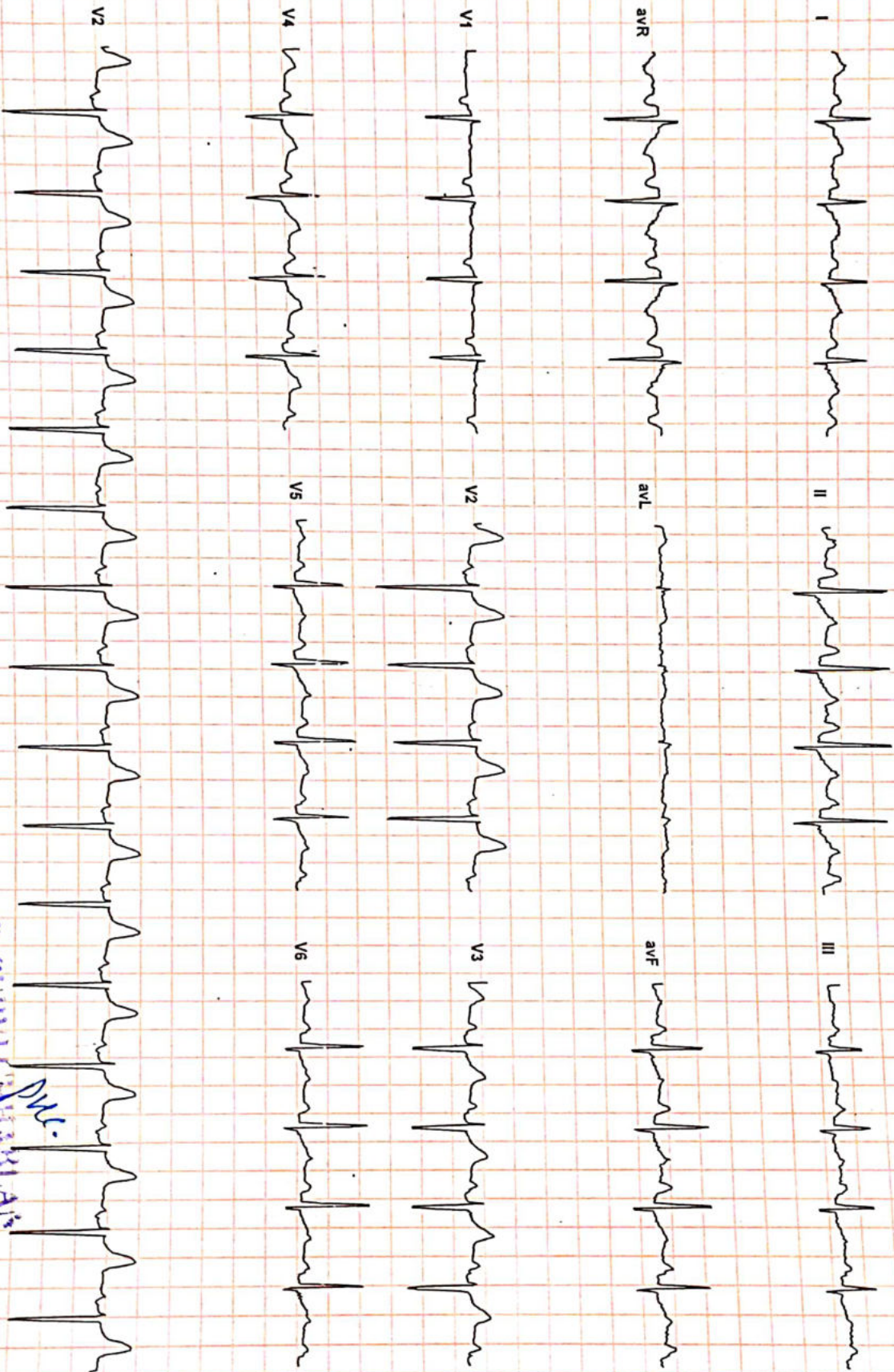
*Dr. Hari Chhabiani*  
DR. HARI CHHABI ANI  
MBBS (MD) (DIPLOMA IN POST GRADUATE)  
LOW INTENSIVE CARE  
MCO REG. NO. - 91702

**DR PLUS HEALTHCARE CENTRE - MUMBAI CENTRAL**

**ECG**

2193 / SHAKEEL SHAIKH / 52 Yrs / M

Heart Rate : 100 bpm / Tested On : 24-Sep-22 10:34:24 / HF 0.05 Hz - LF 100 Hz / Notch 50 Hz / Sn 1.00 Cm/mV / Sw 25 mm/s  
/ Refd By: DR. HARI CHHABLANI



Allergens ECG (P/Scs)(P/IS216200529)

*Handwritten signature*

**DR. PURVI CHHABLANI**  
Reported By: DR. PURVI CHHABLANI

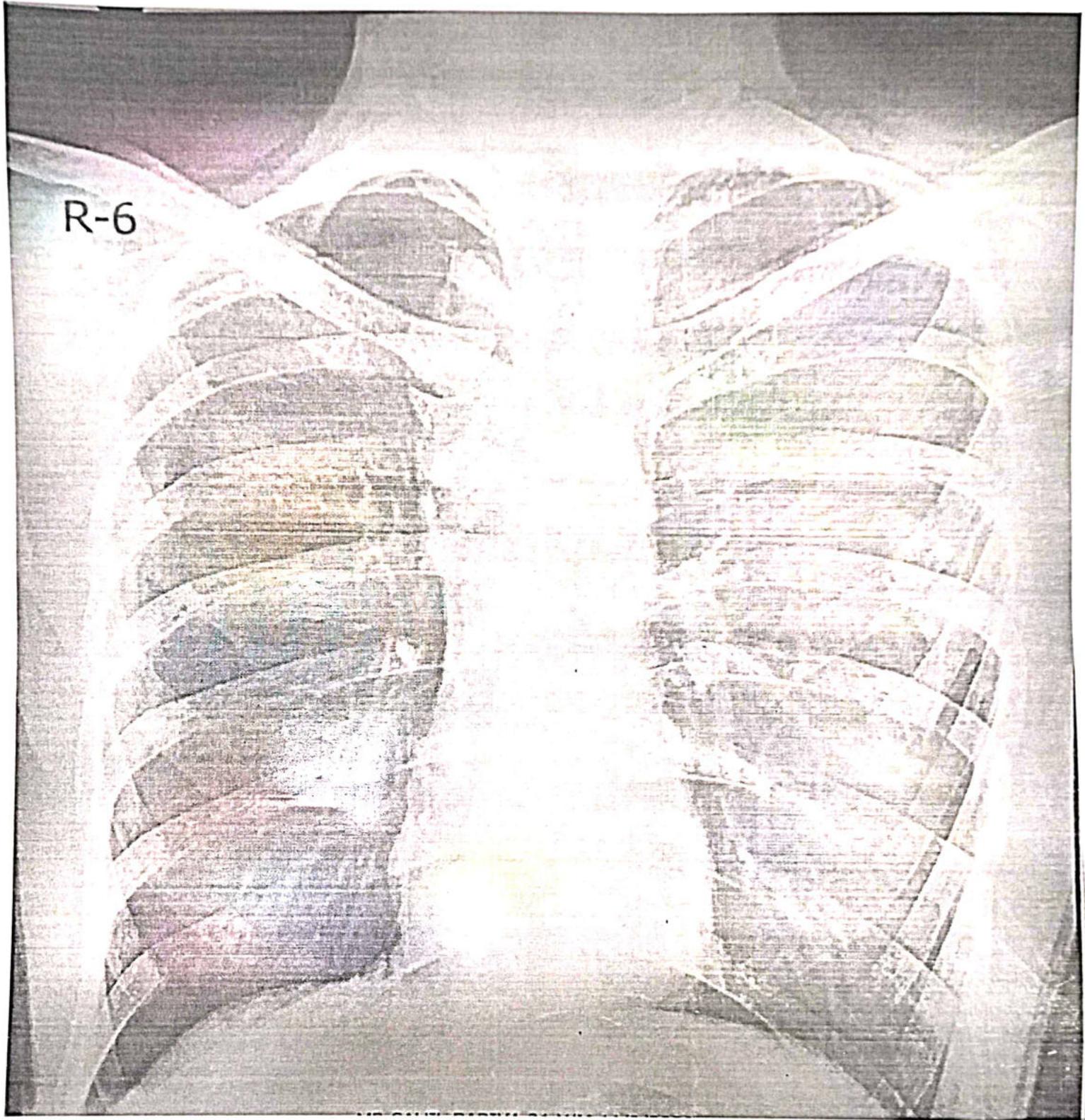
Consultant Physician And Intensivist

Reg No 77996

SHAKEEL SHAIKH

52/M

24/09/22



'DR. PLUS HEALTHCARE CENTRE'  
NATHANI HEIGHTS', B-WING  
42, MUMBAI CENTRAL (EAST)



# Dr-Plus Healthcare Centre

NATHANI HEIGHTS, B-Wing, Shop No. 42, Ground Floor, Opp. Mumbai Central Station (East), Mumbai - 400 008.

Patient's Name : SHAIKH SHAKEEL

Report Date : 24/09/2022

Referred By : SELF

Age : 52 Years

Sex : MALE

## X- RAY CHEST

BOTH THE LUNG FIELDS ARE CLEAR.

THE HILAR SHADOWS APPEAR NORMAL.

THE COSTO-PHRENIC ANGLES ARE CLEAR.

THE CARDIAC SHADOWS APPEAR NORMAL.

THE TRACHEAL IS CENTRAL IN POSITION.

THE BONY CAGE APPEARS NORMAL.

**IMPRESSION : THE ABOVE EXAMINATION IS WITHIN NORMAL LIMITS.**

  
DR. A. J. MAZUMDAR  
MD. DMRE, MDRD

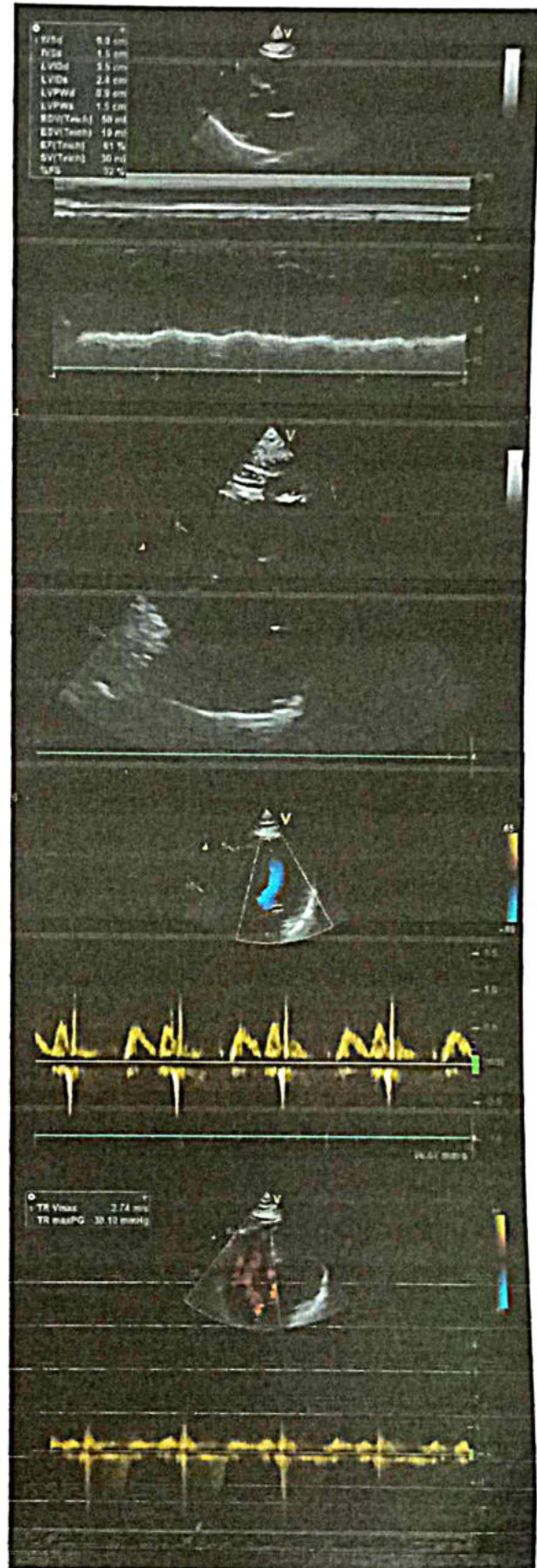
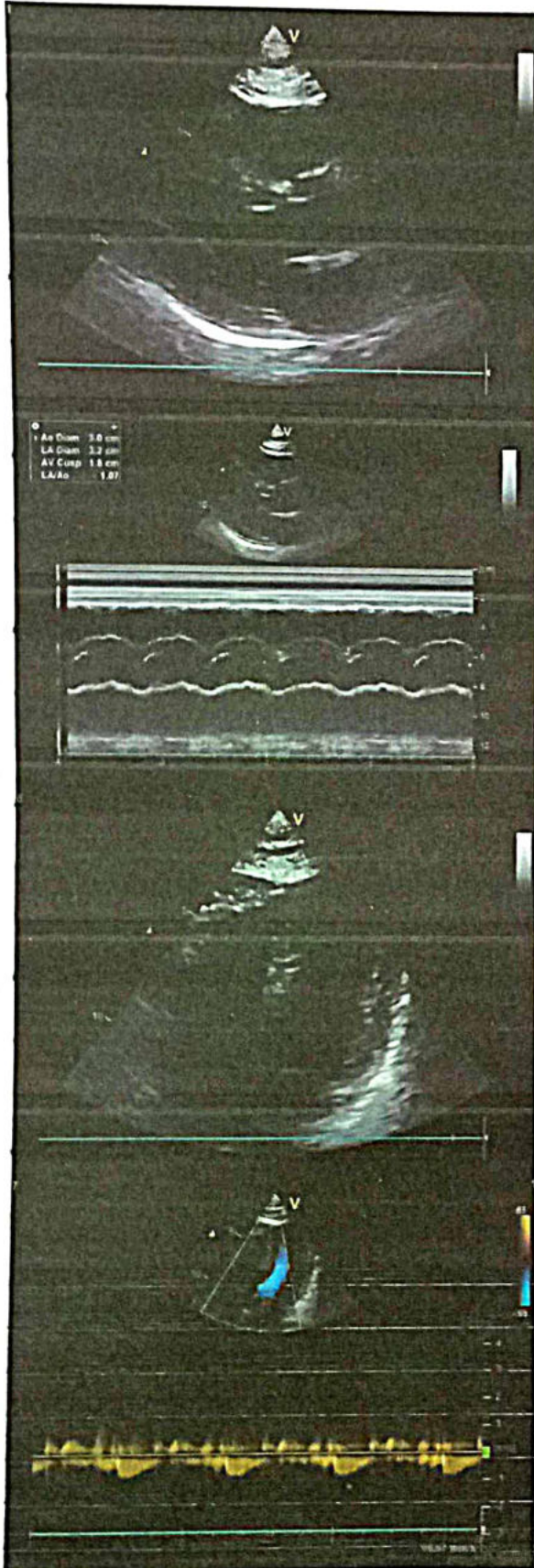
DR. PLUS HEALTHCARE CENTRE  
NATHANI HEIGHTS, B-WING  
42, MUMBAI CENTRAL (EAST)

Name **SHAKEEL SHAIKH**

Sex **Male**

Age **52**

Date **24/09/2022**





NAME : SHAKEEL SHAIKH

52/M


DATE:24/09/2022


REF BY: SELF

## 2D-ECHO. AND COLOR DOPPLER REPORT

- NORMAL CARDIAC VALVES WITH TRIVIAL TR.
- NORMAL CARDIAC CHAMBERS
- NO E/O REGIONAL WALL MOTION ABNORMALITY. WITH NORMAL LVEF OF 60 %.
- E/O MILD PULMONARY HYPERTENSION .PASP 30 mmHg by TR jet.
- NO E/O LEFT VENTRICULAR HYPERTROPHY.
- NO E/O DIASTOLIC DYSFUNCTION.
- NO E/O PERICARDIAL EFFUSION.
- NO E/O INTRACARDIAC CLOT OR VEGETATION
- INTACT IAS / IVS
- CONVENTIONL DOPPLER :
  - E TO A RATIO IS MORE THAN ONE IN LV INFLOW.
  - THERE IS NO GRADIENT ACROSS AV, LVOT OR RVOT
  - PASP FROM TR JET IS 30 mm OF Hg.
- COLOUR DOPPLER:
  - TRIVIAL TR

EF Slope	110	85-120 mm/sec		
Opening Amplitude	23			
Posterior leaflet				
E.P.S.S	02			
Mitral valve prolapse		mm		
Vegetations				
<b>TRICUSPID VALVE</b>	<b>OBSERVED</b>	<b>NORMAL VALUES</b>		
<b>PULMONARY VALVE</b>	<b>OBSERVED</b>	<b>NORMAL VALUES</b>		
EF Slope				
'A' Wave				
Midsystolic notch				
Flutter				
Other Findings				
<b>AORTIC VALVE</b>	<b>OBSERVE</b>	<b>NORMAL VALUES</b>		
Cuspal opening	15	mm		
Closure line	Central			
Eccentricity index	1			
Other Findings				
<b>DIMENSIONS</b>	<b>OBSERVED</b>	<b>NORMAL VALUES</b>		
1. Lvd (Diastolic)	35	26-52		
2. Lvd (Systolic )	24	24-42mm		
3. RVD (Diastolic)	18	7-23mm		
4. IVST (Diastolic)	09	6-11mm		
5. IVST (Systolic )	15			
6. LVPWT (Diastolic)	09	6-11mm		
7. LVPWT (Systolic )	15			
8. Aortic root	32	22-37mm		
9. left Atrium	22	19-40mm		
	<b>STRUCTURE</b>	<b>REGURG GRADING</b>	<b>VELOCITY m/sec</b>	<b>STENOSIS GRADIENT mm/Hg</b>
			Max mean	Peak mean
<b>MITRAL VALVE</b>	NORMAL	0/3	/	/
<b>TRICUSPID VELVE</b>	NORMAL	TRIVIAL	/	/
<b>PULMONARY VELVE</b>	NORMAL	0/4	/	/
<b>AORTIV VALVE</b>	NORMAL	0/4	/	/

  
**DR.P.H.CHHABLANI**  
**M.B.B.S, DNB.(MEDICINE)**  
**CONSULTANT PHYSICIAN AND CARDIOLOGIST.**

  
**DR. P.H. CHHABLANI**  
**M.B.B.S, DNB, Medicine.**  
**Consultant Physician And Intensive**  
**Reg. No. 72898**



# Dr-Plus Healthcare Centre

NATHANI HEIGHTS, B-Wing, Shop No. 42, Ground Floor, Opp. Mumbai Central Station (East), Mumbai - 400 008.

Full Name

SHAIKH SHAKEEL

52/M

24/09/2022

Life to be assured:

	Type of Test	Actual Reading	Normal Range
1	Fasting Blood Sugar	89.9	70-100 mg%
2	PPBS	125.1	110 TO 140 mg%
3	Total Cholesterol	183..5	120-200 mg%
4	VERY LOW DENSINTY LEVEL(VLDL)	14.1	10-30 mg/dl
5	High Density Lipid (HDL)	47.3	40-60 mg%
6	Low Density Lipid (LDL)	122.1	Upto 150
7	S. Triglycerides	115.5	50-150 mg%
8	CHOL/HDL	3.8	Upto 5
9	HDL/LDL	0.3	
10	S. Creatinine	0.9	0.5-1.2 mg%
11	Blood Urea Nitrogen (BUN)	15.1	7-21 mg%
12	BUN/CREAT RATIO	16.7	
13	S. Proteins	6.8	6.0-7.9 mg%
14	(a) Albumin	3.6	3.5-5.5 mg%
15	(b) Globulin	3.2	2.0-3.5 mg%
16	A/G RATIO	1.1	
17	S. Bilirubin	1.1	0.3-1.3mg%
18	(a) Direct	0.6	0.0-0.8 mg%
19	(b) Indirect	0.5	0.0-0.5 mg%
20	SGOT (AST)	22.3	05-34 IU
21	SGPT (ALT)	34.1	05-40 IU
22	GGTP (GGT)	37.5	05-50 IU
23	SGOT/SGPT	0.6	
24	HBA1C	5.6	UPTO 6.5
25	S. Alkaline Phosphatase	100.3	30-115 IU
26	T3	139.2	80-180ng/dl
27	T4	5.6	4.6-12 ug/dl
28	TSH	3.8	0.4-4.0 mIU/L
29	SERUM URIC ACID	4.7	2.5-7.2mg/dl
30	URINE SUGAR PP	ABSENT	
31	URINE SUGAR FASTING	ABSENT	
32	BLOOD GROUP	"B POSITIVE "	

DR. AKESH PATKAR  
M.D., M.B. (Pathology)  
2019/08/1089





# Dr-Plus Healthcare Centre

NATHANI HEIGHTS, B-Wing, Shop No. 42, Ground Floor, Opp. Mumbai Central Station (East), Mumbai - 400 008.

Full Name of life to be assured:

SHAKIL SHAIKH

52/M

24/09/2022

## HAEMOGRAM

		Normal Range	
1.	Red Blood Cell Count	4.9	[M : 4.5 - 5.6 / F : 3.5 - 5.5/cu.mm]
2.	Hb%	15.6	[M: 14-18 / F : 11-16%]
3.	Hematocrit	45.6	[M : 40-53 / F : 30-47 %]
4.	Indices:		
(a)	MCV(Mean Corpuscular Volume)	90.2	[79-101 cu.mi.]
(b)	MCH(Mean Corpuscular Hb)	29.4	[27-32 pg]
(c)	MCHC(Mean Corpuscular Hb Concentration)	35.1	[32-38%]
5.	Morphology		
	Macrocytes :	--	Microcytes: -- Hypochromia: --
	Poikilocytosis: --	Anisocytosis: --	
6.	Target cells: --		
	Spherocytes: --	Elliptocytes: --	
7.	TOTAL W.B.C.Count	6,800	{4000-11000/cu.mm}
Differential Count			
a)	Neutrophils :	59	[45 - 70%]
b)	Lymphocytes :	30	[20 - 45%]
c)	Eosinophils:	05	[01 - 06%]
d)	Monocytes:	05	[00 - 08%]
e)	Basophils :	01	[00 - 01%]
8.	Platelets :3.96		1.5-4.5 Lacks/cu.mm
9.	Erythrocyte Sedimentation Rate: 15		20 mm at end of 1 hour
			Method : Westergrens

## ROUTINE URINE EXAMINATION (RUA)

### 1. Physical Examination

(i)	Colour:	PALE YELLOW	(ii)	Sediment:	CLEAR
(iii)	Transparency:	ABSENT	(iv)	Reaction:	ACIDIC
(v)	Specific gravity	1.010			

### 2. Chemical Examination:

(i)	Protein :	ABSENT	(ii)	Sugar:	ABSENT
(iii)	Bile salt:	ABSENT	(iv)	Bile pigment:	ABSENT

### 3. Microscopic Examination:

(i)	Red Blood Cells:	ABSENT	(ii)	Epithelial Cells:	ABSENT
(iii)	Crystals:	ABSENT	(iv)	Pus Cells:	02 TO 03/HPF
(v)	Casts:	ABSENT	(vi)	Deposits:	ABSENT
(vii)	Bacteria's :	ABSENT			

DR. K. KESHAV PATKAR  
 M.D. (Pathology)  
 Reg. No. 2013/05/1000



# Dr. Hari Chhablani

Cardiometabolic Physician & Intensivist  
M.B.B.S., F.C.C.P. (RESP. MED.), PGDHHM,  
PGDMLS, FELLOW INTENSIVE CARE MED.

ATTACHED TO: Wockhardt Hospital • Saifee Hospital • Apollo Spectra Hospital

NATHANI HEIGHTS, B-Wing, Shop No. 42, Ground Floor, Opp. Mumbai Central Station (East),  
Mumbai - 400 008. • Cell : 98206 46163 • E : drharichhablani@gmail.com

## PHYSICIAN REPORT

DATE : 24/09/2022

NAME : SHAIKH SHAKEEL 52/M

PRESENTING COMPLAINS : NIL

PAST HISTORY : H/O B/L RENAL STONE -2018 .

H/O T.B 14 YEARS AGO - TOOK COMPLETE TREATMENT .

FAMILY HISTORY: NOT SIGNIFICANT.

TREATMENT : NIL

HABITS: NIL

HT.- 168 CM. WT.- 74 Kg. BMI.-26

P: 100/MIN ., REGULAR BP: 120/70

EYE EXAMINATION : NEAR VISION -B/E- N6 , DISTANT VISION -B/E -6/6 COLOR VISION : NORMAL

RS: CLEAR

CVS: S1,S2 REGULAR

PA: SOFT

CNS: CLINICALLY NAD

ENT EXAMINATION : WNL

LABS: ATTACHED

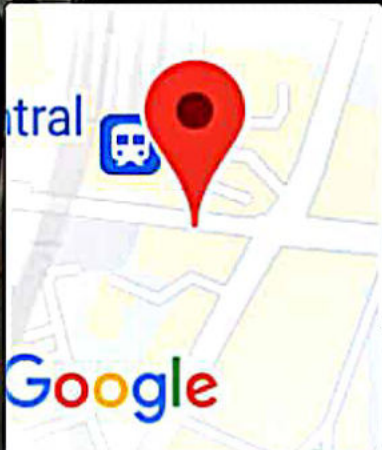
2-D- ECHO : ATTACHED

ECG: ATTACHED

X-RAY : ATTACHED

IMPRESSION : : FIT ON CLINICAL MEDICAL EXAMINATION .

  
DR. HARI CHHABLANI  
M.B.B.S. F.C.C.P. (RESP. MEDICINE) PGDHHM, PGDMLS  
FELLOW INTENSIVE CARE  
MMC REG. NO. - 91702



# Mumbai, Maharashtra, India

Shop No 65, Nathani Heights, Marzban Parsi Colony, Dalal Estate, Mumbai Central, Mumbai, Maharashtra 400008, India

Lat 18.968786°

Long 72.819976°

24/09/22 09:10 AM GMT +05:30