



भारत सरकार
Government of India



UIDAI



प्रिर्ना सुरेश भट्टनागर
Prerna Suresh Bhatnagar
जन्म तारीख/DOB: 18/07/1990
लिंग/ GENDER: FEMALE

5138 1247 4316

VID : 9164 3538 5202 2873

माझी **आधार**, माझी **आकंख**



भारतीय विशिष्ट पहचान प्राधिकरण
Unique Identification Authority of India



पते:
C/O सती अर्जुन धारवार, 264, गवामवाडी, सोवले,
राजशेरी, सोवले, मुंबई
महाराष्ट्र - 410500

Address:
C/O Santosh Arjun Dharwar, 264,
Gavamwadi, Solvare, Solvare,
Rajsheri, Solvare,
Maharashtra - 410510



5138 1247 4316

VID : 9164 3539 5262 2873



1817



help@uidai.gov.in



www.uidai.gov.in

MEDICAL EXAMINATION REPORT

Date – 09/11/2024

Name : Pratima .Santosh . Bhairavkar

Age : 34 years

Gender : Female

Temperature – 98°F Height – 159 cms Weight - 60 kg BMI – 23.7 %

History : Nil significant history .

Past history : Not tested positive for COVID-19 infection till date.

2 Doses Vaccinated.

Personal history : Nil significant history

Neurological history : Nil significant history

Menstrual history : G3P2A1L2D0 , L.M.P – 16/10/2024 , Bleeding 28+/- 3 days, Regular, 2 days bleeding and 3 days spotting.

1st missed abortion at 3 weeks in 2012 at Nawankul hospital sawantwadi by Dr.Nawankul [DNC done]

2nd LSCS -2013 – male – Govt. hospital sawantwadi by Dr.durbhatkar.

3rd LSCS with Tubectomy – 2017 – male – Bhakti hospital sawantwadi by Dr.Dheeraj sawant.

Family history : Mother – Blood cancer under chemo on tablets.

Allergic history : Nil significant history

Nature of work : Sedantary

Occupational history : Assistant Manager at Bank of Baroda .

Ongoing treatment : Nil significant history.

General examination : No Pallor, jaundice, clubbing, cyanosis, lymphadenopathy ,pedal oedema.

Built : Thin

Nutrition : Normal

Pulse : 68 bpm

B.P: 110/70 mmHg

RS: Clear , NAD

CVS: S1S2 normal

CNS: conscious, well oriented

PA: Soft,non-tender ,No organomegaly

Skin: Normal , NAD

Musculoskeletal : NAD

Vision :Without glasses (R)

(L)

Distant : 6/6

Distant : 6/6

Near : N - 6

Near : N - 6

Colour vision : Normal

ENT : NAD


DR.DIGAMBAR.S.NAIK

[M.B.B.S , MD]

[Consultant Physician Cardiologist]

DR. DIGAMBAR NAIK M.D
Consultant Physician Cardiologist
GMC Reg.No. 1238

Patient ID	: 20264	SampleID	: 38309
Patient Name	: Mrs. PRATIMA S BHAIKAVKAR	Receipt Date	: 09-Nov-2024
Age/ Sex	: 34 Years / Female	Report Date	: 09-Nov-2024
Consultant Doctor	: MEDIWHEEL	LabCode	

INVESTIGATION	RESULT	REFERENCE RANGE	UNIT
HAEMATOLOGY			
CBC			
Haemoglobin	15.0	12.5-18.0	gm%
Total Leucocyte Count(TLC)	11600	H 4000-10000	cells/cumm
Differential Leucocyte Count(DLC)			
Neutrophil	80.0	H 50-70	%
Lymphocyte	15.8	L 20-40	%
Monocyte	2.6	0-8	%
Eosinophil	1.5	0-4	%
Basophil	0.10	0-1	%
Packed Cell Volume (PCV)	48.6	H 36-48	%
Total RBC Count	5.34	H 3.5-5.5	millions/cu mm
Platelets Count	3.02	1.45-4.5	lakh/cumm
RBC Indices			
MCV	91.01	80-95	Cu microns
MCH	28.0	26-32	Picograms
MCHC	30.86	L 32-36	g/dl
E.S.R	15	Upto 20	mm/hr
Blood Group			
ABO	'B'		
RH- Typing	POSITIVE		



Dr. Padmanabh Joshi

MD. Pathologist
GMC Reg No. 2720

Patient Name : PRATIMA S BHAIRAVKAR

Receipt Date: 09-Nov-2024

Age/ Sex : 34 Years / Female

Report Date: 09-Nov-2024

Consultant Doctor :- MEDIWHEEL

INVESTIGATION	RESULT	REFERENCE RANGE	UNIT
---------------	--------	-----------------	------

TEST NAME	VALUE	UNITS	NORMAL RANGE
BUN	7	mg/dl	7-20
CREATININE	0.8	mg/dl	0.5-1.5
BUN/SR. CREATININE RATIO	8	Ratio	



Dr. Padmanabh Joshi

MD, Pathologist
GMC Reg No. 2720

Patient Name	: PRATIMA S BHAIRAVKAR	Receipt Date: 09-Nov-2024
Age/ Sex	: 34 YEARS / Female	Report Date: 09-Nov-2024
Consultant Doctor	: MEDIWHEEL	
INVESTIGATION	RESULT	REFERENCE RANGE UNIT

BIOCHEMISTRY

BLOOD SUGAR FASTING

Blood Sugar (F) 88 70-110 mg/dl

BLOOD SUGAR POST PRANDIAL

Blood Sugar (PP) 93 80-140 mg/dl

HbA1c- GLYCOSYLATED HAEMOGLOBIN
(EDTA SAMPLE)

HbA1c : 5.3 **DIAGNOSTIC REFERENCE RANGE**

Non-diabetic: 4.5 -6.5 %

THERAPEUTIC GOALS FOR GLYCEMIC CONTROL

Ideal control: 6.0-7.0

Good control: 7.0-8.0

Poor control: > 8.0
mg/dl

Estimated Average : 111



Dr. Padmonabh Joshi

MD Pathologist
GMC Reg No. 2720

Patient Name : PRATIMA S BHAIRAVKAR
Age/ Sex : 34 Years / Female
Consultant Doctor :- MEDIWHEEL

Receipt Date: 09-Nov-2024
Report Date: 09-Nov-2024

INVESTIGATION	RESULT	REFERENCE RANGE	UNIT
---------------	--------	-----------------	------

BIOCHEMISTRY

LIPID PROFILE

Cholesterol	171	upto 200	mg/dl
Triglyceride	96	60-165	mg/dl
HDL (High Density Lipoprotein)	48	35-55	mg/dl
LDL (Low Density Lipoprotein)	103.60	80-120	mg/dl
VLDL (Very Low Density Lipoprotein)	19.20	5-30	mg/dl
CHOL:HDL	3.56	0-4.4	mg/dl
LDL:HDL RATIO	2.1	BELOW 5.0	mg/dl



Dr. Padmanabh Joshi



MD. Pathologist
GMC Reg No. 2720

Patient ID	: 20264	SampleID	: 38309
Patient Name	: Mrs. PRATIMA S BHAIRAVKAR	Receipt Date	: 09-Nov-2024
Age/ Sex	: 34 Years / Female	Report Date	: 09-Nov-2024
Consultant Doctor	: MEDIWHEEL	LabCode	

INVESTIGATION	RESULT	REFERENCE RANGE	UNIT
---------------	--------	-----------------	------

BIOCHEMISTRY

Complete Liver Profile

Bilirubin Total	1.0	upto 1.0	mg/dl
Direct Bilirubin	0.22	upto 0.3	mg/dl
Indirect Bilirubin	0.78	upto 0.9	mg/dl
S.G.O.T	27	upto 45	IU/L
S.G.P.T	21	upto 49	IU/L
GAMMA GT	20	9-39	U/L
Alkaline Phosphatase	178	110-310	U/L
Total Protein	6.7	6.5-8.5	gm/dl
Albumin	4.7	3.2 - 5.5	gm/dl
Globulin	2.00	1.8 - 3.6	gm/dl
Albumin:Globulin	2.35	1.1 - 2.2 : 1	

Complete Renal Profile

Blood UREA	18	15-45	mg/dl
BUN	7	7-20	mg/dl
Sr. CREATININE	0.8	0.5-1.5	mg/dl
URIC ACID	5.0	2.5-6.5	mg/dl

Dr. Padmanabh Joshi




MD Pathologist
GMC Reg No. 2720

Patient ID	: 20264	SampleID	: 38309
Patient Name	: Mrs. PRATIMA S BHAIRAVKAR	Receipt Date	: 09-Nov-2024
Age/ Sex	: 34 Years / Female	Report Date	: 09-Nov-2024
Consultant Doctor	: MEDIWHEEL	LabCode	

INVESTIGATION	RESULT	REFERENCE RANGE	UNIT
---------------	--------	-----------------	------

URINE ANALYSIS

Urine Routine/Microscopic Exam

PHYSICAL EXAMINATION

COLOUR	PALE YELLOW		
APPEARANCE	SLIGHTLY HAZY		
SP.GRAVITY	1.020	1.003-1.030	

CHEMICAL EXAMINATION

REACTION	ACIDIC
SUGAR	NIL
ALBUMIN	NIL
UROBILINOGEN	NORMAL
KETONE BODIES	ABSENT
BLOOD	ABSENT
LEUKOCYTES	ABSENT

MICROSCOPIC EXAMINATION

PUS CELLS	4-5		
RBC's	NIL	0-2	/HPF
EPITHELIAL CELLS	10-12	0-6	/HPF
CRYSTALS	ABSENT		/HPF
CASTS	ABSENT		
BACTERIA	PRESENT(FEW)		
YEAST CELLS	BUDDING YEAST SEEN (FEW)		



Dr. Padmanabh Joshi

MD. Pathologist
GMC Reg No. 2770

LABORATORY TEST REPORT

Patient Name **Mrs PRATIMA BHAIRAWKAR**

Age : 34 Year(s) Gender : Female

Sample ID : 20834756

Sample Type : Serum

Patient ID : 2473876

Ref. Doctor :

Ref. Customer :

Lab Code : CPC-GO-020

Sample Collection Date : 2024-11-09 10:00

Registration Date : 2024-11-09 13:15

Approved Date : 2024-11-09 14:02



CLINICAL BIOCHEMISTRY

Test Description	Result	Units	Biological Reference Ranges
Thyroid Profile I			
T3-Total, Triiodothyronine (TT3) <small>(Method: Trichloroacetic acid)</small>	147.90	ng/dl	60 - 200 Pregnancy: 1st Trimester: 81 - 190 2nd & 3rd Trimester: 100 - 260
T4-Total, Thyroxine (TT4) <small>(Method: Trichloroacetic acid)</small>	10.57	ug/dL	5.5 - 11.0 1st Trimester: 4.6 - 15.5 2nd & 3rd Trimester: 4.6 - 18.5
Thyroid Stimulating Hormone (TSH) <small>(Method: Macrohomology Class II Monoclonal Antibody)</small>	1.33	uIU/ml	0.35 - 5.40 Pregnancy: 1st Trimester: 0.6 - 3.4 2nd Trimester: 0.37 - 3.6 3rd Trimester: 0.38 - 4.0

Thyroid Function Test Interpretation

The thyroid gland is not functioning properly due to one of a variety of disorders, then increased or decreased amounts of thyroid hormones may result. When TSH concentrations are increased, the thyroid will make and release inappropriate amounts of T4 and T3 and the person may experience symptoms associated with hypothyroidism. If there is decreased production of thyroid hormones, the person may experience symptoms of hyperthyroidism.

The following table summarizes some examples of typical test results and their potential meaning.

TSH	Free T4	Total T3	Conditions
Normal	Normal	Normal	None
Low	High	High	Hyperthyroidism
High	Normal	Normal	Mild (Subclinical) Hypothyroidism
High	Low	Lower than normal	Hypothyroidism
Low	Normal	Normal	Mild (Subclinical) Hyperthyroidism
Low	High or normal	High or normal	Hyperthyroidism
Low	Low or normal	Low or normal	Primary (non-toxic) hypothyroidism
Normal	High	High	Thyroid hormone resistance syndrome

Notes:

- The above test results alone are not diagnostic but will prompt a health practitioner to perform additional testing to investigate the cause of the excess or deficiency and thyroid disorder. As examples, the most common cause of hyperthyroidism is Graves disease and the most common cause of hypothyroidism is Hashimoto's thyroiditis.
- Recommended test for T3 and T4 is unbound fraction or free levels as it is metabolically active.
- Physiological rise in total T3 / T4 levels is seen in pregnancy and in patients on steroid therapy.

-End of Report-

M Ramesh Babu
Manager Lab Operations



Dr. Inahanna Alha De Souza
MD, Pathologist

Patient Name : PRATIMA S. BHAIKAVKAR

Receipt Date: 09-NOV-2024

Age/ Gender : 34 Years / Female

Report Date : 11-NOV-2024

Referred by : MEDIWHEEL

CYTOPATHOLOGY REPORT

Specimen: Pap smear

No of smears: 2 - Conventional smears

Microscopy: Smears satisfactory for evaluation

Superficial and intermediate squamous epithelial cells noted.

Few clue cells seen.

Dense neutrophilic infiltrate and clotted bacilli noted in the background.

No evidence of fungi in smears examined.

No evidence of atypia/ dysplasia/ malignancy in smears examined.

Impression: NILM - Negative for intraepithelial lesion/ malignancy

Advise: Kindly correlate with clinical findings.

Pradnya
Dr. Pradnya N. Reddy
M.B.B.S., M.D. Pathology
GMC Reg. No. 5184

Name : BHAI RAUKAR PRATIMA

Gender : Female

Date of Birth : 09/07/1990

Case ID : 4333

Height : 0 cm(s)

BSA : 0

Age : 34 Years 1, 3 Month(s), 21 Day(s)

Weight : 0.0 Kg(s)

BMI : 0

BP : 120/80 mmHg

Date of Echo : 09/11/2024 12:51:44 PM

Date of Report : 09/11/2024

Reason for Echo : Routine checkup

Referred By : None

Clinic Observations :

Examined By : Dr. Digambar Naik

Echocardiography Report

Echocardiographic study was done by using:

1. M Mode Echocardiography
2. Two Dimensional Echocardiography
3. Conventional and Colour Doppler Echocardiography
4. Tissue Doppler
5. Speckle Tracking and Strain Imaging

Echo Window: Good

Following observations were obtained

Valves

Mitral valve	: Regurgitation Severity : Trace
Aortic valve	: Aortic Regurgitation Severity : Trace (Trivial)
Pulmonary valve	: Normal in size and contractility
Tricuspid valve	: Normal in size and contractility

Chambers

Left atrium	: Normal in structure and opens and closes normally
Left ventricle	: Normal in structure and opens and closes normally
Right atrium	: Normal in structure and opens and closes normally
Right ventricle	: Normal in structure and opens and closes normally

Artery Relation

Aorta	: Normal in size and structure
Pulmonary Artery	: Normal in size and structure

Vein Relation

IVC	: Normal in size and contractility
Pulmonary Vein	: Normal in size and contractility

Regional Wall Motion

Anterior wall	: Contracts well
Posterior wall	: Contracts well
Inferior wall	: Contracts well
Lateral wall	: Contracts well
Anterior septum	: Contracts well
Inferior septum	: Contracts well
Apex	: Contracts well

Ventricular Function

Left Ventricular Function	: Normal
Right Ventricular Function	: Normal

Pericardium

Pericardium	: Normal
Pericardial Effusion	: Nil

Intracardiac

Intracardiac Clot	: Nil
Intracardiac Tumour	: Nil
Interatrial Septum	: Normal
Interventricular Septum	: Normal

Ejection Fraction

Value of EF	: 59.00 %
-------------	-----------

Speckle Tracking

Average peak systolic strain is	: -19.70 %
Reduced peak systolic strain over	: None

Special Observation

Nil

Impressions

Cardiac chambers are normal in dimension and function.
Great vessels are normal in size and function.
No Diastolic Dysfunction.

No Regional wall motion abnormality noted
Normal RV Function
Normal PA pressures
No vegetation
No pericardial effusion noted
No intracavitary clots seen
Normal testing left ventricular systolic function with Ejection Fraction 59%


Trivial aortic regurgitation
Trivial mitral regurgitation

Conclusions

Essentially normal heart echo study

Doctor's Comments / Advice

Medical Line of Management



Dr. Digambar Naik

M.D. (Med) D.O.L.I., F.I.A.F., D.R.A., F.A.I.M.P (Cardiology)
KMU registration: 163056



Name : BHAIRAUKAR PRATIMA

Case ID : 4533

Gender : Female

Date of Birth : 19/07/1990

Age : 34 Year(s), 3 Month(s), 21 Day(s)

Height : 0 cm(s)

BSA : 0

BP : 120/80 mmHg

Weight : 0.0 Kg(s)

BMI : 0

Date of Report : 09/11/2024

Date of Echo : 09/11/2024 17:51:41 PM


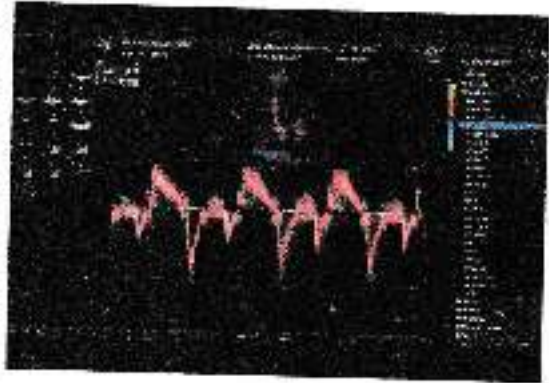

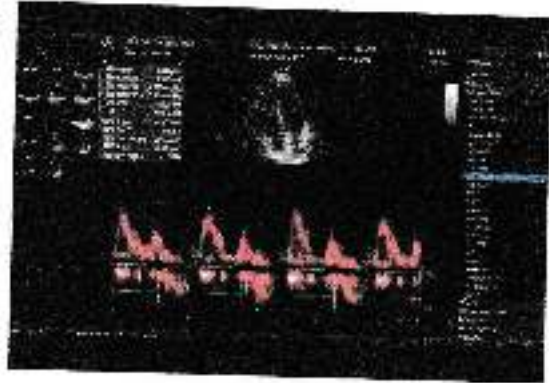
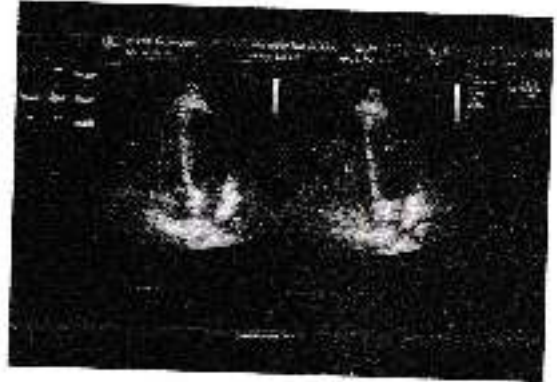
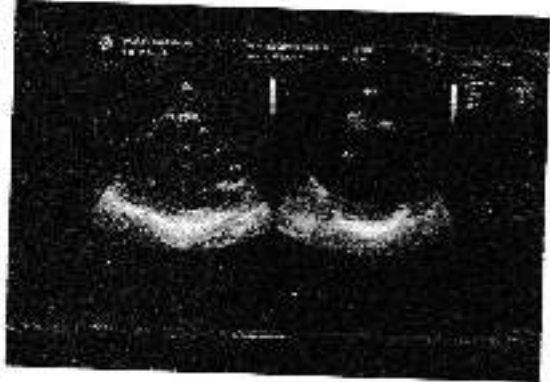
Referred By : None

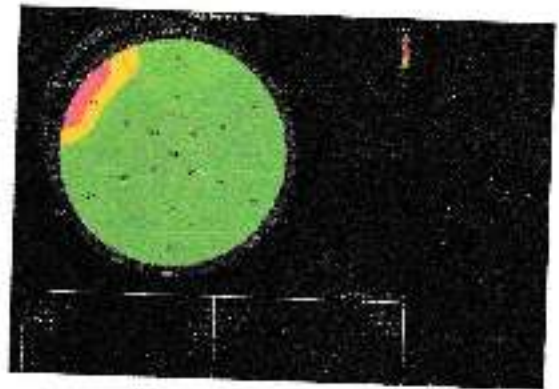
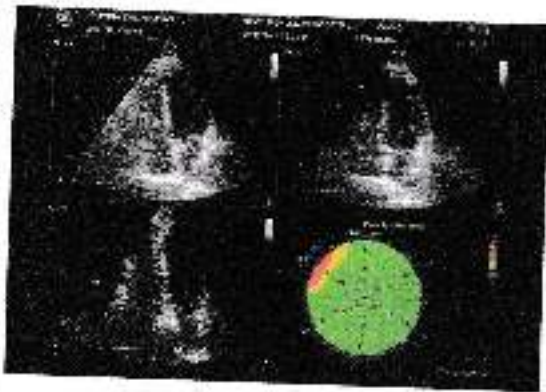
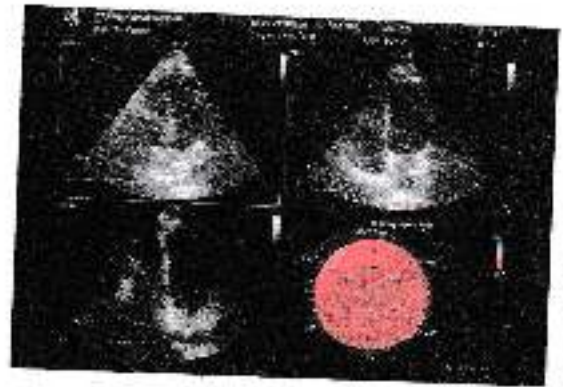

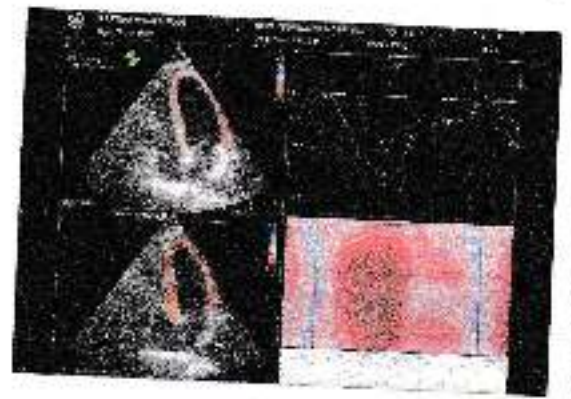

Reason for Echo : Routine checkup

Examined By : Dr. Digambar Nark

Clinic Observations :

Critical Image





Name : BHAIKUMAR PRATIMA

Gender : Female

Date of Birth : 19/07/1990

Case ID : 4313

Height : 0 cm(s)

BSA : 0

Age : 34 Year(s), 3 Month(s), 21 Day(s)

Weight : 0.0 Kg(s)

BMI : 0

BP : 120/80 mmHg

Date of Echo : 09/11/2024 12:51:44 PM

Date of Report : 09/11/2024

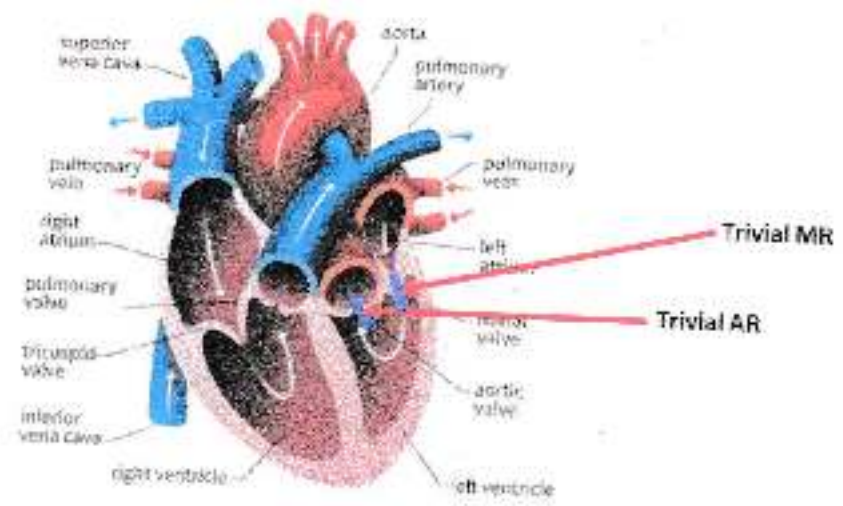
Reason for Echo : Routine checkup

Referred By : None

Examined By : Dr. Digambar Naik

Clinic Observations :

Heart Anatomy



Name : BHAIRAJKAR PRATIMA

Gender : Female

Height : 0 cm(s)

Weight : 0.0 Kg(s)

Date of Echo : 09/11/2024 12:51:44 PM

Reason for Echo : Routine checkup

Click Observations :

Date of Birth : 19/07/1960

BSA : 0

BMI : 0

Case ID : 4733

Age : 24 Year(s), 3 Month(s), 21 Day(s)

BP : 120/80 mmHg

Date of Report : 09/11/2024

Referred By : None

Examined By : Dr. Digvijay Nair

Measurements

Left Ventricle

Measurement	Measured Value	Extra Detail(s)
Aortic Valve Closure	354 ms	Measurement Method : AFI Selection Status : Most recent value chosen Image Mode : 2D mode
Aortic Valve Closure	354 ms	Measurement Method : AFI Image Mode : 2D mode

Aortic Valve

Measurement	Measured Value	Extra Detail(s)
Peak Gradient	6.1884805368 mm(Hg)	Derivation : Mean Selection Status : Mean value chosen Direction of Flow : Antegrade flow Image Mode : Doppler Pulsed
Peak Gradient	6.1884805368 mm(Hg)	Direction of Flow : Antegrade flow Image Mode : Doppler Pulsed
Peak Velocity	1.2438328401 m/s	Derivation : Mean Selection Status : Mean value chosen Direction of Flow : Antegrade flow Image Mode : Doppler Pulsed
Peak Velocity	-1.2438328401 m/s	Direction of Flow : Antegrade flow Image Mode : Doppler Pulsed

Mitral Valve

Measurement	Measured Value	Extra Detail(s)
Mitral Valve A-Wave Peak Velocity	0.6443124413 m/s	Derivation : Mean Selection Status : Mean value chosen Image Mode : Doppler Pulsed
Mitral Valve A-Wave Peak Velocity	0.6443124413 m/s	Image Mode : Doppler Pulsed
Deceleration Slope	3.1242032393 m/s ²	Derivation : Mean Selection Status : Mean value chosen Direction of Flow : Antegrade flow Image Mode : Doppler Pulsed
Deceleration Slope	3.1242032393 m/s ²	Direction of Flow : Antegrade flow Image Mode : Doppler Pulsed
Deceleration Time	266.3991432 ms	Derivation : Mean Selection Status : Mean value chosen Direction of Flow : Antegrade flow Image Mode : Doppler Pulsed
Deceleration Time	266.3991432 ms	Direction of Flow : Antegrade flow Image Mode : Doppler Pulsed
Mitral Valve E-Wave Peak Velocity	0.8322850862 m/s	Derivation : Mean Selection Status : Mean value chosen Image Mode : Doppler Pulsed
Mitral Valve E-Wave Peak Velocity	0.8322850862 m/s	Image Mode : Doppler Pulsed

Report created by Golden Health Service Pvt. Ltd.

Measurement	Measured Value	Extra Detail(s)
Mitral Valve E to A Ratio	1.2917414174	Derivation : Mean Selection Status : Mean value chosen Image Mode : Doppler Pulsed
Mitral Valve E to A Ratio	1.2917414174	Image Mode : Doppler Pulsed
E Velocity to Annulus E Velocity Ratio	5.1235674174	Derivation : Mean Selection Status : Mean value chosen Image Mode : Doppler Pulsed
F Velocity to Annulus F Velocity Ratio	-5.1235674174	Image Mode : Doppler Pulsed
Peak Tissue Velocity	0.1624424934 m/s	Derivation : Mean Selection Status : Mean value chosen Finding Site : Mitral Annulus Cardiac Cycle Point : Early Diastole Image Mode : Doppler Pulsed
Peak Tissue Velocity	-0.1624424934 m/s	Finding Site : Mitral Annulus Cardiac Cycle Point : Early Diastole Image Mode : Doppler Pulsed



DR. RIVONKAR'S IMAGING CENTRE

B/F 11, Campal Trade Centre, Behind
Military Hospital, Campal, Panaji - Goa.

Clino : (0832) - 2232691 / 2223046 Res. : (0832) - 2462796



ISO 9001:2015
Quality Management System

DR. RAVINDRA J. RIVONKAR
M. B. DMRD, FICR, FAI
Radiologist & Sonologist

- ▶ Fellow of Indian College of Radiology & Imaging
- ▶ Life Member Indian Radiological & Imaging Association
- ▶ International Member of American Roentgen Ray Society

Patient's Name: Mrs Pratima Bhairavkar

Referred by : New Vrundavan

Date: 10.11.2024.

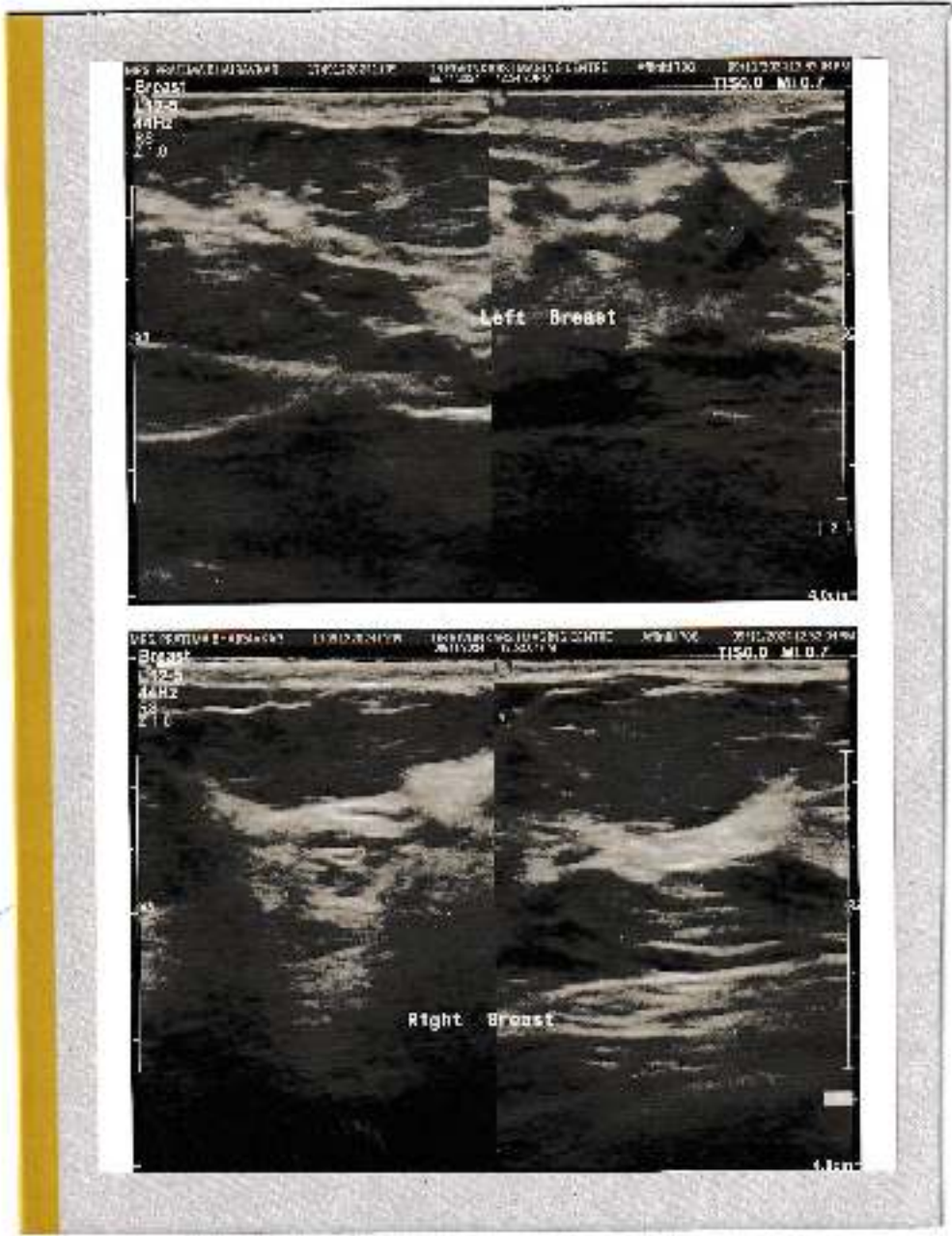
Sonomammography of Both Breasts

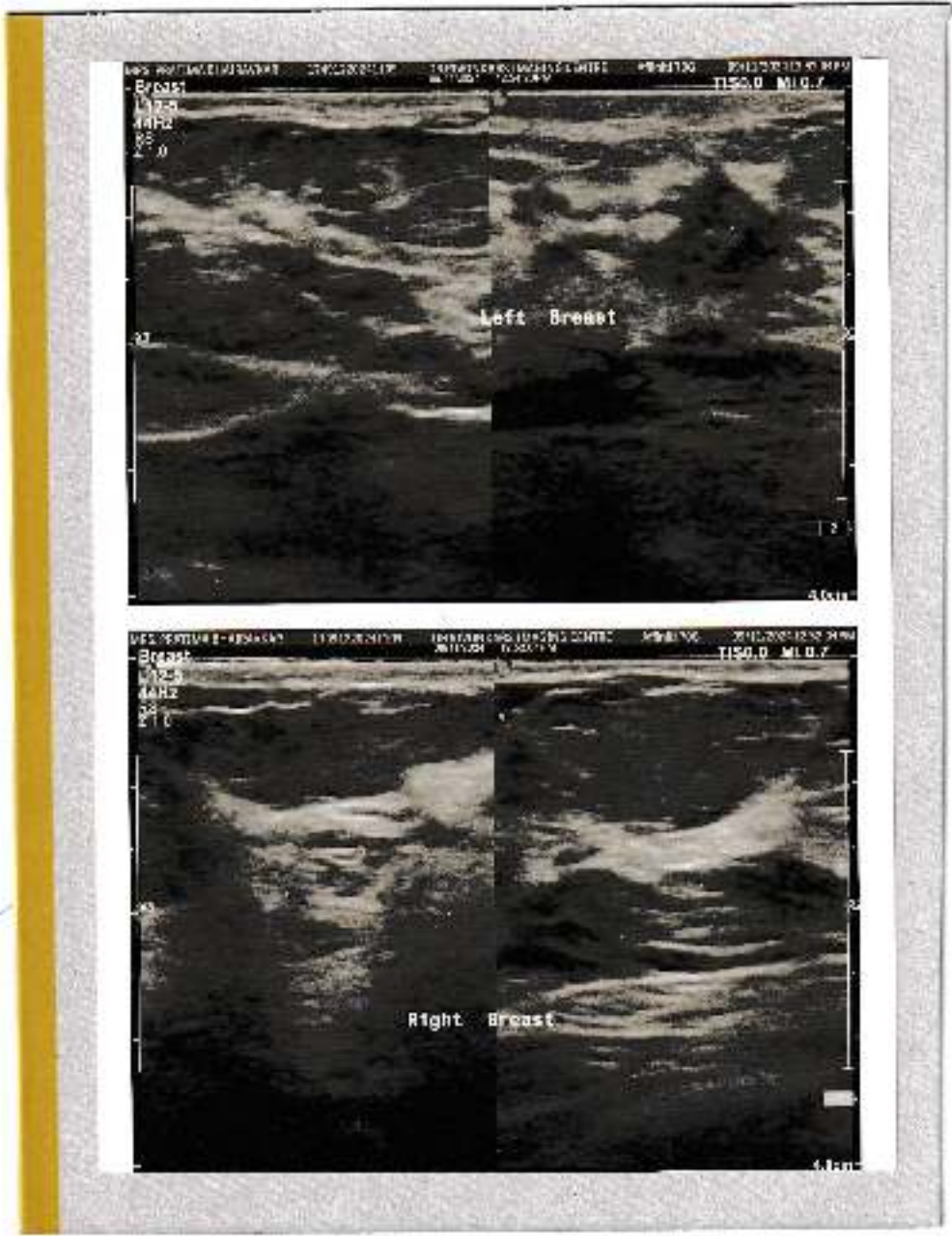
Both breasts show normal subcutaneous tissue with normal breasts parenchyma. No solid or any cystic mass lesion seen. Nipple and retroareolar region shows normal echotexture.

Impression:- No solid or any cystic lesion seen in the breasts.


(Dr. R. J. Rivonkar)







Name : PRATIMA BHAIRAUKAR

Date : 09/11/2024

Age/Sex: 34Yrs/FEMALE

ABDOMINAL/PELVIC ULTRASONOGRAPHY
POCUS- POINT OF CARE ULTRASONOGRAPHY

LIVER	Liver in normal in size. Normal parenchymal echotexture. No focal lesions. Portal vein is normal. Intrahepatic radicals are normal. CBD is normal.
PANCREAS	Head, tail and body of pancreas appear normal No evidence of para aortic lymphadenopathy
GALL BLADDER	Gall bladder is normal in size, shape, position and wall not thickened. No calculi seen.
RIGHT KIDNEY	Right kidney is normal in size, shape and position Corticomedullary differentiation is maintained No hydronephrosis , No calculus seen
LEFT KIDNEY	Left kidney is normal in size, shape and position Corticomedullary differentiation is maintained No hydronephrosis, No calculus seen
SPLEEN	Spleen is normal in size and echotexture Splenic vein is normal.
URINARY BLADDER	Urinary bladder is normal. No stones. No wall thickening.
UTERUS	Normal in size and echotexture
OVARIES	Both appear normal

No free fluid/ pleural effusion is noted

IMPRESSION:

- No significant abnormal findings in ultrasonography.


DOCTOR'S SIGNATURE



NEW VRUNDAVAN HOSPITAL

Dempo Viston, Behind Starbucks,
La Campala Colony, Miramar, Panaji, Goa



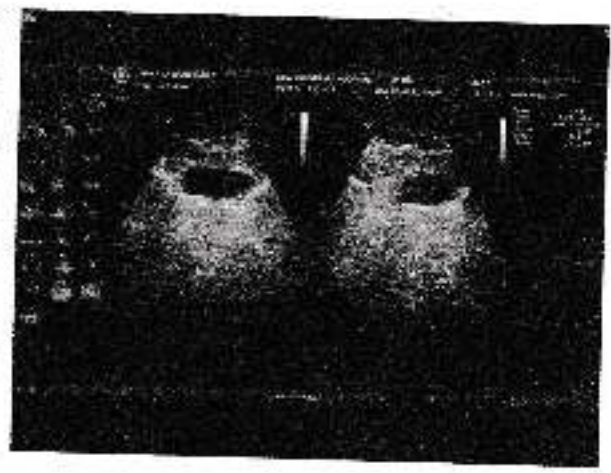
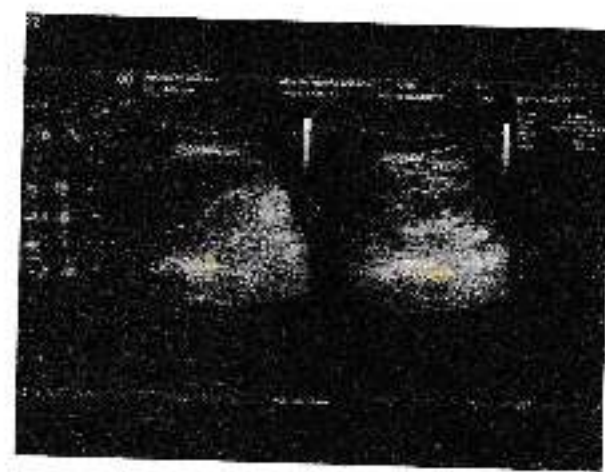
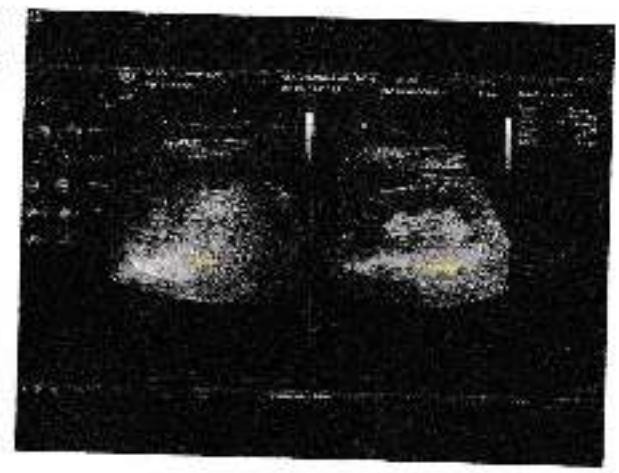
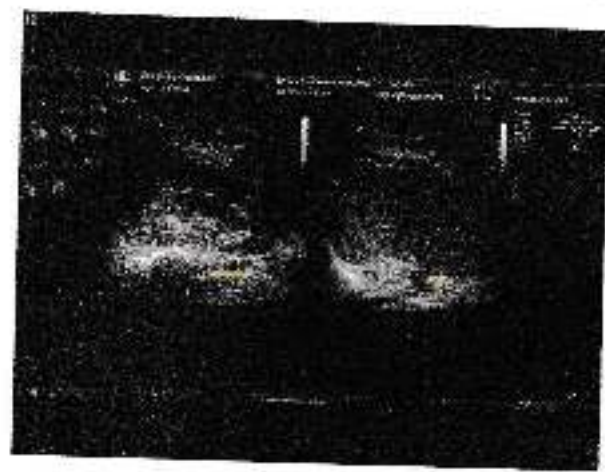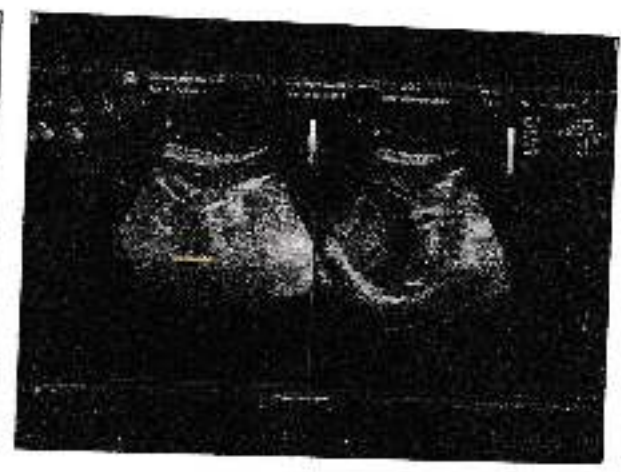
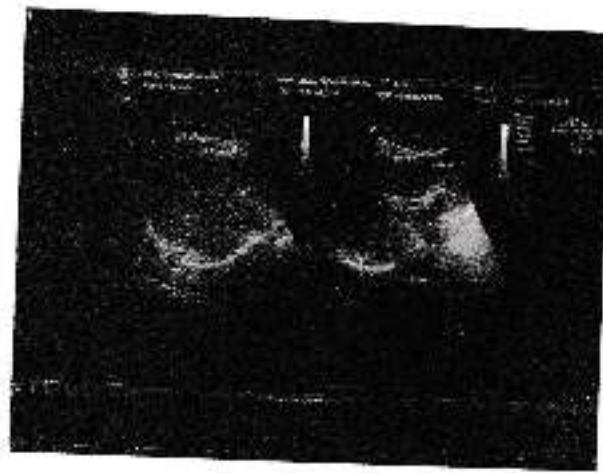
Name **BHAIRAU KAR, PRATIMA**

Date **09/11/2024**

Age **34**

Sex **Female**

ULTRASOUND IMAGES

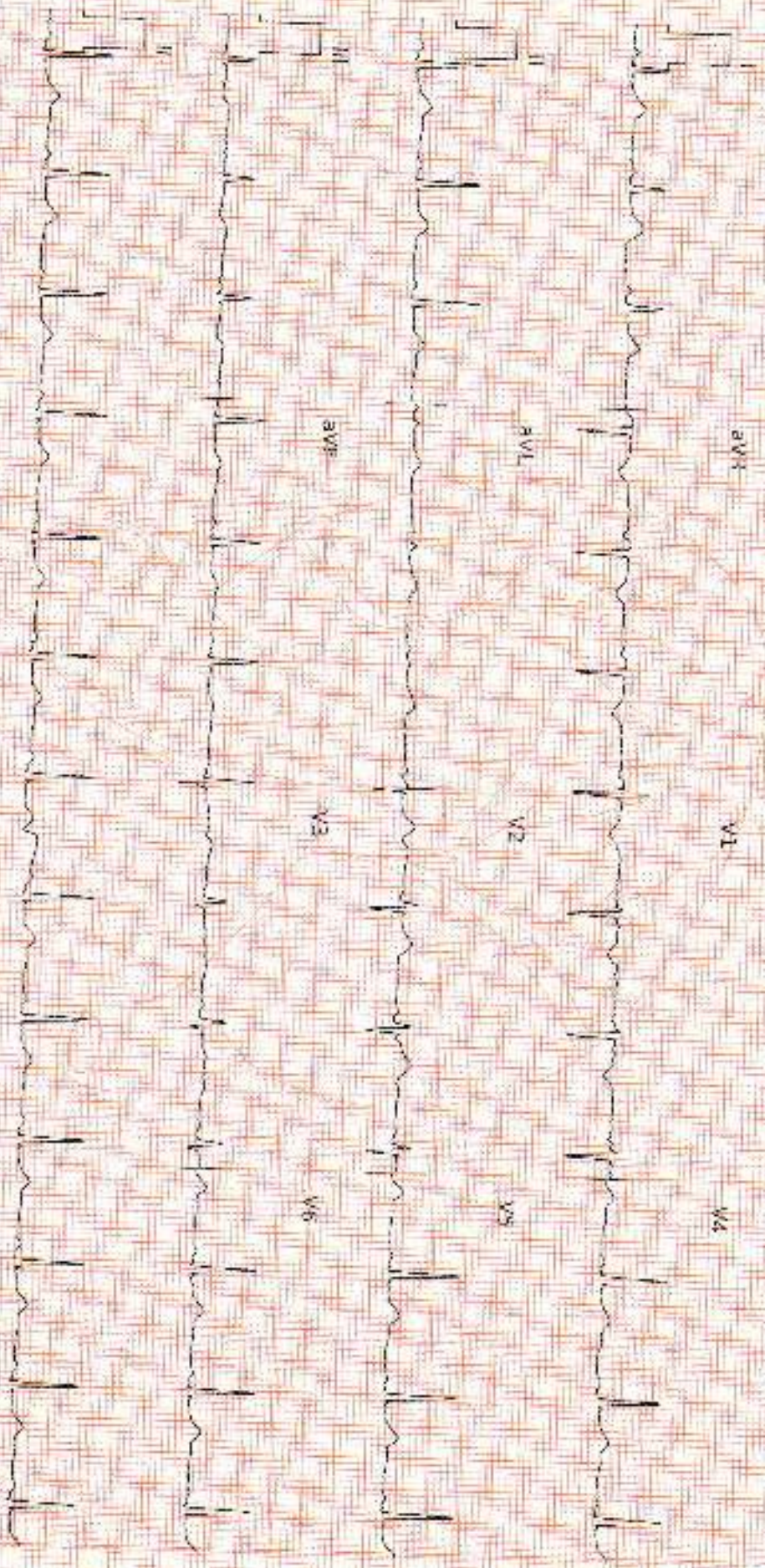


Patient Name: Khatun, Binayaka
Gender: Male, 34 Years
Patient ID: 10000000000000000000

Recording Date: 19-Nov-2024 10:27:18
Location: Khatun Binayaka Diagnostic Centre
Recorded By: Dr. Shalok D. Malik

Heart Rate: 70BPM
Avg. RR: 75BPM
QRS Dur: 88ms

Q/QTc: 39/42ms
P/QTc: 55/31ms
M/QTc: 99ms



Dr. Shalok D. Malik (09-Nov-2024 12:14:29)
Medicine, MBBS, MCh, FRCG



Shalok

After: Khatun Binayaka Medical and Research Centre Ltd. (KBC) is a private diagnostic center, not affiliated with any government or military organization.
Khatun Binayaka Medical and Research Centre Ltd. (KBC) is a private diagnostic center, not affiliated with any government or military organization.

Please note the following health check-up booking summary on 09/11/2024

Subject: Please note the following health check-up booking summary on 09/11/2024

From: "Customer Care (Mediwheel : New Delhi)" <customercare@mediwheel.in>

Date: 09-11-2024, 7:24 am

To: "hospital@newvrundavan.com" <hospital@newvrundavan.com>

9404748374 MRS. BHAIRAVKAR PRATIMA SANTOSH	34 year	Mediwheel Full Body Health Annual Plus Check
SANTOSH ARJUNBHAIKAVKAR	42 year	Mediwheel Full Body Annual Plus Above 50 Male

Thanks & Regards



Arcoferni Health Care Ltd | F-701 A, Laxo Sarai, Mehrauli | New Delhi - 110 030

Ph No. 011-41195859

Email: customercare@mediwheel.in | Web: www.mediwheel.in



GPS Mo
Camera Lit

FRP6+CPG, Dayanand Bandodkar Marg, Miramar, Panaji, Goa
403001, India

Latitude
15.486165°

Longitude
73.8121361°

Local 08:49:09 AM
GMT 03:19:09 AM

Altitude 10 meters
Saturday, 09.11.2024