



Organization is Accredited
by Joint Commission International



Ms. MONA GOHEL (28 /F)

UHID : AHIL.0000820007

AHC No : AHILAH177512

Date : 26/11/2022

MEDIWHEEL-FULL BODY CHK-BELOW40-FEMALE

Dear Ms. MONA GOHEL

Thank you for choosing Apollo ProHealth, India's first personalized, predictive health screening program with health risk assessments curated just for you to guide targeted intervention, continuum of care and a path to wellness. Our holistic care continuum integrates clinical expertise and artificial intelligence to gauge and avert the risk, onset and progression of non-communicable diseases (NCDs).

In this personalized health report, you will find your

- Medical History and Physical examination results
- Investigations Results
- Artificial Intelligence powered risk scores
- Physician's Impressions on your Health
- Path to Wellness: A personalized management protocol, including follow-up assessments
- Vaccination counselling advice

Apollo ProHealth encompasses the following processes:

Personalized Health Risk Assessment (pHRA): Based on your online risk assessment, medical history, physical examination, and psychological evaluation, we recommended a health screening assessment for you, including diagnostic and imaging tests. Based on the results of these assessments, we have advised additional follow-up tests and consultations - details of which we have included in your report. Your physician will explain their relevance, and we strongly suggest you comply with the recommendations.

Health Mentor: We have assigned a dedicated health mentor to proactively work with you towards your health goals and ensure that you regularly adhere to the guidance and recommendations from clinical and nutrition consultants. Your health mentor will call you periodically to track your progress

For Enquiry/Appointments Contact **+91 76988 15003 / +91 79 66701880**

Apollo Hospitals International Limited
Plot No.-1A, Bhat, GIDC, Gandhinagar, Gujarat - 382428, India.
Phone : +91 79 66701800 | Fax No. : +91 79 66701843
E-mail : info@apolloahd.com | www.ahmedabad.apollohospitals.com

Apollo Hospitals - City Centre (NON NASHIJI)
1, TulsiBaag Society Nr. Parimal Garden, Ahmedabad.
Phone : +91 79 66305800 / 01 or +91 76988 15148
E-mail : infoahcc@apolloahd.com

Regd. Office
19, Bishop Gardens, R.A. Puram, Chennai - 600 028
CIN No. : UB5110TN1997PLD0390116 | GSTin : 24AARCA44150H225
For online appointment : www.askapollo.com



For online appointment : www.askapollo.com
Keep the records carefully and bring them along during your next visit to our Hospital



Organization is Accredited
by Joint Commission International



ProHealth App: You will get access to the Apollo ProHealth App, which will facilitate easy navigation of personal health records, progress towards your health goals, appointment booking, customized tips and guidance for health and lifestyle management, and regularly connecting with your Health Mentor through the in-app chat. Until you return for your 2nd-year assessment, you will receive periodic updates and reminders to motivate you to keep up the momentum regarding health goal milestones.

Follow- Up Consultation:

For any follow-up consultations, you can visit your ProHealth physician in-person at the center or you can book a virtual consultation through <https://www.apollo247.com/specialties> or through the Apollo 247 app on your phone.

Scan the QR code to download the Apollo 247 App



You can also download the Apollo 247 app on

ANDROID IOS

Disclaimer: The services offered in the program may vary as per the respective agreements made in the program or center or agreed mutual consent.

Note: You are entitled to one complimentary follow-up consultation with your ProHealth physician within a period of 1 year. Please contact your health mentor for the complimentary consult coupon code. This is available for ProHealth Super, Regal and Covid Recovery and Wellness programs

For Enquiry/Appointments Contact +91 76988 15003 / +91 79 66701880

Apollo Hospitals International Limited
Plot No.-1A, Bhat, GIDC, Gandhinagar, Gujarat - 382428, India.
Phone : +91 79 66701800 | Fax No. : +91 79 66701843
E-mail : info@apolloahd.com | www.ahmedabad.apollohospitals.com

Apollo Hospitals - City Centre (NON MADH-JCI)
1, Tulsibaug Society Nr. Pannal Garden, Ahmedabad.
Phone : +91 79 66305800 / 01 or +91 76988 15148
E-mail : infoahcc@apolloahd.com

Regd. Office
19, Bishop Gardens, R.A. Puram, Chennai - 600 028
CIN No. : U85110IN1997PL0039016 | GSTIN : 24AABC44150H2Z5
For online appointment : www.askapollo.com



For online appointment : www.askapollo.com
Keep the records carefully and bring them along during your next visit to our Hospital



Organization is Accredited
by Joint Commission International



Name : Ms. MONA GOHEL (28 /F)

Date : 26/11/2022

Address :

Examined by : Dr. SHASHIKANT NIGAM

UHID : AHIL.0000820007

MEDIWHEEL-FULL BODY CHK-BELOW40-FEMALE

AHC No : AHILAH177512



Chief Complaints

For Annual health checkup
No specific complaints



Systemic Review

Cardiovascular system : - Nil Significant

Respiratory system : - Nil Significant

Oral and dental : - Nil Significant

Gastrointestinal system : - Nil Significant

Genitourinary system : - Nil Significant

Gynaec history : - Nil Significant

Central nervous system : - Nil Significant

Eyes : - Nil Significant

ENT : - Nil Significant

Musculoskeletal system :

Spine and joints
- Nil Significant

Skin : - Nil Significant



Organization is Accredited
by Joint Commission International



Name : Ms. MONA GOHEL

UHID : AHIL.0000820007

Date : 26/11/2022

MEDIWHEEL-FULL BODY CHK-BELOW40-FEMALE

AHC No : AHILAH177512

General symptoms : - Nil Significant



Past medical history

Do you have any allergies? - No

Do you have any drug allergies? - No



Surgical history

Surgical history - Nil



Personal history

Ethnicity - Indian Asian

Marital status - Married

Profession - corporate employed

Diet - Vegetarian

Alcohol - does not consume alcohol

Smoking - No

Chews tobacco - No

Physical activity - Moderate



Family history

Father - alive

Aged - 55

Mother - alive

Aged - 46

Brothers - 1

Coronary artery disease - none

Cancer - None

Physical Examination



General

General appearance - normal



Organization is Accredited
by Joint Commission International



Name : Ms. MONA GOHEL

UHID : AHIL.0000820007

Date : 26/11/2022

MEDIWHEEL-FULL BODY CHK-BELOW40-FEMALE

AHC No : AHILAH177512

Build	- normal
Height	- 153
Weight	- 49.6
BMI	- 21.19
Pallor	- No
Oedema	- no



Cardiovascular system

Heart rate (Per minute)	- 87
Rhythm	- Regular
	- B.P. Supine
Systolic(mm of Hg)	- 120
Diastolic(mm of Hg)	- 90
Heart sounds	- S1S2+

Respiratory system

Breath sounds	- Normal vesicular breath sounds
---------------	----------------------------------



Abdomen

Organomegaly	- No
Tenderness	- No

Printed By : MUKTA S ADALTI

Page 5 of 12

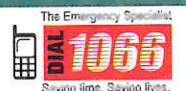For Enquiry/Appointments Contact +91 76988 15003 / +91 79 66701880

Apollo Hospitals International Limited
Plot No.-1A, Bhat, GIDC, Gandhinagar, Gujarat - 382428, India.
Phone : +91 79 66701800 | Fax No. : +91 79 66701843
E-mail : info@apolloahd.com | www.ahmedabad.apollohospitals.com

Apollo Hospitals - City Centre (NON NABH-JCI)
1, Tulsiang Society, Nr. Panimal Garden, Ahmedabad.
Phone : +91 79 66305800 / 01 or +91 76988 15148
E-mail : infoahcc@apolloahd.com

Regd. Office
19, Bishop Gardens, R.A. Puram, Chennai - 600 028
CIN No. : U85110TN1997PL0034016 | GSTin : 24AAABC44150H2Z5
For online appointment : www.askapollo.com

For online appointment : www.askapollo.com
Keep the records carefully and bring them along during your next visit to our Hospital





Organization is Accredited
by Joint Commission International



Name : Ms. MONA GOHEL

UHID : AHIL.0000820007

Date : 26/11/2022

MEDIWHEEL-FULL BODY CHK-BELOW40-FEMALE

AHC No : AHILAH177512

URINE FOR ROUTINE EXAMINATION

Urinalysis, is the physical, chemical and microscopic examination of the urine and is one of the most common methods of medical diagnosis. It is used to detect markers of diabetes, kidney disease, infection etc.

Test Name	Result	Unit	Level	Range
Volume	25	mL		
Specific Gravity	1.005			
Colour:	Pale-Yellow			
Transparency:	Clear			
pH	5.5			
Protein :	Nil			
Sugar:	Nil			
Blood:	Negative			
Ketone	Absent			
Bile Pigments:	Absent			
Urobilinogen	Nil	E.U./dL		
Nitrite	Negative			
Pus Cells	1-2 /h.p.f			0-5
RBC	Nil	/hpf		0-5/hpf
Epithelial Cells	Occasional			
Casts:	Absent			
Crystals:	Absent			

COMPLETE BLOOD COUNT WITH ESR

Test Name	Result	Unit	Level	Range
Hemoglobin (Photometric Measurement)	12	gm%	●	12-16
Packed cell volume(Calculated)	37.4	%	●	36-46
RBC COUNT (Impedance)	4.78	Million/ul	●	3.8-5.2
MCV (From RBC Histogram)	78.2 *	fl	●	80-100
MCH(Calculated)	25.2 *	pg	●	27-32
MCHC(Calculated)	32.2	%	●	31-36
RDW(Calculated)	14.6 *	%	●	11.5-14.5
WBC Count (Impedance)	8147	/cu mm	●	4000-11000

● Within Normal Range ● Borderline High/Low ● Out of Range

For Enquiry/Appointments Contact +91 76988 15003 / +91 79 66701880

Apollo Hospitals International Limited
Plot No.-1A, Bhat, GIDC, Gandhinagar, Gujarat - 382428, India.
Phone : +91 79 66701800 | Fax No. : +91 79 66701843
E-mail : info@apolloahd.com | www.ahmedabad.apollohospitals.com

Apollo Hospitals - City Centre (NON NASHIJD)
1, Tulsihang Society Nr. Parimal Garden, Ahmedabad,
Phone : +91 79 66305800 / 01 or +91 76988 15148
E-mail : infoahcc@apolloahd.com

Regd. Office
19, Bishop Gardens, R.A. Puram, Chennai - 600 028
CIN No. : U85110TN1997PLC0380116 | GSTIN : 24AABCA4150H25
For online appointment : www.askapollo.com





Organization is Accredited
by Joint Commission International



Name : Ms. MONA GOHEL

UHID : AHIL.0000820007

Date : 26/11/2022

MEDIWHEEL-FULL BODY CHK-BELOW40-FEMALE

AHC No : AHILAH177512

Test Name	Result	Unit	Level	Range
Neutrophils	52	%	●	40-75
Lymphocytes	41 *	%	●	20-40
Monocytes	6	%	●	2-10
Eosinophils	1	%	●	01-06
Basophils	0	%	●	0-1
Platelet Count (Impedance)	362800	/cu mm	●	150000-450000
MPV (Calculated)	7.5	fl	●	7-11
ERYTHROCYTE SEDIMENTATION RATE (ESR) (Automated/ optic-electronic)	05	mm/1st hr	●	0-20

URINE GLUCOSE(FASTING)

Test Name	Result	Unit	Level	Range
Urine Glucose (Post Prandial)	Nil			

URINE GLUCOSE(POST PRANDIAL)

Test Name	Result	Unit	Level	Range
Urine Glucose (Post Prandial)	Nil			

BLOOD GROUPING AND TYPING (ABO and Rh)

Test Name	Result	Unit	Level	Range
BLOOD GROUP:	B Positive			

LFT (LIVER FUNCTION TEST)

Liver function tests(LFT), are groups of clinical biochemistry blood assays that give information about the state of a patient's liver. These tests can be used to detect the presence of liver disease, distinguish among different types of liver disorders, gauge the extent of known liver damage, and follow the response to treatment.

Test Name	Result	Unit	Level	Range
ALT(SGPT) - SERUM / PLASMA	12	U/L	●	0-35
ALKALINE PHOSPHATASE - SERUM/PLASMA	111 *	U/L	●	Adult(Female): 35 - 104
AST (SGOT) - SERUM	19	U/L	●	>1 year Female : <32
Total Bilirubin	0.429	mg/dL	●	0.300-1.200
Direct Bilirubin	0.131	mg/dL	●	Upto 0.3 mg/dl

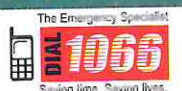● Within Normal Range ● Borderline High/Low ● Out of Range

For Enquiry/Appointments Contact +91 76988 15003 / +91 79 66701880

Apollo Hospitals International Limited
Plot No.-1A, Bhat, GHO, Gandhinagar, Gujarat - 382428, India.
Phone : +91 79 66701800 | Fax No. : +91 79 66701843
E-mail : info@apolloahd.com | www.ahmedabad.apollohospitals.com

Apollo Hospitals - City Centre (NON-MGH-JCI)
1, TulsiBang Society, Nr. Parimal Garden, Ahmedabad.
Phone : +91 79 66305800 / 01 or +91 76988 15148
E-mail : infoahcc@apolloahd.com

Regd. Office
19, Bishop Gardens, R.A. Puram, Chennai - 600 028
CIN No. : U85110TN1997PLG039016 | GSTIN : 24AABCA4150H225
For online appointment : www.askapollo.com



For online appointment : www.askapollo.com
Keep the records carefully and bring them along during your next visit to our Hospital



Organization is Accredited
by Joint Commission International



Name : Ms. MONA GOHEL

UHID : AHIL.0000820007

Date : 26/11/2022

MEDIWHEEL-FULL BODY CHK-BELOW40-FEMALE

AHC No : AHILAH177512

Indirect Bilirubin	0.298	mg/dL	●	1 Day ≤5.1 mg/dL 2 Days ≤7.2 mg/dL 3-5 Days ≤10.3 mg/dL 6-7 Days ≤8.4 mg/dL 8-9 Days ≤6.5 mg/dL 10-11 Days ≤4.6 mg/dL 12-13 Days ≤2.7 mg/dL 14 Days - 9 Years 0.2-0.8 mg/dL 10-19 Years 0.2-1.1 mg/dL ≥20 Years 0.2-1.2 mg/dL
--------------------	-------	-------	---	--

CREATININE - SERUM / PLASMA

Test Name	Result	Unit	Level	Range
CREATININE - SERUM / PLASMA	0.69	mg/dL	●	Adult Female: 0.5 - 1.2

LFT (LIVER FUNCTION TEST)

Liver function tests(LFT), are groups of clinical biochemistry blood assays that give information about the state of a patient's liver. These tests can be used to detect the presence of liver disease, distinguish among different types of liver disorders, gauge the extent of known liver damage, and follow the response to treatment.

Test Name	Result	Unit	Level	Range
GGTP: GAMMA GLUTAMYL TRANSPEPTIDASE - SERUM	14	U/L	●	Male : 10 - 71 Female : 6 - 42

GLUCOSE - SERUM / PLASMA (FASTING)

Test Name	Result	Unit	Level	Range
Glucose - Plasma (Fasting)	93	mg/dL	●	70 - 100 : Normal 100 - 125 : Impaired Glucose Tolerance ≥ 126 : Diabetes Mellitus

GLUCOSE - SERUM / PLASMA (POST PRANDIAL) - PPBS

Test Name	Result	Unit	Level	Range
Glucose - Plasma (Post Prandial)	108	mg/dL	●	70-140

GLYCOSYLATED HEMOGLOBIN (HBA1C) - WHOLE BLOOD

Test Name	Result	Unit	Level	Range
-----------	--------	------	-------	-------

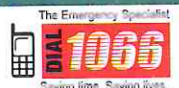● Within Normal Range ● Borderline High/Low ● Out of Range

For Enquiry/Appointments Contact +91 76988 15003 / +91 79 66701880

Apollo Hospitals International Limited
Plot No.-1A, Bhat, GIDC, Gandhinagar, Gujarat - 382428, India.
Phone : +91 79 66701800 | Fax No. : +91 79 66701843
E-mail : info@apolloahd.com | www.ahmedabad.apollohospitals.com

Apollo Hospitals - City Centre (NON NABH-CO)
1, TulsiBaag Society, Nr. Parimal Garden, Ahmedabad.
Phone : +91 79 66305800 / 01 or +91 76988 15148
E-mail : infoahcc@apolloahd.com

Regd. Office
19, Bishop Gardens, R.A. Puram, Chennai - 600 028
CIN No. : U85110TN1997PLCO039016 | GSTin : 24AAHCA44150H225
For online appointment : www.askapollo.com



For online appointment : www.askapollo.com
Keep the records carefully and bring them along during your next visit to our Hospital



Organization is Accredited
by Joint Commission International



Name : Ms. MONA GOHEL

UHID : AHIL.0000820007

Date : 26/11/2022

MEDIWHEEL-FULL BODY CHK-BELOW40-FEMALE

AHC No : AHILAH177512

Glycosylated Hemoglobin (HbA1c)	5.6	%	●	Normal < 5.7
				%Increased risk for Diabetes 5.7 - 6.4%
				Diabetes >= 6.5%
				Monitoring criteria for Diabetes Mellitus <7.0 : Well Controlled Diabetes 7.1 – 8.0 : Unsatisfactory Control > 8.0 : Poor Control & Needs Immediate Treatment
Estimated Average Glucose.	114.02			

LFT (LIVER FUNCTION TEST)

Liver function tests(LFT), are groups of clinical biochemistry blood assays that give information about the state of a patient's liver. These tests can be used to detect the presence of liver disease, distinguish among different types of liver disorders, gauge the extent of known liver damage, and follow the response to treatment.

Test Name	Result	Unit	Level	Range
PROTEIN TOTAL - SERUM / PLASMA	8.05 *	g/dL	●	6.00-8.00
PROTEIN TOTAL - SERUM / PLASMA	8.05 *	g/dL	●	6.00-8.00
ALBUMIN - SERUM	4.9	g/dL	●	Adult(18 - 60 Yr): 3.5 - 5.2
ALBUMIN - SERUM	4.9	g/dL	●	Adult(18 - 60 Yr): 3.5 - 5.2
Globulin-Serum/Plasma	3.15		●	2.20-4.20
Globulin-Serum/Plasma	3.15		●	2.20-4.20
A/G ratio	1.56		●	1.00-2.00
A/G ratio	1.56		●	1.00-2.00

THYROID PROFILE (T3,T4 AND TSH)

Test Name	Result	Unit	Level	Range
TOTAL T3: TRI IODOTHYRONINE - SERUM	2.7	nmol/L	●	Adults(20-120 Yrs): 1.2 - 3.1 Pregnant Female : First Trimester : 1.61 - 3.53 Second Trimester : 1.98 - 4.02 Third Trimester : 2.07 - 4.02
TOTAL T4: THYROXINE - SERUM	119	nmol/L	●	Adults(20-100 Yrs).66 - 181 Pregnant Female : First Trimester : 94.3 - 190 Second Trimester : 102 - 207 Third Trimester : 89 - 202
TSH: THYROID STIMULATING HORMONE - SERUM	2.93	µIU/mL	●	14-120 years : 0.27 - 4.20

● Within Normal Range ● Borderline High/Low ● Out of Range

For Enquiry/Appointments Contact +91 76988 15003 / +91 79 66701880

Apollo Hospitals International Limited
Plot No.-1A, Bhat, GIDC, Gandhinagar, Gujarat - 382428, India.
Phone : +91 79 66701800 | Fax No. : +91 79 66701843
E-mail : info@apolloahd.com | www.ahmedabad.apollohospitals.com

Apollo Hospitals - City Centre (NON-RASH-JCI)
1, Tulshibang Society, Nr. Panimal Garden, Ahmedabad.
Phone : +91 79 66305800 / 01 or +91 79388 15148
E-mail : info@ccc@apolloahd.com

Regd. Office
19, Bishop Gardens, R.A. Puram, Chennai - 600 028
CIN No. : U85110TN1997PLC039016 | GSTin : 24AAABC44150H225
For online appointment : www.askapollo.com



For online appointment : www.askapollo.com
Keep the records carefully and bring them along during your next visit to our Hospital



Organization is Accredited
by Joint Commission International



Name : Ms. MONA GOHEL

UHID : AHIL.0000820007

Date : 26/11/2022

MEDIWHEEL-FULL BODY CHK-BELOW40-FEMALE

AHC No : AHILAH177512

URIC ACID - SERUM

Uric acid is a product of the metabolic breakdown of purine. High blood concentrations of uric acid can lead to gout. It is also associated with other medical conditions including diabetes and the formation of kidney stones.

Test Name	Result	Unit	Level	Range
URIC ACID - SERUM	5.0	mg/dL	●	Male : 3.4-7.0 Female : 2.4-5.7

BUN (BLOOD UREA NITROGEN)

Test Name	Result	Unit	Level	Range
BUN (BLOOD UREA NITROGEN)	7	mg/dL	●	6-20
UREA - SERUM / PLASMA	16	mg/dL	●	15 - 50

LIPID PROFILE - SERUM

Test Name	Result	Unit	Level	Range
Total Cholesterol	196	mg/dl	●	0 - 200 : Desirable 200 - 240 : Borderline High 240 - 280 : High > 280 : Very High
Triglycerides - Serum	111	mg/dL	●	0-150
HDL CHOLESTEROL - SERUM / PLASMA (Direct Enzymatic Colorimetric)	45 *	mg/dL	●	< 40 : Major risk factor for heart disease 40 - 59 : The higher The better. ≥60 : Considered protective against heart disease
LDL Cholesterol (Direct LDL)	142 *	mg/dL	●	100 : Optimal 100-129 : Near Optimal 130-159 : Borderline High 160-189 : High ≥190 : Very High
VLDL CHOLESTEROL	22		●	< 40 mg/dl
C/H RATIO	4		●	0-4.5

X-RAY CHEST PA

X-ray imaging creates pictures of the inside of your body. Chest X-ray can reveal abnormalities in the lungs, the heart, and bones that sometimes cannot be detected by examination.

NORMAL STUDY.

● Within Normal Range ● Borderline High/Low ● Out of Range



Organization is Accredited
by Joint Commission International



Name : Ms. MONA GOHEL

UHID : AHIL.0000820007

Date : 26/11/2022

MEDIWHEEL-FULL BODY CHK-BELOW40-FEMALE

AHC No : AHILAH177512

ECHO/TMT

Investigations Not Done / Not Yet Reported

Haematology

STOOL ROUTINE

Histopathology

CONVENTIONAL PAP SMEAR /CERVICAL SMEAR

CARDIOLOGY

ECG

● Within Normal Range ● Borderline High/Low ● Out of Range

For Enquiry/Appointments Contact +91 76988 15003 / +91 79 66701880

Apollo Hospitals International Limited
Plot No.-1A, Bhat, GIDC, Gandhinagar, Gujarat - 382428, India.
Phone : +91 79 66701800 | Fax No. : +91 79 66701843
E-mail : info@apolloaid.com | www.ahmedabad.apollohospitals.com

Apollo Hospitals - City Centre (NON 24x7-30)
1, Tulshibang Society, Nr. Parnai Garden, Ahmedabad.
Phone : +91 79 66305800 / 01 or +91 78988 15148
E-mail : info@ccc@apolloaid.com

Regd. Office
19, Bishop Gardens, R.A. Puram, Chennai - 600 028
CIN No. : U85110TN1997PLC039016 | GSTin : 24AA8CA4150H225
For online appointment : www.askapollo.com



For online appointment : www.askapollo.com
Keep the records carefully and bring them along during your next visit to our Hospital



Organization is Accredited
by Joint Commission International



Name: Ms. MONA GOHEL


UHID : AHIL.0000820007

Date : 26/11/2022

MEDIWHEEL-FULL BODY CHK-BELOW40-FEMALE

AHC No : AHILAH177512

Executive Summary

-  .BODY WEIGHT 49.6 KG,DEAL BODY WEIGHT 45-53 KG
- .DYSLIPIDEMIA
- .ECG - NORMAL SINUS RHYTHM
- .ECHO - NORMAL
- .USG ABDOMEN - GRADE I FATTY LIVER
- .CHEST X-RAY - NORMAL
- .EYE - NORMAL
- .ENT - NORMAL
- .DENTAL - AS PER DOCTOR ADVICE

Wellness Prescription

Advice On Diet :-

-  BALANCED DIET---
- LOW FAT DIET

Advice On Physical Activity :-

-  REGULAR WALK FOR 30 MINS FOR HEALTH,
- 60 MINS WALK FOR WEIGHT REDUCTION
- PRACTICE YOGA AND MEDITATION
- MAINTAIN WEIGHT BETWEEN 45-53 KG

Follow-up and Review Plan

-  CHECK LIPID PROFILE EVERY 6 MONTHS



Scan the QR code
in AskApollo App
to book your
follow-up
appointments and
investigations

Printed By : MUKTA S ADALTI


Dr. Shashikant Nigam
MBBS, MD (Gen. Med.)
AHC Physician / Consultant Internal Medicine
Apollo Hospitals International Ltd., Gandhinagar,
Gujarat-382428, INDIA. Regd. No.: G-21961


Note :- The Health Check-up examinations and routine investigations have certain limitations and may not be able to detect all the diseases. Any new or persisting symptoms should be brought to the attention of the Consulting Physician. Additional tests, consultations and follow up may be required in some cases.



Organization is Accredited
by Joint Commission International



CARDIOLOGY

Patient Details : Ms. MONA GOHEL | Female | 28Yr 4Mth 14Days
UHID : AHIL.0000820007 **Patient Location:** AHC
Patient Identifier: AHILAH177512 
DRN : 5622088997 **Completed on :** 26-NOV-2022 11:07
Ref Doctor : DR. SHASHIKANT NIGAM

ECHO/TMT

FINDINGS :

Normal cardiac chamber dimensions.
 Normal LV systolic function, LVEF: 60%.
 No Regional wall motion abnormalities at rest.
 Normal LV compliance.
 Mild Mitral valve prolapse.
 Other cardiac valves are structurally normal.
 IAS/ IVS Intact.
 Trivial MR, No AR, Trivial TR.
 No PAH.
 No Clot / Vegetation / effusion.

MEASUREMENTS (mm) ::



Organization is Accredited
by Joint Commission International



Ms. MONA GOHEL

AHIL.0000820007

AHILAH177512

ECHO/TMT

	LVID diastole
Measurements (mm)	.

IMPRESSION

--- END OF THE REPORT ---

DR SUBIR GHOSH MD.DM

Interventional Cardiologist

Printed on : 28-Nov-2022 8:45

Printed By : 153182

Reported By : 1010611

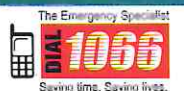Page 2 of 2

For Enquiry/Appointments Contact +91 76988 15003 / +91 79 66701880

Apollo Hospitals International Limited
Plot No.-1A, Bhat, GIDC, Gandhinagar, Gujarat - 382428, India.
Phone : +91 79 66701800 | Fax No. : +91 79 66701843
E-mail : info@apolloahd.com | www.ahmedabad.apollohospitals.com

Apollo Hospitals - City Centre (NON NABH-JCI)
1, TulsiBaag Society, Nr. Panimal Garden, Ahmedabad.
Phone : +91 79 66305800 / 01 or +91 76988 15148
E-mail : infoahcc@apolloahd.com

Regd. Office
19, Bishop Gardens, R.A. Puram, Chennai - 600 028
CIN No. : U85110TN1997PLC039016 | GSTin : 24AARCA4150H225
For online appointment : www.askapollo.com



For online appointment : www.askapollo.com

Visit the website, register and book your appointment before you reach our Hospital


Saving time. Saving lives.



Organization is Accredited
by Joint Commission International



DEPARTMENT OF RADIOLOGY AND IMAGING SCIENCES

Patient Details : Ms. MONA GOHEL | Female | 28Yr 4Mth 14Days
UHID : AHIL.0000820007 **Patient Location:** AHC
Patient Identifier: AHILAH177512 
DRN : 122135395 **Completed on :** 26-NOV-2022 15:19
Ref Doctor : DR. SHASHIKANT NIGAM

X-RAY CHEST PA

FINDINGS :

Lung fields are clear.
 Cardio thoracic ratio is normal.
 Both costophrenic angles are clear.
 Domes of diaphragm are well delineated.
 Bony thorax shows no significant abnormality.

IMPRESSION

NORMAL STUDY.

--- END OF THE REPORT ---


DR. VAIBHAVI PATEL



Organization is Accredited
by Joint Commission International



Radiology

Patient Details : Ms. MONA GOHEL | Female | 28Yr 4Mth 14Days
UHID : AHIL.0000820007 **Patient Location:** AHC
Patient Identifier: AHILAH177512 
DRN : 222061121 **Completed on :** 26-NOV-2022 12:32
Ref Doctor : DR. SHASHIKANT NIGAM

USG WHOLE ABDOMEN

FINDINGS :

Liver appears normal in size and shows uniform normal echotexture. No evidence of focal or diffuse pathology seen. Intra and extra hepatic biliary radicles are not dilated. Portal vein is normal in calibre. Intrahepatic portal radicles appear normal.

Gall bladder appears normal with no evidence of calculus. Wall thickness appears normal. No evidence of pericholecystic collection.

Head, body and tail of pancreas appear normal in size and echotexture. No focal lesions identified Pancreatic duct appears normal in caliber.

Spleen measures 8.7 cms and shows uniform echotexture..

Both kidneys are normal in size and show normal echopattern with good corticomedullary differentiation .Cortical outlines appear smooth. No evidence of calculi. Pelvicalyceal system on both sides appear normal.

No evidence of ascites or lymphadenopathy.

Urinary bladder is normal in contour and outline.Wall thickness appears normal. No evidence of any intraluminal pathology seen.

Uterus measures 6.8 x 4.5 x 3.0 cm. Endometrial thickness is 3 mm.

Uterus is anteverted and appears normal in size and echotexture. No focal lesion is seen.

Myometrial and endometrial echopattern appear normal.

Both ovaries are normal in size and echopattern.

No free fluid is seen in Pouch Of Douglas.

No definite evidence of adnexal/pelvic mass is seen.

Printed on : 28-Nov-2022 8:45

Printed By : 153182

Reported By : 717876

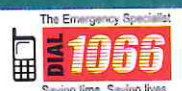Page 1 of 2

For Enquiry/Appointments Contact +91 76988 15003 / +91 79 66701880

Apollo Hospitals International Limited
Plot No.-1A, Bhat, GIOC, Gandhinagar, Gujarat - 392429, India.
Phone : +91 79 66701800 | Fax No. : +91 79 66701843
E-mail : info@apolloahd.com | www.ahmedabad.apollohospitals.com

Apollo Hospitals - City Centre NON NASHIK
1, Tolisbaug Society, Nr. Parimal Garden, Ahmedabad.
Phone : +91 79 66305800 / 01 or +91 76988 15148
E-mail : infoahco@apolloahd.com

Regd. Office
19, Bishop Gardens, R.A. Puram, Chennai - 600 028
CIN No. : U85110TN1997PLC039016 | GSTin : 24AABCA4150H225
For online appointment : www.askapollo.com



For online appointment : www.askapollo.com
Please keep your records safe and bring them along during your next visit to our Hospital

Saving time. Saving lives.



Organization is Accredited
by Joint Commission International



Ms. MONA GOHEL

AHIL.0000820007

AHILAH177512

USG WHOLE ABDOMEN

IMPRESSION :-

Normal study.

— END OF THE REPORT —

A. A. PATEL

Dr. ALPESH A PATEL

DNB Resident

Printed on : 28-Nov-2022 8:45

Printed By : 153182

Reported By : 717876

Page 2 of 2

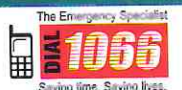For Enquiry/Appointments Contact +91 76988 15003 / +91 79 66701880

Apollo Hospitals International Limited
Plot No.-1A, Bhat, GIDC, Gandhinagar, Gujarat - 382428, India.
Phone : +91 79 66701800 | Fax No. : +91 79 66701843
E-mail : info@apolloahd.com | www.ahmedabad.apollohospitals.com

Apollo Hospitals - City Centre (NON NASH-JCI)
1, Tulshbag Society, Nr. Fauna Garden, Ahmedabad
Phone : +91 79 66701800 / 01 or +91 76988 15148
E-mail : infoahcc@apolloahd.com

For online appointment : www.askapollo.com

Regd. Office
19, Bishop Gardens, R.A. Puram, Chennai - 600 028
CIN No. : U85110TN1997PLC039016 | GSTin : 24AARCA44150H225
For online appointment : www.askapollo.com



Saving time. Saving lives.

Ms Mona, Gehel
ID 820007

26.11.2022 14:47:24
Apollo Hospital
Bhar.
Gandhinagar

Location
Room:
Order Number:
Indication:
Medication 1:
Medication 2:
Medication 3:

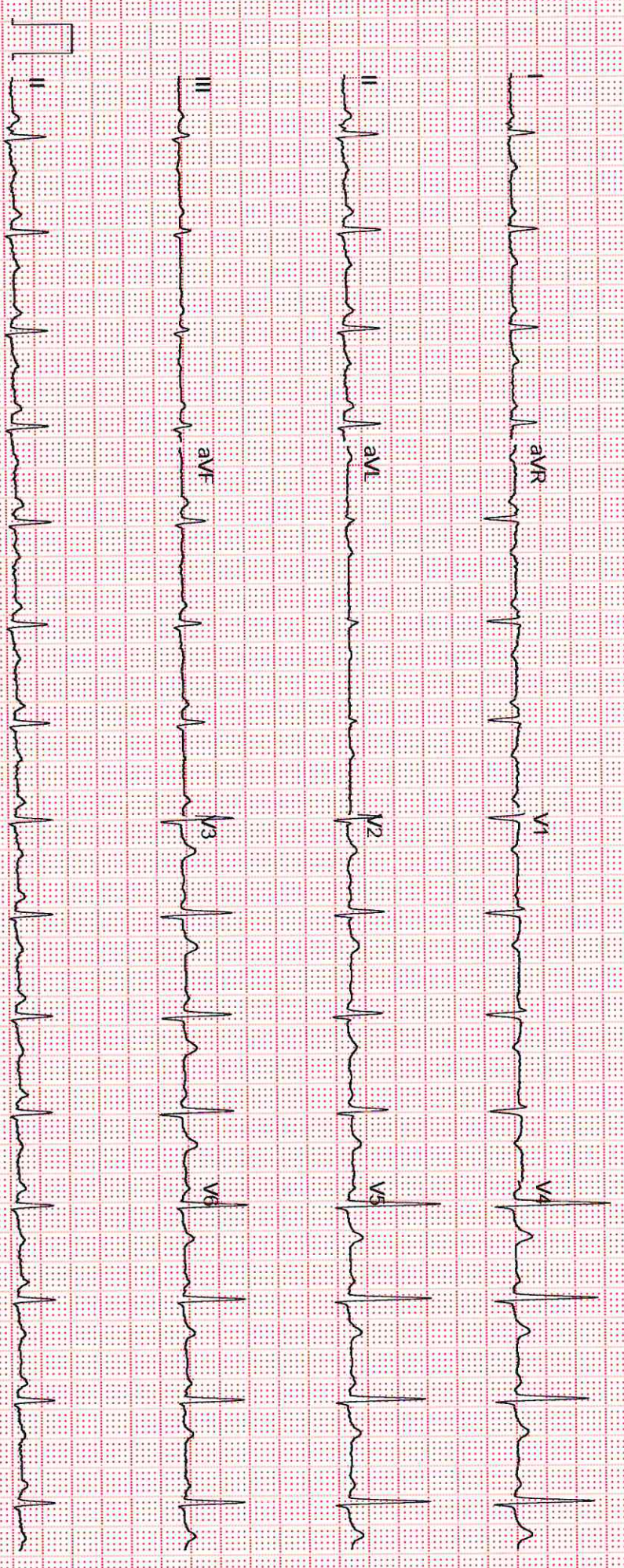
91 bpm
- / - mmHg

28 Years
Male

QRS 70 ms
QT/QTcBaz 336/413 ms
PR 136 ms
P 106 ms
RR/PP 662/659 ms
P/QRS/T 55/48/27 degrees

Normal sinus rhythm
Normal ECG

Technician
Ordering Ph:
Referring Ph:
Attending Ph:



GE MAC2000 1 1 12SL™ V241 25 mm/s 10 mm/mV ADS 0.56 20 Hz 50 Hz 4x2.5x3.25 R1

Unconfirmed


1/1



Organization is Accredited
by Joint Commission International



Radiology

Patient Details : Ms. MONA GOHEL | Female | 28Yr 4Mth 14Days
UHID : AHIL.0000820007 **Patient Location:** AHC
Patient Identifier: AHILAH177512 
DRN : 222061121 **Completed on :** 26-NOV-2022 12:32
Ref Doctor : DR. SHASHIKANT NIGAM

USG WHOLE ABDOMEN

FINDINGS :

Liver appears normal in size and shows uniform normal echotexture. No evidence of focal or diffuse pathology seen. Intra and extra hepatic biliary radicles are not dilated. Portal vein is normal in calibre. Intrahepatic portal radicles appear normal.

Gall bladder appears normal with no evidence of calculus. Wall thickness appears normal. No evidence of pericholecystic collection.

Head, body and tail of pancreas appear normal in size and echotexture. No focal lesions identified Pancreatic duct appears normal in caliber.

Spleen measures 8.7 cms and shows uniform echotexture..

Both kidneys are normal in size and show normal echopattern with good corticomedullary differentiation .Cortical outlines appear smooth. No evidence of calculi. Pelvicalyceal system on both sides appear normal.

No evidence of ascites or lymphadenopathy.

Urinary bladder is normal in contour and outline.Wall thickness appears normal. No evidence of any intraluminal pathology seen.

Uterus measures 6.8 x 4.5 x 3.0 cm. Endometrial thickness is 3 mm.

Uterus is anteverted and appears normal in size and echotexture. No focal lesion is seen.

Myometrial and endometrial echopattern appear normal.

Both ovaries are normal in size and echopattern.

No free fluid is seen in Pouch Of Douglas.

No definite evidence of adnexal/pelvic mass is seen.

For Enquiry/Appointments Contact +91 76988 15003 / +91 79 66701880

Apollo Hospitals International Limited
Plot No.-1A, Bhat, GIDC, Gandhinagar, Gujarat - 382429, India.
Phone: +91 79 66701880 Fax No. +91 79 66701449
E-mail: info@apolloahd.com | www.ahmedabad.apollohospitals.com

Apollo Hospitals - City Centre (NON NASH-IC)
1, TulsiBaag Society, Nr. Parnaj Garden, Ahmedabad.
Phone: +91 79 66305800 Fax No. +91 79 66701880
E-mail: infoahcc@apolloahd.com

Regd. Office
19, Bishop Gardens, R.A. Puram, Chennai - 600 028
CIN No. U18511DN1997PLC0390196377 - 24AABC44150H225
Printed By: 1075754
Referred By: 71786
For online appointment: www.ahd.apollo.com
For online appointment: www.ahd.apollo.com





Organization is Accredited
by Joint Commission International



Ms. MONA GOHEL

AHIL.0000820007

AHILAH177512

USG WHOLE ABDOMEN

IMPRESSION :-
Normal study.

--- END OF THE REPORT ---

A. A PATEL

Dr. ALPESH A PATEL

DNB Resident

For Enquiry/Appointments Contact +91 76988 15003 / +91 79 66701880

Apollo Hospitals International Limited
Plot No.-1A, Bhat, GIDC, Gandhinagar, Gujarat - 382428, India.
Phone: +91 79 66701880 Fax: +91 79 66701843
E-mail: info@apolloind.com | www.aahindia.apollohospitals.com

Apollo Hospitals - City Centre (NON NASH-CC)
1, Tulsibaug Society, Nr. Parimal Garden, Ahmedabad.
Phone: +91 79 30580107 Fax: +91 79 30580154
E-mail: infoahcc@apolloind.com

Regd. Office
19, Bishop Gardens, R.A. Puram, Chennai - 600 028
CIN No: U51909TN1997PLC0390171
E-mail: info@apollo.com | www.ahpollo.com
For online appointment: www.ahpollo.com



For Online appointment: www.ahpollo.com

Keep the records carefully and bring them along during your next visit to our Hospital

Serving since 1983



AHIL.0000820007

Ms. MONA
GOHEL

28 Year(s) / Female



HID,
1

DENTISTRY

Name : Date : 26/11/22 Unit No. :
 Occupation : Ref. Physician :
 Age : Sex : Male Female Copies to :

DENTAL RECORD

ALLERGIES : NA

PAIN : Score (0-10) 0 Location : Character :

DENTAL CLEANING HABIT Once Twice Occasionally
 Brush Finger Stick Any other
 Tooth Paste Powder Any other

DO THE GUMS BLEED WHEN YOU BRUSH YOUR TEETH? Yes No

ARE YOUR TEETH SENSITIVE TO HEAT / COLD? Yes No

ORAL HYGIENE Good Fair Poor

ORAL TISSUE EXAMINATION	PERIODONTAL EXAMINATION	OCCLUSION
NORMAL FINDINGS IN DISEASE	MILD MOD SEV	CLASS I II III CROSSBITE
Lips : Cheeks : Tongue : Floor of the mouth : Palate : Tonsillar Area : Any other :	Gingivitis <input type="checkbox"/> <input type="checkbox"/> <input type="checkbox"/> Calculus <input checked="" type="checkbox"/> <input type="checkbox"/> <input type="checkbox"/> Recession <input type="checkbox"/> <input type="checkbox"/> <input type="checkbox"/> Periodontal Pockets <input type="checkbox"/> <input type="checkbox"/> <input type="checkbox"/> Attrition <input type="checkbox"/> <input type="checkbox"/> <input type="checkbox"/> Erosion <input type="checkbox"/> <input type="checkbox"/> <input type="checkbox"/> Mobility <input type="checkbox"/> <input type="checkbox"/> <input type="checkbox"/>	Hypoplasia Impaction Non-vital Fracture Abscess Ulcers Caries Missing Teeth Supernumerary Others

PRESENT COMPLAINT : Root canal treatment

PRE-MEDICAL HISTORY: DM HTN Thyroid Acidity Pregnancy
 Anticoagulant Under Drug Therapy

NA

OBSTETRICS & GYNAECOLOGY - AHC

Name :	AHIL.0000820007	Date : <u>26/11/2022</u>	Unit No. :
Occupation	Ms. MONA GOHEL	Ref. Physician : <u>Dr. Kirly Nohar</u>	
Age :	28 Year(s) / Female	Copies to :	



GYNAEC CHECK UP

Chief Complaint:

None.

Children: None.

Deliveries: None

Last Child: None

Abortions: None.

Periods: Regular 4-5 days
30-35

LMP: 14/11/2022

Menopause: -

G. Condition: Fit

P/A: Soft

S/E: -

P/V: -

P/R: -

Impression: -

Weight:

BP:

Breasts: Normal.

PAP Smear: Taken.

Previous Medical H/O:

None

f/H/O: None

Previous Surgical H/O:

None.

Kirly

Doctor Signature
Date & Time

26/11/2022
1:33 PM.

AHIL.0000820007

Ms. MONA
GOHEL

28 Year(s) / Female

OPHTHALMI

RECORDS

Date : 26/11/22

Name :



UHID :

Distance Vision :

Right Eye -

6/9

BE 6/8

Left Eye -

6/9

Near Vision :

Right Eye :

NG

Left Eye :

NG

APLN.TN - Right Eye

14

Left Eye -

16

mmHg

Both Eye - Colour Vision

Normal

Both Eye - Anterior Segment Examinations -

WM

Both Eye Posterior Segment Examinations -

WM

Dr

Dr. Jagriti Sinha
MS (Ophthalmology)
Jr. Consultant

Apollo Hospitals International Ltd., Gandhinagar,
Bangalore-560028, INDIA. Regd. No.: G-68792

Doctor's Signature

Ophthalmologist Name