



PANACEA HOSPITAL

B 36/44 F.K KABIR NAGAR, DURGAKUND
TOLLFREE NO-18001233070. Whatsapp No - 8795832852
www.piire.org
panaceaquery@gmail.com|panaceahospitalit@gmail.com



OP Slip

Print Date : 09-Mar-2024 09:30AM



UHID No :- UD-23240006695	OP No :- OP-23240020560	OP Date :- 09 Mar 2024 9:30AM
Patient Name :- Mr PANKAJ KUMAR	Age/Sex :- 33 Y/Male	Mobile No :- 7906461473
Father :- SURAJ PAL SINGH	Department :- OPHTHALMOLOGY	
Pay Type :- Cash	Consultant :- Dr Santosh Verma (MBBS,MS)	
Token No :- NOR. - 1	Paid :- 0.00	
Patient Type :- Normal		
Address :- HNO-421 WARD NO-6 KHATRIVADA SIKANDRABAD BULANDSHAHR 203205,UTTAR PRADESH		

BP :- 110/70
 height :- 162
 Weight (kg) :- 93
 BMI :-
 CH - 115
 AC - 42
 WC - 108
 RR - 64
 SPO₂ - 97
 PEFIR 300

Rx
 A VA 6/6 -- ✕
 6/6 -- ✕
 N6 NG
 N6

Locally BLE
 1-6. Substone ultra GEP
 0000

Dr. SANTOSH VERMA
 MBBS, MS (Ophthalmologist)
 MCI Reg. No. 09-34327

Printed By : Ms. Renuka
 Created By : Ms. Renuka



PANACEA HOSPITAL

B 36/44 F.K KABIR NAGAR, DURGAKUND
TOLLFREE NO-18001233070. Whatsapp No - 8795832852
www.piire.org
panaceaquery@gmail.com|panceahospitalit@gmail.com



OP Slip

Print Date : 09-Mar-2024 09:30AM



UHID No :- UD-23240006695	OP No :- OP-23240020560	OP Date :- 09 Mar 2024 9:30AM
Patient Name :- Mr PANKAJ KUMAR	Age/Sex :- 33 Y/Male	Mobile No :- 7906461473
Father :- SURAJ PAL SINGH	Department :- DENTAL	
Pay Type :- Cash	Consultant :- Dr SHRUTI MISHRA (AA)	
Token No :- NOR. - 1	Paid :- 0.00	
Patient Type :- Normal		
Address :- HNO-421 WARD NO-6 KHATRIVADA SIKANDRABAD BULANDSHAHR 203205,UTTAR PRADESH		

BP :-
height :-
Weight (kg) :-
BMI :-

Rx patient came for routine dental
Checkup
P/c - stains/calculus ++
o/c - proximal caries ++
T/c - Scaling/polishing

Shruti
Dr. SHRUTI MISHRA
BDS, (DENTIST)
MCI Reg. No. (A-09784)

Printed By : Ms. Renuka
Created By : Ms. Renuka



PANACEA HOSPITAL

B 36/44 F.K KABIR NAGAR, DURGAKUND
TOLLFREE NO-18001233070. Whatsapp No - 8795832852
www.piire.org
panaceaquery@gmail.com|panaceahospitalit@gmail.com



OP Slip

Print Date : 09-Mar-2024 09:30AM



UHID No :- UD-23240006695	OP No :- OP-23240020559	OP Date :- 09 Mar 2024 9:30AM
Patient Name :- Mr PANKAJ KUMAR	Age/Sex :- 33 Y/Male	Mobile No :- 7906461473
Father :- SURAJ PAL SINGH	Department :- DERMATOLOGY	
Pay Type :- Cash	Consultant :- Dr DR ASHUTOSH MISHRA (MBBS,MD)	
Token No :- NOR. - 1	Paid :- 0.00	
Patient Type :- Normal		
Address :- HNO-421 WARD NO-6 KHATRIVADA SIKANDRABAD BULANDSHAHR 203205,UTTAR PRADESH		

BP :-
height :-
Weight (kg) :-
BMI :-

Rx

Phair hai tablet or →
 10x1A . m...
 keba...
 10x1A

Adv
 WFG
 20x1A



Printed By : Ms. Renuka
Created By : Ms. Renuka



PANACEA HOSPITAL

B 36/44 F.K KABIR NAGAR, DURGAKUND
TOLLFREE NO-18001233070. Whatsapp No - 8795832852
www.piire.org
panaceaquery@gmail.com|panaceahospitalit@gmail.com



OP Slip

Print Date : 09-Mar-2024 09:29AM



UHID No :- UD-23240006695	OP No :- OP-23240020558	OP Date :- 09 Mar 2024 9:29AM
Patient Name :- Mr PANKAJ KUMAR	Age/Sex :- 33 Y/Male	Mobile No :- 7906461473
Father :- SURAJ PAL SINGH	Department :- GENERAL MEDICINE	
Pay Type :- Cash	Consultant :- Dr Pallavi Mishra (MBBS,MD,MBBS)	
Token No :- NOR. - 3	Paid/Bal :- 0.00 /1030.00	
Patient Type :- Normal		
Address :- HNO-421 WARD NO-6 KHATRIVADA SIKANDRABAD BULANDSHAHR 203205,UTTAR PRADESH		

BP :- 110/70 **Rx**
 height :- 162
 Weight (kg) :- 93 **62**
 BMI :- **BMI**

CH - 115
 NC - 42
 WC - 108
 PR - 64
 SPO2 - 97
 PEF2 - 300

wt loss plany / Examine
 Rx ✓ FOS 5gm < 0 AM

[Signature]
 DR. Pallavi Mishra
 MBBS, MD(GENERAL MEDICINE)
 MCI Reg. No.52033

Printed By : Ms. Renuka
 Created By : Ms. Renuka

Facilities:

All clinical Biomedical & Hematology Investigations including Bone Marrow Examination VPT, Podiascan & Complete Foot Care (First Time in Purvanchal) All Hormonal Investigation by Chemiluminescent Method Visceral Fat by (AB-140) Ambulatory BP Monitoring CGMS & Insulin Pump Available PFT, 2D-ECHO (Color Doppler), Holter, TMT, Cardiac-3 available VIA, VILI, Colposcopy available Special Endocrinological Investigation Protocols.

ISO 9001:2008 Certified
Mobile: 9389994334, 9554572190, 9453837595



Panacea Pathology

Clinical Reference Lab

Persistence, Preparedness and Precision
EQAS (CMC Vellore Attached) & IQAS System
पूर्वांचल की सर्वोत्तम गुणवत्ता वाली पैथोलॉजी

UHID No :- UD-23240006695 **Booking No/Date** :- 70 / 09-Mar-2024 01:14 PM
Patient Name :- Mr PANKAJ KUMAR **Age/Sex** :- 33 Y/M
Father :- SURAJ PAL SINGH **OP No** :- OP-23240020560
Address :- HNO-421 WARD NO-6 KHATRIVADA SIKANDRABAD BULANDSHAHR 203205, UTTAR PRADESH **Mobile No** :- 7906461473
Consultant :- Dr Pallavi Mishra (MBBS,MD)

HAEMATOTOLOGY

Investigations	Observations	Biological Ref. Interval	Unit
CBC			
HAEMOGLOBIN <small>DefaultMethod / test Machine</small>	15.2	13.00 - 16.00	gm/dl
TLC <small>Methology / Carn</small>	6,400	4000.00 - 11000.00	Cells/cumm.
DLC DIFFERENTIAL LEUCOCYTE COUNT			
NEUTROPHILS	63	40.00 - 75.00	%
LYMPHOCYTES	30	20.00 - 45.00	%
EOSINOPHILS	05	1.00 - 6.00	%
MONOCYTES	02	2.00 - 10.00	%
BASOPHILS	00	<1-2	%
PLATELET COUNT	1.79	1.50 - 4.10	lacs /cumm
PCV	45.2	33.00 - 42.00	%
RBC <small>Methology / Carn</small>	4.56	4.50 - 5.50	million/cumm
MCV(MEAN CELL VOLUME)	93.0	83.00 - 101.00	fl
MCH(MEAN CELL HAEMOGLOBIN)	29.1	27.00 - 32.00	pg
MCHC	32.0	31.50 - 35.00	gm%

HAEMATOTOLOGY

ESR 10.0 0.00 - 15.00 mm at 1 hr

BLOOD GROUP ABO & RH FACTOR

Lab Technician

Consulting Pathologist
DR. UMESH KUMAR
M.B.B.S. (PATHOLOGIST)
MCI Reg. No. 41413
M.D., Pathology

Timing : 24/7 hrs

This Report is not valid for medico legal purpose

Note: These tests have technical limitations. Clinico-pathological interpretation is necessary. In case of any disparity test may be repeated immediately.

Address : 36/44 FK Kabir Nagar, Durgakund, Varanasi - 221005

Email: dramishra@gmail.com, drpallaviojha@gmail.com Website: panaceahospital.org

Facilities:

All clinical Biomedical & Hematology Investigations including Bone Marrow Examination VPT, Podiascan & Complete Foot Care (First Time in Purvanchal) All Hormonal Investigation by Chemiluminescent Method Visceral Fat by (AB-140) Ambulatory BP Monitoring CGMS & Insulin Pump Available PFT, 2D-ECHO (Color Doppler), Holter, TMT, Cardiac-3 available VIA, VILI, Colposcopy available Special Endocrinological Investigation Protocols.

ISO 9001:2008 Certified

Mobile: 9389994334, 9554572190, 9453837595



Panacea Pathology

Clinical Reference Lab

Persistence, Preparedness and Precision
EQAS (CMC Vellore Attached) & IQAS System
पूर्वांचल की सर्वोत्तम गुणवत्ता वाली पैथोलॉजी

UHID No :- UD-23240006695 **Booking No/Date** :- 70 / 09-Mar-2024 01:14 PM
Patient Name :- Mr PANKAJ KUMAR **Age/Sex** :- 33 Y/M
Father :- SURAJ PAL SINGH **OP No** :- OP-23240020560
Address :- HNO-421 WARD NO-6 KHATRIVADA SIKANDRABAD BULANDSHAHR 203205, UTTAR PRADESH **Mobile No** :- 7906461473
Consultant :- Dr Pallavi Mishra (MBBS,MD)

Investigations	Observations	Biological Ref. Interval	Unit
BLOOD GROUP	"B"		
RH FACTOR	POSITIVE		
HBA1C -(BY GOLD STANDARD METHOD :HPLC)	5.8	Normal: 4.0 - 5.4 Prediabetic : 5.5 -6.3 Diabetes mellitus := 6.4	%

BIOCHEMISTRY

LIPID PROFILE

TOTAL CHOLESTROL	153.0	Desirable : - < 200 mg/dL Borderline: - 200 - 239 mg/dL High : - > 240mg/dL	mg/dl
TRIGLYCERIDES	148.0	35.00 - 160.00	mg/dl
HDL CHOLESTROL	41.0	35.30 - 79.50	mg/dl
LDL CHOLESTROL	82.4	< 130	mg/dl
VLDL	29.60	< 40	mg/dl
CHOLESTROL/ HDL RATIO	3.73	< 3.0 LOW RISK, 3.0-5.0 AVG RISK, > 5.0 HIGH RISK	ratio
LDL/HDL RATIO	2.01	< 3	ratio

LFT (LIVER FUNCTION TESTS)

TOTAL BILIRUBIN	0.60	0.00 - 1.20	mg/dl
DIRECT BILIRUBIN	0.20	0.00 - 0.30	

Lab Technician

Umesh Kumar
Consulting Pathologist
DR. UMESH KUMAR
MBBS, MD (PATHOLOGIST)
M.C. Pathology 13

Timing : 24/7 hrs

This Report is not valid for medico legal purpose

Note: These tests have technical limitations. Clinico-pathological interpretation is necessary. In case of any disparity test may be repeated immediately.

Address : 36/44 FK Kabir Nagar, Durgakund, Varanasi – 221005

Email: dramishra@gmail.com, drpallaviojha@gmail.com Website: panaceahospital.org

Facilities:

All clinical Biomedical & Hematology Investigations including Bone Marrow Examination
VPT, Podiascan & Complete Foot Care (First Time in Purvanchal)
All Hormonal Investigation by Chemiluminescent Method
Visceral Fat by (AB-140) Ambulatory BP Monitoring
CGMS & Insulin Pump Available
PFT, 2D-ECHO (Color Doppler), Holter, TMT, Cardiac-3 available
VIA, VILI, Colposcopy available
Special Endocrinological Investigation Protocols.

ISO 9001:2008 Certified
Mobile: 9389994334, 9554572190, 9453837595



Panacea Pathology

Clinical Reference Lab

Persistence, Preparedness and Precision
EQAS (CMC Vellore Attached) & IQAS System
पूर्वाचल की सर्वोत्तम गुणवत्ता वाली पैथोलॉजी

UHID No :- UD-23240006695
Patient Name :- Mr PANKAJ KUMAR
Father :- SURAJ PAL SINGH
Address :- HNO-421 WARD NO-6 KHATRIVADA
SIKANDRABAD BULANDSHAHR 203205
, UTTAR PRADESH
Consultant :- Dr Pallavi Mishra (MBBS,MD)

Booking No/Date :- 70 / 09-Mar-2024 01:14 PM
Age/Sex :- 33 Y/M
OP No :- OP-23240020560
Mobile No :- 7906461473

Investigations	Observations	Biological Ref. Interval	Unit
INDIRECT BILIRUBIN	0.40	0.20 - 0.70	mg/dl
SGOT	21.0	2.00 - 31.00	U/L
SGPT	25.0	10.00 - 45.00	U/L
ALKALINE PHOSPHATASE	59.0	25.00 - 140.00	U/L
TOTAL PROTIENS	7.44	6.60 - 8.70	g/dl
ALBUMIN	4.10	3.50 - 5.20	gm%
GLOBULIN	3.34	1.50 - 3.60	gms/dl
A/G RATIO	1.22	2:1	RATIO
YGGT	16.0	10.00 - 50.00	U/L
S.CREATININE	0.76	0.60 - 1.40	mg/dl
BLOOD UREA NITROGEN	10.0	6.00 - 21.00	mg/dl
URIC ACID			
URIC ACID	3.76	3.60 - 7.70	mg/dl
BUN	10.0	7.00 - 21.00	mg/dl

IMMUNOLOGY

THYROID PROFILE (T3,T4,TSH)

T3	0.92	0.60 - 1.81	ng/ml
T4	7.2	4.50 - 10.90	ug/dl

Lab Technician

Consulting Pathologist
DR. UJESH KUMAR
MBBS (PATHOLOGIST)
MCI Reg. No. 44413
M.D., Pathology

Timing : 24/7 hrs

This Report is not valid for medico legal purpose

Note: These tests have technical limitations. Clinico-pathological interpretation is necessary. In case of any disparity test may be repeated immediately.

Address : 36/44 FK Kabir Nagar, Durgakund, Varanasi – 221005

Email: dramishra@gmail.com, drpallaviojha@gmail.com Website: panaceahospital.org

Facilities:

All clinical Biomedical & Hematology Investigations including Bone Marrow Examination
VPT, Podiascan & Complete Foot Care (First Time in Purvanchal)
All Hormonal Investigation by Chemiluminescent Method
Visceral Fat by (AB-140) Ambulatory BP Monitoring
CGMS & Insulin Pump Available
PFT, 2D-ECHO (Color Doppler), Holter, TMT, Cardiac-3 available
VIA, VILI, Colposcopy available
Special Endocrinological Investigation Protocols.

ISO 9001:2008 Certified
Mobile: 9389994334, 9554572190, 9453837595



Panacea Pathology

Clinical Reference Lab

Persistence, Preparedness and Precision
EQAS (CMC Vellore Attached) & IQAS System
पूर्वांचल की सर्वोत्तम गुणवत्ता वाली पैथोलॉजी

UHID No	:- UD-23240006695	Booking No/Date	:- 70 / 09-Mar-2024 01:14 PM
Patient Name	:- Mr PANKAJ KUMAR	Age/Sex	:- 33 Y/M
Father	:- SURAJ PAL SINGH	OP No	:- OP-23240020560
Address	:- HNO-421 WARD NO-6 KHATRIVADA SIKANDRABAD BULANDSHAHR 203205 , UTTAR PRADESH	Mobile No	:- 7906461473
Consultant	:- Dr Pallavi Mishra (MBBS,MD)		

Investigations	Observations	Biological Ref. Interval	Unit
TSH	1.06	0.39 - 6.10	uIU/mL

BIOCHEMISTRY

BLOOD SUGAR FASTING

GLUCOSE	91.0	60.00 - 100.00	mg/dl
PRE-DIABETICS(IMPAIRED FASTING TOLER)	-	100.00 - 125.00	mg/dl
DIABETICS	-	upto 126	mg/dl
TARGET IN DM	-	80.00 - 130.00	mg/dl

PPBS(POST PRANDIAL BLOOD SUGAR)

POST PRANDIAL BLOOD GLUCOSE(2 HR AFTER MEAL)	101.0	110.00 - 150.00	mg/dl
IGT(2 HR 75GM GLUCOSE)	-	140.00 - 199.00	mg/dl
DIABETES	-	upto200	mg/dl
TARGET IN DM	-	80.00 - 130.00	mg/dl


PARASITOLOGY

STOOL ROUTINE

GROSS EXAMINATION

COLOR <i>Methology</i>	YELLOW	CLEAR YELLOW
CONSISTANCY	NORMAL	

Lab Technician


Consulting Pathologist
DR. UMESH KUMAR
MBBS,MD (PATHOLOGIST)
M.D. Pathology

Timing : 24/7 hrs

This Report is not valid for medico legal purpose

Note: These tests have technical limitations. Clinico-pathological interpretation is necessary. In case of any disparity test may be repeated immediately.

Address : 36/44 FK Kabir Nagar, Durgakund, Varanasi - 221005

Email: dramishra@gmail.com, drpallaviojha@gmail.com Website: panaceahospital.org

Facilities:

All clinical Biomedical & Hematology Investigations including Bone Marrow Examination
 VPT, Podiascan & Complete Foot Care (First Time in Purvanchal)
 All Hormonal Investigation by Chemiluminescent Method
 Visceral Fat by (AB-140) Ambulatory BP Monitoring
 CGMS & Insulin Pump Available
 PFT, 2D-ECHO (Color Doppler), Holter, TMT, Cardiac-3 available
 VIA, VILI, Colposcopy available
 Special Endocrinological Investigation Protocols.

ISO 9001:2008 Certified
 Mobile: 9389994334, 9554572190, 9453837595



Panacea Pathology

Clinical Reference Lab

Persistence, Preparedness and Precision
 EQAS (CMC Vellore Attached) & IQAS System
 पूर्वांचल की सर्वोत्तम गुणवत्ता वाली पैथोलॉजी

UHID No :- UD-23240006695
Booking No/Date :- 70 / 09-Mar-2024 01:14 PM
Patient Name :- Mr PANKAJ KUMAR
Age/Sex :- 33 Y/M
Father :- SURAJ PAL SINGH
OP No :- OP-23240020560
Address :- HNO-421 WARD NO-6 KHATRIVADA
 SIKANDRABAD BULANDSHAHR 203205
 , UTTAR PRADESH
Mobile No :- 7906461473
Consultant :- Dr Pallavi Mishra (MBBS,MD)

Investigations	Observations	Biological Ref. Interval	Unit
BLOOD	ABSENT		
MUCUS	ABSENT		
<u>MICROSCOPIC EXAMINATION</u>			
OVA OR EGGS OF HELMINTHS	ABSENT		
CYST OF PROTOZOA	ABSENR		
PUS CELLS	02-03	2.00 - 3.00	/HPF
RBC <i>Methology / Carm</i>	NIL	4.50 - 5.50	million/cumm

URINE EXAMINATION


URINE ROUTINE EXAMINATION

PHYSICAL EXAMINATION

QUANTITY	25		ml
COLOR <i>Methology</i>	STRAW	CLEAR YELLOW	
APPEARANCE <i>DefaultMethod</i>	CLEAR	CLEAR	

CHEMICAL EXAMINATION

SPECIFIC GRAVITY	1.015	1.01 - 1.03	
PH	5.5	4.60 - 8.00	
GLUCOSE	NIL	60.00 - 100.00	mg/dl
PROTEIN-	NIL		


 Consulting Pathologist
 DR. UMESH KUMAR
 MBBS, MD (PATHOLOGIST)
 MID, Pathology 13

Lab Technician

Timing : 24/7 hrs

This Report is not valid for medico legal purpose

Note: These tests have technical limitations. Clinico-pathological interpretation is necessary. In case of any disparity test may be repeated immediately.

Address : 36/44 FK Kabir Nagar, Durgakund, Varanasi – 221005

Email: dramishra@gmail.com, drpallaviojha@gmail.com Website: panaceahospital.org

Facilities:

All clinical Biomedical & Hematology Investigations including Bone Marrow Examination
 VPT, Podiascan & Complete Foot Care (First Time in Purvanchal)
 All Hormonal Investigation by Chemiluminescent Method
 Visceral Fat by (AB-140) Ambulatory BP Monitoring
 CGMS & Insulin Pump Available
 PFT, 2D-ECHO (Color Doppler), Holter, TMT, Cardiac-3 available
 VIA, VILI, Colposcopy available
 Special Endocrinological Investigation Protocols.

ISO 9001:2008 Certified
 Mobile: 9389994334, 9554572190, 9453837595



Panacea Pathology

Clinical Reference Lab

Persistence, Preparedness and Precision
 EQAS (CMC Vellore Attached) & IQAS System
 पूर्वांचल की सर्वोत्तम गुणवत्ता वाली पैथोलॉजी

UHID No :- UD-23240006695 **Booking No/Date** :- 70 / 09-Mar-2024 01:14 PM
Patient Name :- Mr PANKAJ KUMAR **Age/Sex** :- 33 Y/M
Father :- SURAJ PAL SINGH **OP No** :- OP-23240020560
Address :- HNO-421 WARD NO-6 KHATRIVADA **Mobile No** :- 7906461473
 SIKANDRABAD BULANDSHAHR 203205
 , UTTAR PRADESH
Consultant :- Dr Pallavi Mishra (MBBS,MD)

Investigations	Observations	Biological Ref. Interval	Unit
MICROSCOPIC EXAMINATION			
PUS CELLS	01-02	2.00 - 3.00	/HPF
RBCS (RED BLOOD CELLS)	NIL	4.50 - 5.50	/HPF
EPITHELIAL CELLS	NIL		/HPF
CASTS	ABSENT	ABSENT	
CRYSTALS	ABSENT	ABSENT	

* END OF REPORT *

Lab Technician

Timing : 24/7 hrs

This Report is not valid for medico legal purpose

Consulting Pathologist
 DR. UMESH KUMAR
 MBBS, MD (PATHOLOGY)
 M.D. Pathology

Note: These tests have technical limitations. Clinico-pathological interpretation is necessary. In case of any disparity test may be repeated immediately.

Address : 36/44 FK Kabir Nagar, Durgakund, Varanasi – 221005

Email: dramishra@gmail.com, drpallaviojha@gmail.com Website: panaceahospital.org



PANACEA HOSPITAL



A shelter for many hearts A Home for many lives

(An ISO 9001:2008 Certified Organisation)
Lab Attached with CMC Under EQAS Scheme

Dept. of Radiodiagnosis - 32 Slice CT Scan, 3D/4D USG, 2D ECHO, Colour Doppler, Intervention Procedures, Digital X-Ray

NAME: PANKAJ KUMAR
REF.DR. DR.ASHUTOSH MISHRA(MD)

AGE/SEX: 33 YRS/MALE
DATE: 09/03/2024

ULTRA SOUND WHOLE ABDOMEN REPORT

Liver: Normal in size(14.2cm), shape & echogenicity. Intra & extra hepatic biliary Radicals & Vascular structures are normal. Margins are smooth and regular.

Gall bladder: Normally distended with echo free lumen.

Portal vein: Normal in course and caliber.

CBD diameter: Visualized part normal in course & caliber.

Pancreas: Normal in size, shape & echogenicity. Margins are smooth & regular. No diffuse/ focal lesion seen. Pancreatic duct not visualized.

Spleen: Normal in size, shape & echogenicity. Margins are smooth & regular.
No diffuse / focal lesion seen. Splenic vessels at hilum is normal.

Kidney: Both normal in size, shape echogenicity & position. Cortical-medullary differentiation is maintained. Pelvicalyceal system normal. No evidence of any calculus/mass lesion seen
No hydronephrosis/ hydroureter seen. No suprarenal mass lesion.

Urinary bladder: Normally distended with normal wall thickness. No echogenic foci lumen or diverticula seen.
Both VUJ appears normal. No evidence of calculus / mass lesion seen.

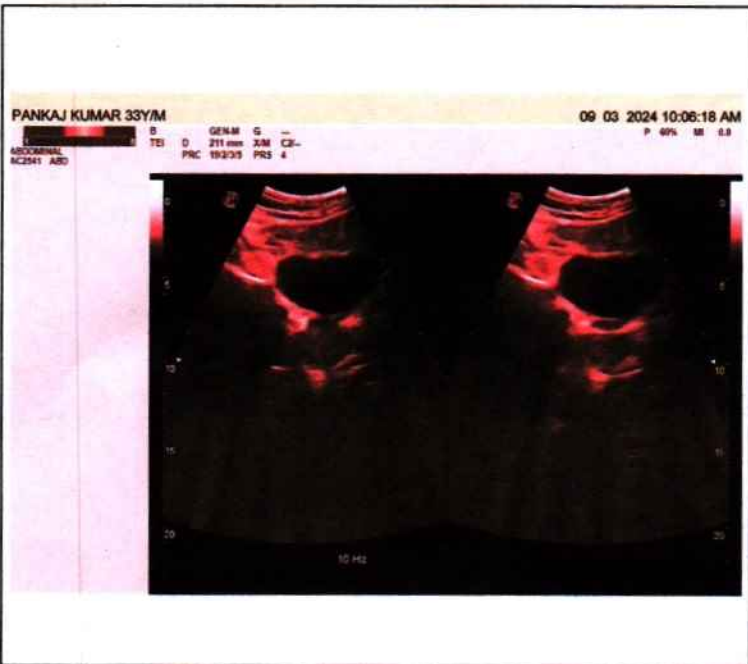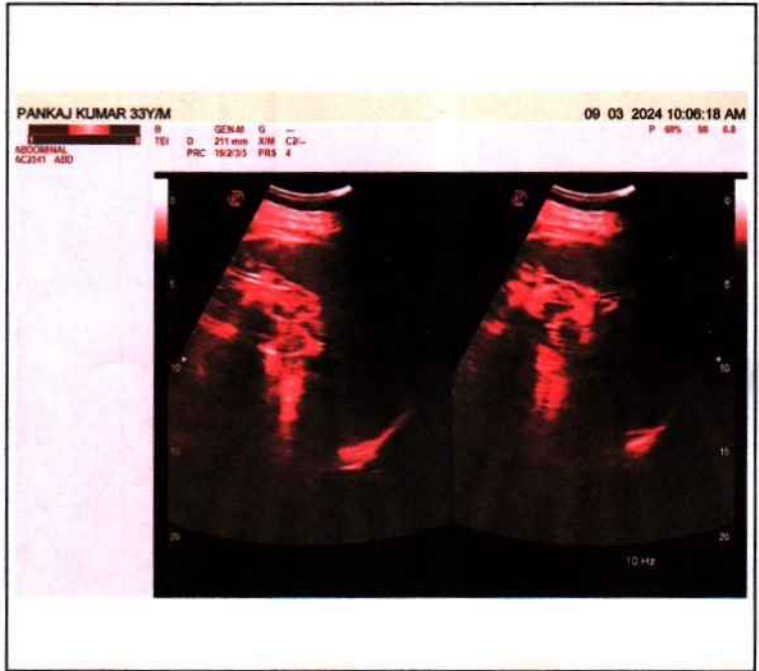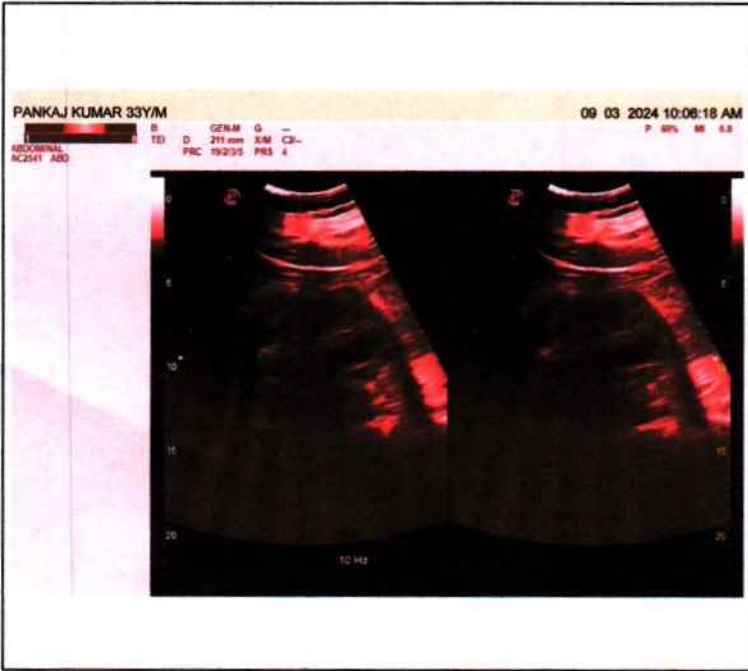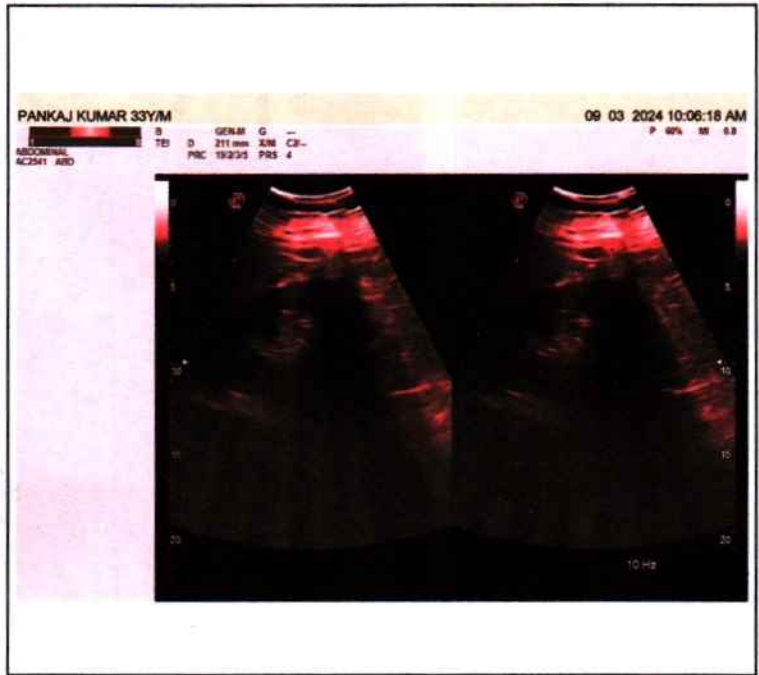
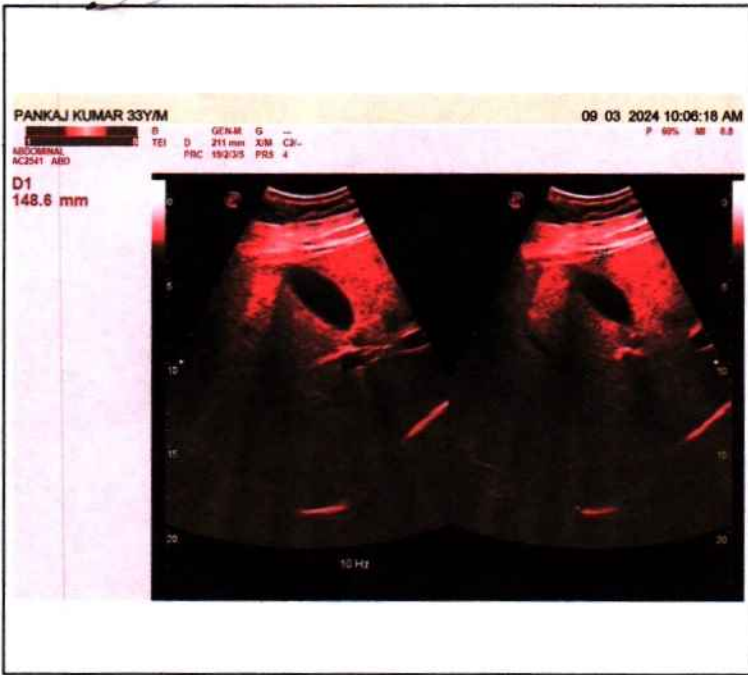Prostate: Normal in size, shape & echogenicity..

Others: No free fluid in peritoneal cavity.
No free fluid in bilateral pleural cavity.
No evidence of significantly enlarged retroperitoneal/ mesenteric lymph nodes noted.

IMPRESSION: - **NO OBVIOUS SONOLOGICAL ABNORMALITY SEEN.**

Please correlate clinically and further investigations.

Dr. Rakesh Kumar Tiwari
MBBS, MD (Radio Diagonosis),
Reg. No. 57557





PANACEA HOSPITAL



A shelter for many hearts A Home for many lives
 (An ISO 9001:2008 Certified Organisation)
 Lab Attached with CMC Under EQAS Scheme

Dept. of Radiodiagnosis - 32 Slice CT Scan, 3D/4D USG, 2D ECHO, Colour Doppler, Intervention Procedures, Digital X-Ray

PATIENT'S NAME : PANKAJ KUMAR **AGE/SEX: 33 Y/M**
REF. BY : Dr. ASHUTOSH MISHRA (MD) **Saturday, March 09, 2024**


Echo - Cardiography

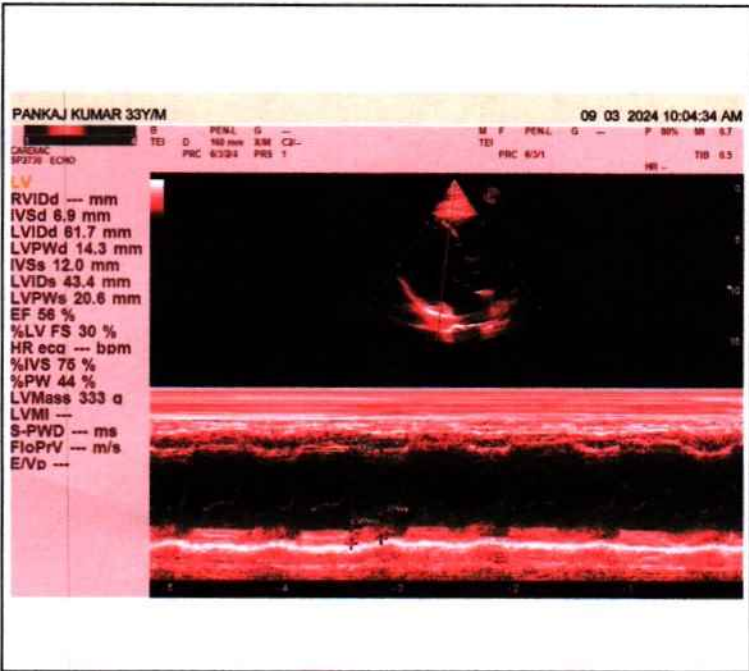
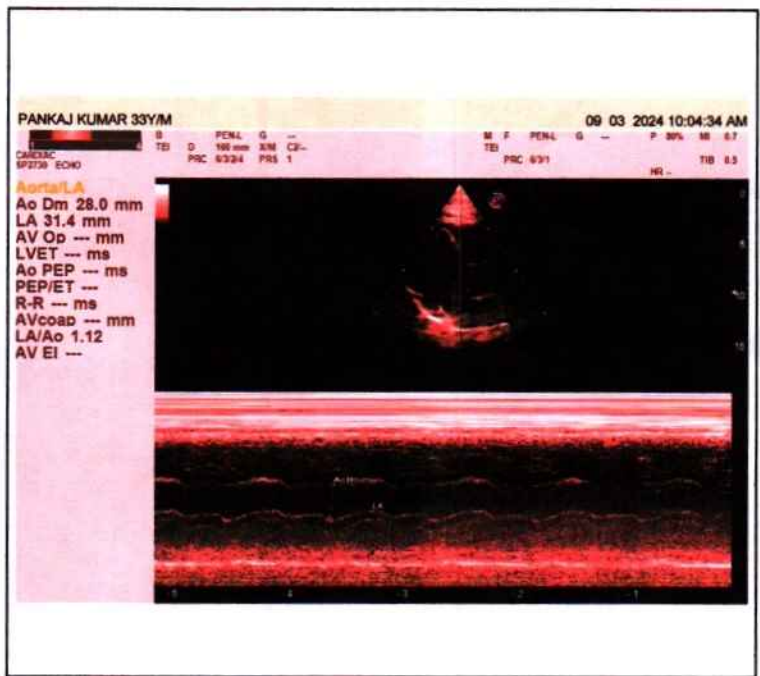
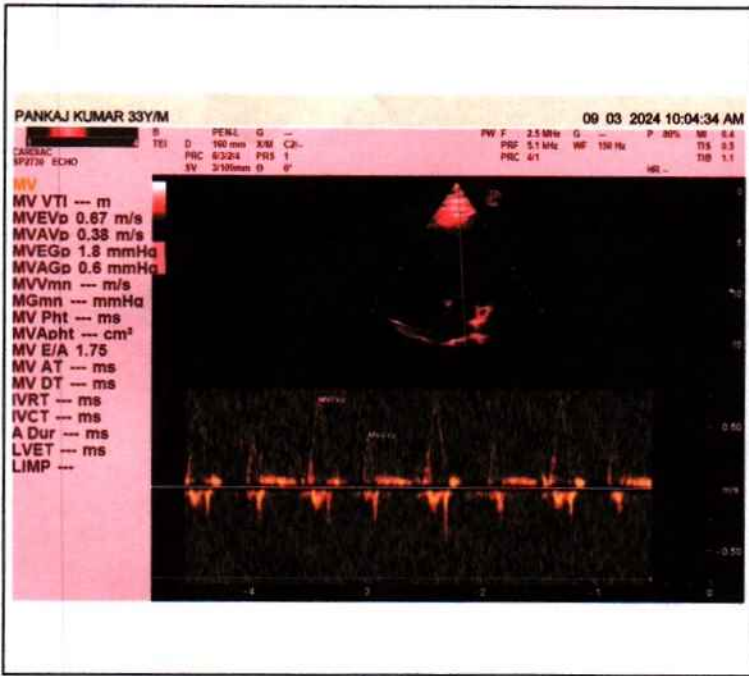
MITRAL VALVE Doppler	AML - normal morphology MV Flow - E - 0.6 A-0.3 E/A=1.75	PML - normal morphology MVA - 3.0 cm ² Mitral Regurgitation - No
TRICUSPID VALVE Doppler	Normal TV Flow -No	Tricuspid Regurgitation -No
PULMONARY VALVE Doppler	Normal PV Flow -No	Pulmonary Regurgitation - No
AORTIC VALVE Doppler	Trileaflet-No AV Flow - no	Aortic Regurgitation - no
MEASUREMENT	Aorta - 28.0 (20-38) mm IVS ed - 6.9 (6 - 12) mm LVID ed - 61.7 (35 - 55) mm LVPW ed - 14.3 (6 - 12) mm OA - 7 (> 5) mm	LA - 31.4 (24-32) mm IVS es - 12.0 (6 - 12) mm LVID es - 43.4 (24 - 40) mm LVPW es - 20.6 (6 - 12) mm EPSS - 4 (< 9) mm

CONCLUSION All cardiac chamber dimensions are WNL
 No valvular abnormalities
 Good LV systolic function present Modified Simpson's method (4C, 2C) (LVEF=56%)
 No diastolic dysfunction present (E/A = 1.75)
 No RWMA
 No pericardial effusion
 Intact IAS / IV
 No PAH
 No intra cardiac mass /thrombus /vegetation

IMPRESSION **Normal Echocardiogram**


 Niraj Mishra
 Physician Assistant
 (PIIRE)


 Dr. Pallavi Misra
 MBBS, MD (MED) Lucknow
 Echocardiography Specialist, (PIIRE)
 MC Reg. No. 52033
 Women Cardiologist
 Diabetocardiologist





Call Now - 1800-123-3070

PANACEA HOSPITAL



A shelter for many hearts A Home for many lives

(An ISO 9001:2008 Certified Organisation)
Lab Attached with CMC Under EQAS Scheme

Dept. of Radiodiagnosis - 32 Slice CT Scan, 3D/4D USG, 2D ECHO, Colour Doppler, Intervention Procedures, Digital X-Ray

PATIENT'S NAME :	PANKAJ KUMAR	AGE 33Y/ SEX :M
REF. BY :	Dr. ASHUTOSH MISHRA(MD)	DATE :09/03/2024

X-RAY CHEST (PA VIEW)

- Bilateral lung fields appear normal.
- Trachea and mediastinum appear normal in position.
- Both hila appear normal in size and are symmetrical.
- Transverse cardiac diameter is within normal limits.
- Great vessels appear normal
- Both CP angles appear clear. Normal position and contour diaphragms noted.
- Bony rib cage and soft tissue shadows appear normal.

IMPRESSION

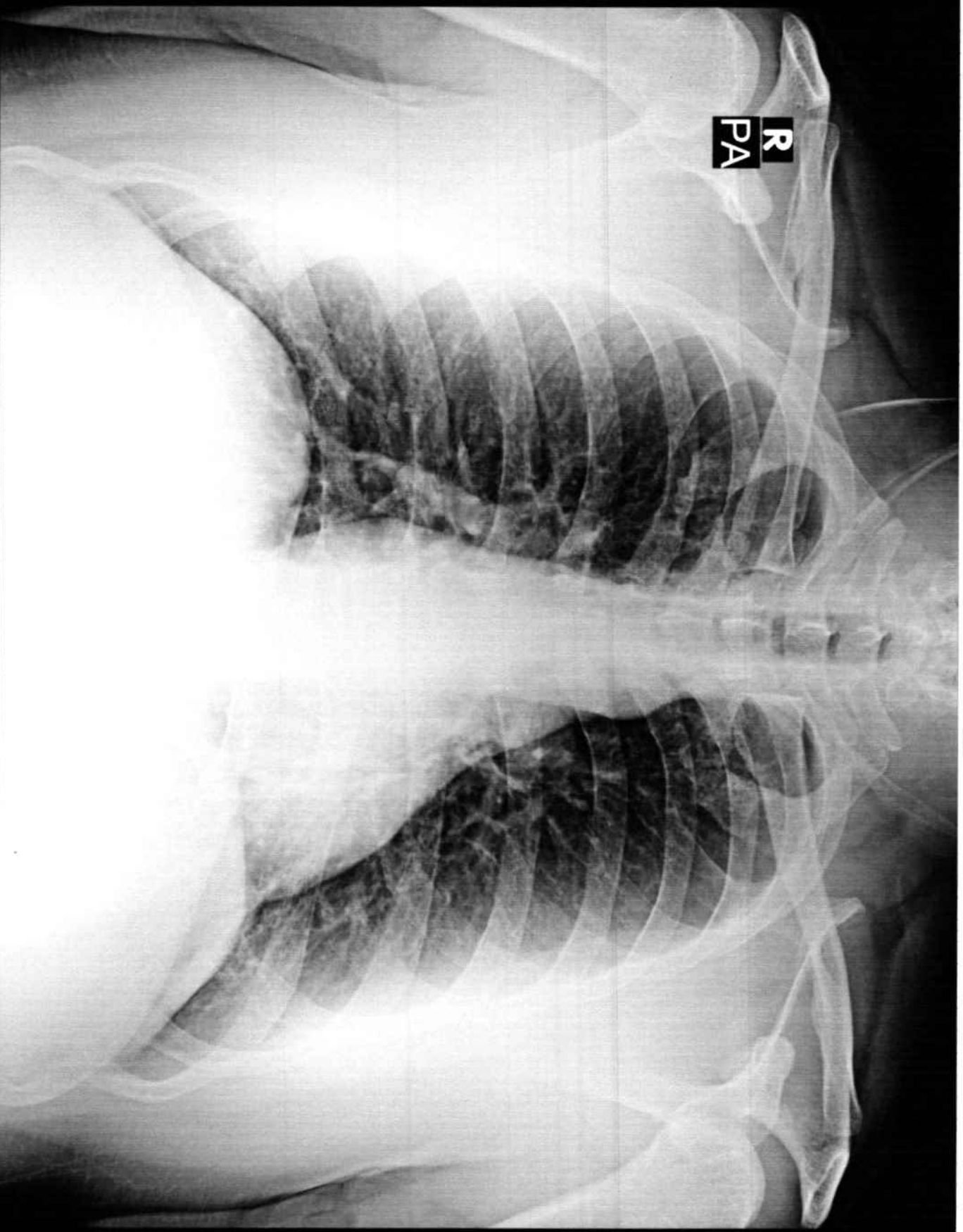
- **No obvious abnormality noted in the chest radiograph.**

Thanks for reference.


Dr. ~~Radiologist~~ Tiwari
MBBS, MD (Radio Diagonosis),
Reg. No. 57557

Disclaimer: This report is not valid for Madicolegal or Judicial Purpose. Radiological diagnosis is solely interpretation of images produced by tissue & may not be always conclusive.

Address : B36/44 B4 Kabir Nagar (Near Sanjay Shiksha Niketan), Durgakund, Varanasi
Mobile : 9554572190 / 9453837595 / Recpn, 9389994334
Email : dramishra@gmail.com, drpallaviojha@gmail.com, Website : www.piore.org

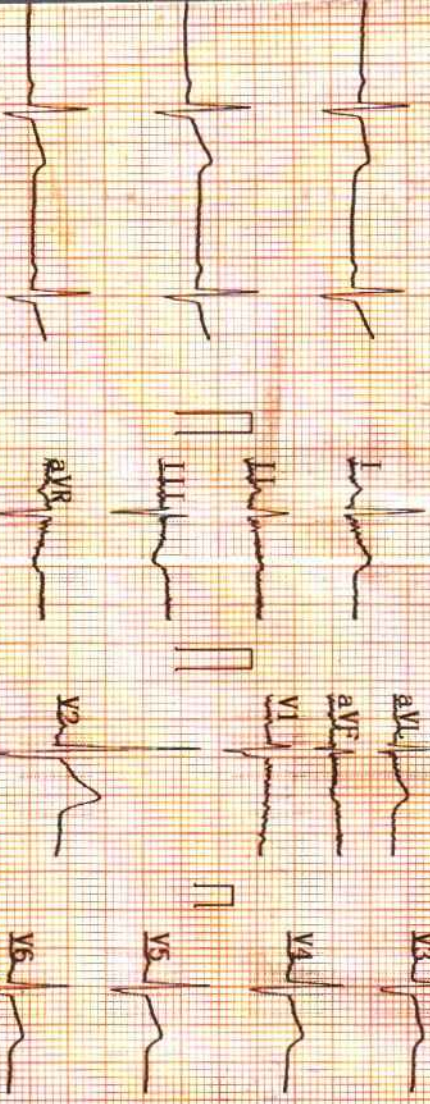


R
PA

PANKAJ KUMAR 33Y/M 6695 M CHEST P.A. 09-Mar-24 10:24 AM

PANACEA HOSPITAL, KABIR NAGAR, DURGAKUND, VARANASI

10mm/mV
10mm/mV
5mm/mV



2024 03 09 10:09

<< Conclusions >>

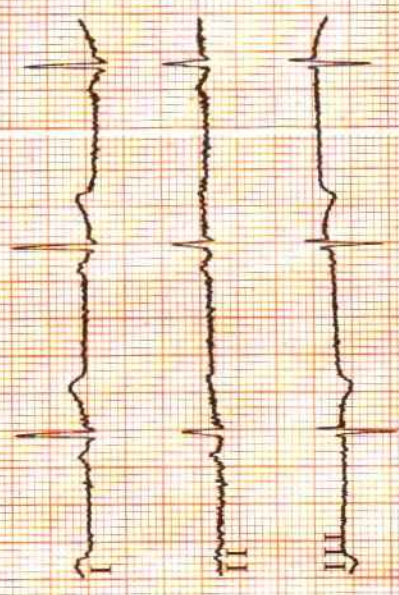
ID :
Name : **Rankey's Kumar**
Sex : **M**
Height : **162**
Weight : **93** kg
SYS :
DIA :

Age : **33**
Report need physician confirm

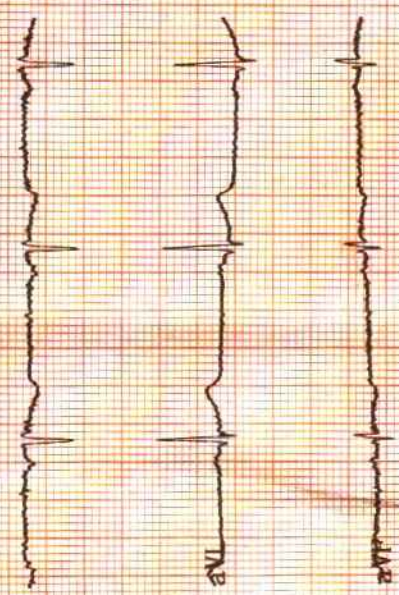
HR : **61** [bpm]
PR Interval : **152** [ms]
P Duration : **113** [ms]
QRS Duration : **76** [ms]
T Duration : **205** [ms]
QT/QTc : **379/380** [ms]
P/QRS/T Axis : **28.6/15.6/21.2** [deg]
R(V5)/S(V1) : **1.70/0.62** [mV]
R(V5)+S(V1) : **2.32** [mV]

Normal Sinus Rhythm!
Longitudinal left axis deviation:
DR. Pankaj Mera
MBBS, MD(GENERAL MEDICINE)
MCI Reg. No.52033
Physician
UPKAR HEALTHCARE INDIA PVT. LTD. PHYSICIAN CELL: 9838889966

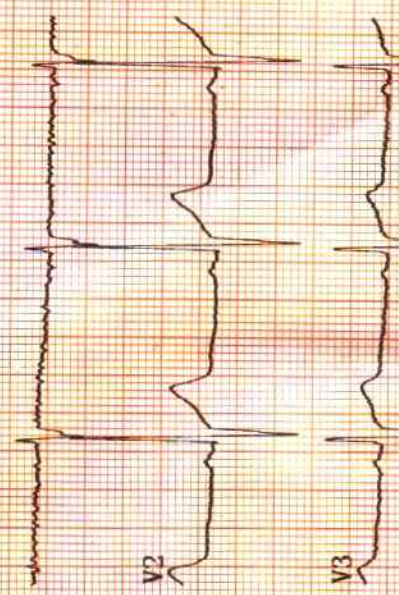
AUTO 10mm/mV



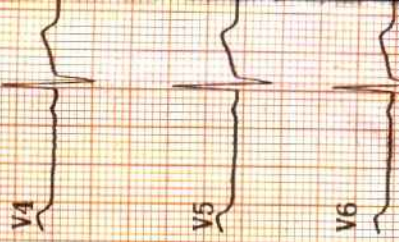
10mm/mV
aVR



10mm/mV
V1



5mm/mV
V4



25mm/s AC50Hz