

Greetings from Apollo!!

Respected Sir/Madam,

Please find corporate HC appointment details scheduled for **02-08-2024** at your **Pulse Radwave Diagnostics Private Limited** Center.


Points to note:-

Collect photocopy of employee ID proof if health check is through an employer.
Collect photocopy of personal ID proof if health check is for insurance.
Collect MER as per package details & that company's format (already shared).
By 12 noon of appointment date, share Work order number & visit status (Show/No show).
Upload reports in Adhutam portal as per specifications given earlier.

Corporate/TPA	Agreement Name	Package name	Package Inclusions	Customer Name
ARCOFEMI HEALTHCARE LIMITED	ARCOFEMI MEDIWHEEL PMC CREDIT PAN INDIA OP AGREEMENT	ARCOFEMI - MEDIWHEEL - PMC PACK H - PAN INDIA - FY2324	Urine Routine (CUE), GLUCOSE - SERUM / PLASMA (FASTING AND POST PRANDIAL, ALT (SGPT) - Serum / Plasma, Bilirubin, Total - Serum, Creatinine - Serum / Plasma, Blood Grouping And Typing (Abo And Rh), ECG, HEMOGRAM (CBC+ESR), X-Ray Chest PA, Fitness by General Physician, Ophthal by General Physician, BUN/CREATININE RATIO	Amir Shaikh

Please login to AHCN Portal for more details.

AHCN Login Url : [Click on Link](#)


DR. TILAK DEDHIA
M.B.B.S.
REG. No. 2011/07/2287

भारत सरकार
Government of India

अमीर सबीर शेख
Amir Sabir Shaikh
जन्म तारीख / DOB : 15/05/1996
पुरुष / Male

9763 8484 5518

आधार - सामान्य माणसाचा अधिकार

Amir

भारत सरकार
Unique Identification Authority of India

पत्ता S/O: सबीर शेख, रूम नो 21
फ्लॉट नो 19, गेट नो 7, मोहनगिरिया
भरतजीव जवळ, माखवणी, माहाड वेस्ट
मुंबई, खारोडी, महाराष्ट्र, 400095

Address: S/O: Sabir Shaikh, Room No 21
Plot No 19, Gate No 7, Near Mohanagiriya
Masur, Marwari, Mahad West, Mumbai,
Kharodi, Maharashtra, 400095

9763 8484 5518

1947
1800 200 1947


help@uidai.gov.in

www.uidai.gov.in

Tilak
DR. TILAK DEDHIA
M.B.B.S.
REG. No. ...011/07/2287

MER- MEDICAL EXAMINATION REPORT

Date of Examination	02/08/2024		
NAME	Mr. Amir. Shaikh		
AGE	28	Gender	Male
HEIGHT(cm)	170cm	WEIGHT (kg)	63.5 kg
B.P.	130/90mmHg		
ECG	WNL		
X Ray	Normal		
Vision Checkup	Normal Colour Vision		(R) 6/6 (L) 6/6
Present Ailments	NO		
Details of Past ailments (If Any)	NO		
Comments / Advice : She /He is Physically Fit	He is physically fit		


DR. TILAK DEDHIA
 M.B.B.S.
 REG. No. 2011/07/2287

Signature with Stamp of Medical Examiner

Patient : MR AMIR S SHAIKH

M/28 Y

2-Aug-24

Ref By : Dr ARCOFEMI HEALTHCARE LT

No : 2

COMPLETE BLOOD COUNT WITH ESR

<u>Test</u>	<u>Value</u>	<u>Normal Range</u>	<u>Units</u>
HAEMOGLOBIN	15.8	13.5 - 18.0	gms/dl
R.B.C. COUNT	5.05	4.50 - 6.50	millions/cumm
PCV	45.9	40.0 - 54.0	%
MCV	90.9	76.0 - 96.0	u3
MCH	31.3	27.0 - 32.0	pg
MCHC	34.4	30.0 - 35.0	%
RDW	14.3	11.5 - 14.5	%
W.B.C. COUNT	5,760	4,000-11,000	cells/cmm
<u>Differential Count :</u>			
Neutrophils	49	45 - 70	%
Lymphocytes	41	20 - 45	%
Eosinophils	03	1 - 6	%
Monocytes	07	1 - 10	%
Basophils	00	0 - 1	%
PLATELET COUNT	231,000	150,000 - 450,000	cells/cmm
PLATELETS ON SMEAR	Adequate		
R.B.C. MORPHOLOGY	Normocytic Normochromic		
W.B.C. MORPHOLOGY	Normal		
E.S.R (Westergren)	12	0 - 20	mm / hr

CBC done on Fully Automated Erba H560 Cell Counter.

Ashwini Sangvikar

Dr Ashwini Sangvikar

M.D. Pathology

Email ID : diagnosticradwave@gmail.com • +91 8097421555

Phone No.: +91 8097421556 / +91 8097421557 / +91 8097421558 / +91 8097421559

Address : Shop No. 2 & 3, Naya Oriental Co-Op Hus. Society Ltd., Opp. Sahakari Bhandar, LIC Colony, Next to Hotel Majestic NX, Borivali (W), Mumbai - 400 103. Maharashtra.

Patient : MR AMIR S SHAIKH

M/28 Y

2-Aug-24

Ref By : Dr ARCOFEMI HEALTHCARE LT

No : 2

BLOOD SUGAR

<u>Test</u>	<u>Value</u>	<u>Normal Range</u>	<u>Units</u>
FASTING BLOOD SUGAR	75	70-110	mg/dl
Urine Sugar	Absent		
Urine Ketones	Absent		
POST PRANDIAL BLOOD SUGAR	88	70-140	mg/dl
Urine Sugar (2 hrs)	No Sample		
Urine Ketones (2 Hrs)	No Sample		

METHOD : Glucose Oxidase Peroxidase (GOD/POD)

American Diabetes Association (ADA 2013) Blood Glucose Level Criteria :

FASTING GLUCOSE LEVEL

Normal glucose tolerance : < 100 mg %

Impaired Fasting Glucose : 100 - 125 mg %

Provisional diagnosis for: ≥ 126 mg % (on two different occasions)
diabetes mellitus

POST LUNCH GLUCOSE LEVEL

Normal glucose tolerance : < 140 mg %

Impaired Glucose Tolerance : 140 - 199 mg %

Provisional diagnosis for: ≥ 200 mg % (on two different occasions)
diabetes mellitus

URINE SUGAR INTERPRETATION : (Approx.)

Trace : 0.1 g/dl

+ : 0.25 g/dl

++ : 0.5 g/dl

+++ : 1.0 g/dl

++++ : >2.0 g/dl

Ashwini Sangvikar

Dr Ashwini Sangvikar

M.D. Pathology

Patient : MR AMIR S SHAIKH

M/28 Y


2-Aug-24

Ref By : Dr ARCOFEMI HEALTHCARE LT

No : 2

BIOCHEMISTRY

<u>Test</u>	<u>Value</u>	<u>Normal Range</u>	<u>Units</u>
Bilirubin (Total)	0.59	0.0-1.20	mg/dl
Bilirubin (Direct)	0.25	0.0-0.40	mg/dl
Bilirubin (Indirect)	0.3	0.1-1.0	mg/dl
BUN / CREATININE RATIO	11.7	5 - 23.5	
Creatinine	0.9	0.5-1.3	mg/dl
S.G.P.T	20.7	0.0-40.0	IU/L



Ashwini Sangvikar

Dr Ashwini Sangvikar

M.D. Pathology

Email ID : diagnosticradwave@gmail.com •  +91 8097421555

Phone No.: +91 8097421556 / +91 8097421557 / +91 8097421558 / +91 8097421559

Address : Shop No. 2 & 3, Naya Oriental Co-Op Hus. Society Ltd., Opp. Sahakari Bhandar, LIC Colony, Next to Hotel Majestic NX, Borivali (W), Mumbai - 400 103. Maharashtra.

Patient : MR AMIR S SHAIKH

M/28 Y

2-Aug-24

Ref By : Dr ARCOFEMI HEALTHCARE LT

No : 2

BLOOD GROUP

Test

Value

BLOOD GROUP

"A" Positive.

Method: Slide & Tube Agglutination



Ashwini Sangvikar

Dr Ashwini Sangvikar

M.D. Pathology

Patient : MR AMIR S SHAIKH

M/28 Y

2-Aug-24

Ref By : Dr ARCOFEMI HEALTHCARE LT

No : 2

Urine Routine

Test

Value

Physical Examination:


Quantity	30 ml
Colour	Pale Yellow
Appearance	Slightly Hazy
Reaction (pH)	Acidic(6.0)
Specific Gravity	1.020

Chemical Examination:

Proteins	Absent
Glucose	Absent
Ketone Bodies	Absent
Occult Blood	Absent
Bile Salts	Absent
Bile Pigments	Absent
Urobilinogen	Normal

Microscopic Examination:

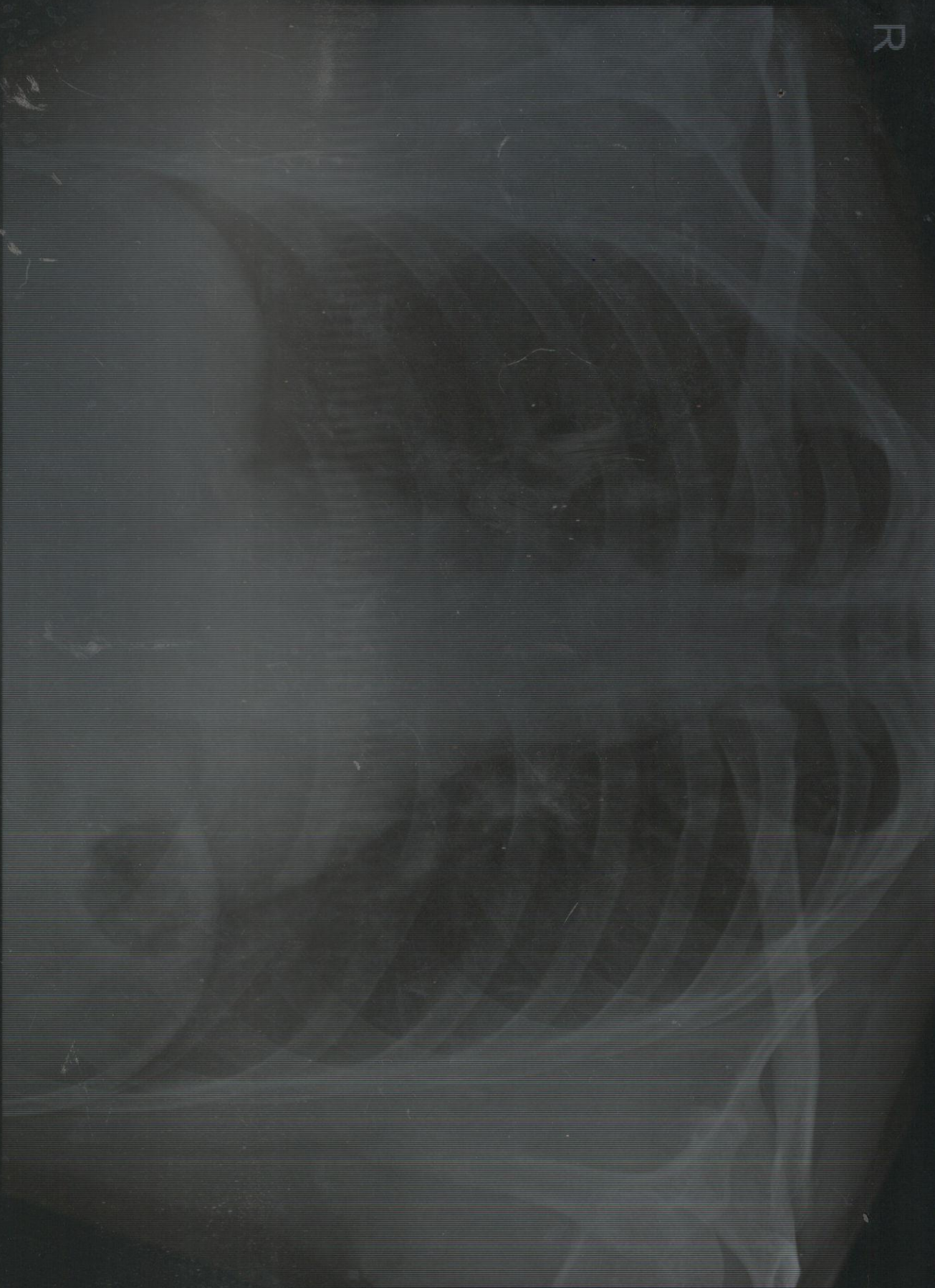
Pus Cells	2 - 3 / hpf
Red Blood Cells	Absent
Epithelial Cells	1 - 2 / hpf
Casts	Absent
Crystals	Absent
Bacteria	Absent
Yeast Cells	Absent
Amorphous Deposits	Absent
Mucus	Absent
Other	----



Dr Ashwini Sangvikar

M.D. Pathology

R



02/08/2024 4995 MR. AMIR SHAIKH 28 Y M APOLLO-ARCOFEMI HEALTHCARE LTD CHEST PA
Pulse Diagnostic Centre (Radwawe Diagnostic Pvt. Ltd), Borivali



PATIENT NAME : MR AMIR S SHAIKH
AGE/ SEX : 28 YRS / MALE
REF. CLINICIAN : APOLLO-ARCOFEMI HEALTHCARE LTD
DATE : 02/08/2024

X-RAY CHEST (P A VIEW)

- Both lung fields are clear.
- Both CP angle are normal.
- Cardiac and aortic shadows are normal.
- No obvious hilar or mediastinal lesion is seen.
- Bony thorax appears normal. No evidence of fracture seen.

CONCLUSION: X-Ray findings show...

- No significant abnormality of note.

Please correlate clinically.
Thanks for the referral,



Dr. Tilak Manilal Dedhia
M.B.B.S; M.D; D.N.B. (Radio-diagnosis)
Consultant Radiologist,

12 LEAD ECG REPORT



PULSE RADWAVE
DIAGNOSTIC
UNIT OF RADWAVE DIAGNOSTIC LLP



21/8/24

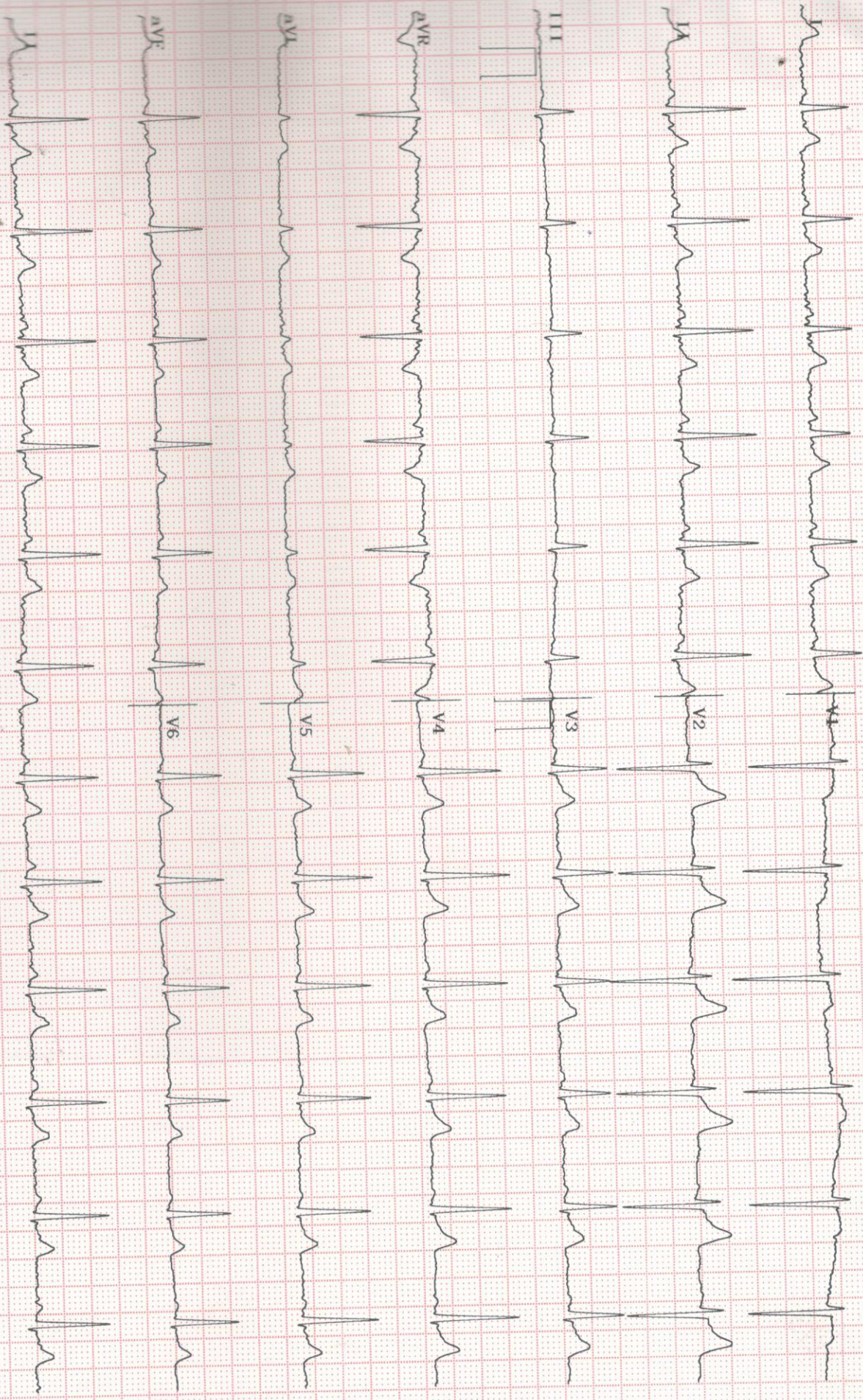
Name: Mr. Amir Shaikh 28/Male . Apollo - Ascofemi Healthcare Ltd

- ▶ Pathology ▶ Digital X - ray ▶ Sonography ▶ 3D - 4D Sonography ▶ Color Doppler ▶ ECG
- ▶ 2D Echo ▶ EEG ▶ EMG ▶ NCV ▶ PFT ▶ Mammography ▶ FNAC ▶ USG Guided Procedures
- ▶ X-Ray Special investigations ▶ Holter Monitor ▶ Sleep Study & Others.

ID :
Name: AMIR
Age : 28 years
Sex : Male
H : 0 cm / W : 0 kg

Heart Rate: 73 bpm
PR/RR Int.: 132/800 ms
QRS Dur.: 104 ms
QT/QTc: 372/413 ms
p-R-T axes: 47 49 24
SV1/RV5/R+S: 1.61/1.33/2.94mV

** Analysis Result ** (To be finally confirmed by physician)
Normal Sinus Rhythm
Normal Axis
[Normal ECG]



Speed: 0.1Hz LPF: 40Hz AC: 50Hz EMG: On

10.0mm/mV 25.0mm/sec

EKG2000 6.00/3.24 Bionet Co., Ltd.

ELECTROCARDIOGRAM

Please Photocopy ECG As Tracings Fades After Some Time

Name: Ms. Pmiv Shaikh.

Date: 02/08/24 Time: _____ Age / Sex: 28/male

Heart Rate: _____

Rhythm: _____

Axis: _____

Voltage: _____

P Wave: _____

PR Interval: _____

Qrs Interval & Complex: _____

ST Segment: _____

T Wave: _____

QT Interval: _____

QTC: _____

Impression: _____

Signature of Physician _____

CONC



DR PRIYAM BHATJIWALE, MD
REG. NO. 68857