

**Health Check up Booking Request(bobE28749), Beneficiary Code-40701**

1 message

Mediwheel <wellness@mediwheel.in>  
To: vidhidiagnostics@gmail.com  
Cc: mediwheelwellness@gmail.com

9 February 2023 at 13:43

**011-41195959**

Email:wellness@mediwheel.in

Dear **VIDHI DIAGNOSTICS,**

**City :** Ahmedabad . **Address :** L-86 Swatantra - Senani Nagar , Opp- Akhbarnagar Bus Terminals, New Wadaj , Ahmedabad -13,

We have received the confirmation for the following booking .

**Name** : MR. DABHI MAHENDRA VIRABHAI  
**Age** : 35  
**Gender** : Male  
**Package Name** : Medi-Wheel Metro Full Body Health Checkup Male Below 40  
**User Location** : ,AHMEDABAD,Gujarat,380001  
**Contact Details** : 8849846200  
**Booking Date** : 09-02-2023  
**Appointment Date** : 25-02-2023

Member Information			
Booked Member Name	Age	Gender	Cost(In INR)
MR. DABHI MAHENDRA VIRABHAI	35	Male	Cashless
Total amount to be paid			Cashless

We will get back to you with confirmation update shortly. Please find the package details as attached for your reference.

**Package Name** : Medi-Wheel Metro Full Body Health Checkup Male Below 40 - Includes (37) Tests

**Tests included in this Package** : Ecg, TSH, X-ray Chest, Stress Test (tmt)/ 2d Echo, Blood Sugar Postprandial, A:g Ratio, Blood Group, Total Cholesterol, Triglycerides, Fasting Blood Sugar, Ultrasound Whole Abdomen , Glycosylated Haemoglobin (hba1c), Hdl, Vldl, Urine Analysis, LDL, Total Protine, General Consultation, HDL/ LDL ratio, GGT(Gamma-glutamyl Transferase), Eye Check-up consultation, ALP (ALKALINE PHOSPHATASE), Uric Acid, AST/ALT Ratio, Serum Protein, CBC with ESR, Stool Analysis, Urine Sugar Fasting, Urine Sugar PP, T3, T4, Cholesterol Total / HDL Ratio, BUN, BUN/Creatinine Ratio, Bilirubin Total & Direct and Indirect, Albumin, Globulin



### Medical Examination Report

Date : 25/02/2023

#### 1. Personal Particulars

Name : Mahendrakumar Virebhai Dabhi

Age : 37 Years Gender : Male / Female

Marital Status : MARRIED

Past & Present Medical History : H/O COVID Positive on April 2021  
14 days Home quarantine

#### 2. Clinical Medical Examination

Height : 155 cm Weight : 76 kg  
Blood Pressure : 132/90 mmHg Pulse : 88 p/min

General Condition : N Skin : N  
Central Nervous System : N Head & Neck : N  
Cardiovascular System : N Chest : N  
Abdomen : N Limbs : N  
Last menstrual period : NA

Vision: Right: 6/6 N/B Left: 6/6 N/B

Colour vision : Normal/Colour Blind

Personal Habit : NO

Remarks : Fit / Unfit for employment

Dr. Vidhi D. Modh  
MBBS  
Reg. No. G-74540

Dr's name, signature & chop

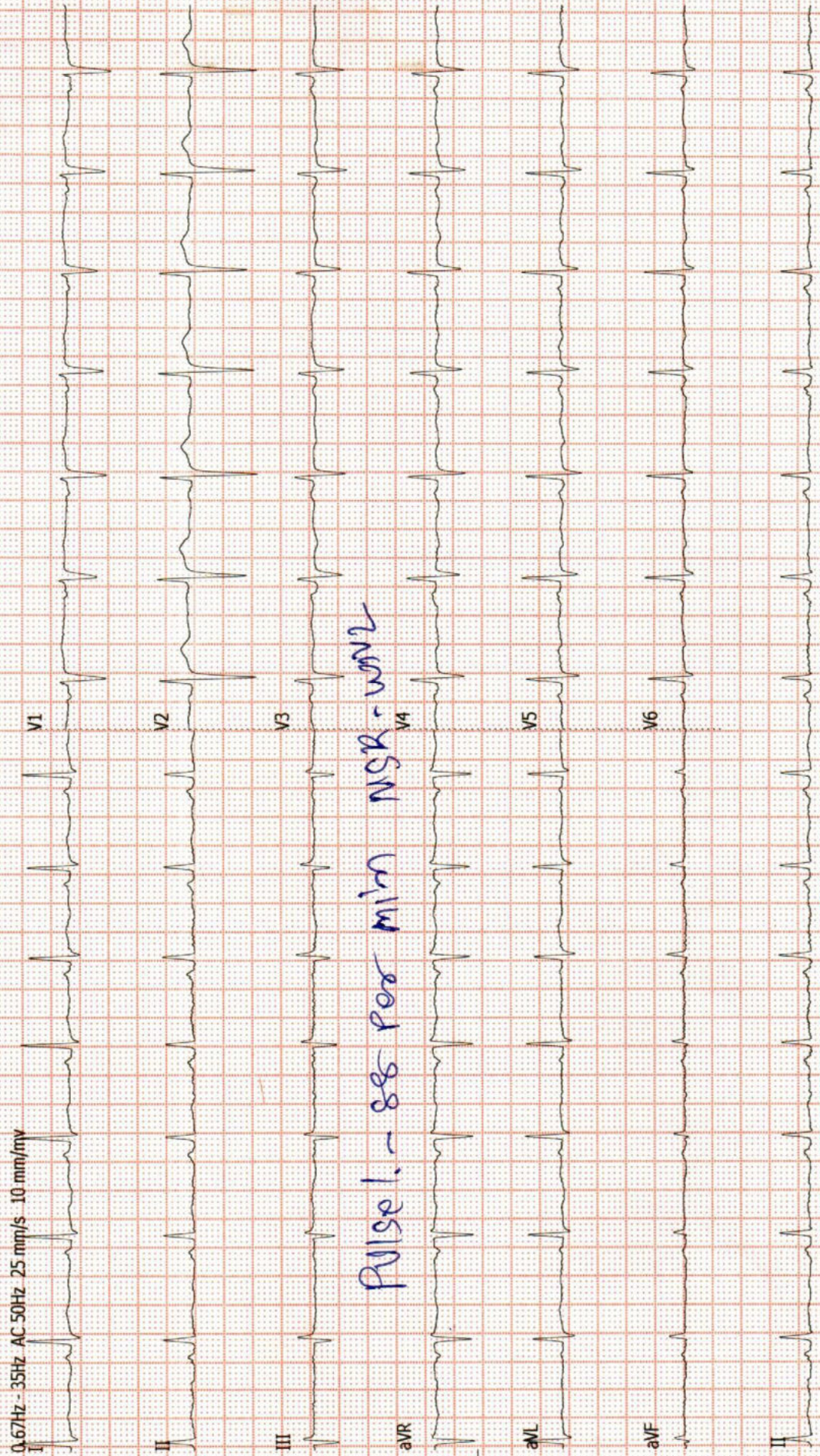
**Vidhi Diagnostics**  
L-86, Swatantra-Sonani Nagar,  
Opp. Akhbarnagar Bus Terminals,  
Nr. Akhbarnagar Circle,  
New Delhi, India-110042-13.



ID: 8117  
 Name: mahendrakumar v dabhi  
 Age: 37yrs  
 Sex: Male  
 Hospital: Dr. Avinash Bhaskar  
MBBS-D Cardio  
 Department: Regi No.: G-45946

HR : 89 bpm  
 PR : 140 ms  
 QRS : 88 ms  
 QT/QTc : 388/472 ms  
 P/QRS/T : 37/15/13 deg.  
 RV5/SV1 : 0.651/-0.676 mv  
 RV5+SV1 : 1.327 mv

Nonspecific T wave abnormality  
**Vidhi Diagnostics**  
 L-86, Swatantra-Senani Nagar,  
 Opp. Akharnagar Bus Terminals,  
 Mr. Akharnagar Circle,  
 New Wadaj, Ahmedabad 380 017  
 Need to be confirmed by doctor. Doctor Name: \_\_\_\_\_





## Dr. Dinesh S. Modh

M.D., D.M.R.E. (Radiodiagnosis)

Consultant Radiologist & Sonologist

Ex. Junior Lecturer, B.J. Medical College, Civil Hospital, A'bad.



Patient's name :	MAHENDRAKUMAR VIRABHAI DABHI	Age/Sex :	37 Years/Male
Reg. ID :	R-13592-23	Accession :	462
Referred by :	Dr. MEDIWHEEL	Date :	25/02/2023

### X-RAY CHEST (PA VIEW)

Both lung fields appear normal.  
No e/o consolidation or cavitations is seen.  
Both costo-phrenic angles appear clear.  
Cardiac size is with in normal limits.  
Both domes of diaphragm appear normal.  
Bony thoracic cage appears normal.

Thanks for reference.

Dr. Dinesh S. Modh  
MD DMRE (Radiodiagnosis)  
DR DINESH S. MODH  
M.D. DMRE(RADIODIAGNOSIS)

ISO 9001:2015 Certified Diagnostics Center

Vidhi Imaging Center

L-86, Swatantra Senani Nagar, Opp. Indian Oil Petrol Pump, Akhbarnagar Circle, Nava Vadaj, Ahmedabad - 380 013.

Phone : (Radiology) 079-2762 1406 | M. 98799 29406, 98250 09406 | Time (Radiology) : Mon. to Sat. 9 am to 2 pm, 5 to 9 pm, Sunday 9 am to 12 Noon

E-mail : vidhidiagnostics@gmail.com, Website : www.vidhidiagnostics.com

Multislice CT Scan | CBCT-Dental Scan | Live 3D-4D Sonography | Colour Doppler | Echo Cardiography | Interventional Radiology | Maxillofacial Radiology | Fetal Medicine  
Digital X-Ray | Digital Mammography | Digital OPG/TMJ | ECG/TMT/PFT/EEG/EMG | Audiometry | Pathology Laboratory | Health Check Up Plans | Pre Employment Check Up

**CT SCAN & CBCT FACILITY NOW AVAILABLE**

## Dr. Dinesh S. Modh

M.D., D.M.R.E. (Radiodiagnosis)

Consultant Radiologist & Sonologist

Ex. Junior Lecturer, B.J. Medical College, Civil Hospital, A'bad.



Patient's name : MAHENDRAKUMAR VIRABHAI DABHI  
Reg. ID : R-13592-23  
Referred by : Dr. MEDIWHEEL

Age/Sex : 37 Years/Male  
Accession : 462  
Date : 25/02/2023

### 2D- ECHO REPORT

#### FINAL CONCLUSION:

LV IS NORMAL SIZE. GOOD LV SYSTOLIC FUNCTION NO RWMA.  
LVEF - 60%. NO CONCENTRIC LVH.  
NORMAL LV COMPLIANCE.  
LA IS NORMAL SIZE. NO LA CLOT.  
RV IS NORMAL SIZE. GOOD RV SYSTOLIC FUNCTION.  
RA IS NORMAL SIZE.  
MITRAL VALVE IS NORMAL. NO MS. MILD MR (15%). NO MVP.  
AORTIC VALVE IS NORMAL. NO AS. NO AR.  
TRICUSPID VALVE IS NORMAL. NO TR. RVSP-26 mmHg. NO PAH.

NO CLOT, NO VEGETATION, NO PERICARDIAL EFFUSION.

#### DIMENSIONS:

AORTA	2.6 C.M
LEFT ATRIUM	2.7 C.M
LVDD	4.1 C.M.
IVSD	1.0 C.M
PWD	1.0 C.M
LVDS	2.6 C.M.

#### COLOUR DOPPLER FINDING:

STRUCTURE	VELOCITY m/sec
	Max
PULMONARY VALVE	0.7
MITRAL VALVE	E : 0.7 A: 0.4
AORTIC VALVE	1.0

*Dr. Avinash Bhaskar*  
MBBS, D Cardio  
DR AVINASH BHASKAR  
Reg. No. 15046

ISO 9001:2015 Certified Diagnostics Center

Vidhi Imaging Center

L-86, Swatantra Senani Nagar, Opp. Indian Oil Petrol Pump, Akharnagar Circle, Nava Vadaj, Ahmedabad - 380 013.

Phone : (Radiology) 079-2762 1406 | M. 98799 29406, 98250 09406 | Time (Radiology) : Mon. to Sat. 9 am to 2 pm, 5 to 9 pm, Sunday 9 am to 12 Noon  
E-mail : vidhidiagnostics@gmail.com, Website : www.vidhidiagnostics.com

Multislice CT Scan | CBCT-Dental Scan | Live 3D-4D Sonography | Colour Doppler | Echo Cardiography | Interventional Radiology | Maxillofacial Radiology | Fetal Medicine  
Digital X-Ray | Digital Mammography | Digital OPG/TMJ | ECG/TMT/PFT/EEG/EMG | Audiometry | Pathology Laboratory | Health Check Up Plans | Pre Employment Check Up

**CT SCAN & CBCT FACILITY NOW AVAILABLE**





## Dr. Dinesh S. Modh

M.D., D.M.R.E. (Radiodiagnosis)

Consultant Radiologist & Sonologist

Ex. Junior Lecturer, B.J. Medical College, Civil Hospital, A'bad.



Patient's name: MAHENDRAKUMAR VIRABHAI DABHI	Age/Sex : 37 Years/Male
Reg. ID : R-13592-23	Accession : 462
Referred by : Dr. MEDIWHEEL	Date : 25/02/2023

### USG ABDOMEN

LIVER: Liver is normal in size and bright in echotexture s/o fatty liver grade1. Intrahepatic biliary radicals appear normal.

Portal vein is normal in caliber. Common Bile duct is normal in course & caliber. No e/o calculus is seen in biliary tree.

GALL BLADDER: is distended & appear normal. No e/o calculus or cholecystitis is seen. GB wall thickness appears normal. No evidence of pericholecystic fluid is seen.

SPLEEN: Spleen is normal in size & shows normal echo texture. No evidence of diffuse or focal lesion is seen. Splenic vein appears normal.

PANCREAS: Pancreas appears normal in size & echotexture. No evidence of diffuse or focal lesion is seen. Main pancreatic duct is normal.

KIDNEY: Both kidneys appear normal in size and echopattern. Corticomedullary differentiation is maintained.

No evidence of calculus or hydronephrosis is seen on both sides.

Both supra renal region appear normal.

No evidence of pre & para aortic lymphadenopathy is seen.

Gas filled non-dilated bowel loops are seen in abdomen.

No evidence of free fluid is seen in abdomen.

No evidence of dilated or thickened bowel loops is seen.

Urinary bladder appears normal. No e/o calculus or mass lesion is seen.

Prostate appears normal in size & echopattern.

Thanks for reference.

Dr. Dinesh S. Modh

MD DMRE (Radiodiagnosis)

DR DINESH S. MODH

M.D. DMRE(RADIODIAGNOSIS)

ISO 9001:2015 Certified Diagnostics Center

Vidhi Imaging Center

L-86, Swatantra Senani Nagar, Opp. Indian Oil Petrol Pump, Akhbarnagar Circle, **Nava Vada**, Ahmedabad - 380 013.

Phone : (Radiology) 079-2762 1406 | M. 98799 29406, 98250 09406 | Time (Radiology) : Mon. to Sat. 9 am to 2 pm, 5 to 9 pm, Sunday 9 am to 12 Noon

E-mail : vidhidiagnostics@gmail.com, Website : www.vidhidiagnostics.com

Multislice CT Scan | CBCT-Dental Scan | Live 3D-4D Sonography | Colour Doppler | Echo Cardiography | Interventional Radiology | Maxillofacial Radiology | Fetal Medicine  
Digital X-Ray | Digital Mammography | Digital OPG/TMJ | ECG/TMT/PFT/EEG/EMG | Audiometry | Pathology Laboratory | Health Check Up Plans | Pre Employment Check Up

**CT SCAN & CBCT FACILITY NOW AVAILABLE**



## Dr. Dinesh S. Modh

M.D., D.M.R.E. (Radiodiagnosis)

Consultant Radiologist & Sonologist

Ex. Junior Lecturer, B.J. Medical College, Civil Hospital, A'bad.

Panel Doctor of L.I.C.



Good Report about Recovery by u.

Mr. Doshi

ISO 9001:2015 Certified Diagnostics Center

Vidhi Imaging Center, L-86, Swatantra Senani Nagar, Opp. Akhbarnagar Petrol Pump, Nr. Akhbarnagar Circle, Nava-Vadaj, Ahmedabad - 380 013.

Phone : 079-2762 1406, Mobile : 98799 29406, 98250 09406, E-mail : vidhidiagnostics@gmail.com, Website : www.vidhidiagnostics.com

FACILITIES : Live 3D-4D Sonography | Colour Doppler | Echo Cardiography | Interventional Radiology | Fetal Medicine | Digital X-Ray  
Digital Mammography | Digital OPG / TMJ | ECG / TMT / PFT / EEG / EMG | Pathology Laboratory | Health Check Up Plans | Pre Employment Check Up





Pathology Department



Patient's name : MAHENDRAKUMAR VIRABHAI DABHI  
 Age/Sex : 37 Years/Male  
 Referred by : Dr. MEDIWHEEL  
 Collection Time : 09:12

Reg. ID : P-7585-23  
 Accession : 446  
 Order Dt/time : 25/02/2023 09:12

**Complete Blood Count**

Sample Type: EDTA

Test Name	Result	Units	Biological Reference Interval
<b><u>Blood Counts</u></b>			
Haemoglobin :	15.6	Gms%	13.5 - 18.0
Total R.B.C. :	<b>4.66</b>	mill/c.mm	4.7 - 6.0
Total W. B. C. :	5,380	/cu mm	4000 - 10500
Platelet Count :	3,13,000	/cu.mm	1,50,000 - 4,50,000
<b><u>Differential Count</u></b>			
Neutrophils :	55	%	40 - 70
Lymphocytes :	40	%	20 - 40
Eosinophils :	03	%	1 - 4
Monocytes :	02	%	2 - 6
Basophils :	00	%	0 - 01
<b><u>Blood Indices</u></b>			
P. C. V :	46.3	%	42 - 52
M. C. V. :	99.4	fl	78 - 100
M.C.H :	<b>33.4</b>	pg	27 - 31
M. C. H. C :	33.6	%	32 - 36
R.D.W :	13.7	%	11.5 - 14.0
<b><u>E.S.R.( Westergren Method )</u></b>			
After one hour :	04	mm/hr	1 - 7

TESTS DONE ON FULLY AUTOMATED HEMATOLOGY ANALYZER.

*Dr. Gayatri M. Mehta*

M. D. (Patho)

Reg. No. G-32215

DR GAYATRI MEHTA  
MD(PATHOLOGY)

DR. ANAND D. PARIKH  
MD(PATHOLOGY)

LAB USE ONLY (Entered by :GM Enter Date/Time:25/02/2023 1:06:00 PM) (Verify by :GM Verify Date/Time:25/02/2023 1:06:00 PM)

ISO 9001:2015 Certified Diagnostics Center

Vidhi Imaging Center | Pathology Department

L-86, Swatantra Senani Nagar, Opp. Akhbarnagar Petrol Pump, Nr. Akhbarnagar Circle, Nava-Vadaj, Ahmedabad - 380 013.

Ph. (Pathology) : 079-2762 1406, 8849893954 M. 98799 29406, 98250 09406, E-mail : vidhidiagnostics@gmail.com, Web. : www.vidhidiagnostics.com

Time (Pathology) : Mon. to Sat. 8.30 am to 8.00 pm, Sunday 9 am to 12 Noon

*Pathology means science behind medicine*

**CT SCAN & CBCT FACILITY NOW AVAILABLE**





Pathology Department



Patient's name : MAHENDRAKUMAR VIRABHAI DABHI  
Age/Sex : 37 Years/Male  
Referred by : Dr. MEDIWHEEL  
Collection Time : 09:12

Reg. ID : P-7585-23  
Accession : 446  
Order Dt/time : 25/02/2023 09:12

### Blood Group

Sample Type: EDTA sample.

Test Name	Result
BG :	" AB "
RH :	POSITIVE
Remarks	Done by forward grouping method.

### Blood Glucose

Sample Type: Serum

Test Name	Result	Units	Biological Reference Interval
Fasting Blood Glucose :	96.7	mg/dl	70 - 110
<i>GOD-POD Method.</i>			

*Dr. Gayatri M. Mehta*  
M. D. (Patho)

DR. GAYATRI MEHTA 2215  
MD(PATHOLOGY)

DR. ANAND D. PARIKH  
MD(PATHOLOGY)

LAB USE ONLY (Entered by :GM Enter Date/Time:25/02/2023 4:25:00 PM) (Verify by :GM Verify Date/Time:25/02/2023 4:25:00 PM)

ISO 9001:2015 Certified Diagnostics Center  
Vidhi Imaging Center | Pathology Department

L-86, Swatantra Senani Nagar, Opp. Akhbarnagar Petrol Pump, Nr. Akhbarnagar Circle, Nava-Vadaj, Ahmedabad - 380 013.

Ph. (Pathology) : 079-2762 1406, 8849893954 M. 98799 29406, 98250 09406, E-mail : vidhidiagnostics@gmail.com, Web. : www.vidhidiagnostics.com

Time (Pathology) : Mon. to Sat. 8.30 am to 8.00 pm, Sunday 9 am to 12 Noon

*Pathology means science behind medicine*

**CT SCAN & CBCT FACILITY NOW AVAILABLE**





Pathology Department

Patient's name : MAHENDRAKUMAR VIRABHAI DABHI  
Age/Sex : 37 Years/Male  
Referred by : Dr. MEDIWHEEL  
Collection Time : 09:12

Reg. ID : P-7585-23  
Accession : 446  
Order Dt/time : 25/02/2023 09:12

**Lipid Profile**

Sample Type: Serum

Test Name	Result	Units	Biological Reference Interval
<b>S. Cholesterol :</b> Oxidase-esterase method.	<b><u>233.0</u></b>	mg/dl	0 - 200
<b>S. Triglyceride :</b> Enzymatic Colorimetry method	107.6	mg/dL	0 - 200
<b>S. HDL - Cholesterol :</b> Serum by Enzymatic method.	61.9	mg/dL	35 - 65
<b>S. LDL - Cholesterol :</b> Serum by Enzymatic method	<b><u>149.58</u></b>	mg/dL	0 - 130
<b>S. VLDL - Cholesterol :</b>	21.52	mg/dL	0 - 30
<b>S. Chole/HDL.Ratio :</b>	3.76		1 - 6
<b>S. LDL / HDL Cholesterol Ratio :</b>	2.42		0 - 3.5

*Dr. Gayatri M. Mehta*

M. D. (Patho)

Reg. No. G-32215

DR GAYATRI MEHTA  
MD(PATHOLOGY)

DR. ANAND D. PARIKH  
MD(PATHOLOGY)

LAB USE ONLY (Entered by :GM Enter Date/Time:25/02/2023 4:25:00 PM) (Verify by :GM Verify Date/Time:25/02/2023 4:25:00 PM)

ISO 9001:2015 Certified Diagnostics Center

Vidhi Imaging Center | Pathology Department

L-86, Swatantra Senani Nagar, Opp. Akhbarnagar Petrol Pump, Nr. Akhbarnagar Circle, Nava-Vadaj, Ahmedabad - 380 013.

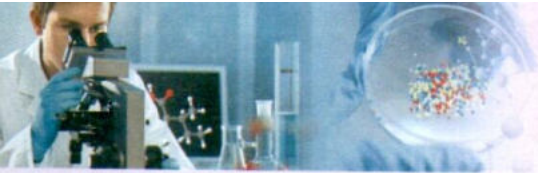Ph. (Pathology) : 079-2762 1406, 8849893954 M. 98799 29406, 98250 09406, E-mail : vidhidiagnostics@gmail.com, Web. : www.vidhidiagnostics.com

Time (Pathology) : Mon. to Sat. 8.30 am to 8.00 pm, Sunday 9 am to 12 Noon

*Pathology means science behind medicine*

**CT SCAN & CBCT FACILITY NOW AVAILABLE**





Pathology Department



Patient's name : MAHENDRAKUMAR VIRABHAI DABHI  
Age/Sex : 37 Years/Male  
Referred by : Dr. MEDIWHEEL  
Collection Time : 09:12

Reg. ID : P-7585-23  
Accession : 446  
Order Dt/time : 25/02/2023 09:12

**HbA1C**

Sample Type: Serum

Test Name	Result	Units	Biological Reference Interval
HbA1C :	5.4	%	Non-diabetic: 4.2-6.2 Pre-diabetic : 6.3-7.2 Diabetic : 7.3-8.2
Mean Blood Glucose of Last 03 months.	108.28	mg/dl	

**Comment**

\*As per the new 2009 update of American Diabetes Association regarding HbA1C & Mean Blood Glucose relationship.

**NOTE:**

This test is used to monitor diabetic patients compliance with the therapeutic regimen and logo It's level is proportional to both the average blood glucose concentration and the life span of the red blood cells (RBC) in circulation. HbA1c values are free of day to day glucose fluctuations and are unaffected by exercise or recent food intake.

*Dr. Gayatri M. Mehta*

M. D. (Patho)

Reg. No. G-32215

DR GAYATRI MEHTA  
MD(PATHOLOGY)

DR.ANAND D.PARIKH  
MD(PATHOLOGY)

LAB USE ONLY (Entered by :GM Enter Date/Time:25/02/2023 4:25:00 PM) (Verify by :GM Verify Date/Time:25/02/2023 4:25:00 PM)

ISO 9001:2015 Certified Diagnostics Center

Vidhi Imaging Center | Pathology Department

L-86, Swatantra Senani Nagar, Opp. Akhbarnagar Petrol Pump, Nr. Akhbarnagar Circle, Nava-Vadaj, Ahmedabad - 380 013.

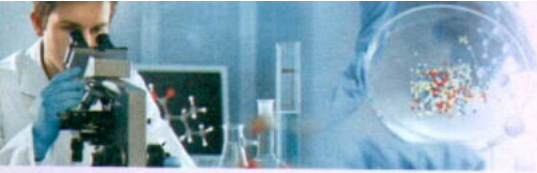Ph. (Pathology) : 079-2762 1406, 8849893954 M. 98799 29406, 98250 09406, E-mail : vidhidiagnostics@gmail.com, Web. : www.vidhidiagnostics.com

Time (Pathology) : Mon. to Sat. 8.30 am to 8.00 pm, Sunday 9 am to 12 Noon

*Pathology means science behind medicine*

**CT SCAN & CBCT FACILITY NOW AVAILABLE**





Pathology Department



Patient's name : MAHENDRAKUMAR VIRABHAI DABHI  
 Age/Sex : 37 Years/Male  
 Referred by : Dr. MEDIWHEEL  
 Collection Time : 09:12

Reg. ID : P-7585-23  
 Accession : 446  
 Order Dt/time : 25/02/2023 09:12

**BIOCHEMISTRY**

Sample type :Serum

Test Name	Result	Units	Biological Reference Interval
<b>Urea</b> , (Serum by GLDH method) :	21.1	mg/dl	10 - 50
<b>S.Uric acid</b> , (Serum by Uricase method) :	5.6	mg/dl	3.4 - 7.0
<b>Bun</b> :	9.9	mg/dl	6-20
<b>Creatinine</b> , (Serum by Enzymatic reaction) :	0.92	mg/dl	0.5-1.2
<b>S.G.P.T (ALT)</b> : (Serum by IFCC method)	39.4	U/L	0 - 40
<b>S.G.O.T (AST)</b> : (Serum by IFCC method)	22.5	U/L	0 - 37
<b>ALK.PHOSPHATASE</b> : (Serum by PNP method)	68.0	U/L	40-129
<b>G.G.T</b> :	16.2	U/L	8 - 78
<b><u>BILIRUBIN</u></b>			
<b>Total</b> :	0.78	mg/dl	Up to 1.2
<b>Direct</b> :	0.31	mg/dl	0-0.7
<b>Indirect</b> :	0.47	mg/dl	0 - 0.5
<b><u>SERUM PROTEINS</u></b>			
<b>Total Protein</b> (Serum by Biuret method) :	7.08	gms/dl	6.4 - 8.5
<b>Albumin</b> (Serum by BCG method) :	4.29	gms/dl	3.97-4.94
<b>Globulins</b> :	2.79	gms/dl	2.3 - 3.5
<b>A/G Ratio</b> :	1.538		0.9 - 2.9

*Dr. Gayatri M. Mehta*  
 M. D. (Patho)

Reg. No. G-32215

DR GAYATRI MEHTA  
 MD(PATHOLOGY)

DR.ANAND D.PARIKH  
 MD(PATHOLOGY)

LAB USE ONLY (Entered by :GM Enter Date/Time:25/02/2023 4:25:00 PM) (Verify by :GM Verify Date/Time:25/02/2023 4:25:00 PM)

ISO 9001:2015 Certified Diagnostics Center  
 Vidhi Imaging Center | Pathology Department

L-86, Swatantra Senani Nagar, Opp. Akhbarnagar Petrol Pump, Nr. Akhbarnagar Circle, Nava-Vadaj, Ahmedabad - 380 013.

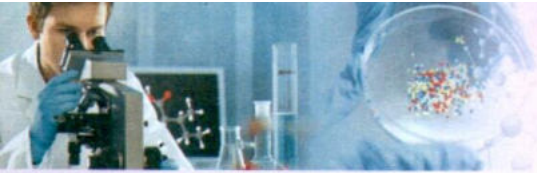Ph. (Pathology) : 079-2762 1406, 8849893954 M. 98799 29406, 98250 09406, E-mail : vidhidiagnostics@gmail.com, Web. : www.vidhidiagnostics.com

Time (Pathology) : Mon. to Sat. 8.30 am to 8.00 pm, Sunday 9 am to 12 Noon

*Pathology means science behind medicine*

**CT SCAN & CBCT FACILITY NOW AVAILABLE**





Pathology Department

**VIDHI**  
DIAGNOSTICS



Patient's name : MAHENDRAKUMAR VIRABHAI DABHI  
Age/Sex : 37 Years/Male  
Referred by : Dr. MEDIWHEEL  
Collection Time : 09:12

Reg. ID : P-7585-23  
Accession : 446  
Order Dt/time : 25/02/2023 09:12

### Thyroid Function Test

Sample Type: Serum

Test Name	Result	Units	Biological Reference Interval
TOTAL T3 :	1.07	ng/ml	0.84 - 2.0
TOTAL T4 :	6.84	ug/dl	5.1 - 14.0
TSH(Ultra sensitive) :	3.363	mIU/L	0.27 - 4.2

*Dr. Gayatri M. Mehta*

M. D. (Patho)

Reg. No. G-32215

DR GAYATRI MEHTA  
MD(PATHOLOGY)

DR. ANAND D. PARIKH  
MD(PATHOLOGY)

LAB USE ONLY (Entered by :GM Enter Date/Time:25/02/2023 4:26:00 PM) (Verify by :GM Verify Date/Time:25/02/2023 4:26:00 PM)

ISO 9001:2015 Certified Diagnostics Center

Vidhi Imaging Center | Pathology Department

L-86, Swatantra Senani Nagar, Opp. Akhbarnagar Petrol Pump, Nr. Akhbarnagar Circle, Nava-Vadaj, Ahmedabad - 380 013.

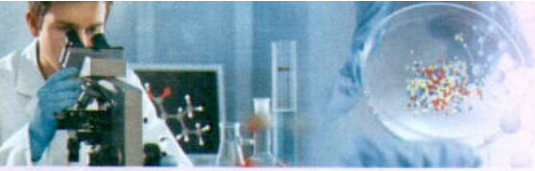Ph. (Pathology) : 079-2762 1406, 8849893954 M. 98799 29406, 98250 09406, E-mail : vidhidiagnostics@gmail.com, Web. : www.vidhidiagnostics.com

Time (Pathology) : Mon. to Sat. 8.30 am to 8.00 pm, Sunday 9 am to 12 Noon

*Pathology means science behind medicine*

**CT SCAN & CBCT FACILITY NOW AVAILABLE**





Pathology Department

Patient's name : MAHENDRAKUMAR VIRABHAI DABHI  
Age/Sex : 37 Years/Male  
Referred by : Dr. MEDIWHEEL  
Collection Time : 09:12

Reg. ID : P-7585-23  
Accession : 446  
Order Dt/time : 25/02/2023 09:12

**Urine Analysis**

Sample Type: Urine

Test Name	Result	Units	Biological Reference Interval
<b><u>Physical Examination</u></b>			
Quantity :	20	ml	0 - 500 ml.
Colour :	Pale Yellow		Pale Yellow
Transparency :	Clear.		Clear
Reaction :	Acidic		4.6 - 8.0
Specific Gravity :	1.015		1.016 - 1.022
Sediment :	Present		
<b><u>Chemical Examination</u></b>			
Albumin :	Present (Faint Trace)		Absent
Sugar :	NIL		Absent
Acetone :	Absent		Absent
Bile Salts :	Absent		Absent
Bile Pigments :	Absent		Absent
Urobilogen :	Absent		Absent
Nitrites :	Absent		Absent
<b><u>Microscopic Examination</u></b>			
Red blood Cells :	Occasional	/h.p.f	Absent
Pus Cells :	2-3	/h.p.f	Absent
Epithelial Cells :	1-2	/h.p.f	< 10.0
Amorphous :	Absent	/h.p.f	Absent
Bacteria :	Absent	/h.p.f	Absent
Crystals :	Absent	/h.p.f	Absent
Casts :	Absent	/h.p.f	Absent
Fungus :	Not seen	/h.p.f	Absent

*Dr. Gayatri M. Mehta*  
M. D. (Patho)

Reg. No. G-32215

DR GAYATRI MEHTA  
MD(PATHOLOGY)

DR. ANAND D. PARIKH  
MD(PATHOLOGY)

ISO 9001:2015 Certified Diagnostics Center

LAB USE ONLY (Entered by : GM Enter Date/Time: 25/02/2023 4:26:00 PM) (Verify by : GM Verify Date/Time: 25/02/2023 4:26:00 PM)

L-86, Swatantra Senani Nagar, Opp. Akharnagar Petrol Pump, Nr. Akharnagar Circle, Nava-Vadaj, Ahmedabad - 380 013.

Ph. (Pathology) : 079-2762 1406, 8849893954 M. 98799 29406, 98250 09406, E-mail : vidhidiagnostics@gmail.com, Web. : www.vidhidiagnostics.com

Time (Pathology) : Mon. to Sat. 8.30 am to 8.00 pm, Sunday 9 am to 12 Noon

*Pathology means science behind medicine*

**CT SCAN & CBCT FACILITY NOW AVAILABLE**



ભારતીય વિશિષ્ટ ઓળખ પ્રાધિકરણ  
Unique Identification Authority of India


નોંધણીની ઓળખ / Enrollment No. : 0648/50579/01007

To  
**Mahendrakumar Virabhai Dabhi**  
મહેન્દ્રકુમાર વીરાભાઈ ડાભી  
C/O: Virabhai,  
279,  
satva homes-2,  
g s t mill compound, opp khodiyar mandir,  
new ranip,  
VTC: Tragad, PO: Tragad,  
Sub District: Ahmadabad City, District: Ahmedabad,  
State: Gujarat, PIN Code: 382470,  
Mobile: 8849846200

24725604



KF247256049FI



આપનો આધાર નંબર / Your Aadhaar No. :

**7827 6237 7224**

મારો આધાર, મારી ઓળખ

**Vidhi Diagnostics**

L-86, Swatantra-Senani Nagar,  
Opp. Akhbarnagar Bus Terminals,  
Nr. Akhbarnagar Circle,  
New Wadaj, Ahmedabad-13.



ભારત સરકાર

Government of India



Issue Date: 06/02/2016



મહેન્દ્રકુમાર વીરાભાઈ ડાભી

**Mahendrakumar Virabhai Dabhi**

જન્મ તારીખ / DOB: 22/06/1985

પુરુષ / Male

Dr. Vidhi D. Modh  
MBBS  
Reg. No. G-74540

*(Handwritten signature)*

**7827 6237 7224**

મારો આધાર, મારી ઓળખ



EMAIL ID  
VIDHI DIAGNOSTICS@  
GMAIL.COM

96


 **GPS Map Camera**

**Ahmedabad, Gujarat, India**

3H96+6PR, Chandlodiya Rd,  
Swatantra Senani Nagar, Nava Vadaj,  
Ahmedabad, Gujarat 380013, India

Lat 23.068124°  
Long 72.561758°

25/02/23 12:32 PM GMT +05:30



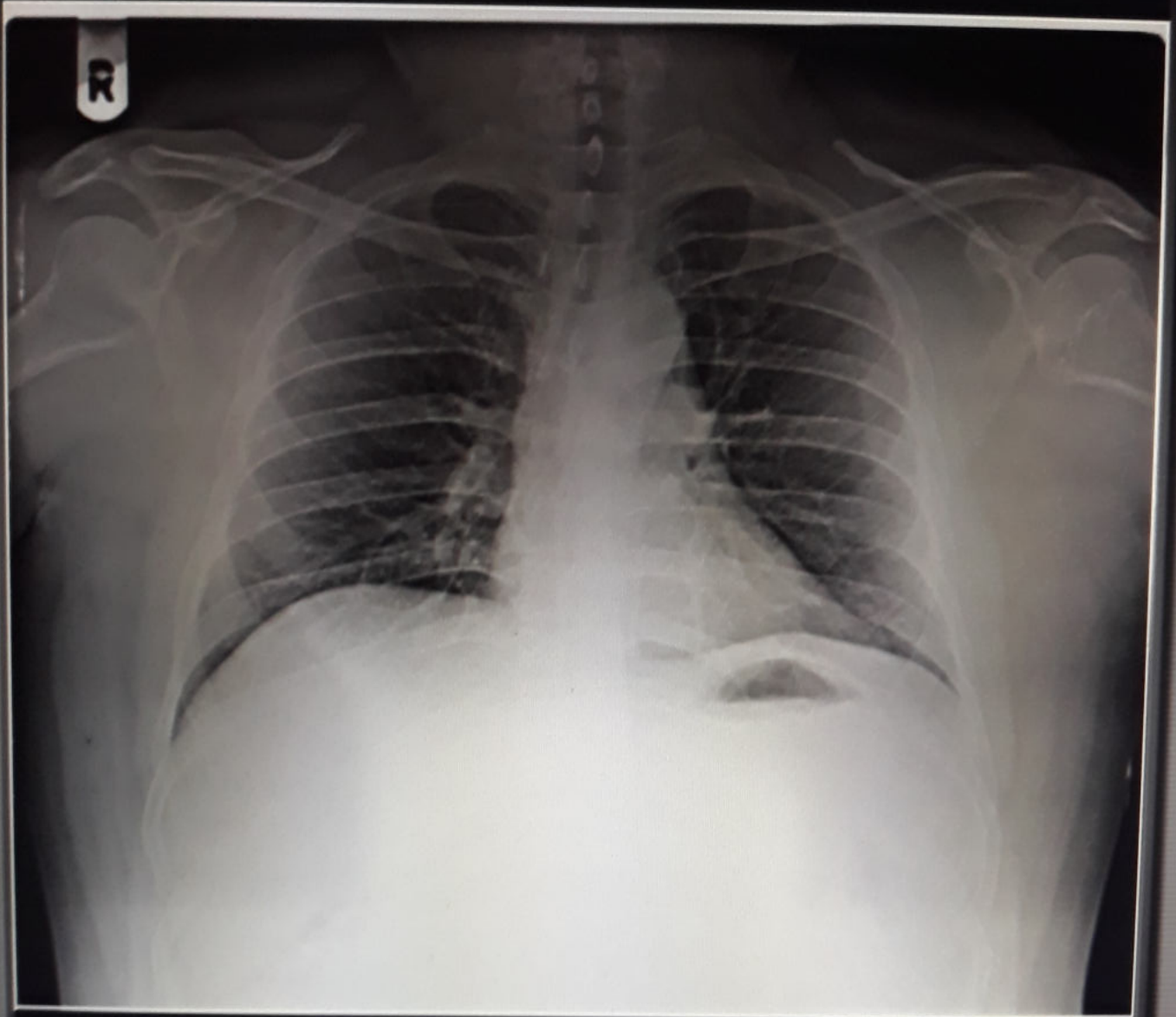
Dr. Vidhi D. Modh  
Reg. No. G-74540

**Vidhi Diagnostics**  
L-86, Swatantra-Senani Nagar,  
Opp. Akhbarnagar Bus Terminals,  
Nr. Akhbarnagar Circle,  
New Vadaj, Ahmedabad-13,



25022310

MAHENDRAKUMAR V DABHI



Navigation and control icons for the medical software interface, including a left arrow, a button labeled '1 (1)', a right arrow, a red 'X' icon, a magnifying glass icon, an 'ALL' icon with a circular arrow, a key icon, a square icon, and a window management icon.

DELL