

To,

The Coordinator,  
Mediwheel (Arcofemi Healthcare Limited)  
Helpline number: 011- 41195959

Dear Sir / Madam,

**Sub: Annual Health Checkup for the employees of Bank of Baroda**

This is to inform you that the following spouse of our employee wishes to avail the facility of Cashless Annual Health Checkup provided by you in terms of our agreement.

PARTICULARS OF HEALTH CHECK UP BENEFICIARY	
NAME	SARITA PATHAK
DATE OF BIRTH	15-07-1983
PROPOSED DATE OF HEALTH CHECKUP FOR EMPLOYEE SPOUSE	12-07-2021
BOOKING REFERENCE NO.	21S114067100001136S
SPOUSE DETAILS	
EMPLOYEE NAME	MR. PATHAK VIJAY KUMAR
EMPLOYEE EC NO.	114067
EMPLOYEE DESIGNATION	SINGLE WINDOW OPERATOR A
EMPLOYEE PLACE OF WORK	MUMBAI,GHATKOPAR WEST
EMPLOYEE BIRTHDATE	12-12-1976

This letter of approval / recommendation is valid if submitted along with copy of the Bank of Baroda employee id card. This approval is valid from **09-07-2021** till **31-03-2022**. The list of medical tests to be conducted is provided in the annexure to this letter. Please note that the said health checkup is a **cashless facility** as per our tie up arrangement. We request you to attend to the health checkup requirement of our employee's spouse and accord your top priority and best resources in this regard. The EC Number and the booking reference number as given in the above table shall be mentioned in the invoice, invariably.

We solicit your co-operation in this regard.

Yours faithfully,

Sd/-

**Chief General Manager  
HRM Department  
Bank of Baroda**

  
**ATHARVA DIAGNOSTIC CENTRE**  
Gr. Floor, Shop No. 5, Saiprasad Bldg.,  
F-Wing, Sion Kamgar CHS, Sion,  
Mumbai - 400 022.

(Note: This is a computer generated letter. No Signature required. For any clarification, please contact Mediwheel (Arcofemi Healthcare Limited))

**SUGGESTIVE LIST OF MEDICAL TESTS**


FOR MALE	FOR FEMALE
CBC	CBC
ESR	ESR
Blood Group & RH Factor	Blood Group & RH Factor
Blood and Urine Sugar Fasting	Blood and Urine Sugar Fasting
Blood and Urine Sugar PP	Blood and Urine Sugar PP
Stool Routine	Stool Routine
<b>Lipid Profile</b>	<b>Lipid Profile</b>
Total Cholesterol	Total Cholesterol
HDL	HDL
LDL	LDL
VLDL	VLDL
Triglycerides	Triglycerides
HDL / LDL ratio	HDL / LDL ratio
<b>Liver Profile</b>	<b>Liver Profile</b>
AST	AST
ALT	ALT
GGT	GGT
Bilirubin (total, direct, indirect)	Bilirubin (total, direct, indirect)
ALP	ALP
Proteins (T, Albumin, Globulin)	Proteins (T, Albumin, Globulin)
<b>Kidney Profile</b>	<b>Kidney Profile</b>
Serum creatinine	Serum creatinine
Blood Urea Nitrogen	Blood Urea Nitrogen
Uric Acid	Uric Acid
HBA1C	HBA1C
Routine urine analysis	Routine urine analysis
USG Whole Abdomen	USG Whole Abdomen
<b>General Tests</b>	<b>General Tests</b>
X Ray Chest	X Ray Chest
ECG	ECG
2D/3D ECHO / TMT	2D/3D ECHO / TMT
Stress Test	Thyroid Profile (T3, T4, TSH)
PSA Male (above 40 years)	Mammography (above 40 years) and Pap Smear (above 30 years).
Thyroid Profile (T3, T4, TSH)	Dental Check-up consultation
Dental Check-up consultation	Physician Consultation
Physician Consultation	Eye Check-up consultation
Eye Check-up consultation	Skin/ENT consultation
Skin/ENT consultation	Gynaec Consultation



भारत सरकार  
GOVERNMENT OF INDIA



सरिता पाठक  
Sarita Pathak  
जन्म तारीख/DOB: 15/07/1983  
महिला/ FEMALE  
Mobile No: 9323471898




**5312 1726 5160**  
VID - 9151 8089 7194 4806

माझे आधार, माझी ओळख

*2*  
**ATHARVA DIAGNOSTIC CENTRE**  
Gr. Floor, Shop No. 5, Saiprasad Bldg.,  
F-Wing, Sion Kamgar CHS, Sion,  
Mumbai - 400 022.

*Sarita*

  
**DR. RUPAL CHIRMADE**  
M.D.D.G.O.  
Gynaecologist & Obstetrician  
Reg. No. 2001/2428



# ATHARVA HOSPITAL & RESEARCH CENTRE

MATERNITY • SURGICAL • GENERAL ORTHOPEDIC • SUPER SPECIALITY

101, 1st Floor, Saiprasad Building, Sion Kamgar CHS Ltd., Opp. Croma Showroom,  
Sion (East), Mumbai - 400 022. • Email : [atharvahospital@gmail.com](mailto:atharvahospital@gmail.com)  
Tel. : 022-2401 6640 / 913609 6640 • Mobile : 98922 44833 / 98678 39996

Date : 14/07/21

Mrs Savita Pathak.

Age 38yrs | F

Booking Reference No - 2151140671000011365

- Dental checkup
- physician checkup
- Eye checkup.
- SKIN/ENT consultation
- Gynaec Consultation

NAD.

  
**DR. RUPALCHIRMADE**  
M.D.D.G.O.  
Gynaecologist & Obstetrician  
Reg. No. 2001/2428

  
**ATHARVA DIAGNOSTIC CENTRE**  
Gr. Floor, Shop No. 5, Saiprasad Bldg.,  
F-Wing, Sion Kamgar CHS, Sion,  
Mumbai - 400 022.





# ATHARVA DIAGNOSTIC CENTRE

## FULLY AUTOMATED COMPUTERISED PATHOLOGY

### X-RAY, SONOGRAPHY, E.C.G. & 2D ECHO

Shop No. 6, Ground Floor, Sai Prasad Building, Sion Kamgar CHS. Ltd., Opp. Croma Showroom,  
Sion (E), Mumbai - 400 022. • Email : [atharvahospital@ymail.com](mailto:atharvahospital@ymail.com)  
Ph.: 022-2401 6640 / 913609 6640 • Mob.: 98922 44833 / 98678 39996

Patient's Name :- Mrs. Sarita Pathak  
Referred By :- Dr. Atul P. Chirmade.  
Examination :- X-RAY CHEST P.A. VIEW

Date :- 14 Jul 20219  
Age & Sex :- 38 Yrs / F

#### REPORT:-

#### X-RAY CHEST

Both lung fields are clear


Heart and aorta are normal.

Both C.P. angles are clear

Pleura, diaphragm and ribcage appear normal.

#### IMPRESSION:-

➤ Normal Radiogram

  
DR. SANDEEP NYAYANIRGUNE  
MD DNB DMRE  
RADIOLOGIST & SONOLOGIST



# ATHARVA DIAGNOSTIC CENTRE

**FULLY AUTOMATED COMPUTERISED PATHOLOGY**  
**X-RAY, SONOGRAPHY, E.C.G. & 2D ECHO**

Shop No. 6, Ground Floor, Sai Prasad Building, Sion Kamgar CHS. Ltd., Opp. Croma Showroom,  
Sion (E), Mumbai - 400 022. • Email : [atharvahospital@ymail.com](mailto:atharvahospital@ymail.com)  
Ph.: 022-2401 6640 / 913609 6640 • Mob.: 98922 44833 / 98678 39996

PATIENT NAME: MRS. SARITA PATHAK.

DATE: 14 Jul 2021

AGE: 38 YRS/F

**Measurements:**

LA : 31 mm  
AO : 22 mm  
LVID(d) : 44 mm  
LVID (s) : 28 mm  
IVS (d) : 11mm  
LVPW (d) : 11 mm  
RA/RV : 29/29mm  
LVEF : 60 %

**RWMA: NO RESTING RWMA**

**2 D Echo:**

Mitral valve- NORMAL

Aortic valve- NORMAL

PV/RVOT-NORMAL

IVS/IAS- intact

Left sided arch, no coarctation

IVC- NORMAL



# ATHARVA DIAGNOSTIC CENTRE

## FULLY AUTOMATED COMPUTERISED PATHOLOGY

### X-RAY, SONOGRAPHY, E.C.G. & 2D ECHO

Shop No. 6, Ground Floor, Sai Prasad Building, Sion Kamgar CHS. Ltd., Opp. Croma Showroom,  
Sion (E), Mumbai - 400 022. • Email : [atharvahospital@ymail.com](mailto:atharvahospital@ymail.com)  
Ph.: 022-2401 6640 / 913609 6640 • Mob.: 98922 44833 / 98678 39996

#### Doppler study

Mitral valve - TRIVIAL MR.

Aortic valve- NO AR, AV PG- 9 mm of Hg

Tricuspid valve - TRIVIAL TR

PASP by TR jet velocity- 28 mm Hg

NO PAH

E/O LV DIASTOLIC DYSFUNCTION

#### Final Diagnosis

NORMAL CHAMBER DIMENSION

NO RESTING RWMA

NO PAH

E/O DIASTOLIC DYSFUNCTION

NORMAL LV SYSTOLIC FUNCTION

ADV - CLINICAL CORRELATION

DR.T. ABHAY  
M.D (MEDICINE),  
DM (CARDIOLOGY)





# ATHARVA DIAGNOSTIC CENTRE

## FULLY AUTOMATED COMPUTERISED PATHOLOGY

### X-RAY, SONOGRAPHY, E.C.G. & 2D ECHO

Shop No. 6, Ground Floor, Sai Prasad Building, Sion Kamgar CHS. Ltd., Opp. Croma Showroom,  
Sion (E), Mumbai - 400 022. • Email : atharvahospital@ymail.com  
Ph.: 022-2401 6640 / 913609 6640 • Mob.: 98922 44833 / 98678 39996

Patient's Name :- Mrs. Sarita Pathak,  
Referred By :- Dr. Rupal Chirmade,  
Examination :- USG ABDOMEN & PELVIS

Date: - 14 Jul 2021

Age & Sex: - 38 Yrs / F

#### USG ABDOMEN & PELVIS:-

Liver appears normal in size and shows normal echotexture.

There is no evidence of any focal lesion in the liver.

Portal Vein appears normal and measures 10 mm. (Normal < 13mms.)

Gall bladder is normal.

Spleen is normal in echotexture

Pancreas is normal in echotexture.

Both Kidneys are normal in size and echotexture.

Right Kidney measures 85 x 45 mm.

Left Kidney measures 91 x 41 mm.

Bladder is normal.

Uterus is Anteverted and measures 60 x 50 x 45 mm.

Endometrium is normal and measures 5 mm.

Right ovary measures 14 x 17 mm.

Left ovary measures 12 x 14 mm.

Mild free fluid seen in POD

Both Ovaries are normal.

Both the adnexae are clear.

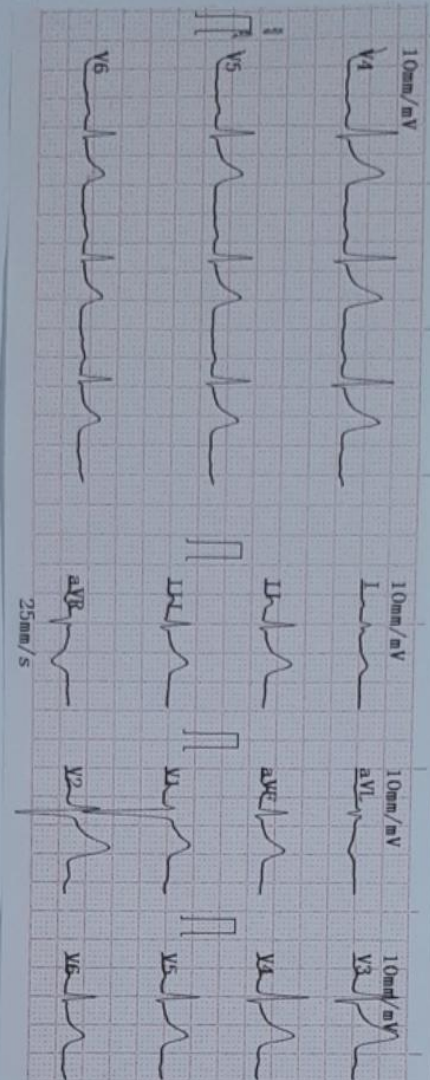
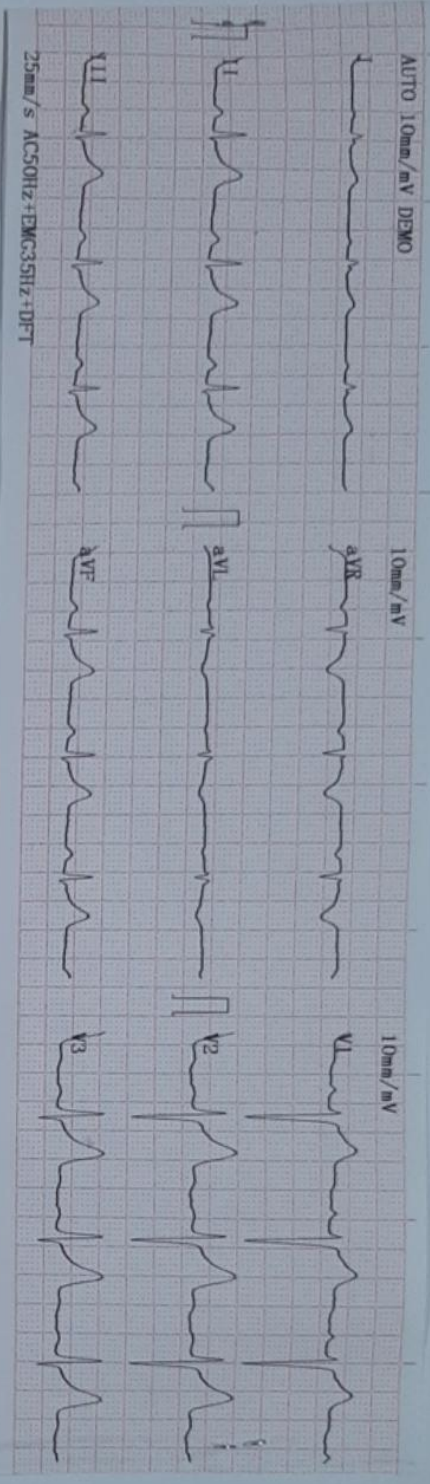
#### IMPRESSION: -

- > Mild Pelvic inflammatory disease.

DR. SANDEEP NYAYANIRGUNE  
MD DNB DMRE  
RADIOLOGIST & SONOLOGIST







8  
 ID : 2021-07-14 10:22  
 Name : Saxta Park  
 Sex : Male  
 Height : 155 cm  
 Age : 38  
 Weight : 52 kg  
 Systolic : 120 mmHg  
 Diastolic : 80 mmHg  
 HR : 70 bpm  
 PR Interval : 181 ms  
 P Duration : 117 ms  
 QRS Duration : 96 ms  
 T Duration : 224 ms  
 QT/QTc : 413/445 ms  
 P/QRS/T Axis : 78.1/50.6/77.8 deg  
 R (V5)/S (V1) : 0.68/1.49  
 R (V5)+S (V1) : 2.17

<< Conclusions >>

Normal sinus rhythm.  
 Cardiac electrical axis normal.

\*\*Revised physician confirm\*\*

**ATHARVA DIAGNOSTIC CENTRE**  
 Gt. Floor, Shop No. 5, Sai Prasad Bldg,  
 F-Wing, Skon Kamgar CHS, Skon,  
 Mumbai - 400 022.

**DR. RUPALCHIRMADE**  
 M.D.D.G.O.  
 Gynaecologist & Obstetrician  
 Reg. No. 2001/2428

**Dr. Abhay Tidake**  
 M.D. D.M. Cardiology  
 Reg. No. 2004/02/0618

Physician





# ATHARVA DIAGNOSTIC CENTRE

**FULLY AUTOMATED COMPUTERISED PATHOLOGY**  
**X-RAY, SONOGRAPHY, E.C.G. & 2D ECHO**

Shop No. 6, Ground Floor, Sai Prasad Building, Sion Kamgar CHS. Ltd., Opp. Croma Showroom,  
Sion (E), Mumbai - 400 022. • Email : atharvahospital@gmail.com  
Ph.: 022-2401 6640 / 913609 6640 • Mob.: 98922 44833 / 98678 39996

NAME: - MRS. SARITA PATHAK. TEST: - PAP SMEAR DATE: - 14/07/21  
AGE: - 38 SEX: - FEMALE REFERRED BY: - DR RUPAL CHIRMADE

## PAP SMEAR

[DONE ON 14/07/21, REPORTED ON: - 16/07/21, LAB NO/HP; - 2/21]

Received 3 smears.

### MICROSCOPIC EXAMINATION:-

CELLULARITY: - Adequate

CELL TYPES: - Superficial cells: - ++ / Intermediate cells: - ++ / Metaplastic cells: - +  
/ End cervical cells: - +

BACKGROUP: - Polymorphs: - +++.

INFECTIVE AGENTS: - Altered bacterial flora present.

EPITHELIAL ABNORMALITIES / MALIGNANCY: - No evidence of

### IMPRESSION:-

NEGATIVE FOR IMTRAEPITHELIAL LESION /MALIGNANCY in these smears.

In view of inflammation repeat PAP smear after treating inflammation.  
Correlate clinically and with colposcopy findings.

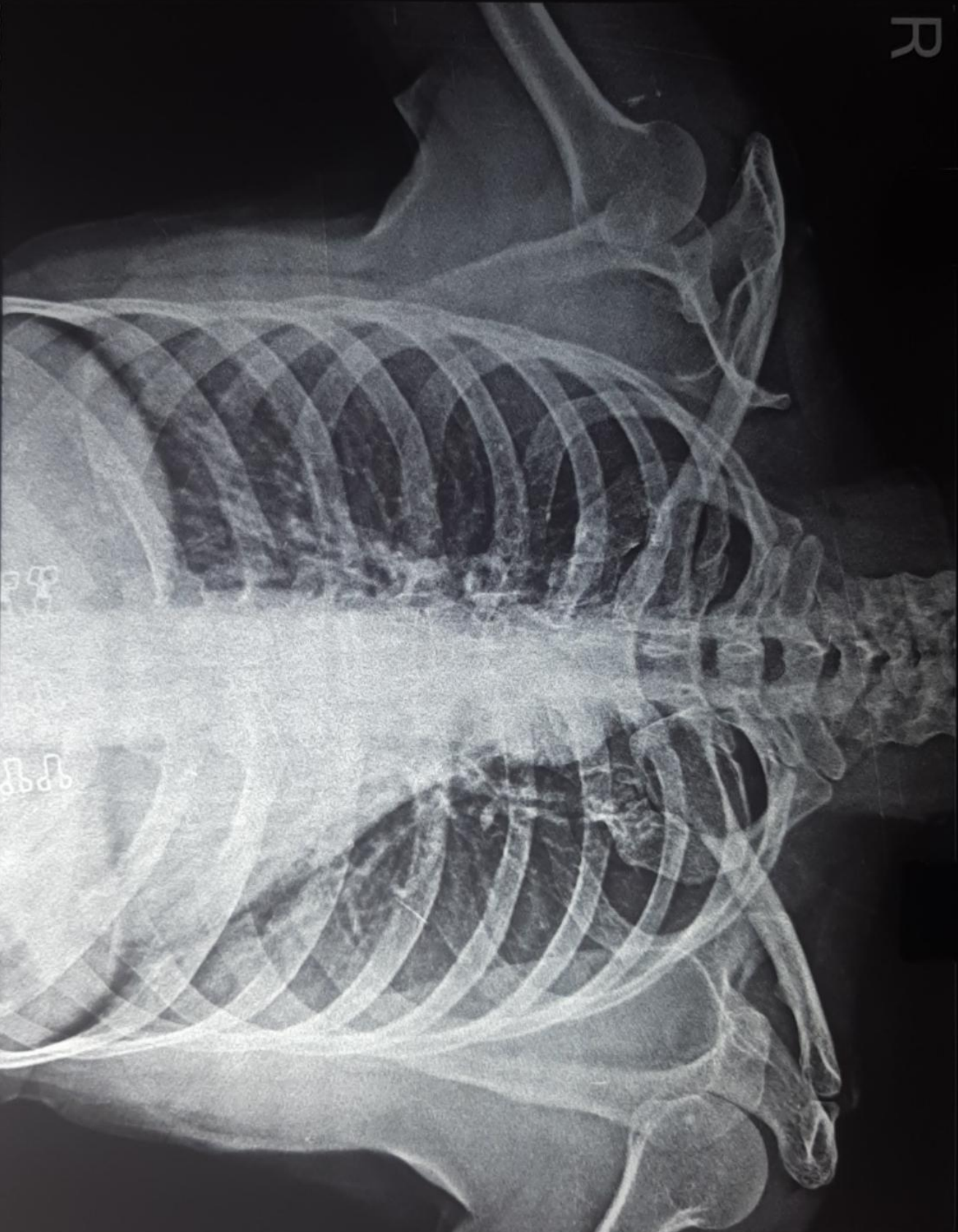
PATHOLOGIST:

Dr. Darshan Gohil MD (Path)

Reg No:- 2008/09/3489



R



MRS SARITA PATHAK 14072103 AGE 38 YERS FEMALE CHEST,FRN P->A 14-Jul  
ATHARVA HOSPITAL AND RESEARCH CENTRE PH: 24016640