



Name	MR. VYSHAK T V	Patient ID	54956
Accession No	53414	Age/Gender	36 Y / Male
Referred By	MEDIWHEEL	Date	14-Aug-2021

USG REPORT - ABDOMEN AND PELVIS

LIVER:

Liver is increased in size (measures ~ 17.3 cm) and shows increased echotexture.

No focal liver lesion. No intra hepatic biliary radical dilatation seen.

GALL BLADDER:

Is adequately distended. No calculus or cholecystitis seen.

PANCREAS:

Appears normal in size and shows uniform echo texture. The pancreatic duct is normal. No calcifications are seen.

SPLEEN:

Appears normal in size and it shows uniform echo texture. It measures ~ 10.9 cm in long axis.

RIGHT KIDNEY:

Right kidney measures ~ 10.2 x 3.5 cms.

The shape, size and contour of the right kidney appear normal.

Cortico medullary differentiation is within normal. No evidence of pelvicalyceal dilatation.

No calculi seen.

LEFT KIDNEY:

Left kidney measures ~ 11.9 x 5 cms .

The shape, size and contour of the left kidney appear normal.

Cortico medullary differentiation is within normal. No evidence of pelvicalyceal dilatation.

No calculi seen.



ARTHI SCANS

Name	MR. VYSHAK T V	Patient ID	54956
Accession No	53414	Age/Gender	36 Y / Male
Referred By	MEDIWHEEL	Date	14-Aug-2021

USG REPORT - ABDOMEN AND PELVIS

URINARY BLADDER:

Is normal contour. No intra luminal echoes are seen.

PROSTATE:

Prostate appears normal in size, Measures ~ 3 x 3.7 x 3.4 cms (Vol - 20 cc).

RIGHT ILIAC FOSSA:

No focal fluid collections seen.

No evidence of hernia seen in anterior abdominal wall.

IMPRESSION:

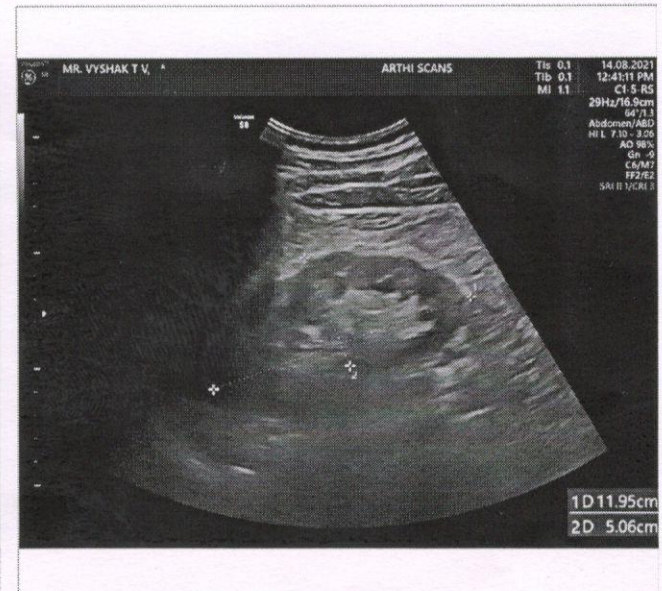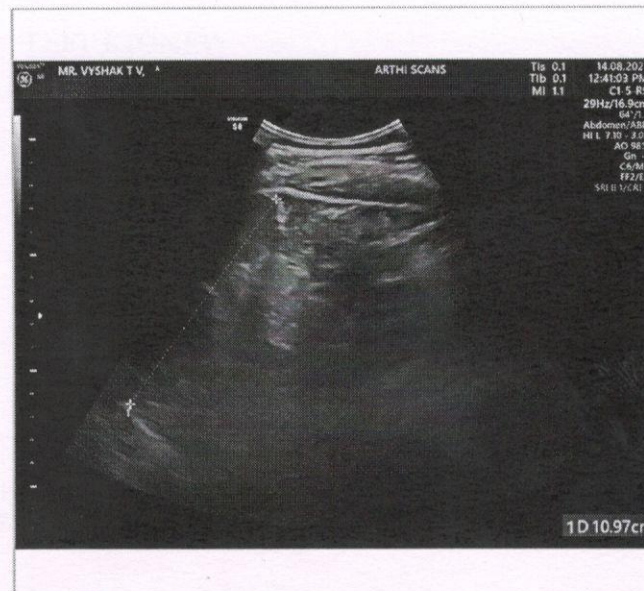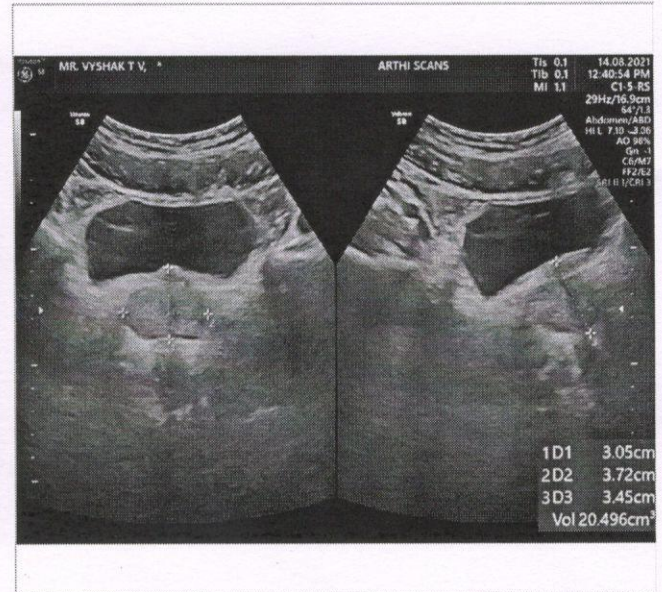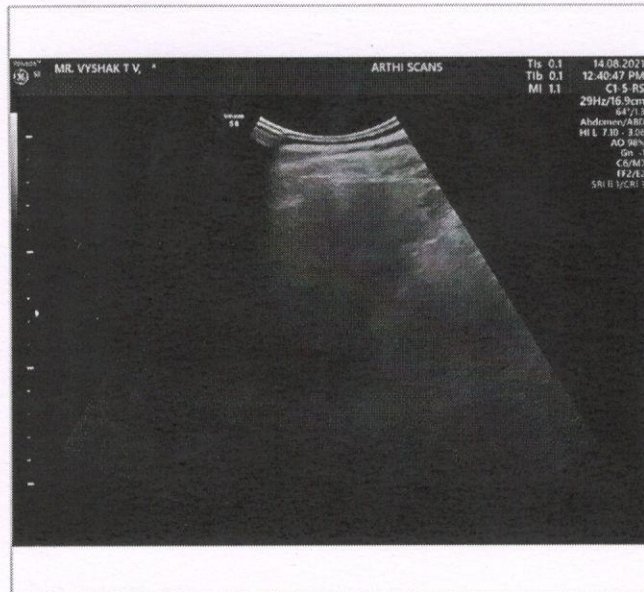
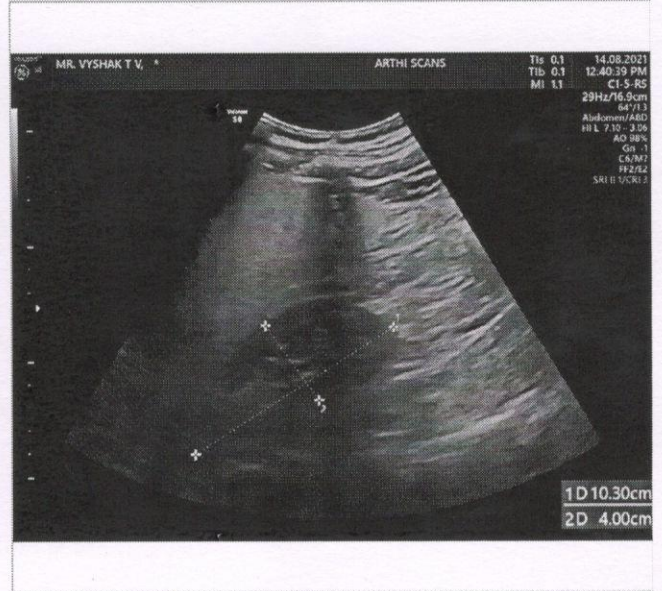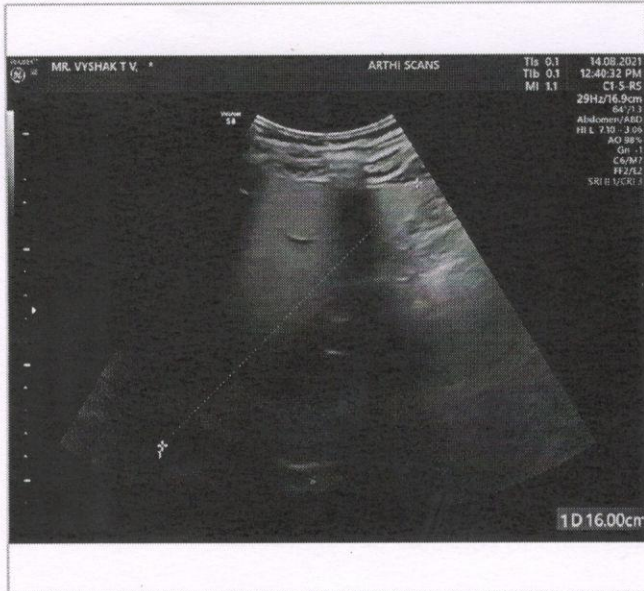- ❖ **Hepatomegaly with grade II fatty liver.**
 - **Suggested clinical correlation.**


Dr. Abinaya Rajasekaran, MDRD.,
Radiologist

Thank you for the courtesy of this referral

Foot Note: Patient's identity is not verified. Report is not valid for medico legal purpose.

MR. VYSHAK T V /M VS8804893-21-08-14-2 14-Aug-2021 09:06:44 AM
 Physician Name





ARTHI SCANS

Name	MR.VYSHAK T V	Patient ID	53414
Accession No	54956	Age/Gender	36Y /MALE
Referred By	MEDIWHEEL	Date	14.08.2021

ECHOCARDIOGRAPHIC EVALUATION

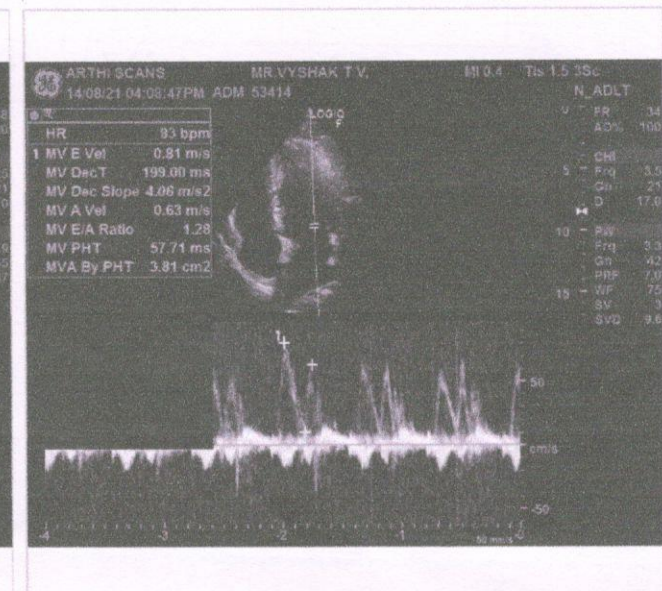
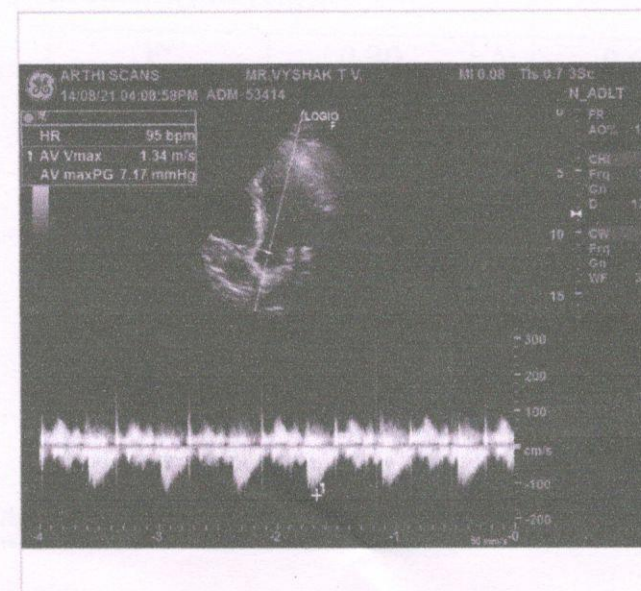
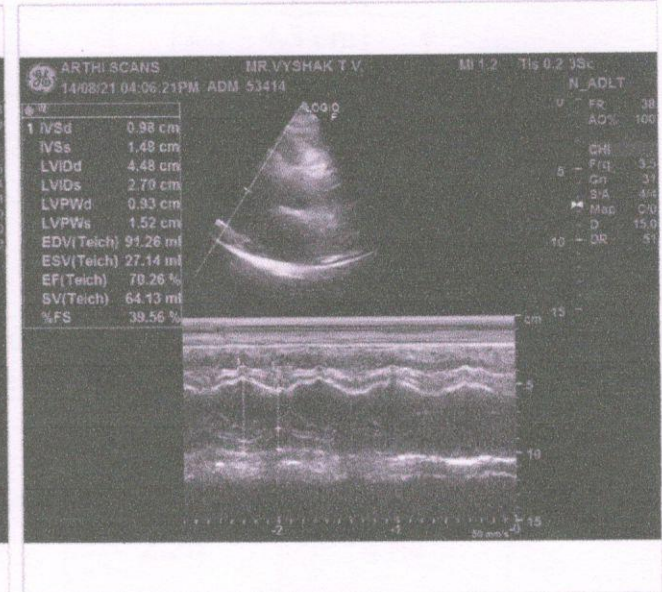
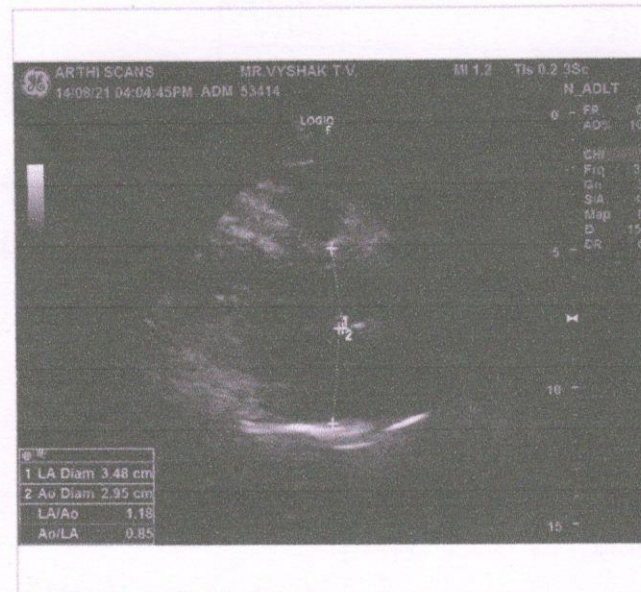
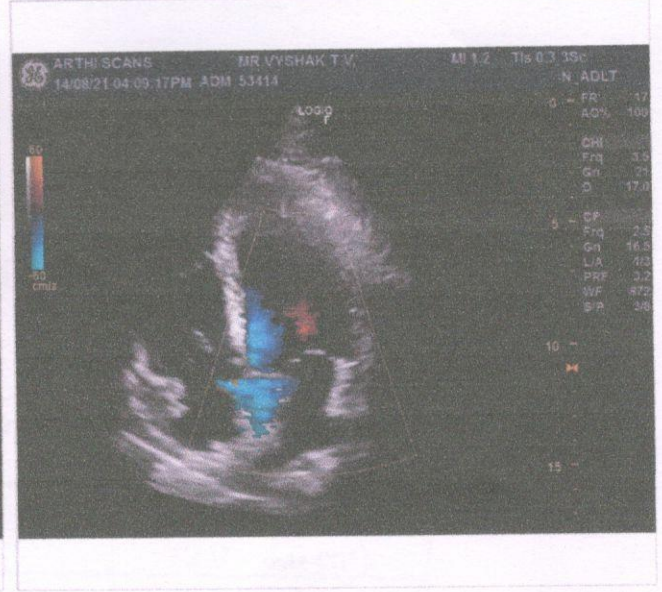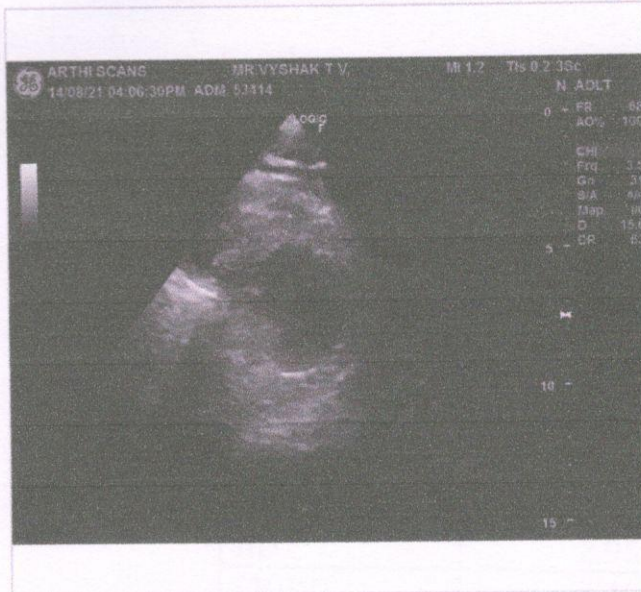
MEASUREMENTS: ACOUSTIC WINDOW: OPTIMAL


2D/ M MODE PARAMETERS

Parameters	Patient Values	Normal Adult Value
LA	3.48	(2.0 - 4.0 cm)
AO	2.95	(2.0 - 4.0 cm)
LVIDD	4.48	(3.5 - 5.5 cm)
LVIDS	2.70	(2.5 - 4.3 cm)
IVSd	0.98	(0.6 - 1.2 cm)
LVPWd	0.93	(0.6 - 1.2 cm)
EF	70	(50% - 70%)

DOPPLER PARAMETERS

valves	Aortic valve	Mitral valve	Tricuspid valve	Pulmonary valve	
Max Velocity(cm.sec)	1.33	0.79	0.74	1.10	
Max Gradient(mm/Hg)	7.17	2.53	2.20	4.84	
E:	0.80	A:	0.63	E/A:	1.27



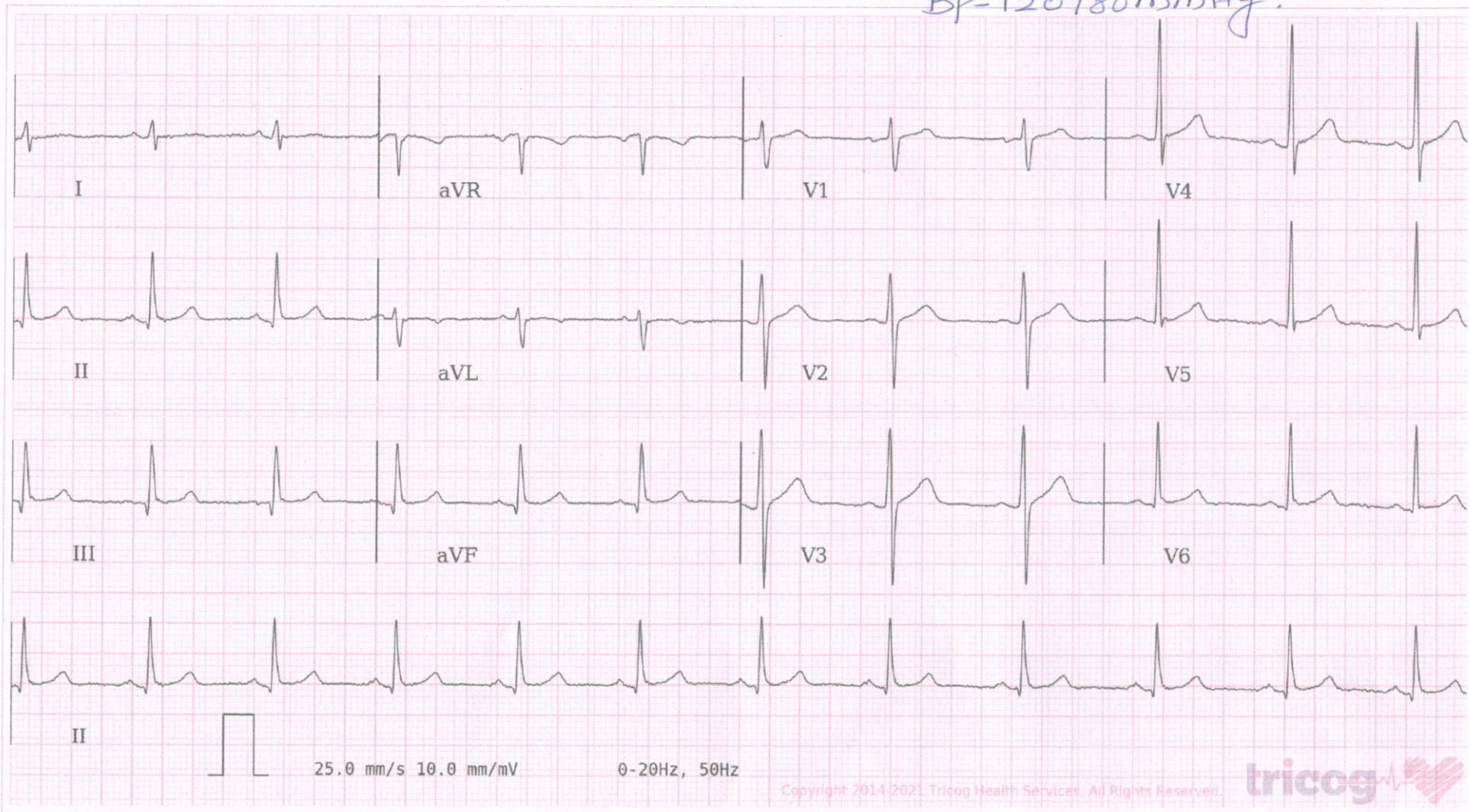


Aarthi CT and MRI Scans, R S Puram West

Age / Gender: 36/Male
Patient ID: 0000053414
Patient Name: MR.VYSHAK T V

Date and Time: 14th Aug 21 9:09 AM

BP-120/80mmHg.



AR: 72 bpm VR: 72 bpm QRSD: 84 ms QT: 388 ms QTc: 424 ms PRI: 150 ms P-R-T: 39° 83° 66°

ECG Within Normal Limits: Sinus Rhythm, Normal Axis. Please correlate clinically.

AUTHORIZED BY

Dr. Charit
MD, DM: Cardiology

REPORT

Dr. Abhisek



VISION TEST ARTHI SCANS

NAME	MR.VYSHAK T V	PATIENT ID	53414
ACCESSION NO	54956	AGE/GENDER	36Y/MALE
REFERRED BY	MEDIWHEEL	DATE	14-AUG-2021

VISUAL ACUITY (VA)

DISTANCE VISION	
Right	6/11
Left	6/10
Both	6/10
NEAR VISION.	
Both	N6

COLOUR VISION.	
BOTH	Normal



बैंक ऑफ बड़ौदा
Bank of Baroda

नाम : टी वी वैशाक
Name : VYSHAK T V

क.कू.सं
E.C. No. : 123989

जारीकर्ता प्राधिकारी
Issuing Authority



धारक के हस्ताक्षर
Signature of Holder

मिलने पर निम्नलिखित को लौटाएं
सहायक महाप्रबंधक (सुरक्षा)
बैंक ऑफ बड़ौदा, बड़ौदा कॉर्पोरेट सेंटर
सी-26, जी - ब्लॉक, बान्द्रा कुर्ला कॉम्प्लेक्स,
मुंबई-400 051, भारत. फोन: 91 22 6698 5196.

If found, please return to:
Assistant General Manager (Security)
Bank of Baroda, Baroda Corporate Centre
C-26, G-Block, Bandra Kurla Complex
Mumbai - 400 051, India. Phone: 91 22 6698 5196.

रक्त समूह / Blood Group : **AB+ve**
पहचान चिन्ह / Identification Marks : **A mole on right side of neck**