

**Patient : MR SHAUNAK SHAH**

**M/26 Y**

**27-Apr-24**

**Ref By : Dr ARCOFEMI HEALTHCARE LT.**

**No : 5**

**BLOOD SUGAR**

<u>Test</u>	<u>Value</u>	<u>Normal Range</u>	<u>Units</u>
FASTING BLOOD SUGAR	89	70-110	mg/dl
Urine Sugar	Absent		
Urine Ketones	Absent		
POST PRANDIAL BLOOD SUGAR	110	70-140	mg/dl
Urine Sugar (2 hrs)	No Sample		
Urine Ketones (2 Hrs)	No Sample		

METHOD : Glucose Oxidase Peroxidase ( GOD/POD )

American Diabetes Association (ADA 2013) Blood Glucose Level Criteria :

**FASTING GLUCOSE LEVEL**

Normal glucose tolerance : < 100 mg %

Impaired Fasting Glucose : 100 - 125 mg %

Provisional diagnosis for:  $\geq 126$  mg % (on two different occasions)  
diabetes mellitus

**POST LUNCH GLUCOSE LEVEL**

Normal glucose tolerance : <140 mg %

Impaired Glucose Tolerance : 140 - 199 mg %

Provisional diagnosis for:  $\geq 200$  mg % (on two different occasions)  
diabetes mellitus

**URINE SUGAR INTERPRETATION : (Approx.)**

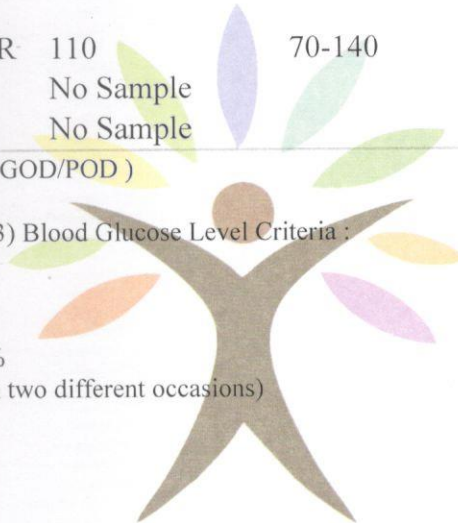
Trace : 0.1 g/dl

+ : 0.25 g/dl

++ : 0.5 g/dl

+++ : 1.0 g/dl

++++ : >2.0 g/dl



*Ashwini Sangvikar*

**Dr Ashwini Sangvikar**

**M.D. Pathology**

<b>Patient : MR SHAUNAK SHAH</b>	<b>M/26 Y</b>	<b>27-Apr-24</b>
<b>Ref By : Dr ARCOFEMI HEALTHCARE LT.</b>		<b>No : 5</b>

**BIOCHEMISTRY**

<u>Test</u>	<u>Value</u>	<u>Normal Range</u>	<u>Units</u>
BUN / CREATININE RATIO	20.1	5 - 23.5	
Creatinine	0.7	0.5-1.3	mg/dl



*Ashwini Sangvikar*

Dr Ashwini Sangvikar

M.D. Pathology



Patient : MR SHAUNAK SHAH

M/26 Y

27-Apr-24

Ref By : Dr ARCOFEMI HEALTHCARE LT

No : 5

**BIOCHEMISTRY**

<u>Test</u>	<u>Value</u>	<u>Normal Range</u>	<u>Units</u>
Bilirubin (Total)	0.90	0.0-1.20	mg/dl
Bilirubin (Direct)	0.25	0.0-0.40	mg/dl
Bilirubin (Indirect)	0.7	0.1-1.0	mg/dl
S.G.P.T	19.3	0.0-40.0	IU/L



*Ashwini Sangvikar*

Dr Ashwini Sangvikar

M.D. Pathology

Patient : MR SHAUNAK SHAH

M/26 Y

27-Apr-24

Ref By : Dr ARCOFEMI HEALTHCARE LT

No : 5

**BLOOD GROUP**

**Test**

BLOOD GROUP

**Value**

"O" Positive.

Method: Slide & Tube Agglutination



*Ashwini Sangvikar*

Dr Ashwini Sangvikar

M.D. Pathology



Patient : MR SHAUNAK SHAH

M/26 Y

27-Apr-24

Ref By : Dr ARCOFEMI HEALTHCARE LT

No : 5

Urine Routine

Test

Value

Physical Examination:

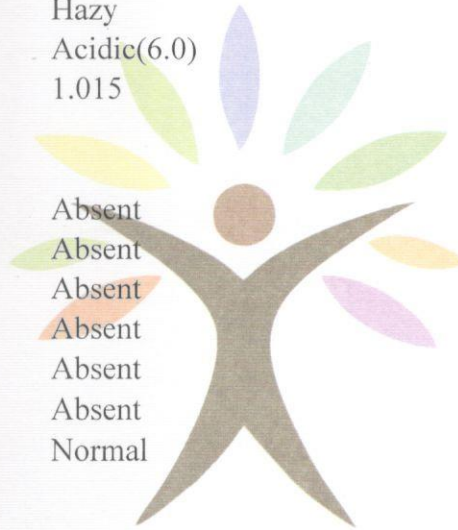
Quantity	10 ml
Colour	Pale Yellow
Appearance	Hazy
Reaction (pH)	Acidic(6.0)
Specific Gravity	1.015

Chemical Examination:

Proteins	Absent
Glucose	Absent
Ketone Bodies	Absent
Occult Blood	Absent
Bile Salts	Absent
Bile Pigments	Absent
Urobilinogen	Normal

Microscopic Examination:

Pus Cells	5 - 6 / hpf
Red Blood Cells	Absent
Epithelial Cells	6 - 8 / hpf
Casts	Absent
Crystals	Absent
Bacteria	Absent
Yeast Cells	Absent
Amorphous Deposits	Absent
Mucus	Present (Trace)
Other	----



*Ashwini Sangvikar*

Dr Ashwini Sangvikar

M.D. Pathology

Patient : MR SHAUNAK SHAH

M/26 Y

27-Apr-24

Ref By : Dr ARCOFEMI HEALTHCARE LT

No : 5

**COMPLETE BLOOD COUNT WITH ESR**

<u>Test</u>	<u>Value</u>	<u>Normal Range</u>	<u>Units</u>
HAEMOGLOBIN	14.8	13.5 - 18.0	gms/dl
R.B.C. COUNT	4.78	4.50 - 6.50	millions/cumm
PCV	44.2	40.0 - 54.0	%
MCV	92.5	76.0 - 96.0	u3
MCH	31.0	27.0 - 32.0	pg
MCHC	33.5	30.0 - 35.0	%
RDW	14.1	11.5 - 14.5	%
W.B.C. COUNT	5,170	4,000-11,000	cells/cmm
<b><u>Differential Count :</u></b>			
Neutrophils	51	45 - 70	%
Lymphocytes	38	20 - 45	%
Eosinophils	05	1 - 6	%
Monocytes	06	1 - 10	%
Basophils	00	0 - 1	%
PLATELET COUNT	195,000	150,000 - 450,000	cells/cmm
PLATELETS ON SMEAR	Adequate		
R.B.C. MORPHOLOGY	Normocytic Normochromic		
W.B.C. MORPHOLOGY	Normal		
E.S.R (Westergren)	15	0 - 20	mm / hr

CBC done on Fully Automated Erba H560 Cell Counter.

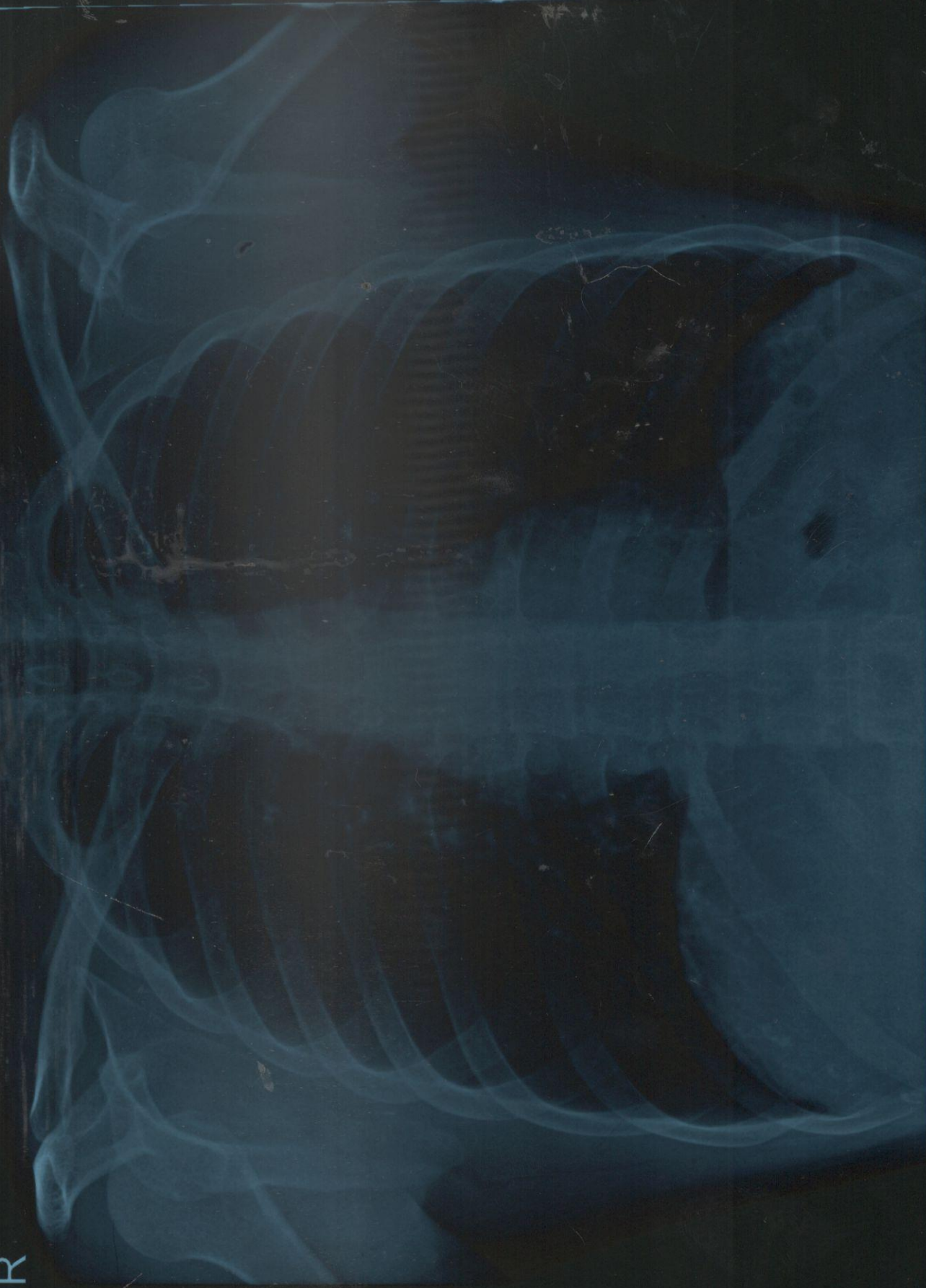
*Ashwini Sangvikar*

Dr Ashwini Sangvikar

M.D. Pathology



R



27/04/2024 4576 MR.SHAUNAK SHAH 26 Y M APOLLO-ARCOFEMI HEALTHCARE.LTD CHEST PA  
Pulse Diagnostic Centre (Radwave Diagnostic Pvt. Ltd), Borivali



PATIENT NAME : MR. SHAUNAK SHAH  
AGE/ SEX : 28 YRS / MALE  
REF.CLINICIAN : APOLLO-ARCOFEMI HEALTHCARE LTD  
DATE : 27/04/2024


X-RAY CHEST (P A VIEW)

- Both lung fields are clear.
- Both CP angle are normal.
- Cardiac and aortic shadows are normal.
- No obvious hilar or mediastinal lesion is seen.
- Bony thorax appears normal. No evidence of fracture seen.

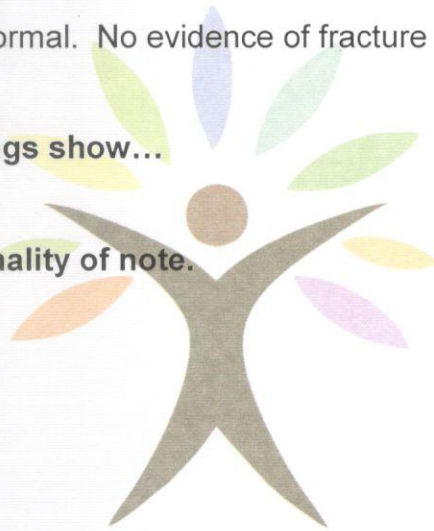
CONCLUSION: X-Ray findings show...

- No significant abnormality of note.

Please correlate clinically.  
Thanks for the referral,



Dr. Tilak Manilal Dedhia  
M.B.B.S; M.D; D.N.B.(Radio-diagnosis)  
Consultant Radiologist,





# 12 LEAD ECG REPORT



## Radwave Diagnostics Pvt. Ltd.

27/04/24

Name: Mr Shawnak Shah 26/male Apollo - Arcofemi HealthCare Ad

- ▶ Pathology ▶ Digital X - ray ▶ Sonography ▶ 3D - 4D Sonography ▶ Color Doppler ▶ ECG
- ▶ 2D Echo ▶ EEG ▶ EMG ▶ NCV ▶ PFT ▶ Mammography ▶ FNAC ▶ USG Guided Procedures
- ▶ X-Ray Special investigations ▶ Holter Monitor ▶ Sleep Study & Others.



Prescribed by:

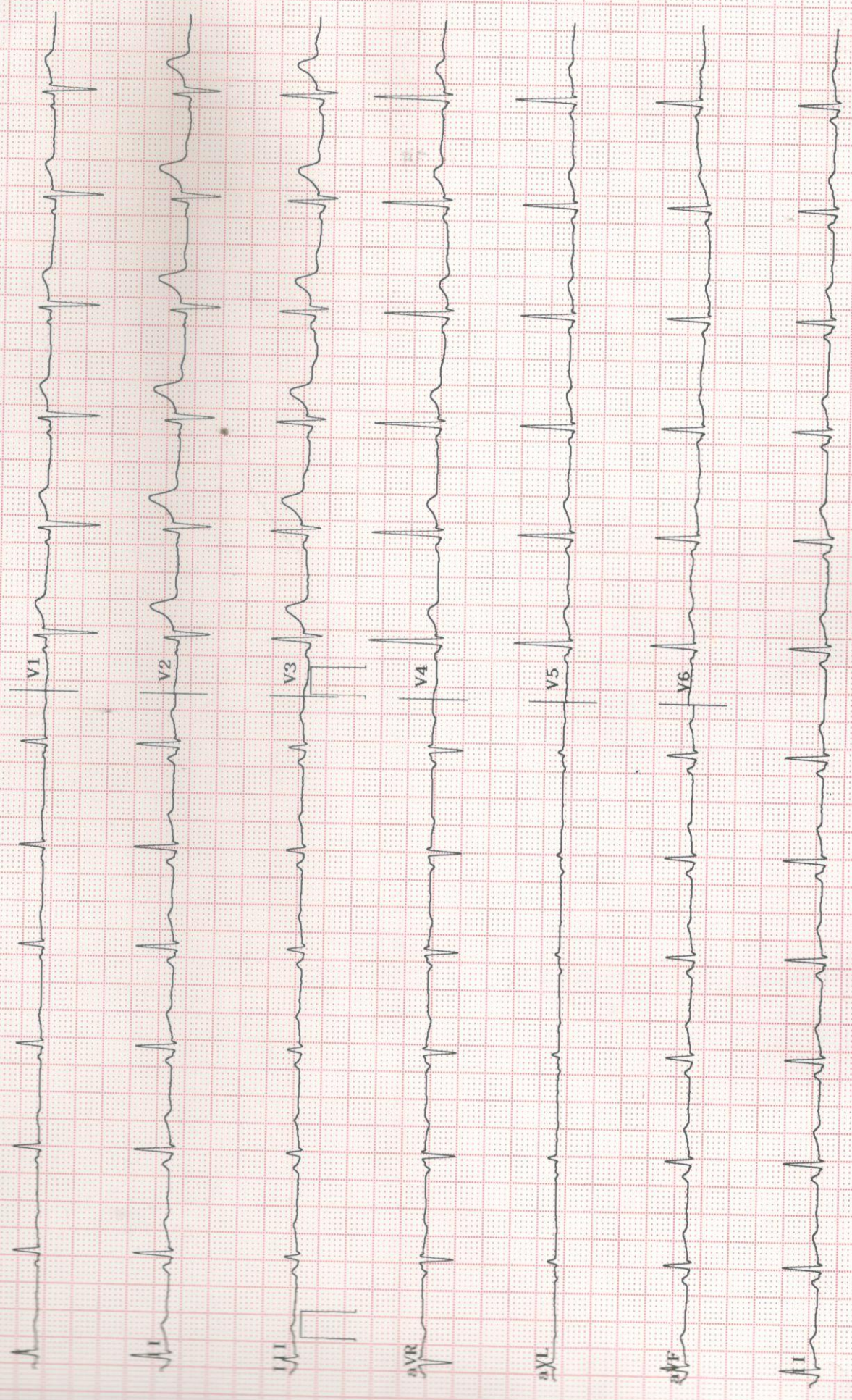
(To be finally confirmed by physician)

*DR. A.*

Heart Rate: 78 bpm  
 PR/RR Int.: 106/769 ms  
 QRS Dur: 92 ms  
 QT/QTc: 356/403 ms  
 P-R-T axes: 71 47 70  
 SV1/RV5/R+S: 0.89/0.98/1.87mV

ID :  
 Name: SHAUNAK  
 Age: 26 years  
 Sex: Male  
 H: 10 cm / W: 0 kg

\*\* Analysis Result \*\*  
 Normal Sinus Rhythm  
 Normal Axis  
 I Normal ECG I





# ELECTROCARDIOGRAM

Please Photocopy ECG As Tracings Fades After Some Time

Name: Mr. Shaunak. Shah  
Date: 27/4/24 Time: \_\_\_\_\_ Age / Sex: 26 / M

Heart Rate: \_\_\_\_\_

Rhythm: \_\_\_\_\_

Axis: \_\_\_\_\_

Voltage: \_\_\_\_\_

P Wave: \_\_\_\_\_

PR Interval: \_\_\_\_\_

Qrs Interval & Complex: \_\_\_\_\_

ST Segment: \_\_\_\_\_

T Wave: \_\_\_\_\_

QT Interval: \_\_\_\_\_

QTC: \_\_\_\_\_

Impression: \_\_\_\_\_

Signature of Physician \_\_\_\_\_

cont

Paul