



भारत सरकार
GOVERNMENT OF INDIA



रीचा
Richa

जन्म तिथि / DOB: 21/03/1991

महिना / FEMALE

Mobile No.: 9896144530

5449 1618 6891



मेरा आधार, मेरी पहचान

Richa


Dr. NITIN AGARWAL
MBBS, MD
Regn. No. DMC-R-1436



भारतीय विशिष्ट पहचान प्राधिकरण
UNIQUE IDENTIFICATION AUTHORITY OF INDIA

पताशोधन
अरुण गoyal, हाउस नं 187, फर्स्ट फ्लोर, ब्लॉक बी, लोक
विहार, झुलेलाल अपार्टमेंट गेट नं 3 के सामने, पीतमपुरा, उत्तर
पश्चिमी,
दिल्ली - 110034

Address:
W/O Arun Goyal, House No 187, first Floor, Block
B, lok Vihar, Opposite Jhulelal Apartment Gate No
3, Pitampura, North West Delhi, Delhi - 110034



Generation Date: 06/04/2018

1947
1800 300 1947
help@uidai.gov.in
www.uidai.gov.in
P.O. Box No. 1947,
Bengaluru-560 001

ONEPLUS ULTRASOUND LAB
47, Harsh Vihar, Pitampura,
Delhi-110034
Ph. 011-42480101, 9599913051
E-mail: oneplusul@gmail.com



Rida

Dr. NITIKA ARWAL
MBBS, MD
Regn. No. DMC-R-1436

ONEPLUS ULTRASOUND LAB
47, Harsh Vihar, Pitam Pura,
Delhi-110044
Ph. 011-42480101, 9599913051
E-mail: oneplusul@gmail.com

ONEPLUS ULTRASOUND LAB

47, HARSH VIHAR, PITAMPURA, DELHI-110034

Ms. RICHA
 Age : 31/F
 Ref. by : MEDIWHEEL
 Indication1 :
 Indication2 :
 Indication3 :
 COMMENTS :

ID : 1810
 HWT : 152/71
 Recorded : 11-11-2021 9:38
 Medication1 :
 Medication2 :
 Medication3 :

BPM : 94
 BP : 118/72
 P Axis : 55 deg
 QRS Axis : 72 deg
 T Axis : 38 deg

P duration : 83 msec
 PR duration : 136 msec
 QRS duration : 100 msec
 QT Interval : 306 msec
 QTc Interval : 404 msec

Raw E.C.G. (Seq)

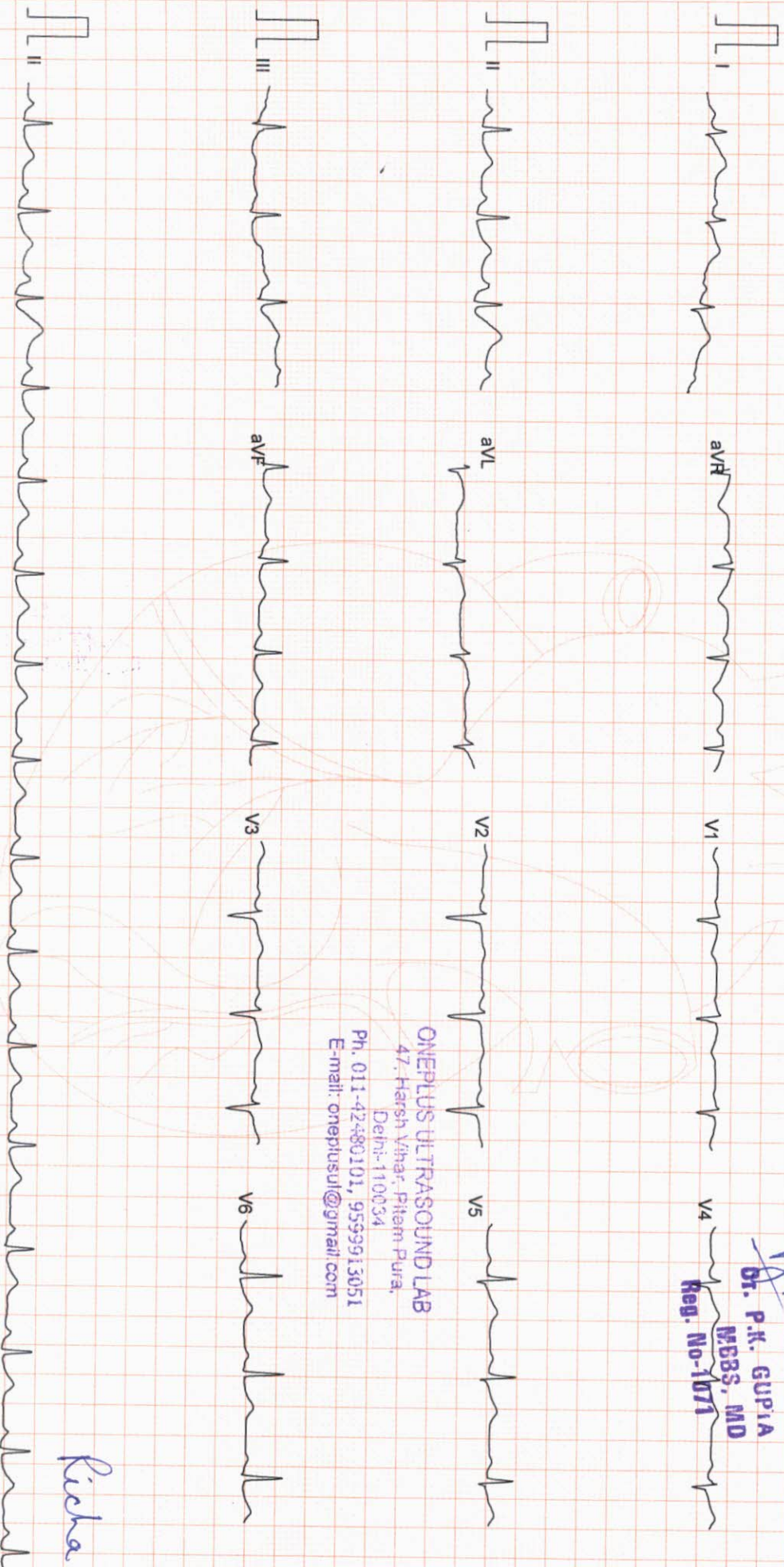
Unconfirmed Report Reviewed By:

Cardiologist

[Signature]
Dr. P.K. GUPIA
MBBS, MD
Reg. No-1071

ONEPLUS ULTRASOUND LAB
 47, Harsh Vihar, Pitam Pura,
 Delhi-110034
 Ph. 011-42480101, 9599913051
 E-mail: oneplusul@gmail.com

Richa



Filtered

25mm/sec 10mm/mV

ARROW

CardiCom, INDIA

ONEPLUS ULTRASOUND LAB

47, HARSH VIHAR PITAMPURA DELHI 110034

Ms. RICHA
 Age : 31/F
 Ref by : MEDIWHEEL
 Indication1 :
 Indication2 :
 Indication3 :

ID : 999
 H/Wt : 152/71
 Recorded : 11-11-2021 9:42

TREADMILL TEST SUMMARY REPORT
 Protocol: BRUCE
 History:
 Medication1 :
 Medication2 :
 Medication3 :

PHASE	PHASE TIME	STAGE TIME	SPEED (Km./Hr.)	GRADE (%)	H.R. (BPM)	B.P. (mmHg)	RPP X100	II	ST LEVEL (mm) V2	V5	METS
STANDING					93	118/72	109	0.5	0.5	0.4	
SUPINE					94	118/72	110	0.5	0.4	0.4	
STAGE 1	2:59	2:59	2.70	10.00	155	130/76	201	0.4	0.5	0.3	4.80
STAGE 2	5:59	2:59	4.00	12.00	183	142/80	259	-0.1	0.3	0.0	7.10
STAGE 3	6:14	0:14	5.40	14.00	184	142/80	261	0.3	0.2	0.1	7.33
PEAK EXER	6:25	0:25			188	156/84	293	0.3	0.2	0.2	
RECOVERY	2:59	2:59	0.00	0.00	112	124/78	138	0.2	0.4	0.2	7.51

RESULTS
 Exercise Duration : 6:25 Minutes
 Max Heart Rate : 188 bpm 99 % of target heart rate 189 bpm
 Max Blood Pressure : 156/84 mmHg
 Max Work Load : 7.51 METS
 Reason of Termination :
IMPRESSIONS : *Negative for wall clots*

ONEPLUS ULTRASOUND LAB
 47, Harsh Vihar, Pitam Pura,
 Delhi-110034
 Ph. 011-42480101, 9599913051
 E-mail: oneplusul@gmail.com

[Signature]
DR. P. JIGIS GUPTA
 Cardiologist
 MBBS, MD
 Reg N. 371

Richa

ONEPLUS ULTRASOUND LAB

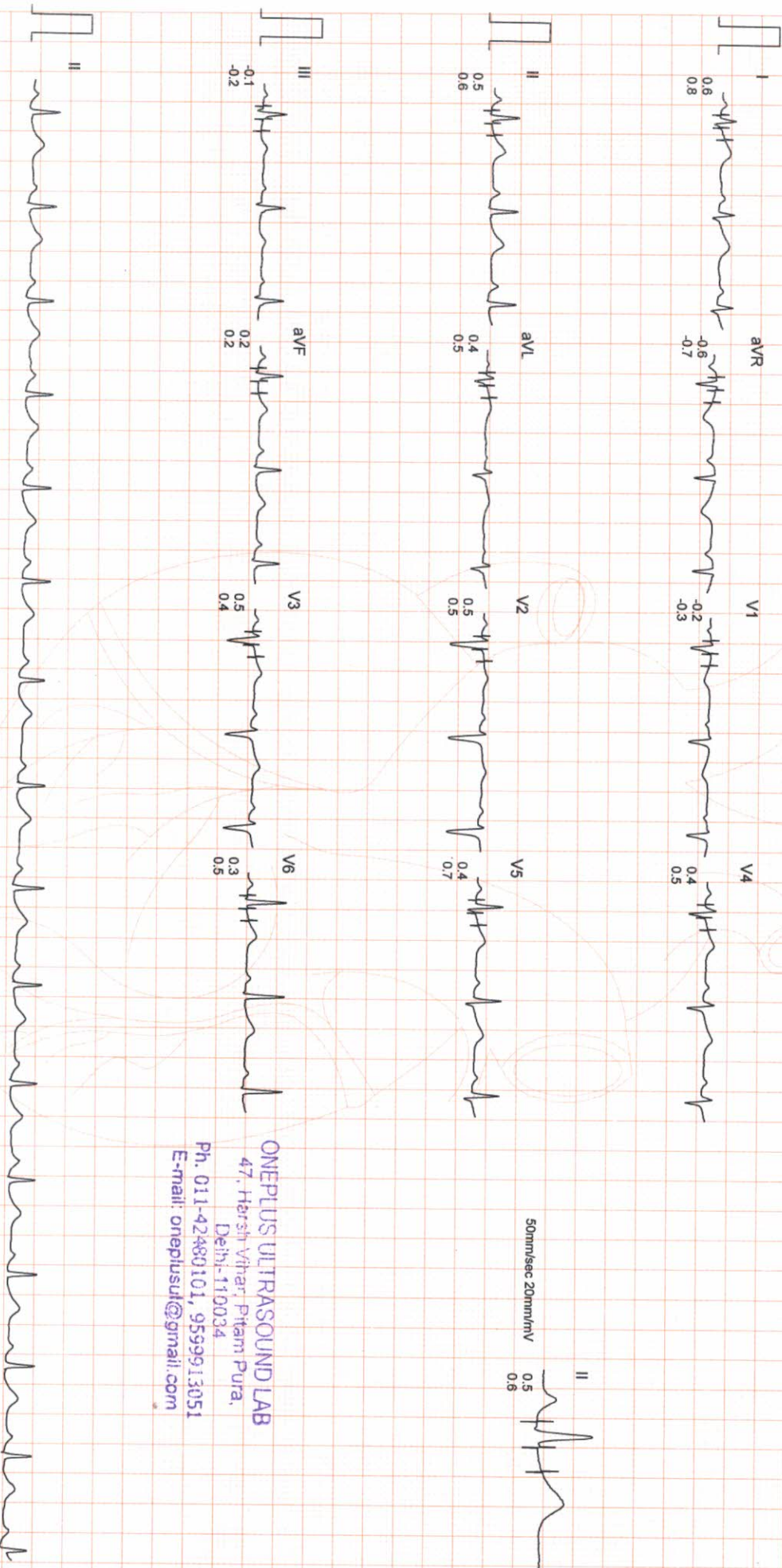
STANDING
PRETEST

ST @ 10mm/mV
80ms PostJ

Ms. RICHA
I.D. : 999
AGE/SEX : 31/F
RECORDED : 11-11-2021 9:42

RATE : 93 BPM
B.P. : 118/72 mmHg

LINKED MEDIAN



ONEPLUS ULTRASOUND LAB
47, Hersh Vihar, Pitam Pura,
Delhi-110034
Ph. 011-42480101, 9559913051
E-mail: oneplusul@gmail.com

ONEPLUS ULTRASOUND LAB

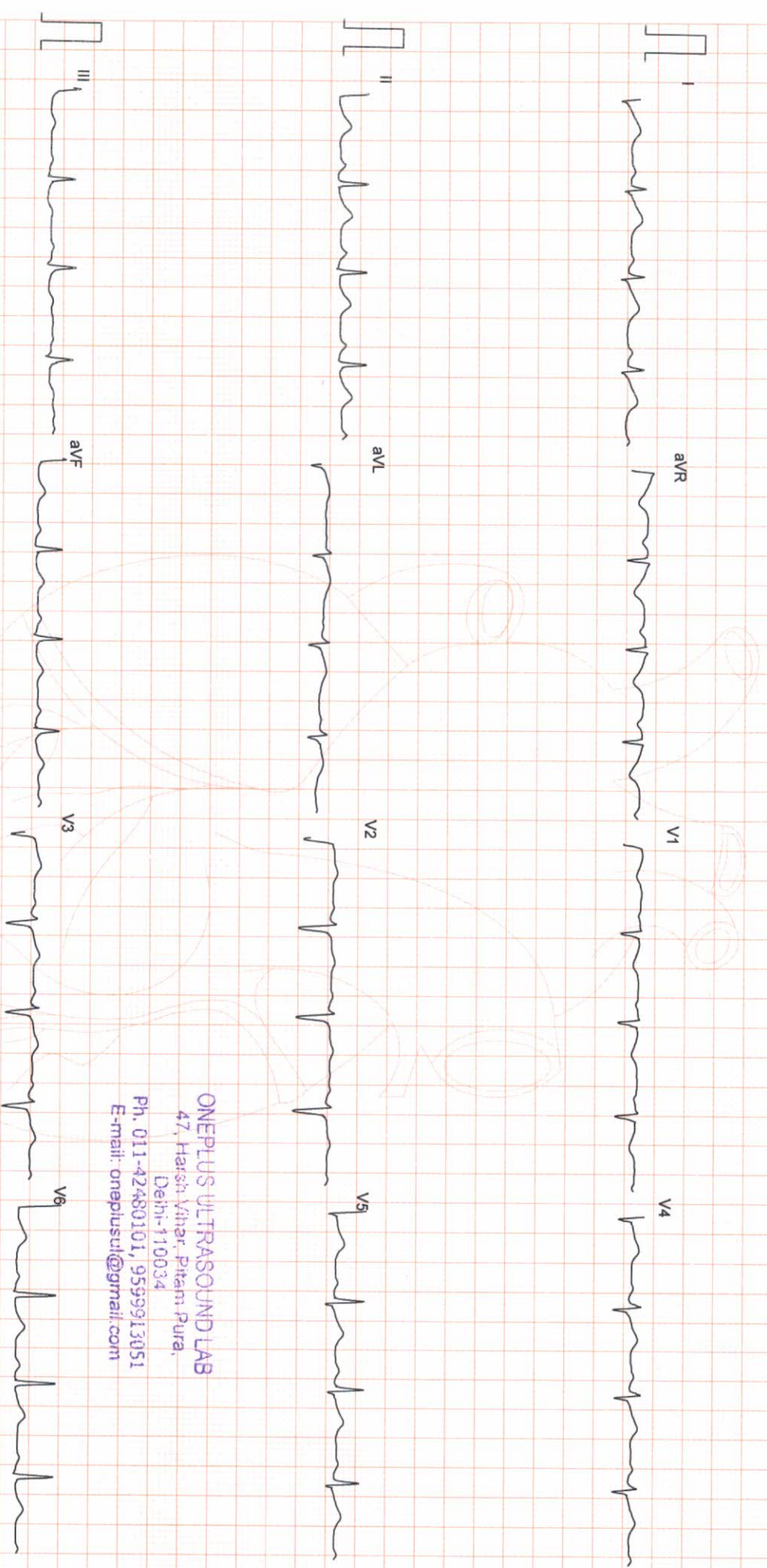
Ms. RICHA
I.D. : 999
AGE/SEX : 31/F
RECORDED : 11-11-2021 9:42

RATE : 94 BPM
B.P. : 118/72 mmHg

SUPINE
PRETEST

ST @ 10mm/mV
80ms PostJ

RAW E.C.G.



ONEPLUS ULTRASOUND LAB
47, Harish Vihar, Pitam Pura,
Delhi-110034
Ph. 011-42480101, 9559913051
E-mail: onepiusul@gmail.com

Filtered

25mm/sec 10mm/mV

Asus W

CardiCom, INDIA Ph.:091-731-2620740, TeleFax:091-731-2431214

ONEPLUS ULTRASOUND LAB

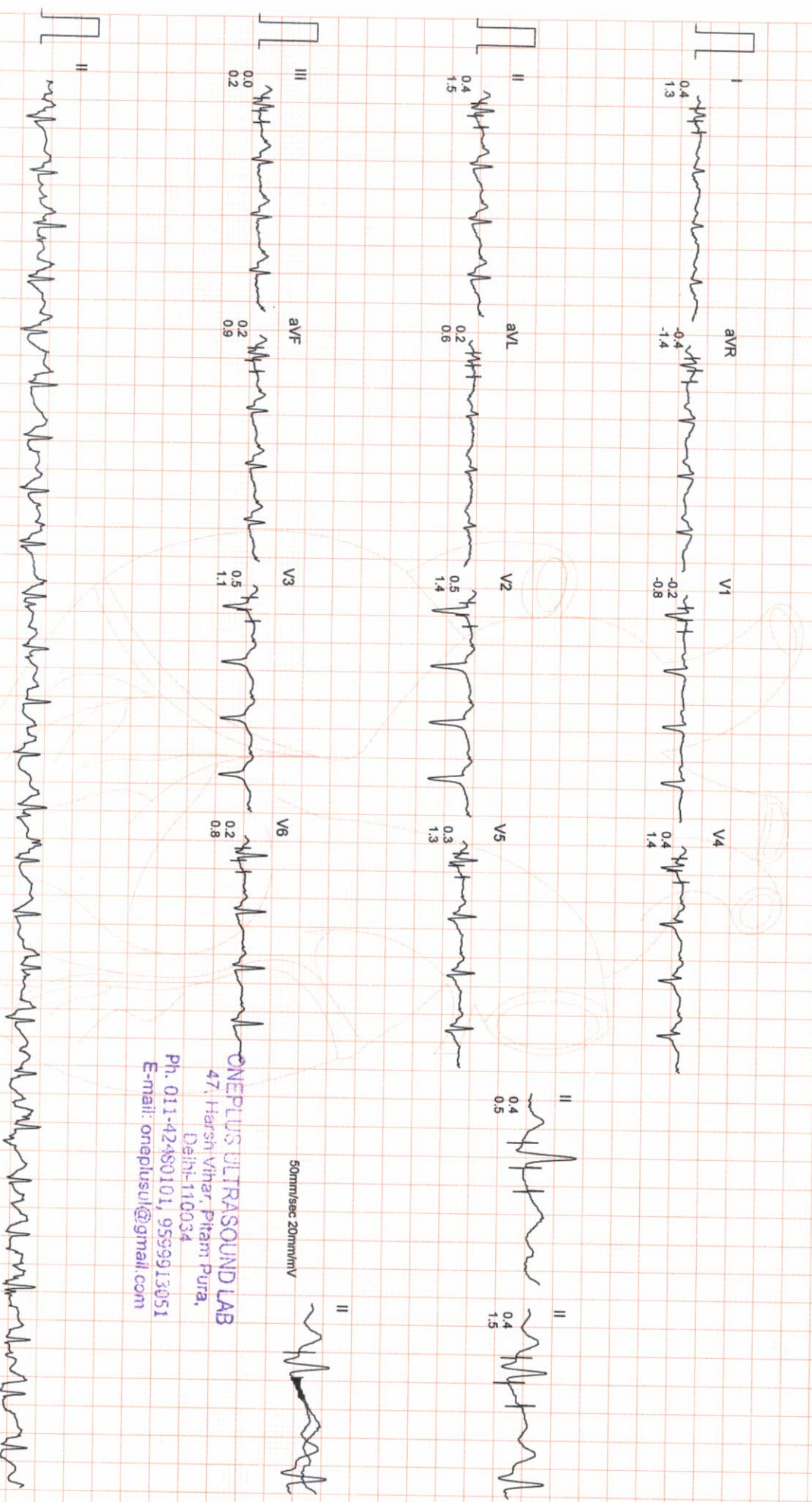
Ms. RICHA
I.D. : 999
AGE/SEX : 31/F
RECORDED : 11-11-2021 9:42

RATE : 155 BPM
B.P. : 130/76 mmHg

BRUCE
EXERCISE 1
PHASE TIME : 2:59
STAGE TIME : 2:59

ST @ 10mm/mV
80ms PostJ
SPEED : 2.7 Km./Hr.
GRADE : 10.0 %

LINKED-MEDIAN



ONEPLUS ULTRASOUND LAB
47, Harsh Vihar, Pitam Pura,
Delhi-110034
Ph. 011-42480101, 9599913051
E-mail: onepplusul@gmail.com

ONEPLUS ULTRASOUND LAB

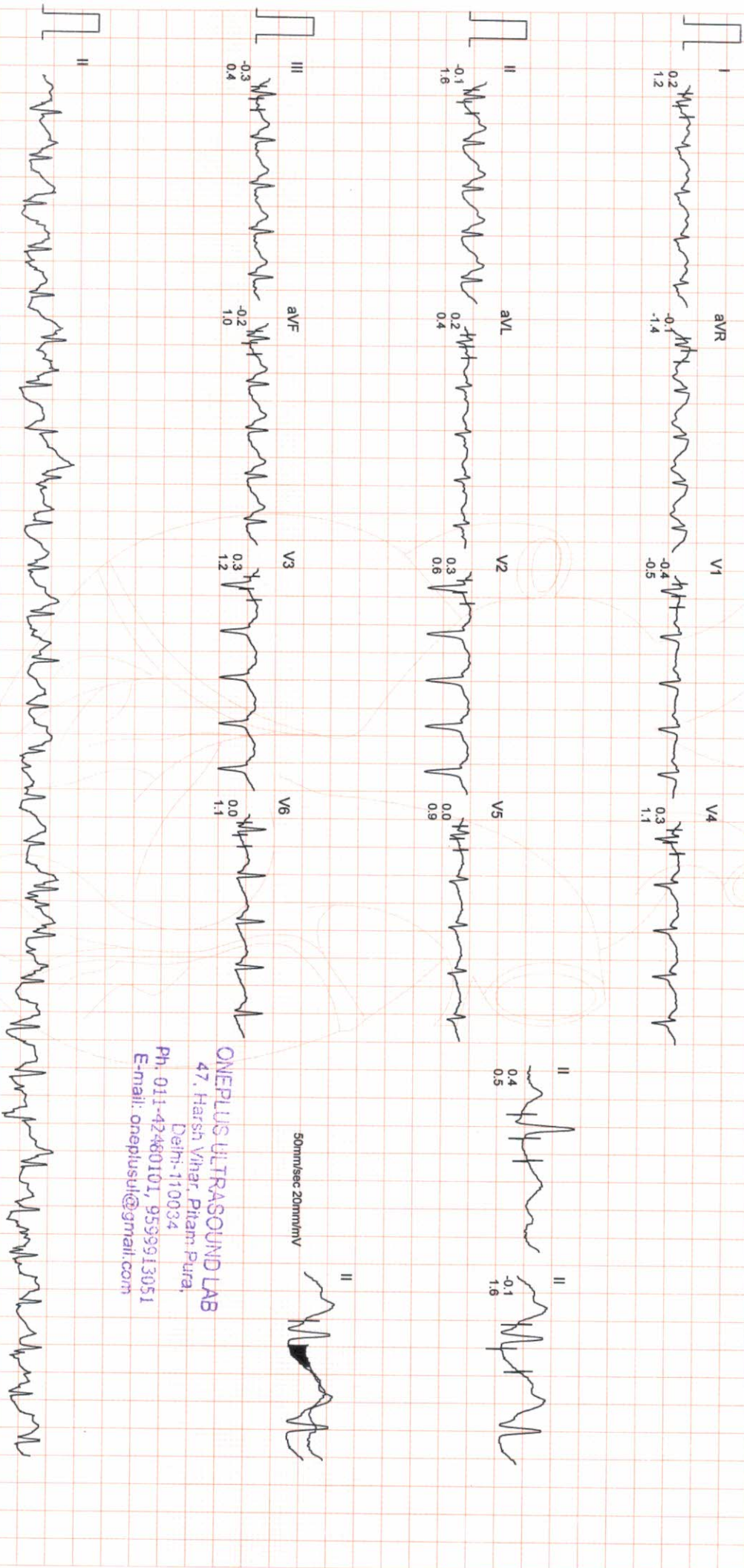
Ms. RICHA
I.D. : 999
AGE/SEX : 31/F
RECORDED : 11-11-2021 9:42

RATE : 183 BPM
B.P. : 142/80 mmHg

BRUCE
EXERCISE 2
PHASE TIME : 5:59
STAGE TIME : 2:59

ST @ 10mm/mV
80ms PostJ
SPEED : 4.0 Km./Hr.
GRADE : 12.0 %

LINKED MEDIAN



ONEPLUS ULTRASOUND LAB
47, Harsh Vihar, Pitam Pura,
Delhi-110034
Ph. 011-42480101, 9593913051
E-mail: oneplusul@gmail.com

ONEPLUS ULTRASOUND LAB

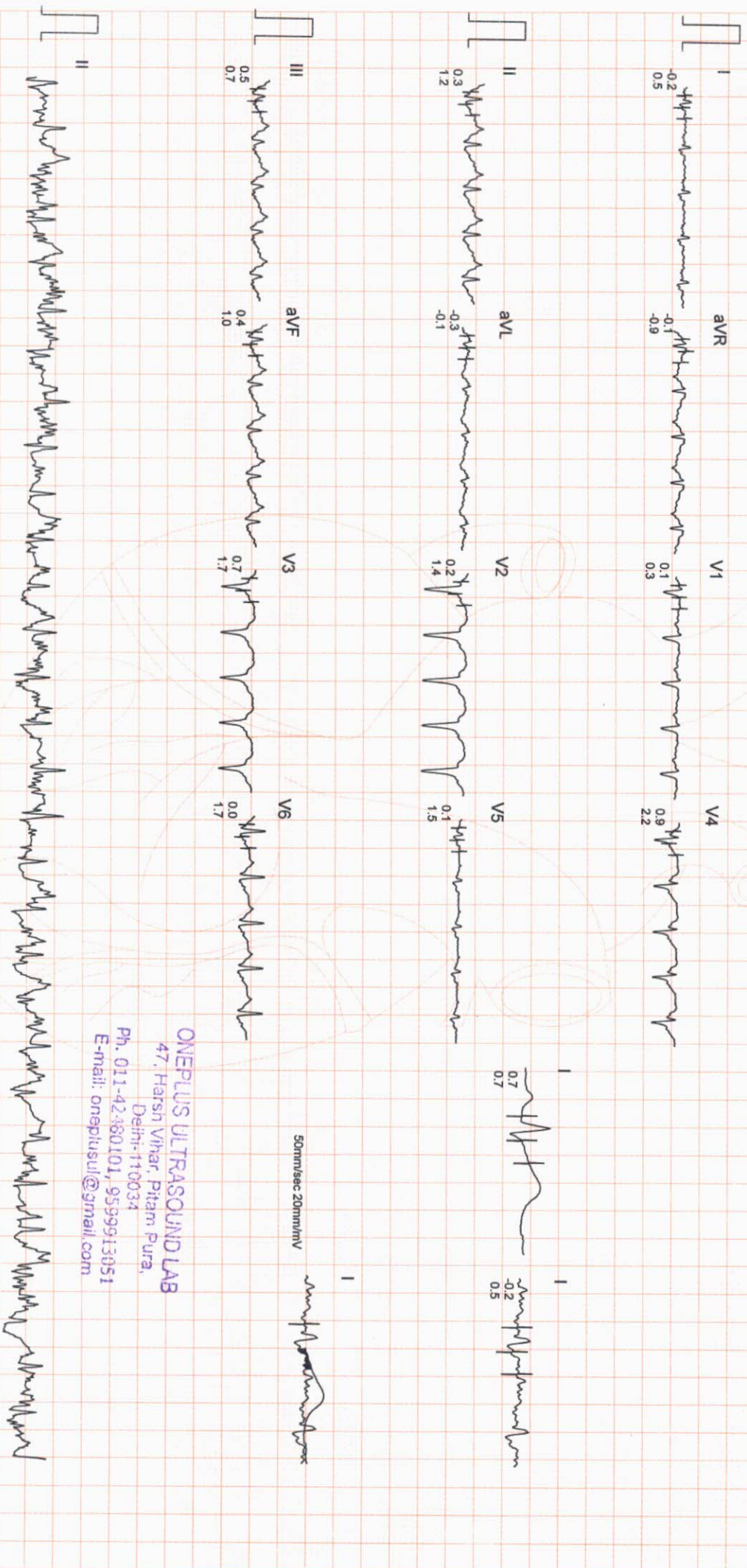
Ms. RICHA
I.D. : 999
AGE/SEX : 31/F
RECORDED : 11-11-2021 9:42

RATE : 184 BPM
R.P. : 142/80 mmHg

BRUCE
EXERCISE 3
PHASE TIME : 6:14
STAGE TIME : 0:14

ST @ 10mm/mV
80ms PostJ
SPEED : 5.4 Km./Hr.
GRADE : 14.0 %

LINKED MEDIAN



ONEPLUS ULTRASOUND LAB
47, Harsh Vihar, Pitam Pura,
Delhi-110034
Ph. 011-42480101, 9599913051
E-mail: oneplusul@gmail.com

ONEPLUS ULTRASOUND LAB

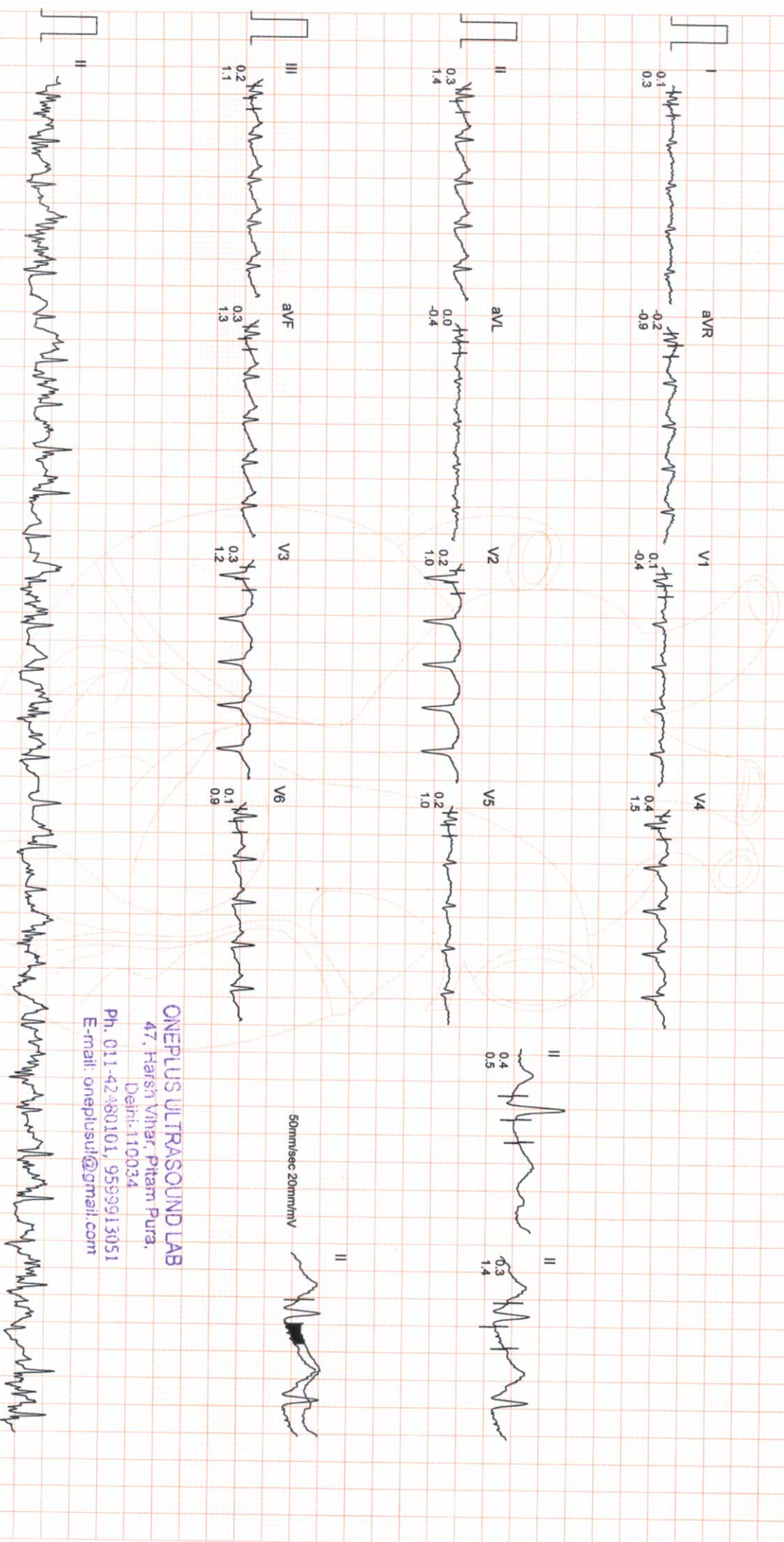
Ms. RICHA
I.D. : 999
AGE/SEX : 31/F
RECORDED : 11-11-2021 9:42

RATE : 188 BPM
B.P. : 156/84 mmHg

BRUCE
PEAK EXER
PHASE TIME : 6:25
STAGE TIME : 0:25

ST @ 10mm/mV
80ms PostJ
SPEED : 5.4 Km./Hr.
GRADE : 14.0 %

LINKED MEDIAN



ONEPLUS ULTRASOUND LAB
47, Harsh Vihar, Pitam Pura,
Delhi-110034
Ph. 011-42480101, 9599913051
E-mail: oneplusul@gmail.com

ONEPLUS ULTRASOUND LAB

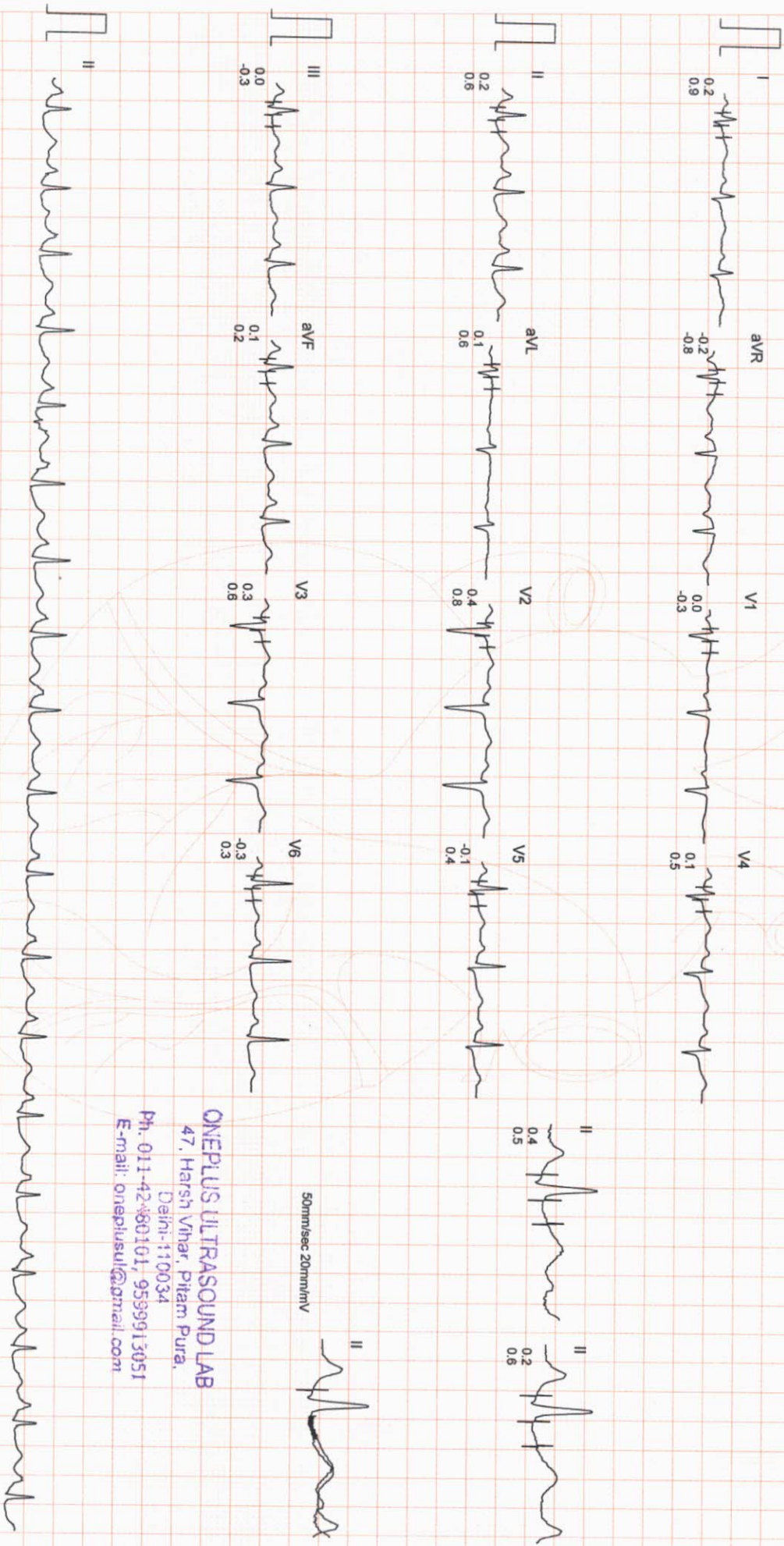
Ms. RICHA
I.D. : 999
AGE/SEX : 31/F
RECORDED : 11-11-2021 9:42

RATE : 112 BPM
B.P. : 124/78 mmHg

BRUCE
RECOVERY
PHASE TIME : 2:59

ST @ 10mm/mV
80ms PostJ
SPEED : 0.0 Km./HR.
GRADE : 0.0 %

LINKED MEDIAN



ONEPLUS ULTRASOUND LAB
47, Harsh Vihar, Pitam Pura,
Delhi-110034
Ph. 011-42460101, 9539913051
E-mail: onepiusul@gmail.com

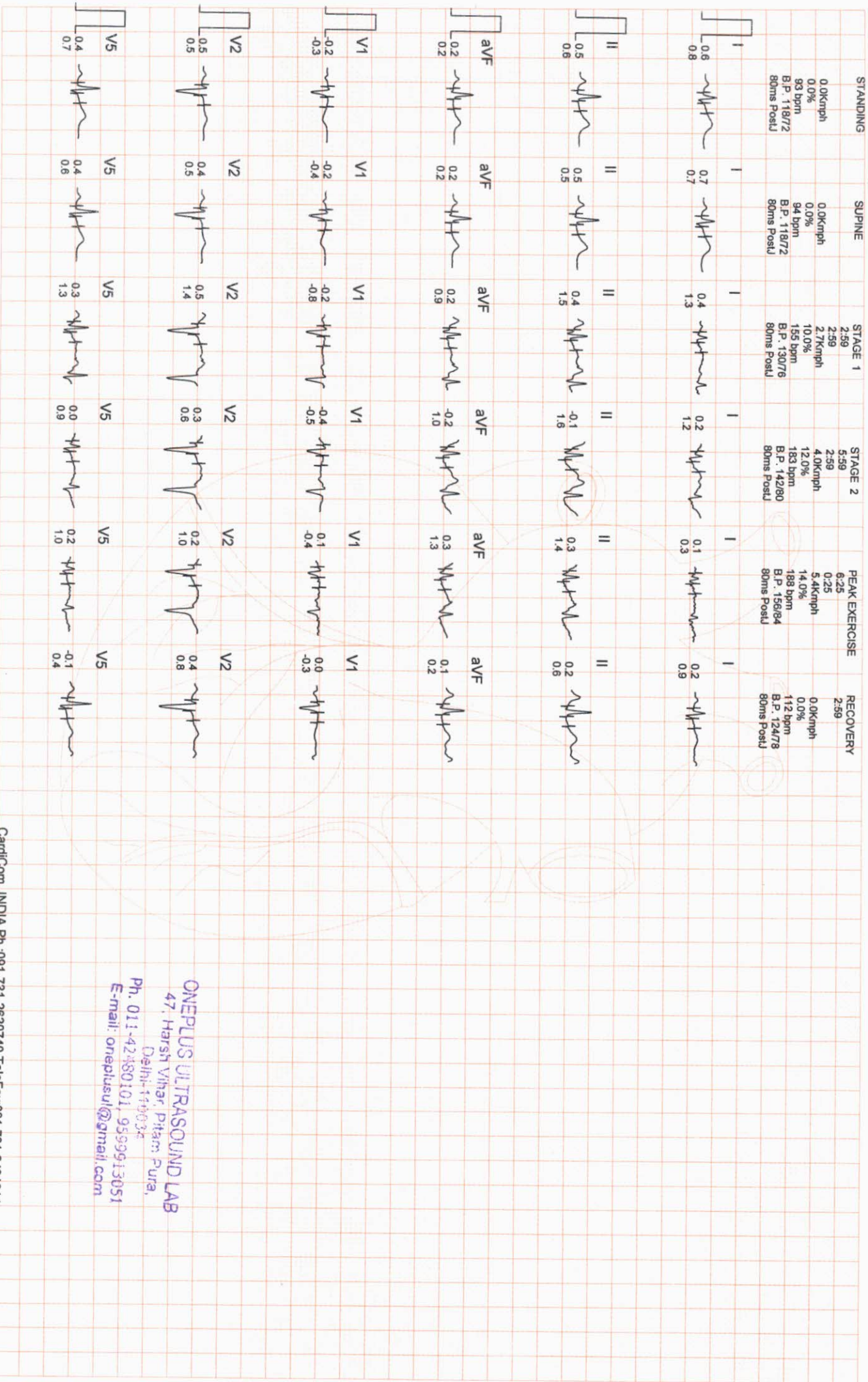
Filtered

Computer Corrected Baseline

25mm/sec 10mm/mV

ARROW

CardiCom, INDIA Ph.:091-731-2620740, Telefax:091-731-2431214























ONEPLUS ULTRASOUND LAB
 47, Harsh Vihar, Pitam Pura,
 Delhi-110034
 Ph. 011-42480101, 9599913051
 E-mail: oneplusul@gmail.com

SUPINE
 0.0Kmph
 0.0%
 94 bpm
 B.P. 118/72
 80ms PostJ

PEAK EXERCISE
 6.25
 0.25
 5.4Kmph
 0.0%
 14.0%
 188 bpm
 B.P. 156/84
 80ms PostJ

SUPINE
 0.0Kmph
 0.0%
 94 bpm
 B.P. 118/72
 80ms PostJ

PEAK EXERCISE
 6.25
 0.25
 5.4Kmph
 0.0%
 14.0%
 188 bpm
 B.P. 156/84
 80ms PostJ



ONEPLUS ULTRASOUND LAB
 47, Harsh Vihar, Pitam Pura,
 Delhi: 110013
 Ph. 011-42480101, 9599913051
 E-mail: onaplusul@gmail.com



OnePLUS
Ultrasound Lab
— QUALITY FIRST... ALWAYS! —

Dr. Nitin Agarwal
Pathologist & Director
Ex. Sr. Res. MAMC
& Lok Nayak Hospital
Ex. Chief of Lab Dr. Lal Path Labs.

Dr. Pooja (Garg) Agarwal
Radiologist & Director
MAMC & Lok Nayak Hospital

Name	: Mrs. RICHA	Age/Sex	: 31 YRS/Female
Ref. By	: Dr. MEDIWHEEL	Lab No	: 012111110005
Date	: 11-Nov-2021	Patient ID	: LSHHI87005

ULTRASOUND EXAMINATION----WHOLE ABDOMEN

Liver is enlarged in size (19.3 cm) and outline with altered echopattern. Diffuse increase in echogenicity of liver parenchyma is noted, suggestive of fatty infiltration (grade I). Intrahepatic biliary radicles are not dilated. No abscess or mass lesion seen. Hepatic veins, portal vein, IVC and aorta are normal. CBD is normal in caliber.

Gall bladder is well distended with anechoic lumen. Wall thickness is normal.

Both kidneys are normal in size, shape, position, outline and echopattern. Corticomedullary differentiation is maintained. No pelvicalyceal dilation or mass lesion is seen.

Spleen is normal in size and echotexture. No mass lesion seen.

Pancreas is normal in size, outline and echotexture.

Urinary bladder is normal in shape and position. No evidence of intravesical stone or mass seen.

Uterus. is normal in size (measures 7.8 x 3.4 cm), shape, position and echopattern. No mass seen

Uterine cavity is empty. Endometrial thickness is 8.7mm.

Both ovaries appear normal in size, shape and echopattern. No tubo-ovarian mass seen.

No abnormal bowel wall thickening seen in right iliac fossa.
No free fluid seen anywhere in abdomen.

IMPRESSION:

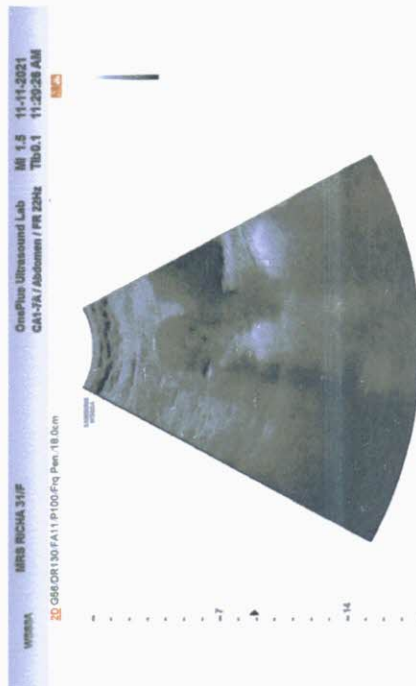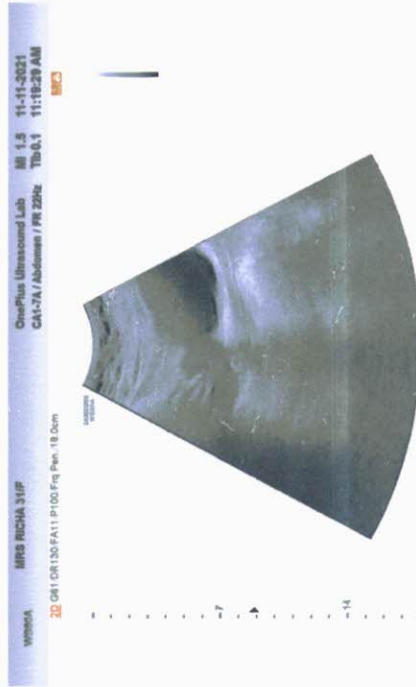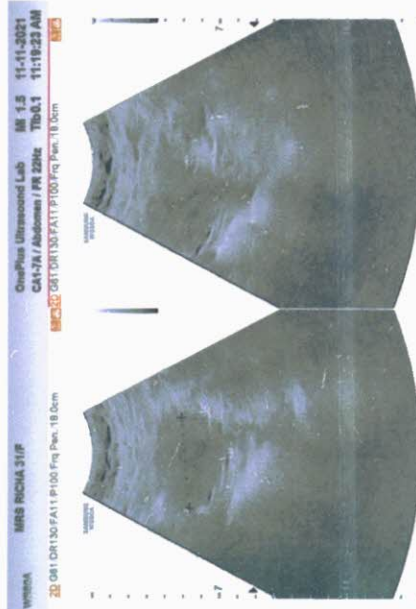
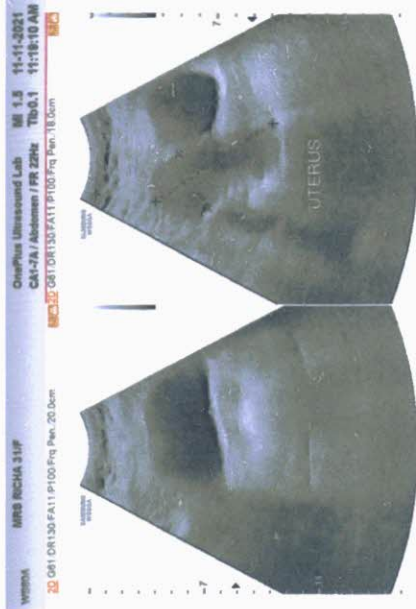
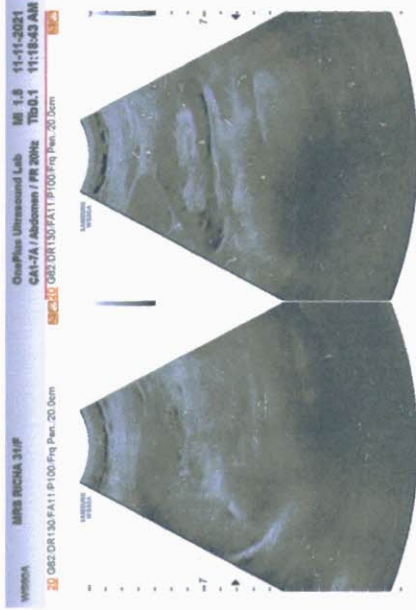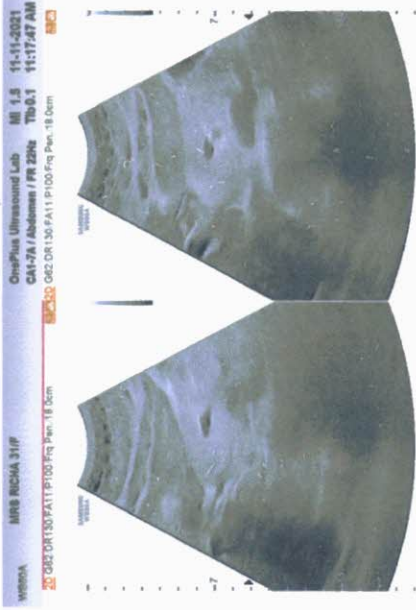
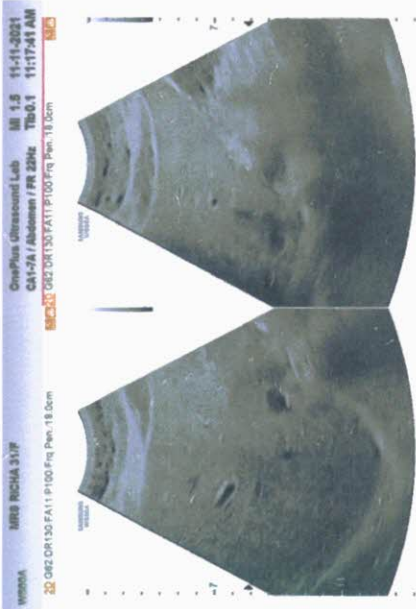- Fatty infiltration of liver (grade I) with hepatomegaly

DR. POOJA GARG
RADIOLOGIST
REG NO- DMC/R/03398

Dr. POOJA GARG
M.B.B.S., D.M.R.D.
Reg. No. DMC/R/03398
Radiologist

Type By : pooja tripathi

47, Harsh Vihar, Pitampura, New Delhi-110034 | Ph.: 011-42480101, 9599913051
E-mail: oneplusul@gmail.com | Web.: www.oneplusul.in





OnePLUS
Ultrasound Lab

— QUALITY FIRST... ALWAYS! —

Dr. Nitin Agarwal

Pathologist & Director
Ex. Sr. Res. MAMC
& Lok Nayak Hospital
Ex. Chief of Lab Dr. Lal Path Labs.

Dr. Pooja (Garg) Agarwal

Radiologist & Director
MAMC & Lok Nayak Hospital

Name	: Mrs. RICHA	Age/Sex	: 31 YRS/Female
Ref. By	: Dr. MEDIWHEEL	Lab No	: 012111110005
Date	: 11-Nov-2021	Patient ID	: LSHHI87005

X-ray-Chest PA view

Bony cage and soft tissues are normal.

Cardiothoracic ratio is normal.

Mediastinum is normal.


Both hila are normal.

Both costophrenic angles are clear.

Both domes of diaphragm are normal.

Lung fields are clear. No parenchymal lesion seen.

IMPRESSION: Normal Study.


DR. POOJA GARG
RADIOLOGIST
REG NO- DMC/R/03398

Dr. POOJA GARG
M.B.B.S., D.M.R.D.
Reg No. DMC/R/03398
Radiologist

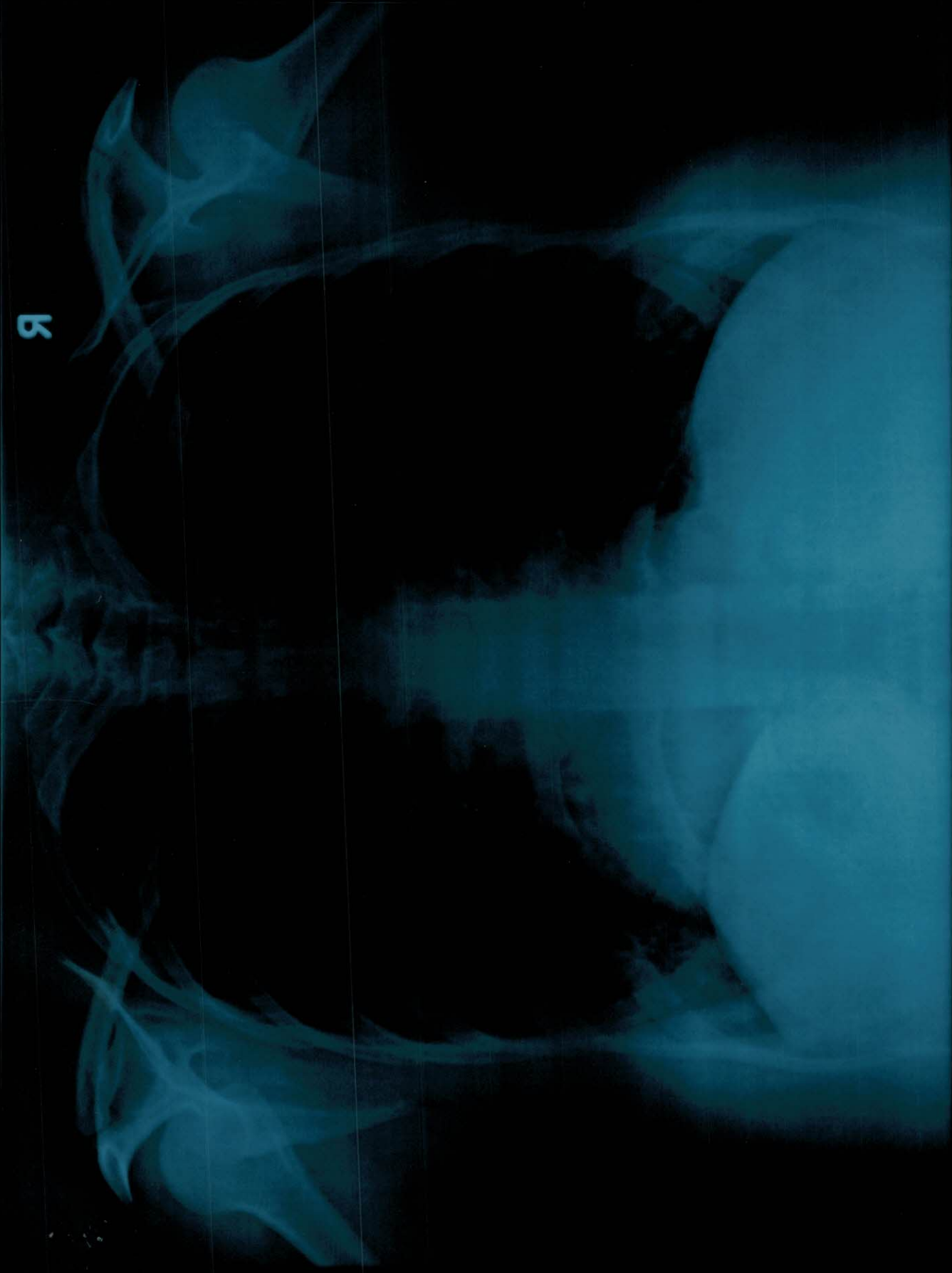
Type By : pooja tripathi

47, Harsh Vihar, Pitampura, New Delhi-110034 | Ph.: 011-42480101, 9599913051

E-mail: oneplusul@gmail.com | Web.: www.oneplusul.in

ONEPLUS ULTRASOUND LAB, 42-HARSH NIHAR, BILAMPURA
MRS RICHA AGE 31 YRS 11-11-5051 F CHEST PA VIEW 11/11/5051

R



R

MRS RICHA AGE 31 YRS 11-11-2021 F CHEST PA VIEW 11/11/2021
ONEPLUS ULTRASOUND LAB, 47-HARSH VIHAR, PITAMPURA



OnePLUS
Ultrasound Lab
— QUALITY FIRST... ALWAYS! —

Dr. Nitin Agarwal
Pathologist & Director
Ex. Sr. Res. MAMC
& Lok Nayak Hospital
Ex. Chief of Lab Dr. Lal Path Labs.

Dr. Pooja (Garg) Agarwal
Radiologist & Director
MAMC & Lok Nayak Hospital



NAME	:Mrs. RICHA	Barcode No	:10108009
AGE/GENDER	:31 YRS/Female	SPECIMEN DATE	:11/Nov/2021 09:07AM
PATIENT ID	:87005	SPECIMEN RECEIVED	:11/Nov/2021 09:24AM
REFERRED BY	:Dr. MEDIWHEEL	REPORT DATE	:11/Nov/2021 04:10PM
CENTRE NAME	:ONEPLUS ULTRASOUND LAB	LAB NO.	:012111110005

Test Name	Result	Unit	Ref. Range
-----------	--------	------	------------

HAEMATOLOGY

Health checkup 2 Female

Glycosylated Hemoglobin (HbA1c)	5.3	%	Non Diabetic adults <5.7 Prediabetic (at risk) 5.7-6.4 Diabetes >6.4
--	-----	---	--

Estimated average blood glucose (eag)	105
--	-----

Reference range (mg/dl):

90 - 120:Excellent control, 121 - 150:Good Control, 151 - 180:Average Control, 181 - 210:Action Suggested
>211:Panic value

REMARKS:-

In vitro quantitative determination of **HbA1C** in whole blood is utilized in long term monitoring of glycemia. The **HbA1C** level correlates with the mean glucose concentration prevailing in the course of the patient's recent history (approx - 6-8 weeks) and therefore provides much more reliable information for glycemia monitoring than do determinations of blood glucose or urinary glucose. It is recommended that the determination of **HbA1C** be performed at intervals of 4-6 weeks during Diabetes Mellitus therapy. On testing of HbA1C by HPLC method the result shows high variant window (93.8%) & no value of HbA1C. Therefore for accurate assay of glycaemic Control Fructosamine assay & for variant analysis Hb electrophoresis should be done.

Assay done by : Bio-Rad : D-10 (HPLC)

BLOOD GROUP (ABO)	A
Rh typing	POSITIVE

NOTE :

- * Apart from major A,B,H antigens which are used for ABO grouping and Rh typing, many minor blood group antigens exist. Agglutination may also vary according to titre of antigen and antibody.
- * So before transfusion, reconfirmation of blood group as well as cross-matching is needed.
- * Presence of maternal antibodies in newborns, may interfere with blood grouping.
- * Auto agglutination (due to cold antibody, falciparum malaria, sepsis, internal malignancy etc.) may also cause erroneous result.

CBC

Haemoglobin	10.8	g/dl	11.5-15.0
-------------	------	------	-----------

Checked By.

Dr. NITIN AGARWAL
M.B.B.S., MD (Path)
DMC/R/01436 DR. NITIN AGARWAL
MBBS, MD (PATHOLOGIST)

47, Harsh Vihar, Pitampura, New Delhi-110034 | Ph.: 011-42480101, 9599913051

E-mail: onepusul@gmail.com | Web.: www.oneplusul.in

Page 3 of 7



OnePLUS Ultrasound Lab

— QUALITY FIRST... ALWAYS! —

Dr. Nitin Agarwal
Pathologist & Director
Ex. Sr. Res. MAMC
& Lok Nayak Hospital
Ex. Chief of Lab Dr. Lal Path Labs.

Dr. Pooja (Garg) Agarwal
Radiologist & Director
MAMC & Lok Nayak Hospital



NAME	:Mrs. RICHA	Barcode No	:10108009
AGE/GENDER	:31 YRS/Female	SPECIMEN DATE	:11/Nov/2021 09:07AM
PATIENT ID	:87005	SPECIMEN RECEIVED	:11/Nov/2021 09:24AM
REFERRED BY	:Dr. MEDIWHEEL	REPORT DATE	:11/Nov/2021 04:10PM
CENTRE NAME	:ONEPLUS ULTRASOUND LAB	LAB NO.	:012111110005

Test Name	Result	Unit	Ref. Range
Total Leucocyte Count	9710	/cumm	4000-10000
Differential leucocyte count			
Neutrophils	63.8	%	40-80
Lymphocyte	30.70	%	20-40
Monocytes	4.30	%	2-10
Eosinophils	0.9	%	1-6
Basophils	0.3	%	0-2
RBC Count	4.12	million/cumm	3.8-4.8
PCV(Hematocrit)	35.5	%	36-46
MCV	86.4	fL	83-101
MCH	26.2	Pg	27-32
MCHC	30.3	G/dL	32-35
Platelet count	196000	/cumm	150000-450000
RDW-CV	16	%	11.4-14.0
ESR(WESTEGRENs METHOD)	15	mm/1hr	<20

BIOCHEMISTRY

Blood sugar fasting	106	mg/dL	70-110
----------------------------	-----	-------	--------

Checked By.


Dr. NITIN AGARWAL
MBBS, MD (Path)
DMC/R/01436

47, Harsh Vihar, Pitampura, New Delhi-110034 | Ph.: 011-42480101, 9599913051

E-mail: oneplusul@gmail.com | Web.: www.oneplusul.in

Page 2 of 7



OnePLUS Ultrasound Lab

— QUALITY FIRST... ALWAYS! —

Dr. Nitin Agarwal
Pathologist & Director
Ex. Sr. Res. MAMC
& Lok Nayak Hospital
Ex. Chief of Lab Dr. Lal Path Labs.

Dr. Pooja (Garg) Agarwal
Radiologist & Director
MAMC & Lok Nayak Hospital



NAME	:Mrs. RICHA	Barcode No	:10108009
AGE/GENDER	:31 YRS/Female	SPECIMEN DATE	:11/Nov/2021 09:07AM
PATIENT ID	:87005	SPECIMEN RECEIVED	:11/Nov/2021 02:46PM
REFERRED BY	:Dr. MEDIWHEEL	REPORT DATE	:11/Nov/2021 04:17PM
CENTRE NAME	:ONEPLUS ULTRASOUND LAB	LAB NO.	:012111110005

Test Name	Result	Unit	Ref. Range
-----------	--------	------	------------

BIOCHEMISTRY

<u>Blood sugar pp</u>	160	mg/dL	70.0-140.0
-----------------------	-----	-------	------------

Checked By.

DR. NITIN AGARWAL
MBBS, MD (PATHOLOGIST)

Dr NITIN AGARWAL
M B B S . MD (Path)

47, Harsh Vihar, Pitampura, New Delhi-110034 | Ph.: 011-42480101, 0599913051

E-mail: oneplusul@gmail.com | Web.: www.oneplusul.in

Page 3 of 7

Clinical correlation is essential for final diagnosis. • If test results are unsatisfactory please contact personally or on phone. • This report is for perusal of doctors only.
• All disputes Subject to Delhi Jurisdiction only. • Not for medicolegal purposes. • All congenital anomalies in a foetus may not be diagnosed in routine obstetric ultrasound.



OnePLUS

Ultrasound Lab

— QUALITY FIRST... ALWAYS! —

Dr. Nitin Agarwal
Pathologist & Director
Ex. Sr. Res. MAMC
& Lok Nayak Hospital
Ex. Chief of Lab Dr. Lal Path Labs.

Dr. Pooja (Garg) Agarwal
Radiologist & Director
MAMC & Lok Nayak Hospital



NAME	:Mrs. RICHA	Barcode No	:10108009
AGE/GENDER	:31 YRS/Female	SPECIMEN DATE	:11/Nov/2021 09:07AM
PATIENT ID	:87005	SPECIMEN RECEIVED	:11/Nov/2021 09:24AM
REFERRED BY	:Dr. MEDIWHEEL	REPORT DATE	:11/Nov/2021 04:10PM
CENTRE NAME	:ONEPLUS ULTRASOUND LAB	LAB NO.	:012111110005

Test Name	Result	Unit	Ref. Range
BIOCHEMISTRY			
Bun (blood urea nitrogen)	12.40	mg/dl	7-18.7
Uric acid, serum	4.6	mg/dl	2.4-5.7
Creatinine, serum	0.61	mg/dl	0.50-0.9
LFT(LIVER FUNCTION TEST)			
Bilirubin Total	0.64	mg/dl	0.1-1.2
Bilirubin Conjugated	0.34	mg/dl	0-0.4
Bilirubin Unconjugated	0.30	mg/dl	up to 0.7
SGOT (AST)	31	U/L	0-31
SGPT (ALT)	18	U/L	<34
Alkaline phosphatase	96	U/L	35-104
Gamma glutamyl transpeptidase	30	U/L	<39
Total Protein	7.8	gm/dl	6.60 - 8.70
Albumin	4.6	g/dL	3.8-5.1
Globulin	3.20	gm/dl	1.8-3.4
Albumin/Globulin Ratio	1.44		1.10 - 2.50
LIPID PROFILE			
Cholesterol	158	mg/dl	50-200
Triglycerides	143	mg/dL	25-150
HDL Cholesterol	44	mg/dL	30 - 70
LDL cholesterol	85	mg/dL	< 130
VLDL cholesterol	28.6	mg/dL	5-40
Cholesterol/HDL Ratio	3.6		Low Risk 3.3-4.97 Average Risk 4.4-7.1 Moderate Risk 7.1-11.0 High Risk >11.0
LDL/HDL Ratio	1.9		0 - 3.55

According to ATP III and NCEP guidelines

Checked By.

DR. NITIN AGARWAL
MBBS, MD (PATHOLOGIST)
Dr NITIN AGARWAL
M B B S , MD (Path)
DMC/R/01436

47, Harsh Vihar, Pitampura, New Delhi-110034 | Ph.: 011-42480101, 9599913051

E-mail: oneplusul@gmail.com | Web.: www.oneplusul.in

Page 4 of 7

Clinical correlation is essential for final diagnosis. • If test results are unsatisfactory please contact personally or on phone. • This report is for perusal of doctors only.
• All disputes Subject to Delhi Jurisdiction only. • Not for medicolegal purposes. • All congenital anomalies in a foetus may not be diagnosed in routine obstetric ultrasound.



OnePLUS
Ultrasound Lab
— QUALITY FIRST... ALWAYS! —

Dr. Nitin Agarwal
Pathologist & Director
Ex. Sr. Res. MAMC
& Lok Nayak Hospital
Ex. Chief of Lab Dr. Lal Path Labs.

Dr. Pooja (Garg) Agarwal
Radiologist & Director
MAMC & Lok Nayak Hospital



NAME	:Mrs. RICHA	Barcode No	:10108009
AGE/GENDER	:31 YRS/Female	SPECIMEN DATE	:11/Nov/2021 09:07AM
PATIENT ID	:87005	SPECIMEN RECEIVED	:11/Nov/2021 09:24AM
REFERRED BY	:Dr. MEDIWHEEL	REPORT DATE	:11/Nov/2021 04:10PM
CENTRE NAME	:ONEPLUS ULTRASOUND LAB	LAB NO.	:012111110005

Test Name	Result	Unit	Ref. Range	
Parameter	Normal	Desirable	Borderline	High
Total cholesterol	<200	200-239		240
Triglycerides	<150	150-199	200-499	500
LDL	Optimal <100 Near Optimal 100-129	130-159	160-180	190
HDL	<40 : LOW 60 : HIGH			

ENDOCRINOLOGY

THYROID PROFILE(T3,T4,TSH)

Triiodothyronine total [t3]	0.74	ng/dl	0.52-1.9
Thyroxine total [t4]	8.20	µg/dl	4.8-11.6
TSH (Thyroid Stimulating Hormone)	3.65	µIU/ml	0.25-5.0

AGE WISE VARIATION IN TSH

AGE	TSH(µIU/ml)	AGE	TSH(µIU/ml)
1-4 weeks	1.00 - 19.0	16-20 yrs	0.25 - 5.0
1-12 mths	1.70 - 9.1	21 - 80 yrs	0.25 - 5.0
1-5 yrs	0.80 - 8.2	I st trimester	0.25 - 5.0
6-10 yrs	0.25 - 5.0	II nd trimester	0.50 - 5.0
11-15 yrs	0.25 - 5.0	II rd trimester	0.4 - 6.0

Reference ranges - Interpretation of Diagnostic tests - (Jacques Wallach)

1. Primary hypothyroidism is accompanied by depressed serum T3 and T4 values and elevated serum TSH level.
2. Primary hyperthyroidism is accompanied by elevated serum T3 and T4 levels along with depressed TSH values.
3. Slightly elevated T3 levels may be found in pregnancy and estrogen therapy, while depressed levels may be encountered in severe illness, renal failure and during therapy with drugs like propranolol and propyl thiouracil.
4. Although elevated TSH levels are nearly always indicative of primary hypothyroidism, and may be seen in secondary thyrotoxicosis

CLINICAL PATHOLOGY

URINE ROUTINE

Checked By.

Dr. NITIN AGARWAL
MBBS, MD (PATHOLOGIST)
DMC/R/01436

47, Harsh Vihar, Pitampura, New Delhi-110034 | Ph.: 011-42480101, 9599913051
E-mail: onepusul@gmail.com | Web.: www.onepusul.in



OnePLUS Ultrasound Lab

— QUALITY FIRST... ALWAYS! —

Dr. Nitin Agarwal
Pathologist & Director
Ex. Sr. Res. MAMC
& Lok Nayak Hospital
Ex. Chief of Lab Dr. Lal Path Labs.

Dr. Pooja (Garg) Agarwal
Radiologist & Director
MAMC & Lok Nayak Hospital



NAME	:Mrs. RICHA	Barcode No	:10108009
AGE/GENDER	:31 YRS/Female	SPECIMEN DATE	:11/Nov/2021 09:07AM
PATIENT ID	:87005	SPECIMEN RECEIVED	:11/Nov/2021 09:24AM
REFERRED BY	:Dr. MEDIWHEEL	REPORT DATE	:11/Nov/2021 04:10PM
CENTRE NAME	:ONEPLUS ULTRASOUND LAB	LAB NO.	:012111110005

Test Name	Result	Unit	Ref. Range
-----------	--------	------	------------

Physical examination

Quantity	20		ML
Colour	PALE YELLOW		
Transparency	SLIGHTLY TURBID		CLEAR
Sp.gravity	1.015		1.010-1.030
pH	6.00		
Reaction	ACIDIC		ACIDIC

Chemical examination

Urine protein	NIL		NIL
Urine sugar	NIL		NIL
Bilirubin, urine	NEGATIVE		NEGATIVE
Urobilinogen	NORMAL		NORMAL
Ketones	NEGATIVE		NEGATIVE

Microscopic examination

Pus cells.	3-4	/HPF	1-2
Epithelial cells	3-5	/HPF	0-5
R.B.C.	NIL	/HPF	NIL
Casts	NIL	/HPF	NIL
Crystals	NIL	/HPF	NIL
Bacteria	NIL	/HPF	NIL
Others.	NIL		NIL

STOOL ROUTINE

Physical examination

Colour	BROWNISH		Brownish
Consistency	SEMI FORMED		Semi Formed
Blood	ABSENT		Absent
Mucus	ABSENT		Absent

Chemical examination, stool

Checked By.

DR. NITIN AGARWAL
MBBS, MD (PATHOLOGIST)

Dr NITIN AGARWAL
M B B S . MD (Path)

47, Harsh Vihar, Pitampura, New Delhi-110034 | Ph.: 011-42480101, 9599913051

E-mail: oneplusul@gmail.com | Web.: www.oneplusul.in

Page 6 of 7



OnePLUS Ultrasound Lab

— QUALITY FIRST... ALWAYS! —

Dr. Nitin Agarwal
Pathologist & Director
Ex. Sr. Res. MAMC
& Lok Nayak Hospital
Ex. Chief of Lab Dr. Lal Path Labs.

Dr. Pooja (Garg) Agarwal
Radiologist & Director
MAMC & Lok Nayak Hospital



NAME	:Mrs. RICHA	Barcode No	:10108009
AGE/GENDER	:31 YRS/Female	SPECIMEN DATE	:11/Nov/2021 09:07AM
PATIENT ID	:87005	SPECIMEN RECEIVED	:11/Nov/2021 09:24AM
REFERRED BY	:Dr. MEDIWHEEL	REPORT DATE	:11/Nov/2021 04:10PM
CENTRE NAME	:ONEPLUS ULTRASOUND LAB	LAB NO.	:012111110005

Test Name	Result	Unit	Ref. Range
pH	6.00		
<u>Microscopic examination</u>			
Pus cells	NIL	/HPF	10-11
Red blood cells	NIL	NIL	
Ova	ABSENT		NIL
Cysts	NIL		NIL
Bacteria	NIL	/HPF	NIL
Others	NIL		

*** End Of Report ***

Checked By.

DR. NITIN AGARWAL
MBBS,MD(PATHOLOGIST)

47, Harsh Vihar, Pitampura, New Delhi-110034 | Ph.: 011-42480101, 9599913051
E-mail: oneplusul@gmail.com | Web.: www.oneplusul.in

Dr NITIN AGARWAL

DMC/R/01435 Page 7 of 7