



YASHFEEN CARDIAC HOSPITAL™

At. & Po. Viraval, Navsari. 396 445. Phone (H) (02637) 235725
Website : www.yashfeenhospital.in E-mail : info@yashfeenhospital.in
(For Laboratory Reports Only)



Patient Name : DIVYESH CHANDRAKANT GOHIL Age : 37 Years Sex : M
Ref By Dr. : - Area : Khergam Date : 14/09/2024
Sample Time : 14/09/2024 10:16 No : 33 Time : 1:13PM

HAEMOGRAM

Test	Findings	UOM	Normal Range
HAEMOGLOBIN	16.7	g/dl	M-13.5-17.0 gm/dl F-11.5-15.5 gm/dl
HAEMOGRAM			
RED BLOOD CELL	6.20	10 ⁶ /μL	3.76-5.70
TOTAL LEUCOCYTE COUNT	11500	10 ³ /μL	4,000-11,000cells/cumm
Differential Count			
Neutrophil	71	%	40-75 %
Lymphocytes	25	%	20-40 %
Eosinophil	1	%	01-06 %
Monocytes	3	%	02-10 %
Basophils	0	%	00-00 %
PLATELET COUNT	289000	10 ³ /μL	1.5-5.5 Lacs/cumm
RBC INDICES			
P.C.V.	48.8	%	Male-40-56%, Female-37-47%
M.C.V.	78.7	fL	76.0-94.0
M.C.H.	26.9	pg	27.0-30.0
M.C.H.C.	34.2	g/dl	30.0-35.0
=			
BLOOD GROUP	" B "	-	-
RH FACTOR	POSITIVE	-	-
E.S.R.(1 hour)	12	mm/hr.	Male-5-10 mm/hr, Female-5-20 mm/hr



Dr. PIYUSH B. CHAUDHARI
M.D. Medicine
Reg. No. G-21518
Yashfeen Cardiac Hospital

Remarks

Designed By : Sarita Infotech Pvt. Ltd., Navsari

signature

Technician

Thanks for Reference



YASHFEEN CARDIAC HOSPITAL™

At. & Po. Viraval, Navsari. 396 445. Phone (H) (02637) 235725
Website : www.yashfeenhospital.in E-mail : info@yashfeenhospital.in
(For Laboratory Reports Only)



Patient Name : DIVYESH CHANDRAKANT GOHIL Age : 37 Years Sex : M
Ref By Dr. : - Area : Khergam Date : 14/09/2024
Sample Time : 14/09/2024 10:17 No : 33 Time : 1:13PM

HAEMOGLOBIN A1 C ESTIMATION

Test	Findings	UOM	Normal Range
Hb A1C	13.8	%	>8 :Action Suggested, 7-8 :Good Control, <7 :Goal, 6-7 :Near Normal Glycemia, <6 :Non-diabetic Level
Technique METHOD - HPLC			
Mean Blood Glucose	348.8	mg/dL	



Dr. PIYUSH B. CHAUDHARI

M.D. Medicine

Reg. No. G-21518

Yashfeen Cardiac Hospital

Remarks

Designed By : Sarita Infotech Pvt. Ltd., Navsari

signature

Technician

Thanks for Reference




YASHFEEN CARDIAC HOSPITAL™

At. & Po. Viraval, Navsari. 396 445. Phone (H) (02637) 235725

Website : www.yashfeenhospital.in E-mail : info@yashfeenhospital.in

(For Laboratory Reports Only)



Patient Name : DIVYESH CHANDRAKANT GOHIL
Ref By Dr. : -
Sample Time : 14/09/2024 10:17 No : 33

Age : 37 Years Sex : M
Area : Khergam Date : 14/09/2024
Time : 1:14PM

BIOCHEMICAL TEST REPORT

Test	Findings	UOM	Normal Range
S.CREATININE	0.6	mg/dL	Male-0.9-1.4 mg/dL, Female-0.8-1.2 mg/dL
BLOOD UREA NITROGEN	5.4	mg/dL	4.7-23.0 mg/dL
S.URIC ACID	4.5	mg/dL	Male:3.5-7.2 mg/dL, Female:2.6-6.0 mg/dL



Dr. PIYUSH B. CHAUDHARI
M.D. Medicine
Reg. No. G-21518

Remarks

Designed By : Sarita Infotech Pvt. Ltd., Navsari

Yashfeen Cardiac Hospital

Signature

Thanks for Reference

Technician



YASHFEEN CARDIAC HOSPITAL™

At. & Po. Viraval, Navsari. 396 445. Phone (H) (02637) 235725
Website : www.yashfeenhospital.in E-mail : info@yashfeenhospital.in
(For Laboratory Reports Only)



Patient Name : DIVYESH CHANDRAKANT GOHIL Age : 37 Years Sex : M
Ref By Dr. : - Area : Khergam Date : 14/09/2024
Sample Time : 14/09/2024 10:17 No : 33 Time : 1:14PM

LIPID PROFILE TEST REPORT

Test	Findings	UOM	Normal Range
S.CHOLESTEROL	225.1	mg/dL	<200:Desirable, 200-239:Borderline High, >=240:High
HDL CHOLESTEROL	49.9	mg/dL	<40:Low(High Risk), >=60:High(Low Risk)
LDL CHOLESTEROL	165.0	mg/dL	<100.0: Optimal, 100.0-129.0: Nearoptimal/ Aboveoptimal, 130.0-159.0:Borderline High, 160.0-189.0:High, >=190.0:Very High
VLDL CHOLESTEROL	35.6	mg/dL	Upto 40.0 mg/dL
S.TRIGLYCERIDES	178.0	mg/dL	<150.0:Normal, 150.0-199.0:Borderline high, 200.0-499.0:High, >=500.0:Very High
CHOL/ HDL RATIO	4.5	mg/dL	LESS THAN 5.0
LDL/ HDL RATIO	3.3	mg/dl.	LESS THAN 5.0



Dr. PIYUSH B. CHAUDHART
M.D. Medicine
Reg. No. G-21518

Remarks

Designed By : Sarita Infotech Pvt. Ltd., Navsari

Yashfeen Cardiac Hospital

Signature

Thanks for Reference

Technician



YASHFEEN CARDIAC HOSPITAL™

At. & Po. Viraval, Navsari. 396 445. Phone (H) (02637) 235725

Website : www.yashfeenhospital.in E-mail : info@yashfeenhospital.in

(For Laboratory Reports Only)



Patient Name : DIVYESH CHANDRAKANT GOHIL
Ref By Dr. : -
Sample Time : 14/09/2024 10:17 No : 33

Age : 37 Years Sex : M
Area : Khergam Date : 14/09/2024
Time : 1:14PM

LIVER FUNCTION TEST REPORT

Test	Findings	UOM	Normal Range
TOTAL BILIRUBIN	0.5	mg/dL	0-1.0 mg/dL
DIRECT BILIRUBIN	0.2	mg/dL	0-0.8 mg/dL
INDIRECT BILIRUBIN	0.3	mg/dL	0-0.2 mg/dL
SGPT	14.6	U/L	Below 40.0 U/L
S.ALKALINE PHOSPHATASE	173.7	U/L	Child-170.0-515.0 U/L, Adults-37.0-147.0 U/L
TOTAL PROTEIN	7.3	g/dl	6.0-8.0 g/dl
ALBUMIN	4.6	g/dl	3.0-5.0 g/dl
GLOBULIN	2.7	g/dl	3.0-3.5 g/dl
A/G	1.7	g/dl	
SGOT	11.0	U/L	Below 40.0 U/L



Dr. PIYUSH B. CHAUDHARI

M.D. Medicine

Reg. No. G-21518

Yashfeen Cardiac Hospital

Remarks

Designed By : Sarita Infotech Pvt. Ltd., Navsari

Signature

Thanks for Reference

Technician




YASHFEEN CARDIAC HOSPITAL™

At. & Po. Viraval, Navsari. 396 445. Phone (H) (02637) 235725

Website : www.yashfeenhospital.in E-mail : info@yashfeenhospital.in

(For Laboratory Reports Only)



Patient Name : DIVYESH CHANDRAKANT GOHIL

Age : 37 Years Sex : M

Ref By Dr. : -

Area : Khergam Date : 14/09/2024

Sample Time : 14/09/2024 10:17 No : 33

Time : 1:14PM

THYROID FUNCTION TEST REPORT

Test	Findings	UOM	Normal Range
T3 (TRIODOXYRONINE)	1.32	ng/ml	Newborns:0.73-2.88, 6 Days-3 Months:0.80-2.75, 4-12Months:0.86-2.65, 1-6 Years:0.92-2.48, 7-11 Years:0.93-2.31, 12-20Years:0.91-2.18, Adults:0.80-2.00
T4(THYROXINE)	8.17	µg/dl	Newborns:5.04-18.5, 6 Days-3 Months:5.41-17.0, 4-12 Months:5.67-16.0, 1-6 Years:5.95-14.7, 7-11 Years:5.99-13.8, 12-20 Years:5.91-13.2, Adults:5.10-14.1
TSH	1.01	µIU/ml	Newborns:0.70-15.2, 6 Days-3 Months:0.72-11.0, 4-12 Months:0.73-8.35, 1-6 Years:0.70-5.97, 7-11 Years:0.60-4.84, 12-20 Years:0.51-4.30, Adults:0.27-4.20

TECHNIQUE

ELECTROCHEMILUMINESCENCE



Dr. PIYUSH B. CHAUDHART

M.D. Medicine
Reg. No. G-21518

Remarks

Designed By : Sarita Infotech Pvt. Ltd, Navsari

Yashfeen Cardiac Hospital

Signature
signature

Thanks for Reference

Technician



YASHFEEN CARDIAC HOSPITAL™

At. & Po. Viraval, Navsari. 396 445. Phone (H) (02637) 235725
Website : www.yashfeenhospital.in E-mail : info@yashfeenhospital.in
(For Laboratory Reports Only)



Patient Name : DIVYESH CHANDRAKANT GOHIL Age : 37 Years Sex : M
Ref By Dr. : - Area : Khergam Date : 14/09/2024
Sample Time : 14/09/2024 10:17 No : 33 Time : 1:14PM

GGT TEST REPORT

Test	Findings	UOM	Normal Range
SERUM GGT	40.0	U/L	10.0-71.0 U/L



Dr. PIYUSH B. CHAUDHARI

M.D. Medicine
Reg. No. G-21518

Yashfeen Cardiac Hospital


Remarks

Designed By : Sarita Infotech Pvt. Ltd., Navsari

signature

Technician

Thanks for Reference



YASHFEEN CARDIAC HOSPITAL™

At. & Po. Viraval, Navsari. 396 445. Phone (H) (02637) 235725

Website : www.yashfeenhospital.in E-mail : info@yashfeenhospital.in
(For Laboratory Reports Only)



Patient Name : DIVYESH CHANDRAKANT GOHIL Age : 37 Years Sex : M
Ref By Dr. : - Area : Khergam Date : 14/09/2024
Sample Time : 14/09/2024 10:17 No : 33 Time : 1:14PM

ROUTINE URINE ANALYSIS

Test	Findings	UOM	Normal Range
PHYSICAL EXAMINATION			
Quantity	-	-	
Colour	YELLOW	-	
Appearance	CLEAR	-	
Reaction	ACIDIC	-	
Sp. Gravity	1.003	-	
CHEMICAL EXAMINATION			
U.Albumin	NIL	-	
Sugar	++++	-	
Acetone	NIL	-	
Bile Salt	NIL	-	
Bile Pigment	NIL	-	
Occult Blood	NIL	-	
MICROSCOPIC EXAMINATION			
Pus Cells	1-2	/hpf	
Epithelial cells	1-2	/hpf	
Red cells	ABSENT	/hpf	
Casts	-	/hpf	
Crystals	AMORPHOUS SEEN	/hpf	
Others	-	/hpf	



Dr. PIYUSH B. CHAUDHARI
M.D. Medicine
Reg. No. G-21518

Remarks

Designed By : Sarita Infotech Pvt. Ltd., Navsari

Yashfeen Cardiac Hospital

Signature

Technician

Thanks for Reference



YASHFEEN CARDIAC HOSPITAL™

At. & Po. Viraval, Navsari. 396 445. Phone (H) (02637) 235725

Website : www.yashfeenhospital.in E-mail : info@yashfeenhospital.in
(For Laboratory Reports Only)



Patient Name : DIVYESH CHANDRAKANT GOHIL Age : 37 Years Sex : M
Ref By Dr. : - Area : Khergam Date : 14/09/2024
Sample Time : 14/09/2024 10:18 No : 33 Time : 1:14PM

BLOOD SUGAR TEST REPORT

Test	Findings	UOM	Normal Range
FASTING BLOOD SUGAR	350.4	mg/dL	70-110 mg/dL
FASTING URINE SUGAR	++++	-	NIL
POSTPANDRIAL BLOOD SUGAR	365.0	mg/dL	70-140 mg/dL
POSTPANDRIAL URINE SUGAR	++++	-	NIL



Dr. PIYUSH B. CHAUDHART
M.D. Medicine
Reg. No. G-21518

Remarks

Designed By : Sarita Infotech Pvt. Ltd., Navsari

Yashfeen Cardiac Hospital

Signature

Thanks for Reference

Technician

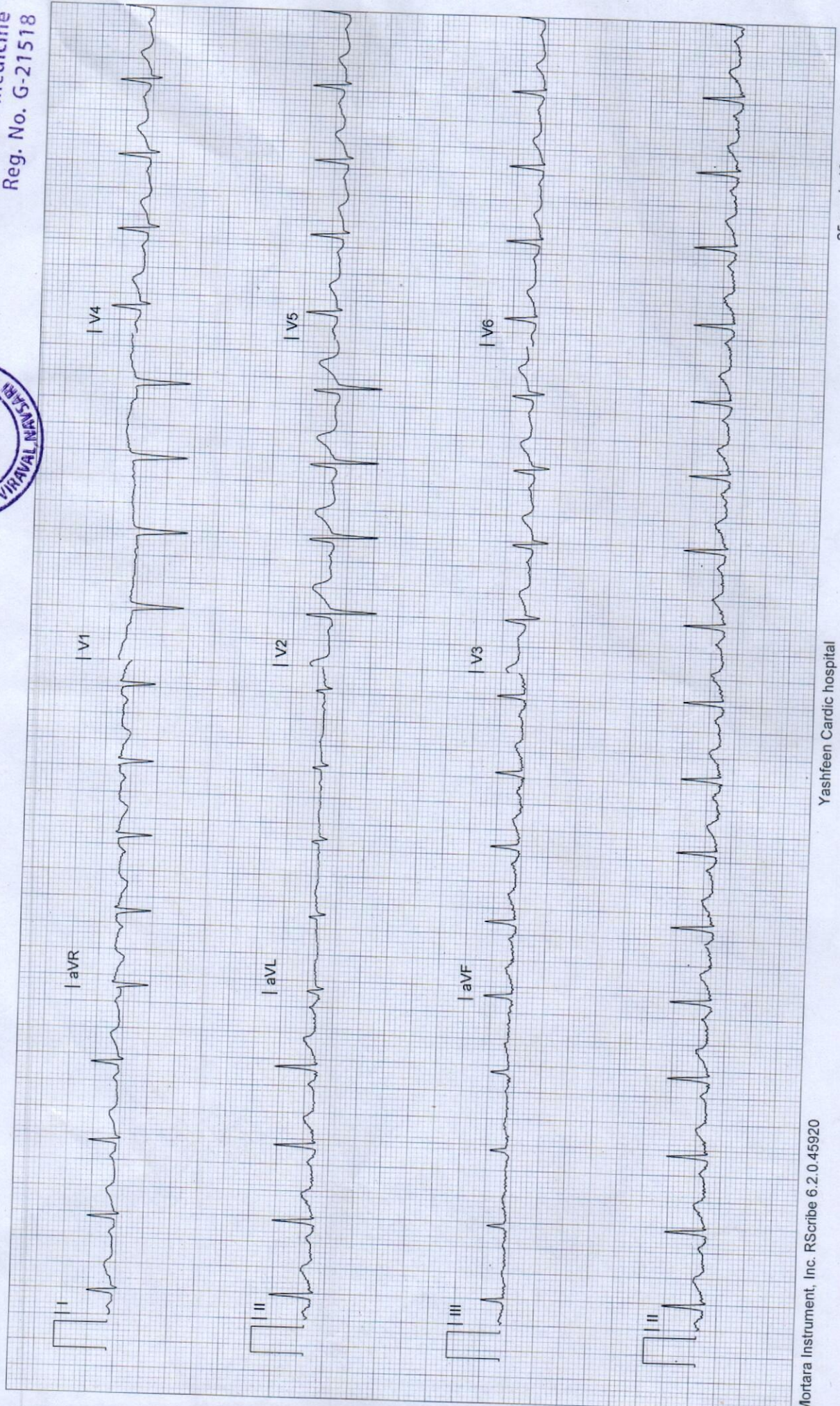
DIVYESH,
ID:
DOB:
37 Years,,
Male ,Unknown
Med.:

14-09-2024 11:14:01
Vent. Rate: 103 BPM
PR int: 145 ms
QRS dur: 85 ms
QT/QTc: 312/372 ms
P-R-T axes: 48 59 51
Avg. RR: 578 ms
QTcB: 410 ms
QTcF: 374 ms

SINUS TACHYCARDIA
ABNORMAL RHYTHM ECG
UNCONFIRMED REPORT
Reviewed by:



Signed by:
Date:
Dr. PIYUSH B. CHAUDHARI
M.D. Medicine
Reg. No. G-21518



YASHFEEN IMAGING & RADIOLOGY DEPARTMENT

MANAGED BY :- YASHFEEN FOUNDATION

VIRAVAL, NAVSARI. 396 445. PHONE : (H) (02637) 235725

Website : www.yashfeenhospital.in E-mail : info@yashfeenhospital.in

Patient's Name:	DIVYESH C. GOHIL	Age & Sex:	37Yrs/M
Ref. by Dr.	SELF	Date:	14-09-2024

X RAY CHEST (PA VIEW)

Both lung fields appear normal.

Both hila appear normal.

Both CP angles appear clear.

Cardiac size appears within normal limit.

Both domes of diaphragm appear normal.

Bony thoracic cage appears normal.

IMPRESSION:

- Normal X-ray chest (PA view).




Dr. DHARMESH DESAI
Dr. Dharmesh Desai
(M.D. Radiology)
Reg. No. 45284
YASHFEEN GROUP OF HOSPITAL

Please contact immediately for any typographical error.

This is only professional opinion, not a final diagnosis. Kindly correlate clinically. Not valid for medicolegal purpose.



(Regd. No. E / 1390 / Navsari)

YASHFEEN CARDIAC HOSPITAL™

MANAGED BY :- YASHFEEN FOUNDATION

VIRAVAL, NAVSARI. 396 445. PHONE : (H) (02637) 235725

Website : www.yashfeenhospital.in E-mail : info@yashfeenhospital.in

(Stationary For Report Only)

2D ECHO CARDIOGRAPHY COLOUR DOPPLER REPORT

Patient Name & No	: DIVYESH CHANDRAKANT GOHIL CH24022635	Age/Sex	UHID :	: 2690
Doctor	: Mohil Nagad	37/ M	No :	: 2761
Referred By	:		Date :	: 14/09/2024

M-Mode findings

LVIDd : 40mm
 LVIDs : 33mm
 IVSd : 09mm
 PWd : 09mm
 EF : 60%
 Aorta : 21mm
 LA : 28mm

2D Imaging

Aortic Valve : Trileaflet, Peak Gradient 7mm of Hg.
 Mitral Valve : Thin, Pliable, Normal Mobility, Normal function
 Tricuspid Valve : Normal
 Pulmonary Valve : Normal

=> : All cardiac chambers are normal sized.
 => : All cardiac valves are normal.
 => : No regional wall motion abnormality.
 => : Normal LV systolic function.
 => : Normal LV diastolic function.
 => : IAS/IVS intact.
 => : No obvious clots/ vegetations/ or effusion.
 => : IVC Normal size.

Doppler Findings

=> : No MS/MR, No TS/TR, No AS/AR & No PS/PR
 Mitral inflow Pattern : E > A
 Tissue Doppler Findings : E' > A'

Impression : Normal LVEF:60%, No RWMA.



Report Prepared By

-
-
-

DR. MOHIL NAGAD
 M.D. Medicine, DM. Cardiology
 Senior Consultant-Interventional Cardiology
 Reg. No. G-22893
 YASHFEEN HOSPITAL, NAVSARI

Report Checked By
 Mobin Sheikh
 M.D. (Phy) Dip. Cardiology
 Non-Invasive Cardiologist

Designed By : Sarita Infotech Pvt. Ltd., Navsari

YASHFEEN IMAGING & RADIOLOGY DEPARTMENT

MANAGED BY :- YASHFEEN FOUNDATION

VIRAVAL, NAVSARI. 396 445. PHONE : (H) (02637) 235725

Website : www.yashfeenhospital.in E-mail : info@yashfeenhospital.in

Name	DIVYESH C. GOHIL	Age	37Y/M
Ref by Dr	SELF	Date	14/09/2024

USG ABDOMEN (SCREENING)

Liver appears normal in size & shape with normal echopattern.
No e/o focal or diffuse lesion. IHBR appear normal.
PV and CBD appear normal.

Gall bladder appears distended & normal in shape & size. No e/o calculus or mass seen.
Walls appear normal.

Pancreas appears normal in size and echogenicity. No e/o focal or diffuse lesion.

Spleen appears normal in size and shows normal echopattern. No e/o focal lesion.

Both Kidneys appear normal in size and echopattern. CM Differentiation is preserved.
No e/o calculus or hydronephrosis on either side.
Perirenal spaces appear normal on either side.
Suprarenal regions appear normal on either side. No e/o mass lesion.

Bladder is physiologically distended. No e/o calculus or mass. Walls appear normal.

Prostate appears enlarged in size measuring 28 cc with normal echopattern.
No e/o calcification.

RIF region appears normal.

No e/o ascites.

IMPRESSION:

Mild prostatomegaly. Adv: S. PSA correlation.



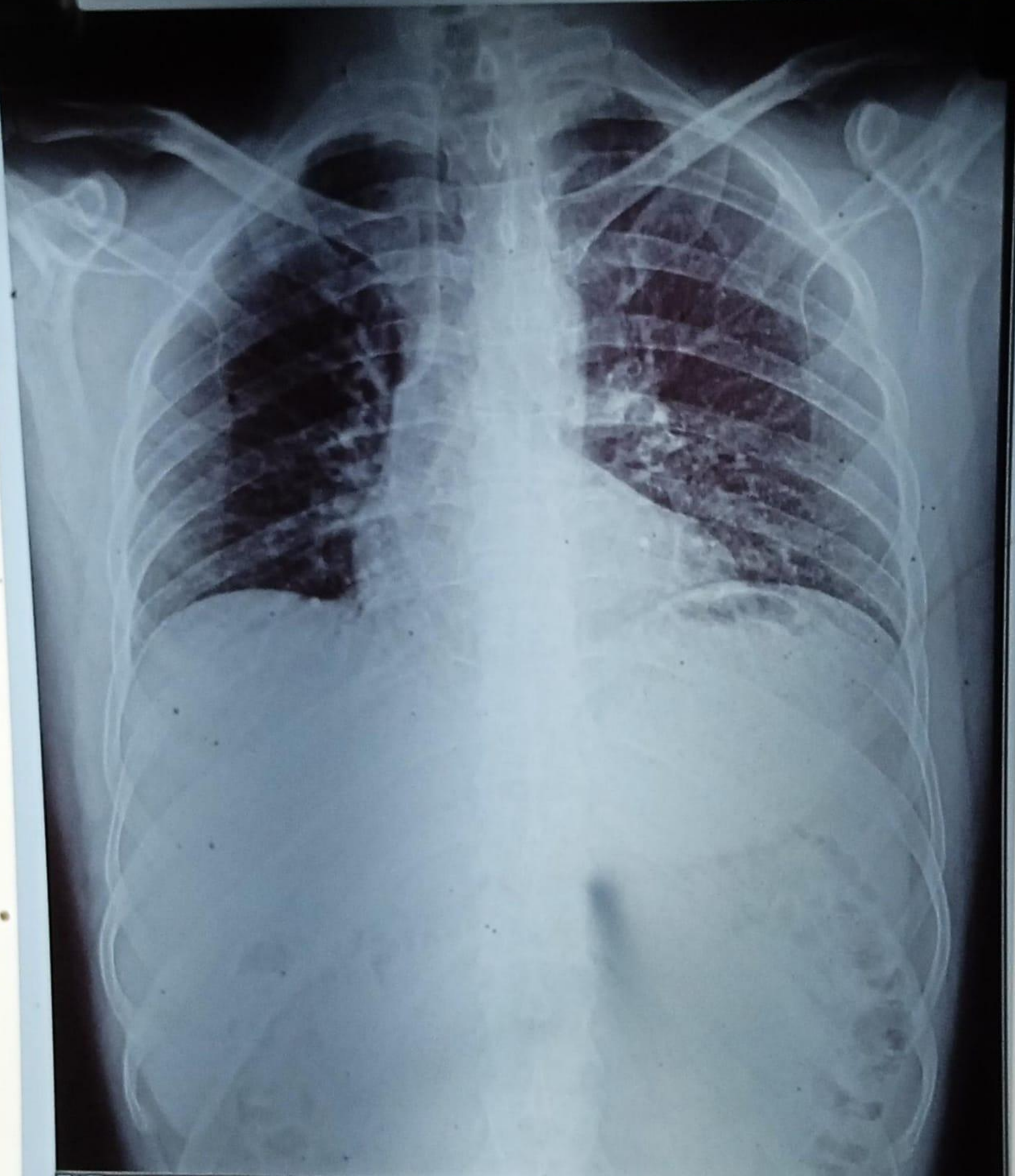
Dr. DHARMESH DESAI

(M.D. Radiology)
Dr. Dharmesh Desai
Reg. No. 45284

YASHFEEN GROUP OF HOSPITAL

Please contact immediately for any typographical error.

This is only professional opinion, not a final diagnosis. Kindly correlate clinically. Not valid for medicolegal purpose.



CH24022635 DIVYESH C GOHIL 37/Y 140924300 ChestErect PA 14/09/2024

YASHFEEN GROUP OF HOSPITALS NAVSARI PH:9924047789